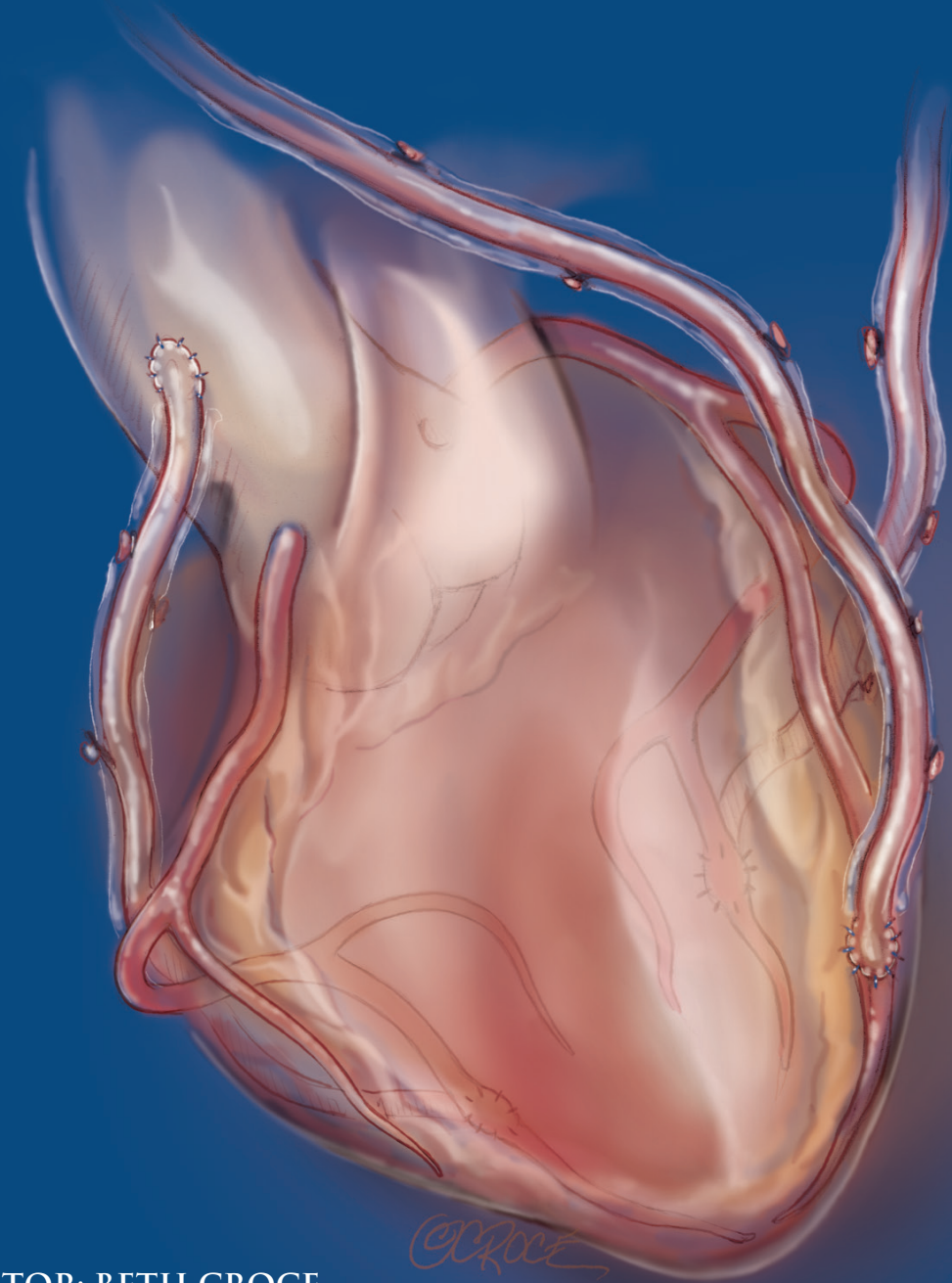


ACS

ANNALS OF CARDIOTHORACIC SURGERY

ART OF OPERATIVE TECHNIQUES

(Volume I)



ILLUSTRATOR: BETH CROCE
EDITOR: TRISTAN D. YAN



ANNALS OF CARDIOTHORACIC SURGERY:
ART OF OPERATIVE TECHNIQUES (Volume I)

EDITOR: TRISTAN D. YAN



AME Publishing Company

Room 604 6/F Hollywood Center, 77-91 Queen's road, Sheung Wan, Hong Kong

Information on this title: www.amegroups.com

For more information, contact info@amepc.org

Copyright © AME Publishing Company. All rights reserved.

This publication is in copyright. Subject to statutory exception and to the provisions of relevant collective licensing agreements, no reproduction of any part may take place without the written permission of AME Publishing Company.

First published 2016

Printed in China by AME Publishing Company

Illustrated by Beth Croce

Edited by Tristan D. Yan

Annals of Cardiothoracic Surgery: Art of Operative Techniques (Volume I)

ISBN: 978-988-14028-6-8 Hardback

AME Publishing Company has no responsibility for the persistence or accuracy of URLs for external or third-party internet websites referred to in this publication, and does not guarantee that any content on such websites is, or will remain, accurate or appropriate.

The advice and opinions expressed in this book are solely those of the author and do not necessarily represent the views or practices of AME Publishing Company. No representations are made by AME Publishing Company about the suitability of the information contained in this book, and there is no consent, endorsement or recommendation provided by AME Publishing Company, express or implied, with regard to its contents.

Annals of Cardiothoracic Surgery: Art of Operative Techniques (Volume I)

EDITOR

Tristan D. Yan

The Collaborative Research (CORE) Group, Macquarie University, Sydney, Australia; Royal Prince Alfred Hospital and Sydney Adventist Hospital University of Sydney, Sydney, Australia

ASSOCIATE EDITOR

David H. Tian

The Collaborative Research (CORE) Group, Macquarie University, Sydney, Australia

AUTHORS

Anelechi Anyanwu

Department of Cardiothoracic Surgery, Mount Sinai Health System, New York, USA

Tohru Asai

Division of Cardiovascular Surgery, Department of Surgery, Shiga University of Medical Science, Setatsukinowa, Otsu, Shiga, Japan

Arie Blitz

Department of Surgery, Division of Cardiac Surgery, University of Cincinnati Medical Center, Cincinnati, Ohio, USA

Munir Boodhwani

Division of Cardiac Surgery, University of Ottawa Heart Institute, Ottawa, Canada

Tomaso Bottio

Division of Cardiac Surgery, Department of Cardiology, Thoracic and Vascular Sciences, University Hospital of Padova, Padova, Italy

Richard F. Brodman

Grace Point Lane, Mount Desert Island, Maine, USA

Brian F. Buxton

Department of Cardiac Surgery, Austin Hospital, Heidelberg, Melbourne, Australia

Frederick Y. Chen

Brigham and Women's Hospital, Harvard Medical School, Boston, Massachusetts, USA

Anson Cheung

Division of Cardiothoracic Surgery, St. Paul's Hospital, University of British Columbia, Vancouver, Canada

Joseph S. Coselli

Division of Cardiothoracic Surgery, Michael E. DeBakey Department of Surgery, Baylor College of Medicine; Department of Cardiovascular Surgery, The Texas Heart Institute at St. Luke's Episcopal Hospital, Houston, Texas, USA

Marta Cova

Thoracic Aortic Research Center, Cardiovascular Surgery, Policlinico San Donato IRCCS, Milan, Italy

Ralph J. Damiano Jr

Division of Cardiothoracic Surgery, Department of Surgery, Washington University School of Medicine, Barnes-Jewish Hospital, St. Louis, Missouri, USA

Laurent de Kerchove

Department of Cardiothoracic and Vascular Surgery, Cliniques Universitaires Saint- Luc, Université Catholique de Louvain, Brussels, Belgium

Kim I. de la Cruz

Division of Cardiothoracic Surgery, Michael E. DeBakey Department of Surgery, Baylor College of Medicine; Department of Cardiovascular Surgery, The Texas Heart Institute at St. Luke's Episcopal Hospital, Houston, Texas, USA

Carlo de Vincentiis

Thoracic Aortic Research Center, Cardiovascular Surgery, Policlinico San Donato IRCCS, Milan, Italy

Joel Dunning

Department of Thoracic Surgery, James Cook University Hospital, Middlesbrough, UK

Gébrine El Khoury

Department of Cardiothoracic and Vascular Surgery,
Cliniques Universitaires Saint- Luc, Université Catholique
de Louvain, Brussels, Belgium

John A. Elefteriades

Aortic Institute at Yale-New Haven, Yale University School
of Medicine, New Haven, Connecticut, USA

Gino Gerosa

Division of Cardiac Surgery, Department of Cardiology,
Thoracic and Vascular Sciences, University Hospital of
Padova, Padova, Italy

Andrew B. Goldstone

Department of Cardiothoracic Surgery, Stanford University
School of Medicine, Stanford, California, USA

Viviana Grassi

Thoracic Aortic Research Center, Cardiovascular Surgery,
Policlinico San Donato IRCCS, Milan, Italy

Henrik J. Hansen

Department of Cardiothoracic Surgery 2.15.2,
Rigshospitalet, Copenhagen University Hospital, Denmark

Philip A. Hayward

Department of Cardiac Surgery, Austin Hospital,
Heidelberg, Melbourne, Australia

Takeshi Inoue

Division of Cardiovascular Surgery, Department of Surgery,
Kobe University Graduate School of Medicine, Kobe, Japan

Stephan Jacobs

Division of Cardiovascular Surgery, University Hospital
Zurich, Zurich, Switzerland

Hiroya Kano

Division of Cardiovascular Surgery, Department of Surgery,
Kobe University Graduate School of Medicine, Kobe, Japan

Joseph Lamelas

Division of Cardiothoracic Surgery, Mount Sinai Heart
Institute, Mount Sinai Medical Center, Miami Beach,
Florida, USA

Jeremy E. Leidenfrost

Division of Cardiothoracic Surgery, Department of
Surgery, Washington University School of Medicine,
Barnes-Jewish Hospital, St. Louis, Missouri, USA

Scott A. LeMaire

Division of Cardiothoracic Surgery, Michael E. DeBakey
Department of Surgery, Baylor College of Medicine;
Department of Cardiovascular Surgery, The Texas Heart
Institute at St. Luke's Episcopal Hospital, Houston, Texas,
USA

Kevin M. Lichtenstein

Brighton and Sussex Medical School, Brighton, East Sussex,
UK

Yong-Min Liu

Department of Cardiovascular Surgery, Beijing Anzhen
Hospital, Beijing Aortic Disease Center, Capital Medical
University, Beijing, China

Chiara Lomazzi

Thoracic Aortic Research Center, Cardiovascular Surgery,
Policlinico San Donato IRCCS, Milan, Italy

Wei-Guo Ma

Department of Cardiovascular Surgery, Beijing Anzhen
Hospital, Beijing Aortic Disease Center, Capital Medical
University, Beijing, China; Aortic Institute at Yale-New
Haven, Yale University School of Medicine, New Haven,
Connecticut, USA

Hitoshi Minami

Division of Cardiovascular Surgery, Department of Surgery,
Kobe University Graduate School of Medicine, Kobe, Japan

Shunsuke Miyahara

Division of Cardiovascular Surgery, Department of Surgery,
Kobe University Graduate School of Medicine, Kobe, Japan

Jahan Mohebbi

Brigham and Women's Hospital, Harvard Medical School,
Boston, Massachusetts, USA

Zahra Mosala Nezhad

Department of Cardiothoracic and Vascular Surgery,
Cliniques Universitaires Saint- Luc, Université Catholique
de Louvain, Brussels, Belgium

Hidekazu Nakai

Division of Cardiovascular Surgery, Department of Surgery,
Kobe University Graduate School of Medicine, Kobe, Japan

Yoshikatsu Nomura

Division of Cardiovascular Surgery, Department of Surgery,
Kobe University Graduate School of Medicine, Kobe, Japan

Taimi Ohara

Division of Cardiovascular Surgery, Department of Surgery,
Kobe University Graduate School of Medicine, Kobe, Japan

Kenji Okada

Division of Cardiovascular Surgery, Department of Surgery,
Kobe University Graduate School of Medicine, Kobe, Japan

Yutaka Okita

Division of Cardiovascular Surgery, Department of Surgery,
Kobe University Graduate School of Medicine, Kobe, Japan

Atsushi Omura

Division of Cardiovascular Surgery, Department of Surgery,
Kobe University Graduate School of Medicine, Kobe, Japan

Robert M. Osterday

Department of Surgery, Division of Cardiac Surgery,
University of Cincinnati Medical Center, Cincinnati, Ohio,
USA

René Horsleben Petersen

Department of Cardiothoracic Surgery, Copenhagen
University Hospital, Rigshospitalet, Copenhagen, Denmark

Gabriele Piffaretti

Section of Vascular Surgery, Department of Surgery and
Morphological Sciences, Circolo University Hospital,
University of Insubria School of Medicine, Varese, Italy

Vincenzo Rampoldi

Thoracic Aortic Research Center, Cardiovascular Surgery,
Policlinico San Donato IRCCS, Milan, Italy

Jason O. Robertson

Division of Cardiothoracic Surgery, Department of
Surgery, Washington University School of Medicine,
Barnes-Jewish Hospital, St. Louis, Missouri, USA

Valerie W. Rusch

Memorial Sloan-Kettering Cancer Center, Cornell
University Medical College, New York

Lindsey L. Saint

Division of Cardiothoracic Surgery, Department of
Surgery, Washington University School of Medicine,
Barnes-Jewish Hospital, St. Louis, Missouri, USA

Toshihito Sakamoto

Division of Cardiovascular Surgery, Department of Surgery,
Kobe University Graduate School of Medicine, Kobe, Japan

Sara Segreti

Thoracic Aortic Research Center, Cardiovascular Surgery,
Policlinico San Donato IRCCS, Milan, Italy

Tomonori Shirasaka

Division of Cardiovascular Surgery, Department of Surgery,
Kobe University Graduate School of Medicine, Kobe, Japan

Li-Zhong Sun

Department of Cardiovascular Surgery, Beijing Anzhen
Hospital, Beijing Aortic Disease Center, Capital Medical
University, Beijing, China

Simon H. Sündermann

Division of Cardiovascular Surgery, University Hospital
Zurich, Zurich, Switzerland

Rei Tanioka

Division of Cardiovascular Surgery, Department of Surgery,
Kobe Graduate School of Medicine, Kobe, Japan

Vincenzo Tarzia

Division of Cardiac Surgery, Department of Cardiology,
Thoracic and Vascular Sciences, University Hospital of
Padova, Padova, Italy

Gianluca Torregrossa

Department of Cardiothoracic Surgery, Mount Sinai
Health System, New York, USA

Santi Trimarchi

Thoracic Aortic Research Center, Cardiovascular Surgery,
Policlinico San Donato IRCCS, Milan, Italy

Scott A. Weldon

Division of Cardiothoracic Surgery, Michael E. DeBakey
Department of Surgery, Baylor College of Medicine;
Department of Cardiovascular Surgery, The Texas Heart
Institute at St. Luke's Episcopal Hospital, Houston, Texas,
USA

Y. Joseph Woo

Department of Cardiothoracic Surgery, Stanford University
School of Medicine, Stanford, California, USA

Katsuaki Yamanaka

Division of Cardiovascular Surgery, Department of Surgery,
Kobe Graduate School of Medicine, Kobe, Japan

Katsuhiro Yamanaka

Division of Cardiovascular Surgery, Department of Surgery,
Kobe University Graduate School of Medicine, Kobe, Japan

Tristan D. Yan

The Collaborative Research (CORE) Group,
Macquarie University, Sydney, Australia; Department of
Cardiothoracic Surgery, Royal Prince Alfred Hospital,
University of Sydney, Sydney, Australia

Jun Zheng

Department of Cardiovascular Surgery, Beijing Anzhen
Hospital, Beijing Aortic Disease Center, Capital Medical
University, Beijing, China

Jun-Ming Zhu

Department of Cardiovascular Surgery, Beijing Anzhen
Hospital, Beijing Aortic Disease Center, Capital Medical
University, Beijing, China

Bulat A. Ziganshin

Aortic Institute at Yale-New Haven, Yale University School
of Medicine, New Haven, Connecticut, USA; Department
of Surgical Diseases # 2, Kazan State Medical University,
Kazan, Russia

Fabio Zucchetta

Division of Cardiac Surgery, Department of Cardiology,
Thoracic and Vascular Sciences, University Hospital of
Padova, Padova, Italy

Illustrator

Beth Croce

Executive Typesetting Editor

Chuyuan Xie

By nature, surgeons are creative people; strongly visual with great attention to accuracy and detail. While these attributes make them gifted operators, it's also precisely why illustration is such an excellent medium, with which to communicate surgical techniques. Good art will draw the viewer in and bridges language issues. Where photographs may flatten vital variations in depth of field and limit the view of landmarks, well-crafted illustrations step in to tell the entirety of the story.

All the figures in this book have been meticulously drawn by Beth Croce. Beth pursued a bio-artistic career through her postgraduate Art as Applied to Medicine program at the Johns Hopkins Medical School in Baltimore, USA. She has been the primary illustrator for several key surgical texts, including preparing over 500 illustrations for 'Ischemic Heart Disease: Surgical Management', a comprehensive textbook that provides detailed up-to-date coverage for cardiac surgeons. By closely collaborating with surgeons and anatomists, Beth's illustrations combine anatomic accuracy with clinical significance to reflect the most pertinent and realistic surgical details. As the Annals of Cardiothoracic Surgery's chief medical illustrator, Beth's attention to detail has drawn praise from contributors and readers alike.

In this book of 'Art of Operative Techniques', we have put together a collection of illustrative articles to detail the critical steps in contemporary cardiothoracic surgical procedures. We hope that you will find this book to be informative and educational. I would like to express my deep appreciation to all contributors for their expertise and knowledge, which has enabled us to put together a seminal piece of work. I hope you enjoy appreciating the elegance and the art in our amazing specialty.

Tristan D. Yan, BSc. MBBS. MS. MD. Ph.D. FRACS.

Professor of Cardiovascular and Thoracic Surgery
Macquarie University, Sydney, Australia

Clinical Professor of Surgery, University of Sydney,
Royal Prince Alfred and Sydney Adventist Hospitals
Sydney, Australia

Table of Contents

Preface

i Tristan D. Yan

Cardiac Surgery

- 1 **Harvesting the radial artery**
Arie Blitz, Robert M. Osterday, Richard F. Brodman
- 11 **The art of arterial revascularization—total arterial revascularization in patients with triple vessel coronary artery disease**
Brian F. Buxton, Philip A. Hayward
- 20 **Mitral valve repair for ischemic mitral regurgitation**
Jaban Mobeali, Frederick Y. Chen
- 26 **The butterfly technique**
Tobru Asai
- 32 **Alternative approaches for mitral valve repair**
Andrew B. Goldstone, Y. Joseph Woo
- 37 **How to perform valve sparing reimplantation in a tricuspid aortic valve**
Laurent de Kerchove, Zabra Mosala Nezhad, Mumir Boodhwani, Gébrine El Khoury
- 44 **Minimally invasive valve sparing mitral valve repair—the loop technique—how we do it**
Stephan Jacobs, Simon H. Siindermann
- 51 **Minimally invasive aortic valve replacement: the “Miami Method”**
Joseph Lamelas
- 58 **Illustrated techniques for transapical aortic valve implantation**
Anson Cheung, Kevin M. Lichtenstein
- 67 **The Jarvik-2000 ventricular assist device implantation: how we do it**
Fabio Zucchetto, Vincenzo Tarzia, Tomaso Bottio, Gino Gerosa
- 74 **SynCardia: the total artificial heart**
Gianluca Torregrassa, Anelechi Anyanwu, Fabio Zucchetto, Gino Gerosa
- 82 **Illustrated techniques for performing the Cox-Maze IV procedure through a right mini-thoracotomy**
Jason O. Robertson, Lindsey L. Saint, Jeremy E. Leidenfrost, Ralph J. Damiano Jr

Aortic Surgery

- 94 **Mini-Bentall procedure**
Tristan D. Yan
- 103 **Surgical techniques of total arch replacement using selective antegrade cerebral perfusion**
Yutaka Okita, Kenji Okada, Atsushi Omura, Hiroya Kano, Hitoshi Minami, Takeshi Inoue, Toshibito Sakamoto, Shunsuke Miyabara, Tomonori Shirasaka, Katsubiro Yamanaka, Taimi Ohara, Yoshikatsu Nomura, Hidekazu Nakai
- 110 **Total aortic arch replacement: current approach using the trifurcated graft technique**
Scott A. LeMaire, Scott A. Weldon, Joseph S. Coselli
- 115 **Sun's procedure for complex aortic arch repair: total arch replacement using a tetrafurcate graft with stented elephant trunk implantation**
Wei-Guo Ma, Jun-Ming Zbu, Jun Zbeng, Yong-Min Liu, Bulat A. Ziganshin, John A. Elefteriades, Li-Zhong Sun
- 121 **Emergent treatment of aortic rupture in acute type B dissection**
Santi Trimarchi, Sara Segreti, Viviana Grassi, Chiara Lomazzi, Carlo de Vincentiis, Vincenzo Rampoldi
- 126 **Open fenestration for complicated acute aortic B dissection**
Santi Trimarchi, Sara Segreti, Viviana Grassi, Chiara Lomazzi, Marta Cova, Gabriele Piffaretti, Vincenzo Rampoldi
- 131 **Thoracoabdominal aortic aneurysm repair with a branched graft**
Kim I. de la Cruz, Scott A. LeMaire, Scott A. Weldon, Joseph S. Coselli
- 144 **Open reconstruction of thoracoabdominal aortic aneurysms**
Yutaka Okita, Atsushi Omura, Katsuaki Yamanaka, Takeshi Inoue, Hiroya Kano, Rei Tanioka, Hitoshi Minami, Toshibito Sakamoto, Shunsuke Miyabara, Tomonori Shirasaka, Taimi Ohara, Hidekazu Nakai, Kenji Okada

Thoracic Surgery

- 152 **Video-assisted thoracoscopic lobectomy using a standardized three-port anterior approach—The Copenhagen experience**
Henrik J. Hansen, René H. Petersen
- 159 **Surgical atlas of thoracoscopic lobectomy and segmentectomy**
Tristan D. Yan
- 168 **Video-assisted thoracoscopic microthymectomy**
Joel Dunning
- 174 **Video-assisted thoracoscopic thymectomy using 5-mm ports and carbon dioxide insufflation**
René Horsleben Petersen
- 179 **Extrapleural pneumonectomy and extended pleurectomy/decortication for malignant pleural mesothelioma: the Memorial Sloan-Kettering Cancer Center approach**
Valerie W. Rusch

Harvesting the radial artery

Arie Blitz¹, Robert M. Osterday¹, Richard F. Brodman²

¹Department of Surgery, Division of Cardiac Surgery, University of Cincinnati Medical Center, Cincinnati, Ohio, USA; ²Grace Point Lane, Mount Desert Island, Maine, USA

Introduction

The radial artery (RA) has emerged as an important arterial graft for coronary bypass surgery. Five-year patency rates in more recent studies are better than 85% (1). Key parameters influencing the long-term patency of the RA graft are appropriate patient selection, meticulous coronary target selection and scrupulous operative technique. In this article we review the steps in harvesting the RA via either an open or endoscopic approach. Prerequisites of a successful harvest include adherence to important anatomical landmarks, protection of the sensory innervation to the volar forearm, and meticulous handling of the RA branches (2). This discussion will focus on the features of the forearm anatomy that are most relevant to the surgeon. For a more complete discussion of forearm anatomy, the reader is referred to the more expansive discussion published previously by one of the authors (2). *Table 1* lists the abbreviations used in this article.

Operative techniques

For the surgeon harvesting the RA, the pertinent anatomy can be summarized by the following phrase: “two muscles, two nerves, and two branches (*Figures 1,2*)”. See *Table 2* for a listing of these anatomic structures. The two muscles are the brachioradialis muscle (BRM) and the flexor carpi radialis muscle (FCRM). These muscles, along with their interconnecting fascia, describe the crevice wherein lies the RA. The two nerves are the lateral antebrachial cutaneous nerve (LABCN) and the superficial radial nerve (SRN). These are the nerves most prone to injury during RA harvesting and knowledge of their course will minimize the risk of injury. The two branches, the recurrent radial artery (RRA) and the superficial palmar artery (SPA), define the proximal and distal limits of the RA harvest respectively. Further details regarding these anatomic features will be discussed below.

There are two basic approaches for harvesting the RA: the open approach and the endoscopic approach. Each of these will be described in turn. Please see *Table 3* for a summary outline of the alternative operative approaches,

dissection planes, and branch-handling techniques.

For all operative approaches, the arm is prepped circumferentially, draped, and secured to an arm board that is positioned at no more than 90 degrees with respect to the operative table. If both a mammary artery and a RA are being harvested, it is useful to simultaneously harvest each mammary artery along with the contralateral RA. If only one RA is harvested, usually the non-dominant arm is chosen.

A preoperative modified Allen’s test is conducted. In this test, the patient makes a clenched fist, and the radial and ulnar arteries are compressed firmly at the wrist by the examiner. While compression is maintained, the patient slowly opens the wrist and incompletely extends the fingers (hyperextension can produce a false positive result). When the ulnar artery is released, a hyperemic response extending to the thenar eminence and thumb within 5 seconds indicates adequate collateral circulation by the ulnar artery and non-dominance of the RA (3).

Other useful adjuncts for preoperative RA evaluation include duplex examination and pulse oximetry. In general, because of concern over vasospasm, we avoid RAs measuring less than 2 mm in diameter.

Open approach for radial artery harvest

A curvilinear skin incision, tailored to the edge of the

Table 1 Key abbreviations

Abbreviation	Term
LABCN	Lateral antebrachial cutaneous nerve
SRN	Superficial radial nerve
BRM	Brachioradialis muscle
FCRM	Flexor carpi radialis muscle
RA	Radial artery
RRA	Recurrent radial artery
SPA	Superficial palmar artery
ERAH	Endoscopic radial artery harvest
BTT	Blunt tip trocar

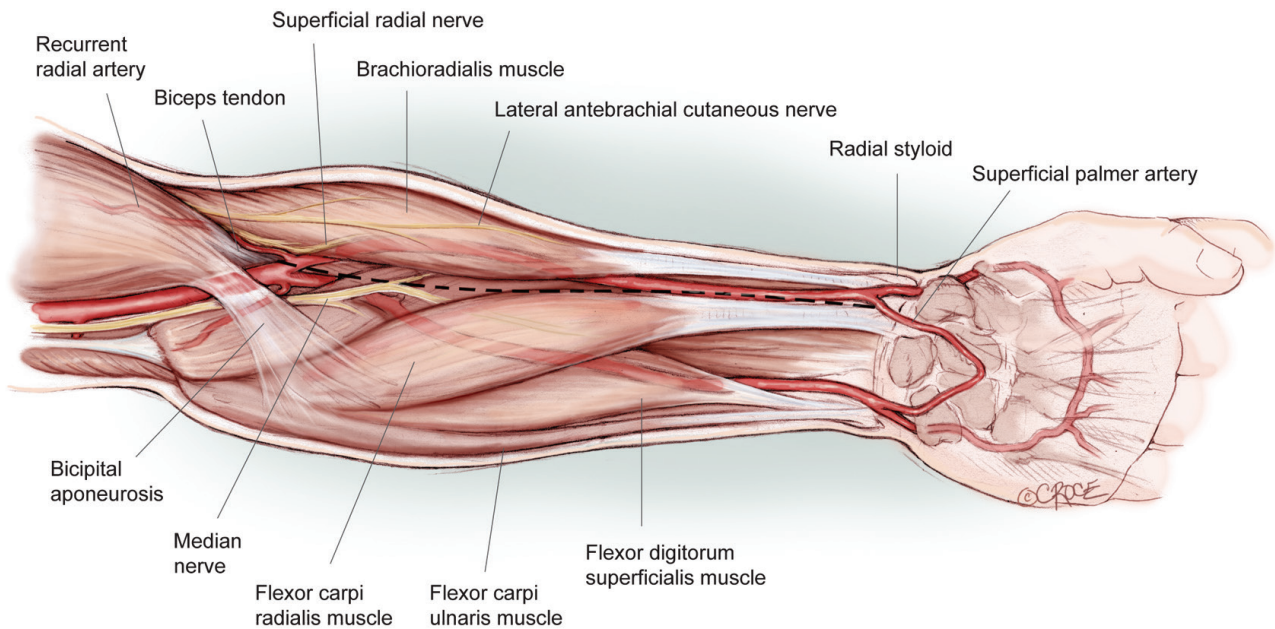


Figure 1 Anatomic landmarks and skin incision. The skin incision follows a curvilinear course over the medial edge of the brachioradialis muscle. The proximal extent of the incision starts just below the inverted “V” formed by the biceps tendon and the bicipital aponeurosis, which lies about a centimeter below the elbow crease. The distal extent of the incision ends approximately 1 cm proximal to the wrist crease, in between the tendon of the flexor carpi radialis and the radial styloid. There are six structures of paramount importance to the surgeon: the brachioradialis muscle, the flexor carpi radialis muscle, the recurrent radial artery, the superficial palmar artery, the superficial radial nerve and the lateral antebrachial cutaneous nerve.

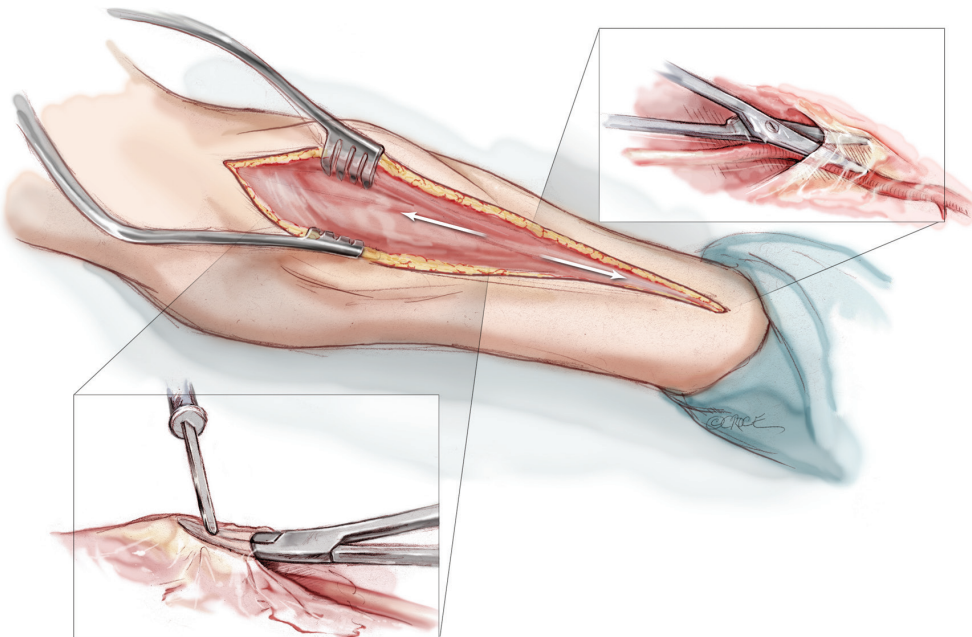


Figure 2 Incising BRM and FCRM fascia. The fascia overlying the RA throughout its course is incised. The more proximal fascia, lying between the BRM and the FCRM, is divided with electrocautery. The more distal fascia, where the RA becomes a more superficial structure, is divided with scissors so as to not injure the radial artery.

Table 2 Key anatomic structures: the rule of two's

Muscles & tendons	Nerves	RA branches
Brachioradialis	Lateral antebrachial cutaneous	Recurrent radial
Flexor carpi radialis	Superficial radial	Superficial palmar

Table 3 Summary of operative approaches, dissection planes, and debranching techniques

Approach	Dissection plane	Debranching technique
Open	Pedicled	Sharp dissection with clips
Endoscopic	Extr fascial	Electrocautery alone
	Skeletonized	Electrocautery with clips

brachioradialis muscle, extends from 1 cm distal to the elbow crease to 1 cm proximal to the wrist crease (*Figure 1*). Corroboration of the appropriate position of the skin incision can be obtained by palpating the radial pulse proximally and distally. Proximally, the radial pulse is best appreciated within the inverted V formed by the biceps tendon laterally and the bicipital aponeurosis medially. This inverted V also defines the site where the radial recurrent artery (RRA) branches off from the RA. Distally, the RA can be palpated between the radial styloid laterally and the tendon of the flexor carpi radialis medially.

Once through the skin, superficial veins are either retracted or divided between clips. Next, the fascia overlying the RA is incised as the RA emerges to become a subcutaneous structure from beneath the belly of the BRM in the mid-forearm (*Figure 2*). This will expose the RA and its venae comitantes lying in loose areolar tissue. The fascia is divided more proximally with electrocautery, separating the muscle bellies of the BRM and the FCRM. Distally, the fascia is divided with sharp scissors due to the close proximity of the underlying RA here.

There are two nerves that are of consequence during the RA harvest: the LABCN and the SRN (*Figure 3*). These nerves provide cutaneous innervation to the volar forearm, portions of the thumb and the dorsum of the hand (2). The LABCN, a branch of the musculocutaneous nerve, lies within the superficial fascia overlying the BRM, and will retract from the field of view once the intervening fascia between the BRM and the FCRM is divided. It frequently travels in proximity to the cephalic vein (4). The SRN travels lateral and in close proximity to the RA. With the appropriate amount of tissue retraction—just enough to

visualize the course of the RA—both of these nerves are well protected and less likely to be injured. In fact, the nerves are often not seen at all, a desirable state of affairs.

Once the plane of the RA pedicle is entered, the dissection is carried proximally and then distally. We prefer harvesting the vessel as a pedicle, along with its venae comitantes. However, others recommend either skeletonization (5) or extr fascial harvesting (6). See *Table 3*. We feel that the pedicle technique minimizes manipulation of the RA, decreases operative time, and facilitates RA dissection. Regardless of the dissection technique chosen, the RA should be handled with great care at all times, if it is handled at all.

A useful maneuver once the RA is exposed is to soak a sponge in papaverine solution (3 mg papaverine per mL of saline) and lay it over the portion of the RA that is not being addressed at any point in time. For example, during dissection of the proximal RA, the sponge should lie over the distal RA, and vice versa. Periodically, additional papaverine solution is added to the sponge so as to adequately bathe the RA.

Key internal landmarks for the proximal and distal limits of RA harvesting are two of its major branches (*Figure 3*). Proximally, the RA should be harvested to just below the takeoff of the RRA. This will not only preserve the collateral network communicating with the RRA, but will also keep the surgeon in safe territory. Important structures vulnerable to injury reside proximal to the RRA, including the ulnar artery, brachial artery and median nerve. Distally, the artery should be harvested proximal to the takeoff of the superficial palmar artery (SPA). This preserves the radial- ulnar collateral network to the hand. While the RRA can be seen within the confines of the incision, the SPA is usually

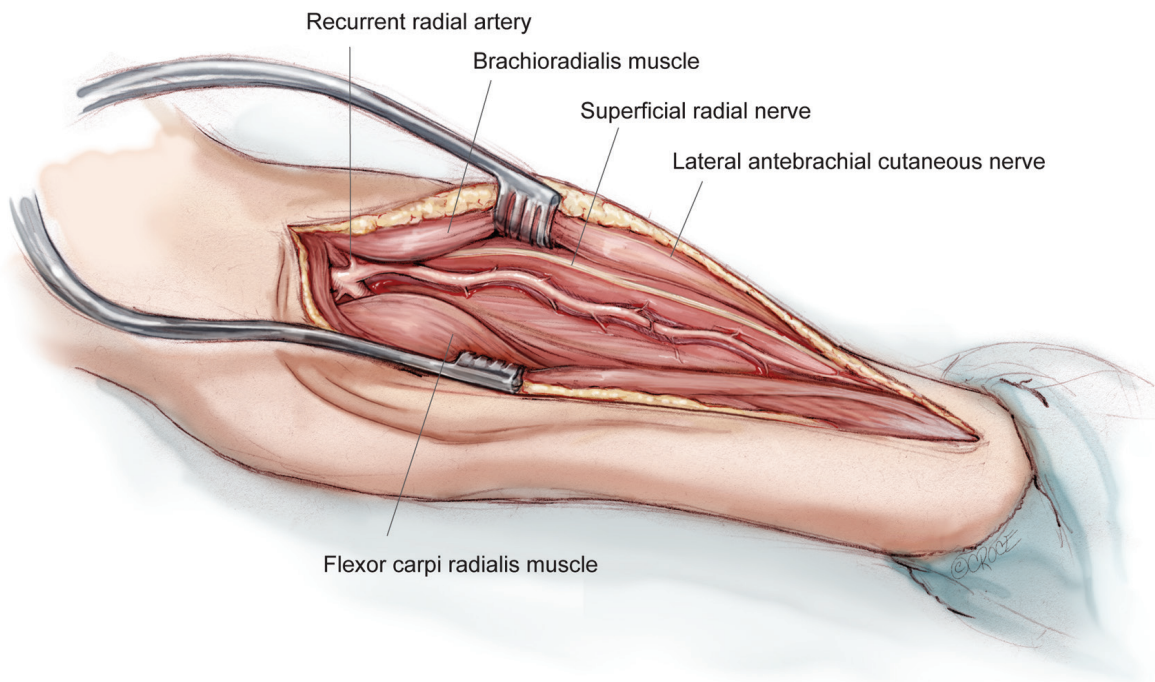


Figure 3 Relationships of the radial artery. This figure illustrates the relevant anatomy once the fascia overlying the RA pedicle is divided. The pertinent anatomy can be summarized by the phrase, “Two muscles, two nerves, and two branches”. The two muscles are the brachioradialis muscle and flexor carpi radialis muscle. The two nerves are the lateral antebrachial cutaneous nerve and the superficial radial nerve. The two branches of the RA are the RRA and the superficial palmar artery. The superficial palmar artery is hidden from view in this illustration, as the surgeon should not encounter this vessel within the confines of the appropriately placed skin incision.

hidden from view distally. Generally speaking, if a shorter segment of RA is needed, the more proximal vessel segment is chosen due to its less developed muscularis layer. This will minimize the effect of vasospasm.

The RA gives off numerous intervening perforating branches that supply the forearm and hand. Most of the branches arise from the dorsal hemicircumference of the RA; in fact, branches are almost never seen arising anteriorly. Proximally under the belly of the BR muscle, an average of just over 4 branches is found. Distally, where the RA is a subcutaneous structure, more than twice as many branches are encountered and are most numerous near the wrist. Besides being more abundant, the more distal branches are shorter and more delicate than the more proximal branches, making them more challenging to dissect out and transect (7).

A variety of alternative techniques are available to manage these RA branches. These techniques are listed in *Table 3* and include (I) electrocautery alone; (II) sharp dissection with clips; (III) a combination of electrocautery and clips and (IV) ultrasonic dissection. We prefer to use

a combination of electrocautery and clips for the rapidity with which the vessel can be harvested and reliability of controlling larger branches. With this technique, a clip is used to secure the branch abutting one of the veins, and electrocautery is used to divide the vessel distally towards the tissue (*Figure 4*). Despite concerns about heat generation from the electrocautery, injury can be minimized by keeping the electrocautery current low (20 Watts). A recent study from the Texas Heart Institute revealed that, properly harvested, the RA does not sustain any intimal injury with the electrocautery at a low setting, and graft flows are actually higher in comparison to those harvested with the sharp dissection technique (8). Regardless, the jury is still out as to which technique, if any, results in better preservation of the RA architecture and hence greater long-term patency of the graft.

Importantly, the RA should never be grasped directly; its venae comitantes provide a convenient and safe grasping surface when handled prudently (*Figure 4*). Another practical method for retracting the RA is to gently roll it with a papaverine-soaked gauze to one side while managing

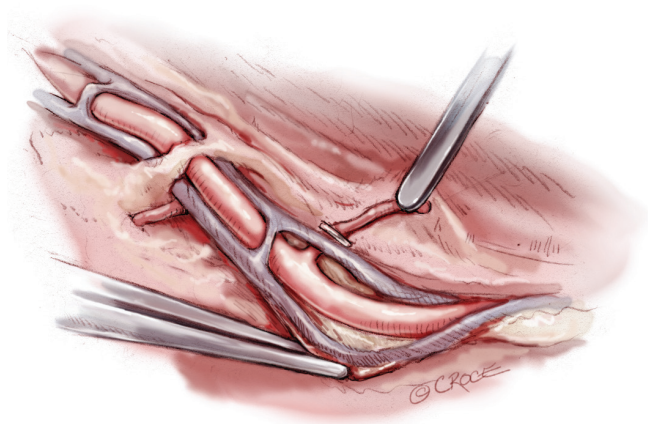


Figure 4 Debranching. Once each branch is gently dissected out, a clip is applied flush with the ipsilateral vena comitans and cautery is applied as distally as possible on the branch so as to protect the RA. The RA is treated with a “no-touch” technique.

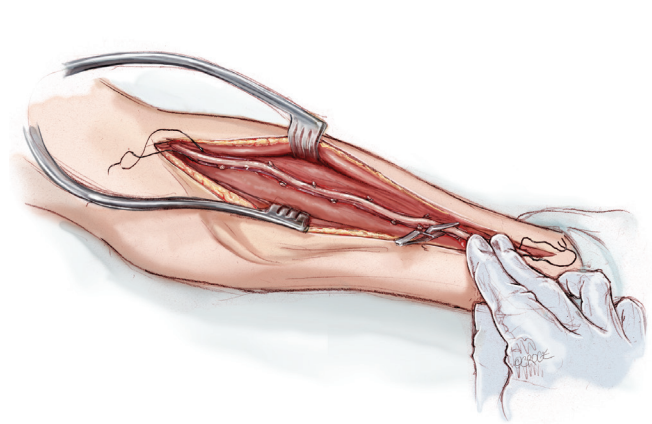


Figure 5 Confirmation of retrograde pulsation. Once the RA is completely mobilized, a bulldog clamp is placed on the mid to distal artery, and final confirmation of a retrograde radial pulse is obtained distal to the clamp before sacrificing the RA.

Table 4 Contents of radial artery solution

250 mL Normosol R
2,500 units of heparin
60 mL of patient's blood
60 mg of papaverine

its branches. Critically, the RA should never be stretched to improve exposure, as stretching causes separation of the intima from the vessel wall.

Once the vessel's branches have been transected and the RA has been mobilized, the RA is atraumatically clamped in its distal portion to confirm a retrograde pulsation from the ulnar collateralization (*Figure 5*). After adequate collateral flow is confirmed, the vessel is ligated with a heavy silk tie distally and transected. The proximal vessel is similarly ligated and transected. The proximal RA is carefully cannulated with a 2 mm flexible olive-tip cannula, and the vessel is flushed with vasodilating solution under minimal pressure. The contents of this solution at our institution are listed in *Table 4*. The vessel is then soaked in the same solution until later use. Subsequently, when cardioplegia is initiated, the RA is connected to the cardioplegia apparatus and cardioplegia is delivered down the graft to detect any side branches that require additional clips.

Once the RA is removed from the arm, the arm is closed in its most superficial layers only. The deeper fascial layers are left unapproximated to minimize the risk of compartment syndrome and nerve injury. The subcutaneous

layers are closed as per convention.

Endoscopic technique for radial artery harvest

Endoscopic Radial Artery Harvest (ERAH) has been rising in popularity in recent years as a result of increasing familiarity with endoscopic vein harvesting and expanding use of the RA as a conduit. The specific ERAH technology chosen depends on the experience of the harvester and the individual institution. Prepping and positioning are the same as for the open technique.

There are two categories of systems for ERAH: the open system and the sealed system. The open system uses a specialized retractor for endoscopic exposure, but CO₂ is not delivered in a pressurized fashion, as the system remains open to the atmosphere. The closed system delivers CO₂ insufflation at a controlled pressure to aid visualization; the wound is sealed at the scope entry site with a specialized balloon. The authors are familiar with the latter technique using the Vasoview Endoscopic Vessel Harvesting System (Maquet) and this is the approach that will be described below (*Figures 6,7*).

A 3 cm longitudinal incision is made over the RA, ending 1 cm proximal to the wrist flexion crease. The RA and its venae comitantes are identified under direct vision (*Figure 8*). The fascia overlying the pedicle is divided with scissors as far proximally as possible under direct vision to create room for scope entry.

A sterile tourniquet is then applied to the upper arm,

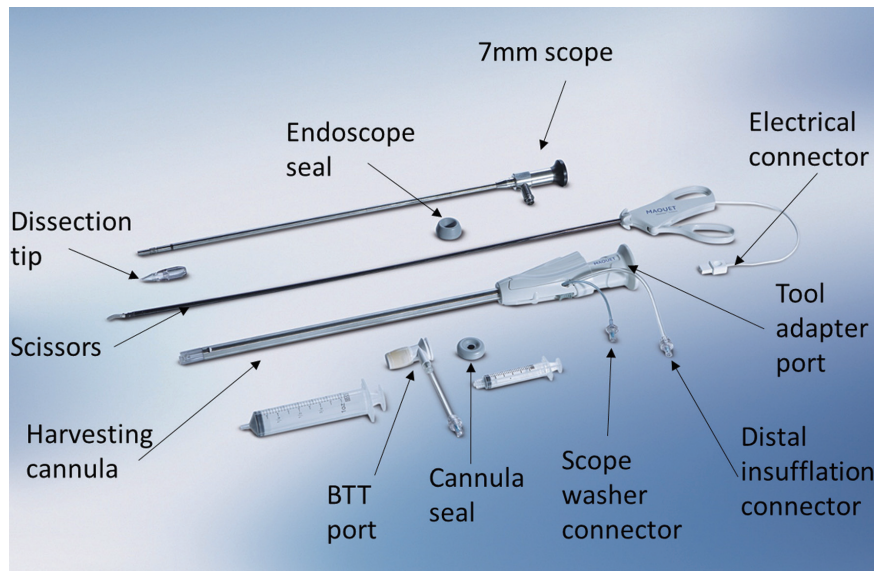


Figure 6 Components of the Vasoview System. Components include the 7 mm scope with the dissection tip, the BTT port with an inflatable balloon, the harvesting cannula and bipolar scissors, along with seals, adapters and connectors. In the first stage of the RA harvest, the 7 mm scope, dissection tip and BTT port are used to dissect out the radial pedicle. In the second stage of the harvest, the 7 mm scope, the harvesting cannula and bipolar scissors are used to manage the branches (Here, the Vasoview 7 System is shown; other generations vary to some degree) (Photo courtesy of Maquet).

and the entire arm is wrapped tightly with a sterile Esmark bandage from its distal to proximal end (*Figure 9*). The sterile tourniquet is inflated to 75 mmHg above the systolic pressure (not to exceed 200 mmHg), and the Esmark removed. This will create a bloodless field. It is important to complete the open distal RA exposure prior to tourniquet application to minimize ischemic time. The start and stop times of tourniquet inflation should be noted and recorded, and every effort expended to keep its duration under 60 minutes.

The components of the Vasoview System can be seen in *Figures 6,7*. *Figure 6* depicts the complete component set for one of the more recent generations of the Vasoview System. *Figure 7* shows the Harvest cannula inserted into the blunt-tipped trocar (BTT) port *in situ* in a human arm. To commence the dissection with the Vasoview System, the clear bullet tipped dissector is threaded on to the scope tip. The blunt-tipped trocar (BTT) is then pre-loaded onto the scope, and the dissector is advanced anteriorly over the RA. Once the dissector is advanced approximately 3 cm, the BTT is slid down over the scope into the incision. The BTT contains a balloon that is inflated with sequential 5 cc aliquots of air (up to 25 cc) until a seal is created (*Figure 7*). The gas line is connected to the insufflation port, and CO₂ is insufflated at a rate of 3-5 L/min under a pressure

of 10-12 mmHg. The dissector is then used to bluntly dissect the RA and its venae comitantes as a pedicle from the surrounding tissue. The dissector is advanced anteriorly (*Figure 10*), withdrawn, then advanced posteriorly (*Figure 11*), and withdrawn once again. Significantly, whenever the dissector is advanced, actual contact with the RA itself should be avoided if possible; accordingly, the dissector is biased slightly to either side of the RA during advancement, so that any contact made is with the venae comitantes instead. In addition, the scope should be slightly torqued away from the pedicle, transmitting any forces to the surrounding tissue. Finally, as the dissection proceeds and branches are encountered, tissue should be judiciously cleared around the branches and the branches themselves should be minimally displaced. The dissector advancement should be up to the level of the RRA or the venous plexus in the antecubital fossa, depending on the scope's relative position with respect to the RA.

Once the dissection is complete, the scope is withdrawn, the dissection tip is removed from the scope and the scope is then inserted into the harvest cannula. The harvest cannula contains several ports through which different tools can be inserted and advanced (*Figures 6,7*). Via the harvest cannula, the cautery instrument can be introduced to perform a fasciotomy of the BRM-FCRM fascia

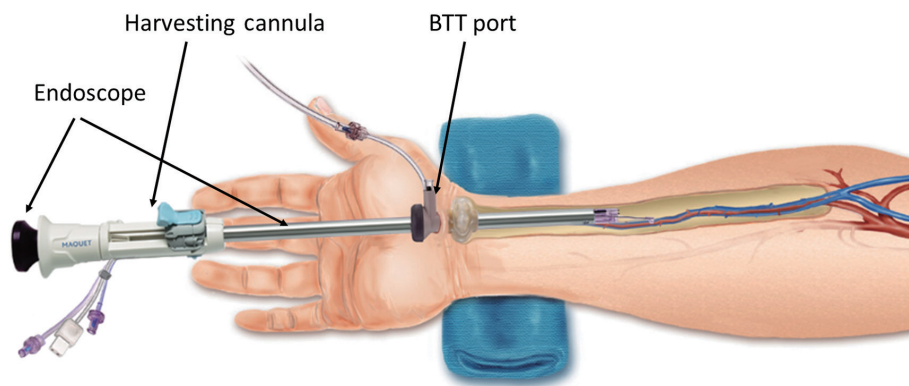


Figure 7 *In situ* display of the Vasoview System. This illustration shows the most of the major components of the Vasoview System as it is being used for harvesting the RA. These components include the 7 mm endoscope, the harvesting cannula and the BTT port (Illustration courtesy of Maquet).

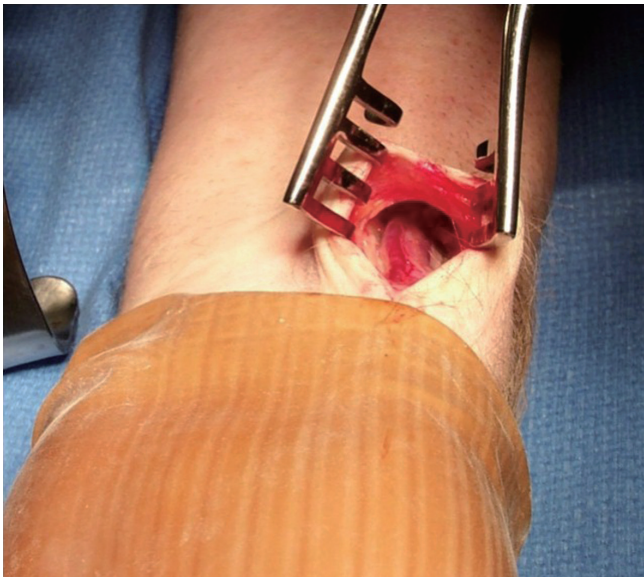

Figure 8 Exposure of RA for endoscopic RA harvest. A 3-cm incision is carried out, ending 1 cm proximal to the wrist crease, and parallel to the RA. Dissection is carried down through the fascia to expose the RA pedicle (Photo courtesy of Maquet).

(*Figure 12*). This will create space to facilitate the harvest and to reduce the risk of compartment syndrome developing in the forearm postoperatively. A cautery instrument is then used to divide the side branches of the RA, while a vessel cradle keeps the RA displaced 2.5 cm away from the cautery (*Figure 13*). The different generations of the Vasoview System offer an assortment of dividing/ligating technologies, including bipolar scissors, bipolar ligating

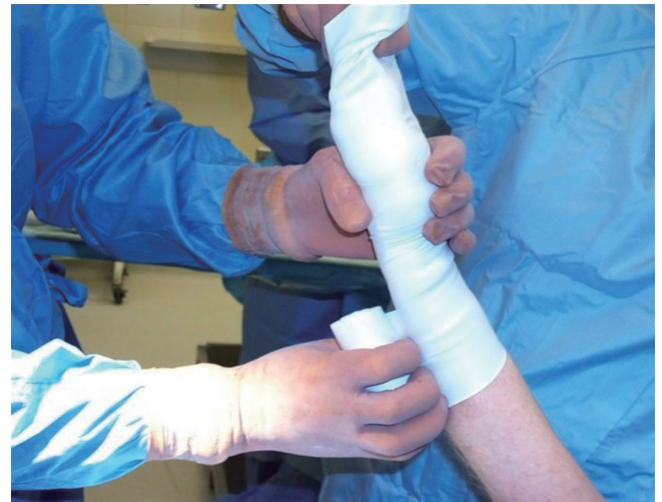

Figure 9 Tourniquet and esmark being applied. A sterile tourniquet is applied to the upper arm, and the entire arm is wrapped tightly with a sterile Esmark bandage from distal to proximal. The sterile tourniquet is inflated to 75 mmHg above the systolic pressure (not to exceed 200 mmHg), and the Esmark is removed (Photo courtesy of Maquet).

bisector tool and direct current cut-and-seal ligating graspers. [One should refer to the specific Instructions for Use (IFU) for each device to learn the particulars of each]. Importantly, minimal stretching or torquing of the pedicle should be applied when addressing the branches so as to not incur intimal injury to the RA. Once all the side branches are divided from the RA, the cradle is slid gently up and down the pedicle to confirm completeness of debranching

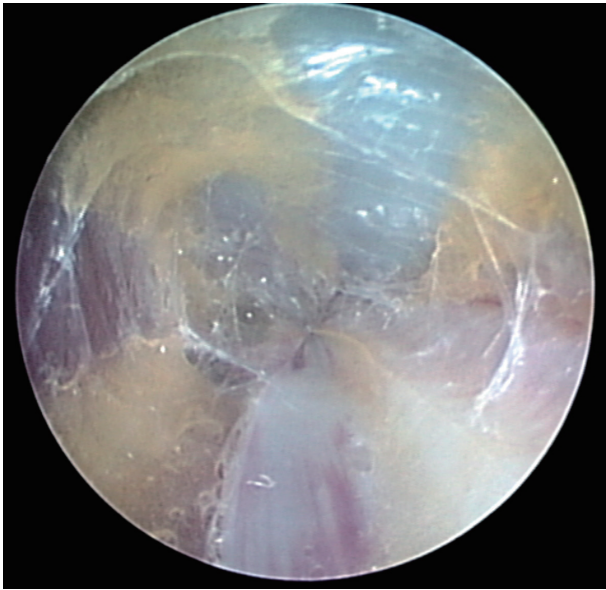

Figure 10 View from within the scope during anterior advancement. The scope is being advanced anterior and to the left over the RA, which can be seen in the 5 o'clock position, along with its venae comitantes at the 4 and 6 o'clock positions. Note that the scope is biased over one of the veins to minimize contact with the RA itself (Photo courtesy of Maquet).

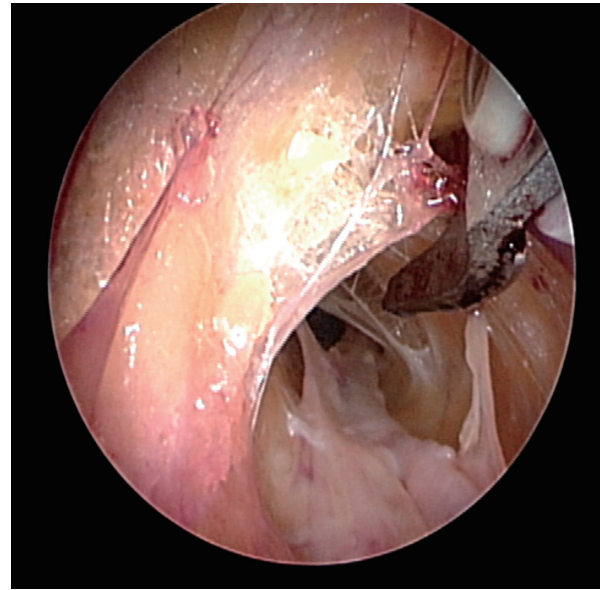


Figure 12 Fasciotomy of the BRM-FCRM fascia. A fasciotomy is being performed via the harvesting cannula with a cauterizing tool at the 2 o'clock position. The RA can be seen at the 5 o'clock position (Photo courtesy of Maquet).

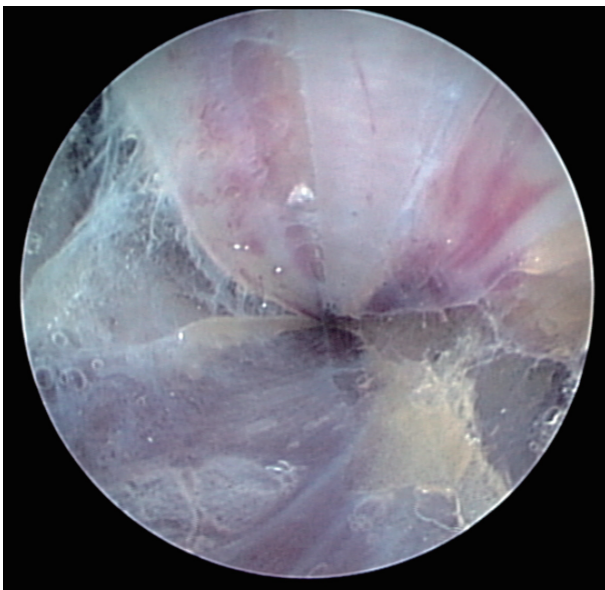

Figure 11 View from within the scope during posterior advancement. The scope is being advanced posterior and to the left under the RA, which can be seen in the 1 o'clock position, along with its venae comitantes at the 11 and 2 o'clock positions. Note again that the scope is biased over one of the veins to minimize contact with the RA itself (Photo courtesy of Maquet).

(*Figure 14*).

A 1 cm incision is made externally at the proximal end of the harvest tunnel, 1 cm distal to the antecubital crease. Prior to making the incision, its appropriate location is verified by pushing down on the overlying skin while visualizing within the tunnel with the scope. After the incision is made, a hemostat is used to retrieve the RA pedicle (*Figure 15*), bring it to skin level, ligate the proximal stump, and divide the radial graft from the stump. The endoscope is then used to withdraw the RA from the harvest tunnel using the cradle, and the distal end is similarly ligated and divided. The radial graft is then cannulated as previously described, and flushed with solution. To ensure hemostasis of the tunnel, the endoscope is reintroduced, the tourniquet is released, and the tunnel is inspected for potential bleeders that are then addressed. The incisions are then closed, sterile dressings are applied, and an ace bandage loosely wrapped around the forearm.

Comments

The RA has been assuming an increasingly prominent role in arterial revascularization, often being used when additional arterial conduits are desired in conjunction

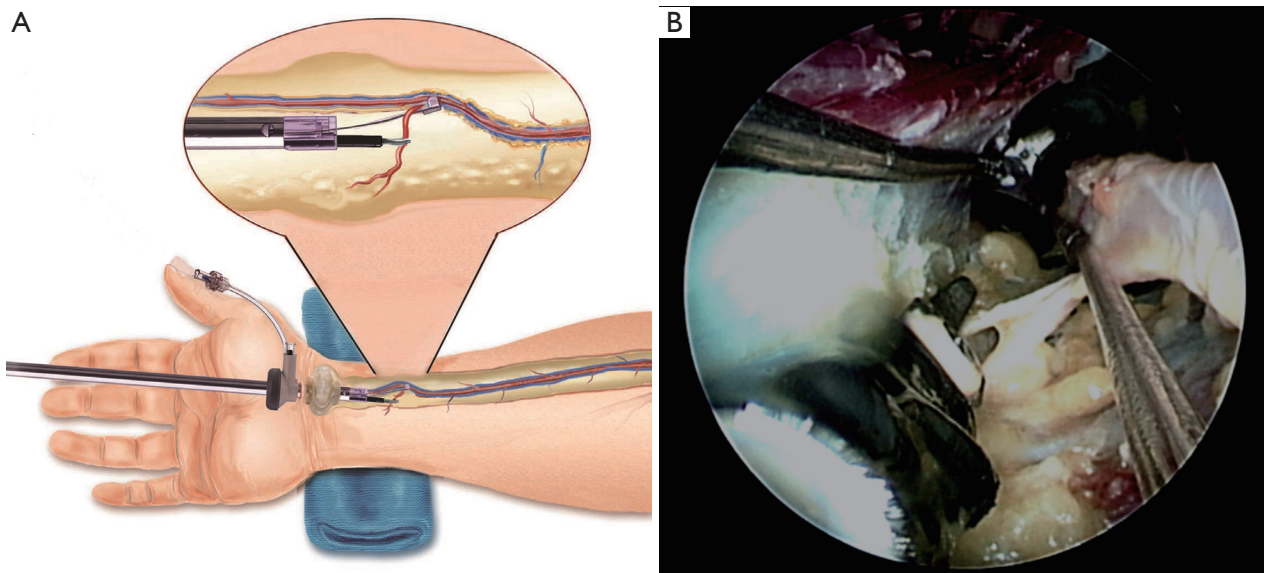


Figure 13 Debranching via the Harvesting Cannula. A branch of the RA is divided with the use of a cautery tool and the vessel cradle in both the illustration (A) and the endoscopic photo (B). In the latter, the cautery tool is seen at the 7 o'clock position. A vessel cradle is seen from the 11 o'clock to the 2 o'clock position and is retracting the RA away from the cautery tool (Photo courtesy of Maquet).

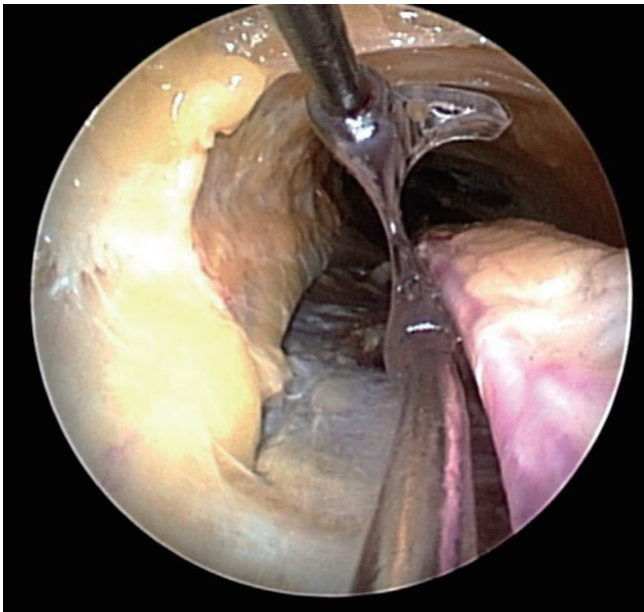


Figure 14 Running the pedicle with the vessel cradle. Upon reaching the distal end of the pedicle, the vessel cradle is used to run the pedicle and ensure no branches have been missed (Photo courtesy of Maquet).

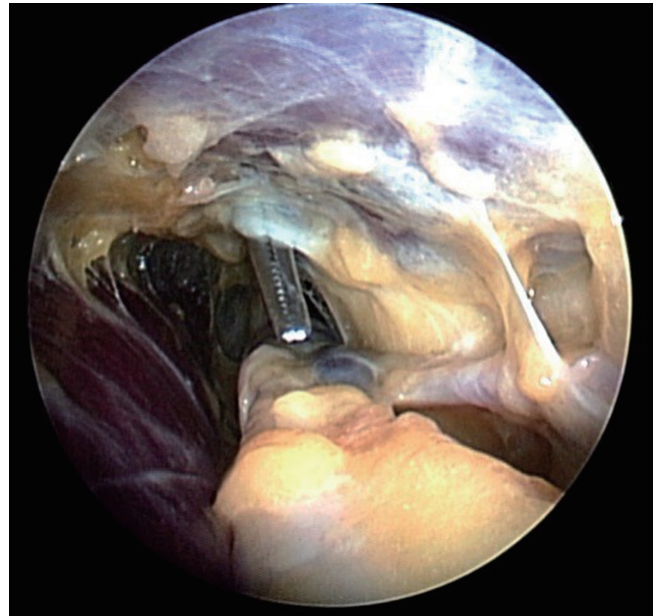


Figure 15 Retrieval of RA. After the incision in the skin over the antecubital space is complete, a mosquito clamp is placed via the incision and—under endoscopic vision—used to grasp the radial pedicle 5-7 mm distal to the RRA. The pedicle is gingerly withdrawn through the incision, the RA pedicle is divided just distal to the clamp, and the vessel beneath the clamp is ligated (Photo courtesy of Maquet).

with the internal mammary arteries. The surgical armamentarium for harvesting is multifold, including (I) either an open or endoscopic operative approach; (II) alternative dissection planes and (III) alternative methods of handling the RA branches. In this article we present both our open and endoscopic approaches. Although much work still needs to be done to fully elucidate which approaches or techniques—if any—are superior, the most important universal dictum is to pay great respect to the RA's propensity for vasospasm. A “no touch” technique will ensure the optimal quality and longevity of the RA conduit, whatever harvesting methodology is chosen.

Acknowledgements

We would like to thank Maquet Getinge Group for providing photographs and illustrations for the endoscopic harvesting portion of the manuscript.

Disclosure: The authors declare no conflict of interest.

References

1. Deb S, Cohen EA, Singh SK, et al. Radial artery and saphenous vein patency more than 5 years after coronary artery bypass surgery: results from RAPS (Radial Artery Patency Study). *J Am Coll Cardiol* 2012;60:28-35.
2. Reyes AT, Frame R, Brodman RF. Technique for harvesting the radial artery as a coronary artery bypass graft. *Ann Thorac Surg* 1995;59:118-26.
3. Conklin LD, Ferguson ER, Reardon MJ. The technical aspects of radial artery harvesting. *Tex Heart Inst J* 2001;28:129-31.
4. Beldner S, Zlotolow DA, Melone CP Jr, et al. Anatomy of the lateral antebrachial cutaneous and superficial radial nerves in the forearm: a cadaveric and clinical study. *J Hand Surg Am* 2005;30:1226-30.
5. Taggart DP, Mathur MN, Ahmad I. Skeletonization of the radial artery: advantages over the pedicled technique. *Ann Thorac Surg* 2001;72:298-9.
6. Sajja LR, Mannam G, Sompalli S. Extradissectionally harvested radial artery in CABG: technique of harvest, complications, and mid-term angiographic patency. *J Card Surg* 2005;20:440-8.
7. Strauch B. YH, Chen ZW, Liebling R. Forearm Region. *Atlas of Microvascular Surgery: Anatomy and Operative Approaches*. New York: Thieme Medical. 1993:44-83.
8. Marzban M, Arya R, Mandegar MH, et al. Sharp dissection versus electrocautery for radial artery harvesting. *Tex Heart Inst J* 2006;33:9-13.

Cite this article as: Blitz A, Osterday RM, Brodman RF. Harvesting the radial artery. *Ann Cardiothorac Surg* 2013;2(4):533-542. doi: 10.3978/j.issn.2225-319X.2013.07.10

The art of arterial revascularization—total arterial revascularization in patients with triple vessel coronary artery disease

Brian F. Buxton, Philip A. Hayward

Department of Cardiac Surgery, Austin Hospital, Heidelberg, Melbourne, Victoria, Australia

Introduction

Since the first series of left internal thoracic artery (LITA) grafts published by Konstantinov (1), the LITA has become the standard treatment for coronary artery bypass grafting (CABG). Barner reported the use of bilateral ITA (BITA) for coronary bypass almost 30 years ago, but was not widely accepted initially (2,3). Tector and others are credited with introducing composite arterial grafting using free ITAs, sequential grafts, T-grafts and combinations for the treatment of multi-vessel coronary artery disease (CAD) (4-7). Many observational studies have suggested that arterial grafting is superior to saphenous vein (SV) techniques, but at present, BITA or multiple arterial grafting have not proved popular for many reasons, mainly because of perceived technical complexity or fear of serious complications such as sternal infection. Few units have reported a BITA grafting rate greater than 10% (8). Survival after bilateral versus single internal thoracic artery (ITA) grafting is being assessed by the randomized controlled Arterial Revascularisation Trial (ART) of Taggart *et al.* (9).

Nonetheless, in patients with multi-vessel CAD, ongoing SV graft failures have led some surgeons to adopt a policy of extensive or total arterial revascularization using one or both internal mammary arteries and alternative conduits such as the radial artery (RA) (10) or right gastroepiploic arterial grafts (11). Arterial grafts have the advantage of durability and may have a protective effect by reducing the progression of native CAD in grafted vessels (12). Multiple arterial grafting may thereby improve survival in patients receiving total arterial revascularization. Beginning in 1995, total arterial revascularization has been the operation of choice in our unit for treatment of three-vessel CAD, with various iterations or graft configurations in use.

Operative techniques

Conduit planning in patients with triple-vessel disease (TVD)

The success of a surgical procedure is related to careful

assessment and planning. All patients should be considered for multiple arterial grafts. Although the BITA rate is about 35% in our unit there are a number of recognized relative contraindications, including obesity (BMI >35), severe airways disease, diabetes, radiotherapy, or immunosuppression. Recent data suggest that the risks of the latter are markedly reduced by the use of skeletonization (13). The RA is our conduit of choice after the ITAs. Most patients with TVD require three major conduits; combined with ITA conduits, our choice is to use the RA rather than a SVG for the supplementary bypass grafts. There are contraindications to RA harvesting: 5% of patients have an abnormal ulnar collateral flow as judged by the Allen test (a return of blood to the ischemic hand in greater than 10 seconds after release of the ulnar pulse), while palpable or visible calcification during harvesting pose potential problems in the elderly. RA trauma following recent cardiac catheterization is a more recent concern, and limited data and anecdotal experience suggests these conduits should be avoided. Patients receiving or likely to receive dialysis may require the preservation of RAs for future fistulae as lack of vascular access remains a major cause of death in long-term dialysis patients.

Aside from the availability of conduits, other factors which may influence optimal planning are the severity of the target lesions and the decision to perform the procedure on- or off-pump. In lesions with less than 70% stenosis in the left circulation, and probably 90% in a dominant right coronary system, competitive flow is a risk factor for arterial graft failure, and lesser lesions may be more safely grafted with a SV or left untouched. Moderate right coronary lesions (40-69%) have a lower rate of progression than often assumed and may reasonably remain ungrafted (14). The use of off-pump techniques favors arterial conduits, given several reports of poorer SVG patency after off-pump coronary artery bypass (OPCAB), and with anaortic OPCAB techniques being performed almost exclusively with multiple arterial grafts.

The management of isolated left main coronary artery

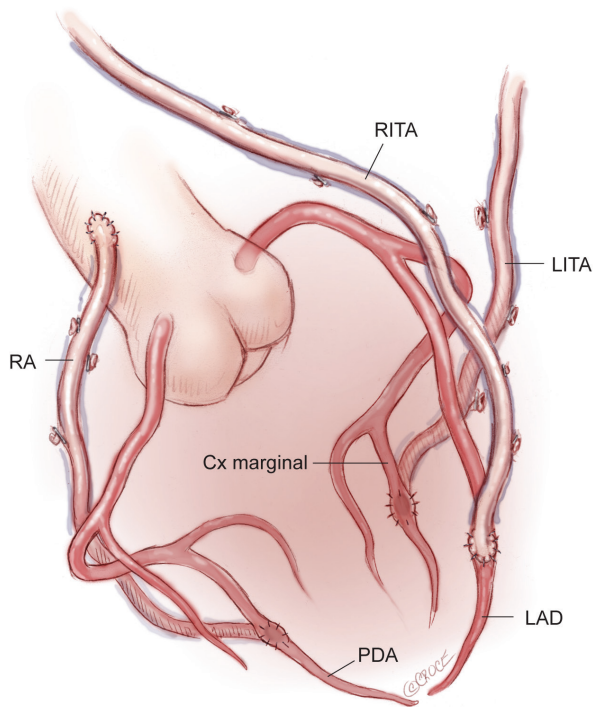


Figure 1 BITA grafts for triple vessel disease. RITA is grafted to the LAD coronary artery, while LITA passes laterally to the circumflex marginal branch. RA graft is sutured to the distal RCA. BITA, bilateral internal thoracic artery; LAD, left anterior descending artery; LITA, left internal thoracic artery; RA, radial artery; RCA, right coronary artery; RITA, right internal thoracic artery.

stenosis presents an interesting problem. Should two grafts be used when the disease affects the origin or the body of the left main coronary artery where no stenosis exists between the major branches? Most surgeons graft the left anterior descending (LAD) and circumflex systems for treatment of bifurcation disease and more proximal lesions because of wide separation of the two territories. Will these grafts compete? Can this be balanced by equivalence of the grafts (bilateral *in situ*, ITAs), or by connecting the grafts as a Y-graft so that they arise from a single inflow as the LAD and circumflex do?

Graft harvest techniques

The ITAs are skeletonized and harvested extending from the inferior border of the subclavian vein distally to the bifurcation into the inferior epigastric and musculophrenic arteries. Extrapleural harvesting can be achieved with careful opening of the sternum and harvesting. This

technique is beneficial in elderly patients and those with respiratory comorbidities by hastening recovery times. A disadvantage of protecting the pleural cavities is that it may restrict the access and ability to position the heart during OPCAB surgery.

RAs are removed by an open method with double clipping, cautery or ultrasound. Endoscopic radial harvesting is growing in popularity and non-randomized published data suggests this is a safe alternative. Pharmacologic dilatation is essential to prevent vasospasm in the perioperative period: glyceryl trinitrate, phosphodiesterase inhibitors or phenoxybenzamine may be employed, and each has its benefits.

Graft configurations

BITA grafting is desirable and forms the cornerstone of total arterial revascularization. The configuration for arterial grafting depends on a number of patient and anatomical variables. The greatest benefit may derive from grafting both ITA grafts to the left system, as is mandated in the largest randomized trial of single *vs.* bilateral ITA grafting.

Use of bilateral *in situ* ITAs can be achieved in a number of different ways. One of the simplest methods, and our preferred technique, is to attach the *in situ* LITA graft to the circumflex or intermediate system on the left side either singly, sequentially to two lateral wall targets, or using a short segment of radial artery as a Y graft for the latter. The RITA is later anastomosed to the appropriate section of the LAD coronary artery, with or without a Y graft of radial artery to a diagonal branch. The arterial reconstruction is completed by grafting the RA to a branch of the right coronary system (*Figure 1*). Prior to grafting, the length of the right internal thoracic artery (RITA) is checked to ensure that it reaches the LAD target in a gentle curve above the aorta, and that it crosses the midline on the innominate vein behind the thymic fat, which provides safety for reoperation, as the RITA and LITA will be found close together as they enter the pericardium via a common slit.

An alternative technique is to anastomose the LITA to the LAD, and if required, to a diagonal branch using either a sequential or Y-graft technique. Sequential grafting is only satisfactory when the diagonal branch lies adjacent to the LAD, thus avoiding a large loop of LITA which may angulate and thus compromise the distal anastomosis. A better technique is to use a short segment of additional arterial graft in a Y configuration from the LITA to the diagonal branch. This is a more flexible solution, allows

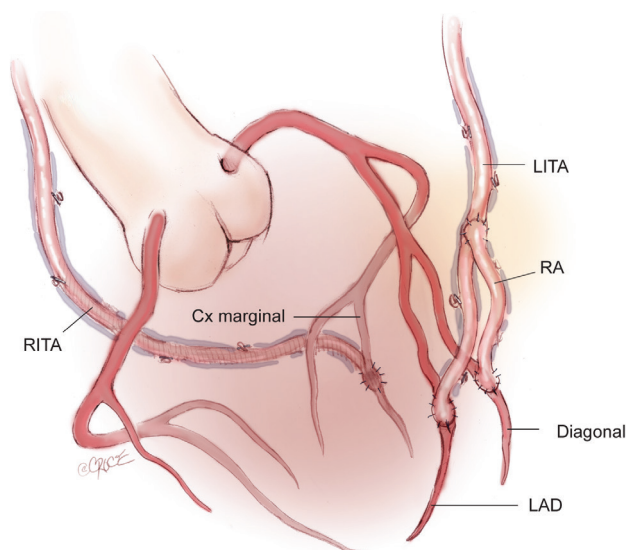


Figure 2 LITA is grafted to the LAD. A short length of the RA is sutured to the *in situ* LAD as a Y-graft for the diagonal branch. RITA passes through the transverse sinus and is grafted to the second circumflex marginal branch.

for any diagonal location, and permits the LITA to find its own lie more easily without kinking when the chest is closed. With this strategy, the *in situ* RITA may be passed through the transverse sinus and anastomosed to the marginal branch of the circumflex system with the potential for a Y graft of radial artery off this to a second marginal target. Occasionally the RITA may be more easily brought anteriorly across the midline—behind the thymus as in the above description—to reach an intermediate or very proximal marginal branch. The reconstruction is then completed with a RA graft to the posterior descending branch (*Figure 2*). This technique is popular with some surgeons although it is difficult to visualize the entire length of the artery and any bleeding sites as it passes through the transverse sinus to the left system, and the posteriorly placed RITA may be difficult to control at reoperation.

A third option is for the LITA to be grafted to the LAD and a RA graft to the circumflex system. The *in situ* RITA may be anastomosed to the main right coronary artery or to the terminal branches of the right coronary artery (RCA) using a graft extension technique. A RITA-RA graft extension may terminate in a single distal anastomosis or as a sequential graft with a side-to-side anastomosis to the posterior descending artery (PDA) and an end-to-side anastomosis with the posterolateral branch

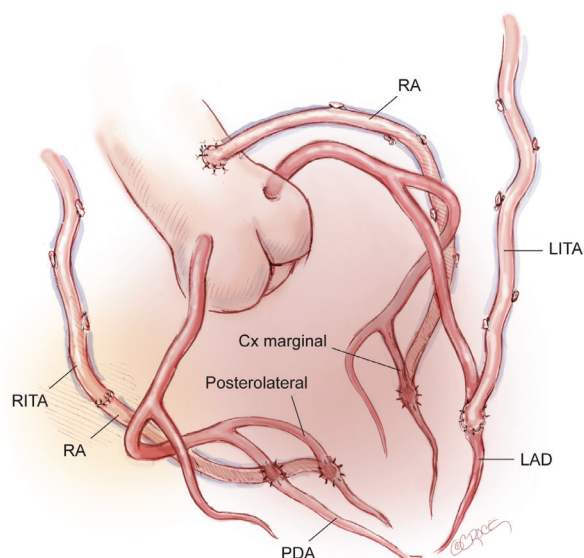


Figure 3 LITA is grafted to the LAD, RA to the circumflex marginal coronary artery. The composite RITA and radial artery extension terminates in posterior descending and posterolateral sequential graft.

(*Figure 3*). *In situ* RITA grafts to the main RCA have suboptimal patency in both our experience and that of others, and this configuration, although technically simple and convenient, is not widely preferred.

When BITAs are contraindicated, or in the very elderly, a total arterial reconstruction can be performed safely in almost all patients using the LITA to the LAD, supplemented by bilateral RA grafting to the circumflex system and to the RCA. This use of bilateral RAs is well tolerated in elderly patients in whom extensive SV graft disease is common. Avoiding the long SV avoids leg trauma and promotes early mobilization (*Figure 4*).

Management of extensive atheroma or calcification of the ascending thoracic aorta remains a challenge. Off-pump surgeons have pioneered the anaortic no-touch technique using single or bilateral ITA composite grafts (15-17) (*Figure 5*). A popular technique involves grafting the *in situ* LITA to the LAD and joining the free RITA or RA as a Y graft to the LITA for distal sequential anastomoses to the branches of the circumflex and RCAs. This has been used successfully by several authors (18,19). There is a potential risk of failure in using a single inflow although this is believed to have adequate flow reserve. There is also the potential for a steal phenomenon as well as a reduction in patency of the distal LITA-LAD segment has been

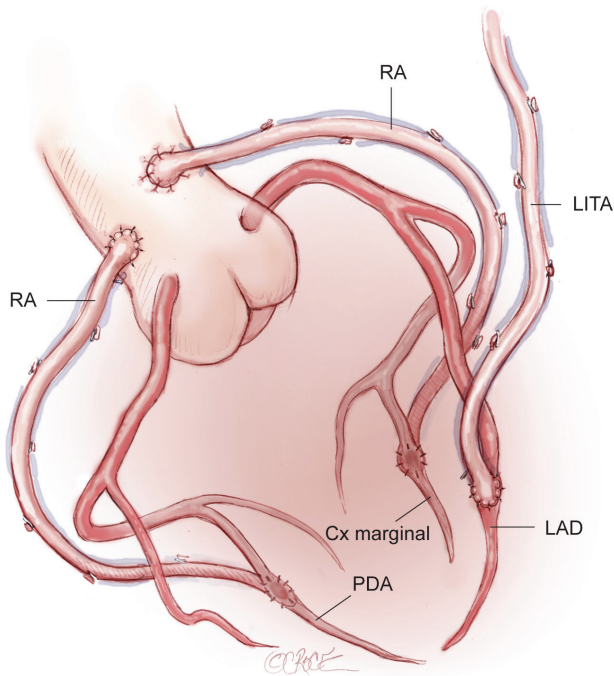


Figure 4 Total arterial revascularization in an 80 year-old patient. A single *in situ* LITA is grafted to the LAD; bilateral RA grafts are sutured to the circumflex and RCAs.

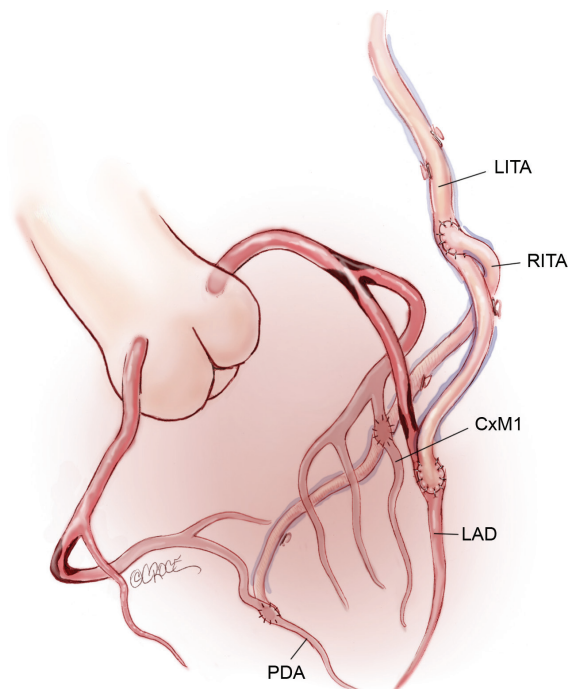


Figure 5 Off-pump anaortic total arterial reconstruction using a composite RITA Y-graft arising from the LITA graft.

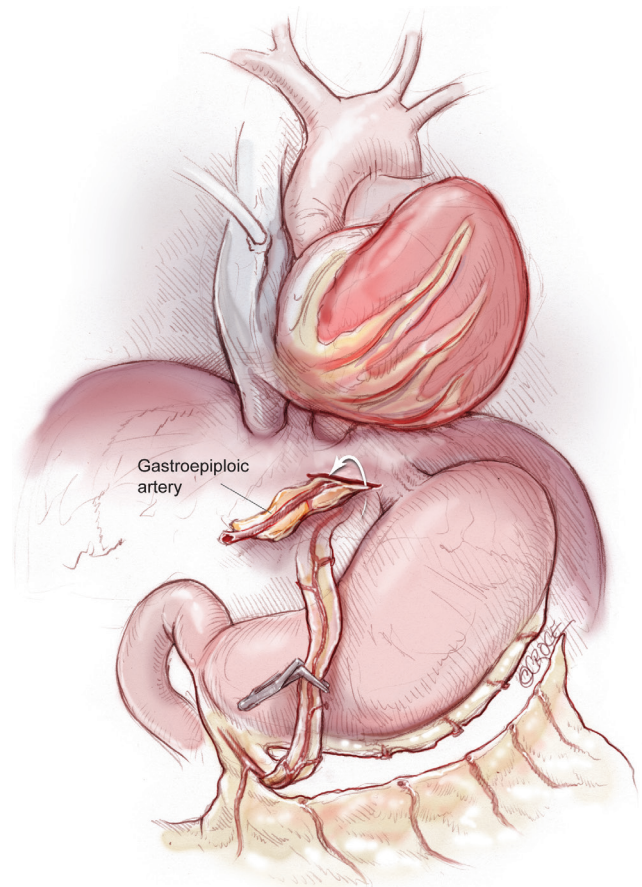


Figure 6 The right gastroepiploic artery is passed anterior to the stomach through a window in the diaphragm to be anastomosed to the posterior descending coronary artery.

reported, which is regarded as a major concern by our group. When anaortic OPCAB is undertaken, we prefer to use bilateral *in situ* ITAs to graft the left circulation, with a RA as Y graft from the circumflex graft to reach around the lateral wall to the posterior descending artery. Alternatively we have used an RA graft to the PDA from the aorta using the ingenious Heartstring device (Maquet Getinge Group, San Jose, California, USA) for a clampless proximal anastomosis on the aorta. The use of three *in situ* arterial conduits by addition of the right gastroepiploic graft to the posterior descending coronary artery is another more technically demanding option (11,20) (Figure 6).

Composite grafting

Sequential grafting (Figure 7A,B), composite Y-grafts

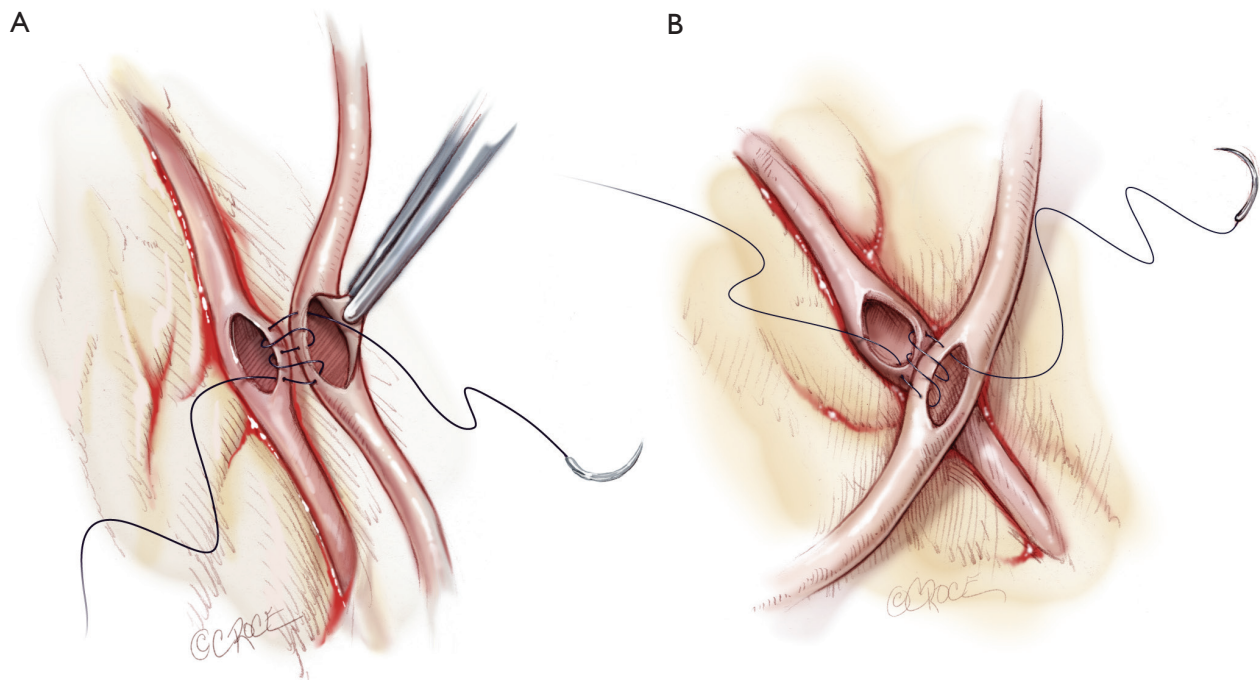


Figure 7 Sequential grafting. (A) Longitudinal in-parallel side-to-side anastomosis between the LITA and RA or segment of RITA; (B) Oblique and diamond-shaped anastomoses for sequential grafting when there is a short length of conduit available.

(Figure 8) and extension grafts (Figure 9) are ancillary procedures allowing additional target artery anastomoses by the efficient use of an arterial conduit. They minimize peripheral incisions for conduit harvesting and may even allow six distal anastomoses in diffuse disease. The LITA-RITA Y-graft technique of Calafiore and Hwang allows complete revascularization based on two intra-thoracic conduits only (18,19) (Figure 10).

Comments

Arterial graft patency

Current patency data confirm that ITA grafts function into the third decade with freedom from failure in over 80%. Most of the later data relates to the widely recognized outstanding results from the LITAs. Tatoulis recently published results of a series of 991 right ITA grafts from 5,766 patients. There was no significant difference between the RITA and the LITA when grafted to the LAD (96.5% *vs.* 94.5%) and similar patencies between RITAs and LITAs were found when grafted to the circumflex system (90.5% and 88.5% respectively). When grafted to the RCA, the *in situ* RITA results were less satisfactory, but arterial grafts

were far superior to SVGs (21). These data support the belief that the RITA behaves in a similar way to the LITA and that more effort should be made by surgeons to explore the potential benefits of the RITA.

There are a large number of observational studies but few randomized trials comparing the RA with the SVG. The 5-year results of the Radial Artery Patency Study (RAPS) confirm a functional benefit of the RA in comparison to the SVG. The Radial Artery Patency and Clinical Outcomes (RAPCO) trial is a two-tiered 10-year biological comparison of the RA *vs.* the free RITA or the SVG. No significant differences were found in survival or patency between the groups at 5 years.

Two large studies of approximately 1,000 gastroepiploic artery (GEA) conduits have indicated 5-year patencies of 62% and 86%. The GEA patency was similar to that of the SV (11,22). More recently, Suzuki reported that skeletonized GEAs had superior patencies to that of SVs (13).

Total arterial revascularization is achievable in most patients with three-vessel CAD (23). The major deterrent in this group of patients is the risk of sternal complications. This is found in patients with diabetes, obesity and pulmonary complications. With careful selection by

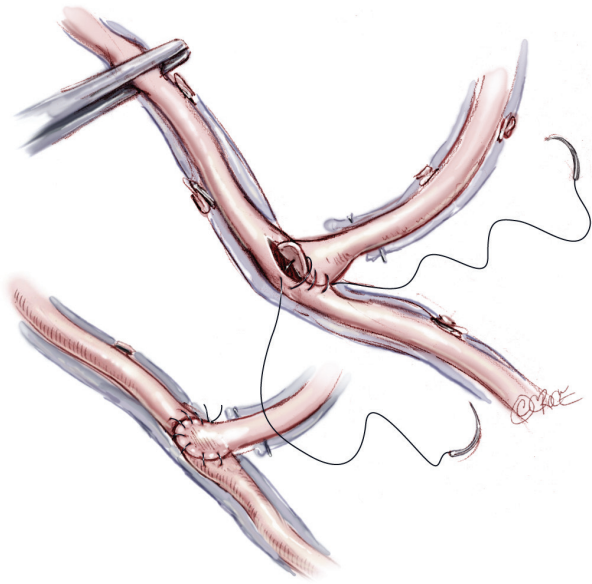


Figure 8 Composite T- or Y-grafts. These angled composite grafts are commonly used on the left system to enhance the number of distal anastomoses.

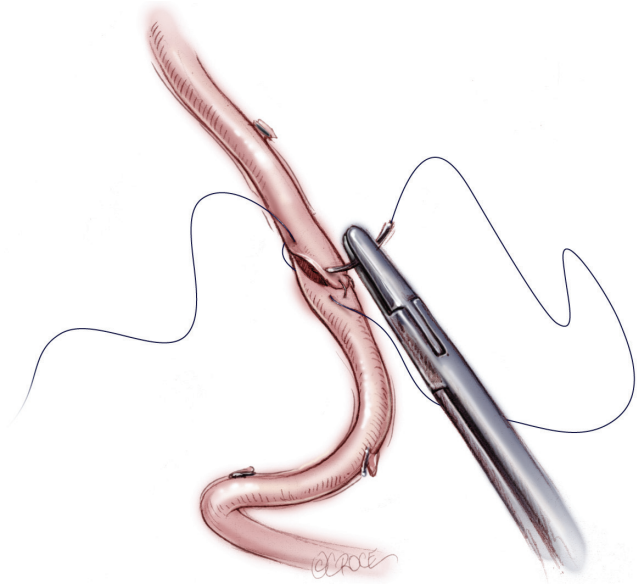

Figure 9 An oblique end-to-end anastomosis to minimize stricture. This technique is employed to provide extra RITA length for distal anastomoses on the right side.

avoiding these high-risk patients, complete arterial revascularization is readily achievable using skeletonized ITAs and yields good long-term results, even in patients with reduced ventricular function (24).

Clinical outcomes after arterial grafting

Grafting both ITAs to the left coronary system is recommended by most surgeons. Recently, the location of the second ITA was suggested not to influence the outcome of coronary bypass grafting (25). In a propensity score-matched analysis, Ruttman compared two groups: the bilateral ITA-SVG and the LITA-RA-SVG group. The incidence of perioperative major adverse cardiac and cerebrovascular events was significantly lower in the RITA compared to the RA groups (1.4% *vs.* 7.6%, $P < 0.001$). They concluded that this study provided strong evidence for the superiority of a RITA graft in comparison to a RA graft as a second conduit in multiple arterial revascularization (26).

Higher risk patients

Patients with diabetes mellitus merit special consideration as they are at an increased risk of sternal complications

from the use of extensive arterial grafting, particularly from BITA grafting. In this subset of patients the risk of sternal complications has increased from less than 1% to about 3% (27-29). A fear of sternal complications is the main cause of surgeons rejecting the use of the RITA during a diabetic arterial reconstruction. An alternative technique is using skeletonization of the graft pedicle to reduce trauma to the chest wall and minimize sternal infections (30). In addition, the combination of single ITA grafts with one or both RA conduits may also reduce chest wall complications.

Total arterial grafting is readily applicable in many very elderly patients. Meticulous harvesting of the ITAs and preservation of the integrity of the pleural cavities reduces postoperative morbidity, particularly pulmonary status, and lowers hospital costs (31). We had adopted a similar extrapleural technique combined with skeletonization of the ITAs in 2001, which produced similar results in elderly patients (*Figure 11*). Most surgeons who practice extensive arterial grafting restrict BITA usage in the eighth decade (32-34). Compared with SV harvesting, a single ITA graft to the LAD, combined with RA conduits, is a safer alternative with a higher degree of patient satisfaction.

There are situations that preclude both BITA use and RA harvesting. In these contexts, and in moderate coronary lesions which risk competitive flow, the use of

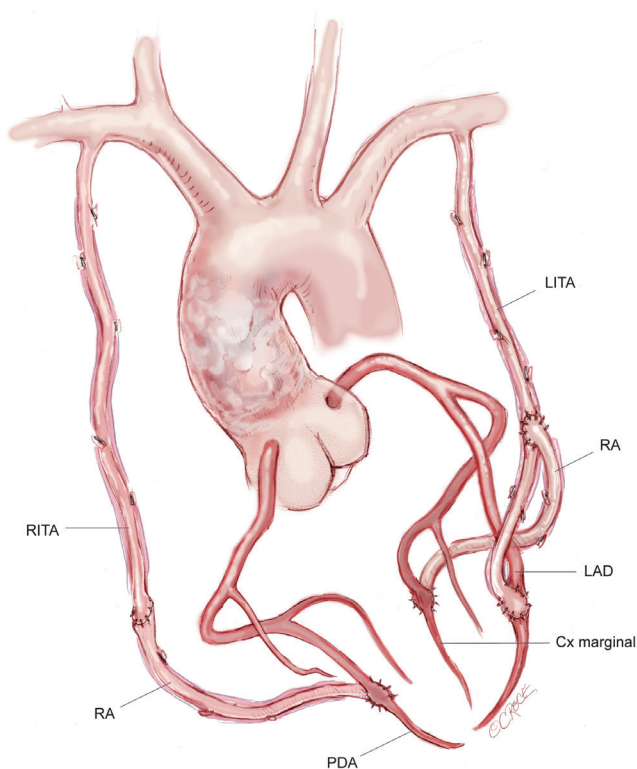


Figure 10 Complete arterial revascularization based on two composite internal thoracic artery conduits in a patient with extensive aortic calcification.

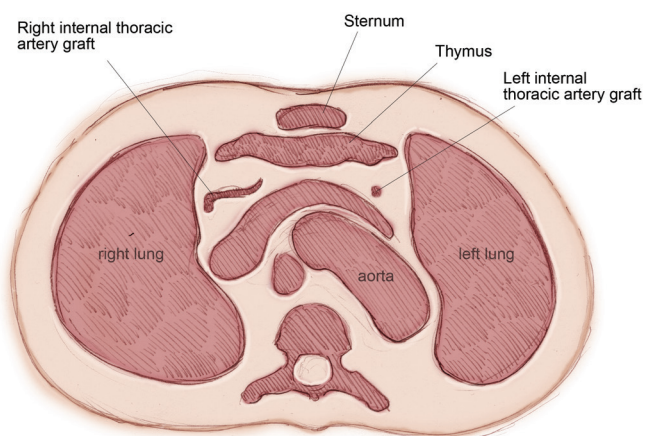


Figure 11 A computed tomographic coronary angiogram at the level of the innominate vein of an extrapleural technique in an elderly patient. The upper end of the skeletonized RITA and LITA are seen extrapleurally passing obliquely to be attached to the LAD and the circumflex system. Note: The pleura remains intact and there is no pleural fluid.

the SV is mandated. However, for the majority of patients with diffuse multivessel disease who dominate surgical caseloads in the post-percutaneous coronary intervention era, total arterial revascularization is achievable. This provides a durable and excellent clinical outcome with lower harvest site complications than from using the SV, as well as potential for lower progression of native vessel disease, higher graft patency and optimal long-term survival.

Acknowledgements

Disclosure: The authors declare no conflict of interest.

References

1. Konstantinov IE, Vasilii I Kolesov: a surgeon to remember. *Tex Heart Inst J* 2004;31:349-58.
2. Barner HB. Double internal mammary-coronary artery bypass. *Arch Surg* 1974;109:627-30.
3. Lytle BW, Blackstone EH, Loop FD, et al. Two internal thoracic artery grafts are better than one. *J Thorac Cardiovasc Surg* 1999;117:855-72.
4. Tector AJ, Kress DC, Schmahl TM, et al. T-graft: a new method of coronary arterial revascularization. *J Cardiovasc Surg (Torino)* 1994;35:19-23.
5. Tector AJ, Amundsen S, Schmahl TM, et al. Total revascularization with T grafts. *Ann Thorac Surg* 1994;57:33-8; discussion 39.
6. Calafiore AM, Di Giammarco G, Luciani N, et al. Composite arterial conduits for a wider arterial myocardial revascularization. *Ann Thorac Surg* 1994;58:185-90.
7. Dion R. Complete arterial revascularization with the internal thoracic arteries. *Operative Tech Card Thorac Surg* 1996;1:84-107.
8. Kelly R, Buth KJ, Légaré JF. Bilateral internal thoracic artery grafting is superior to other forms of multiple arterial grafting in providing survival benefit after coronary bypass surgery. *J Thorac Cardiovasc Surg* 2012;144:1408-15.
9. Taggart DP, Altman DG, Gray AM, et al. Randomized trial to compare bilateral vs. single internal mammary coronary artery bypass grafting: 1-year results of the Arterial Revascularisation Trial (ART). *Eur Heart J* 2010;31:2470-81.
10. Acar C, Ramshehi A, Pagny JY, et al. The radial artery for

- coronary artery bypass grafting: clinical and angiographic results at five years. *J Thorac Cardiovasc Surg* 1998;116:981-9.
11. Suma H, Tanabe H, Takahashi A, et al. Twenty years experience with the gastroepiploic artery graft for CABG. *Circulation* 2007;116:1188-91.
 12. Dimitrova KR, Hoffman DM, Geller CM, et al. Arterial grafts protect the native coronary vessels from atherosclerotic disease progression. *Ann Thorac Surg* 2012;94:475-81.
 13. Suzuki T, Asai T, Matsubayashi K, et al. In off-pump surgery, skeletonized gastroepiploic artery is superior to saphenous vein in patients with bilateral internal thoracic arterial grafts. *Ann Thorac Surg* 2011;91:1159-64.
 14. Hayward PA, Zhu YY, Nguyen TT, et al. Should all moderate coronary lesions be grafted during primary coronary bypass surgery? An analysis of progression of native vessel disease during a randomized trial of conduits. *J Thorac Cardiovasc Surg* 2013;145:140-8; discussion 148-9.
 15. Kim WS, Lee J, Lee YT, et al. Total arterial revascularization in triple-vessel disease with off-pump and aortic no-touch technique. *Ann Thorac Surg* 2008;86:1861-5.
 16. Yan TD, Vallety MP. Aortic no-touch off-pump coronary artery bypass grafting: a state-of-the-art surgical technique. *Ann Thorac Surg* 2010;90:1392-3; author reply 1393-4.
 17. Ross DE. Anaortic coronary bypass surgery. *Semin Thorac Cardiovasc Surg* 2012;24:90-2.
 18. Calafiore AM, Contini M, Vitolla G, et al. Bilateral internal thoracic artery grafting: long-term clinical and angiographic results of in situ versus Y grafts. *J Thorac Cardiovasc Surg* 2000;120:990-6.
 19. Hwang HY, Kim JS, Cho KR, et al. Bilateral internal thoracic artery in situ versus y-composite graftings: five-year angiographic patency and long-term clinical outcomes. *Ann Thorac Surg* 2011;92:579-85; discussion 585-6.
 20. Glineur D, D'hoore W, El Khoury G, et al. Angiographic predictors of 6-month patency of bypass grafts implanted to the right coronary artery a prospective randomized comparison of gastroepiploic artery and saphenous vein grafts. *J Am Coll Cardiol* 2008;51:120-5.
 21. Tatoulis J, Buxton BF, Fuller JA. The right internal thoracic artery: the forgotten conduit--5,766 patients and 991 angiograms. *Ann Thorac Surg* 2011;92:9-15; discussion 15-7.
 22. Takahashi K, Daitoku K, Nakata S, et al. Early and mid-term outcome of anastomosis of gastroepiploic artery to left coronary artery. *Ann Thorac Surg* 2004;78:2033-6; discussion 2036.
 23. Itagaki S, Cavallaro P, Adams DH, et al. Bilateral internal mammary artery grafts, mortality and morbidity: an analysis of 1 526 360 coronary bypass operations. *Heart* 2013;99:849-53.
 24. Galbut DL, Kurlansky PA, Traad EA, et al. Bilateral internal thoracic artery grafting improves long-term survival in patients with reduced ejection fraction: a propensity-matched study with 30-year follow-up. *J Thorac Cardiovasc Surg* 2012;143:844-853.e4.
 25. Kurlansky PA, Traad EA, Dorman MJ, et al. Location of the second internal mammary artery graft does not influence outcome of coronary artery bypass grafting. *Ann Thorac Surg* 2011;91:1378-83; discussion 1383-4.
 26. Ruttman E, Fischler N, Sakic A, et al. Second internal thoracic artery versus radial artery in coronary artery bypass grafting: a long-term, propensity score-matched follow-up study. *Circulation* 2011;124:1321-9.
 27. Boodhwani M, Lam BK, Nathan HJ, et al. Skeletonized internal thoracic artery harvest reduces pain and dysesthesia and improves sternal perfusion after coronary artery bypass surgery: a randomized, double-blind, within-patient comparison. *Circulation* 2006;114:766-73.
 28. Toumpoulis IK, Theakos N, Dunning J. Does bilateral internal thoracic artery harvest increase the risk of mediastinitis? *Interact Cardiovasc Thorac Surg* 2007;6:787-91.
 29. Cohen AJ, Lockman J, Lorberboym M, et al. Assessment of sternal vascularity with single photon emission computed tomography after harvesting of the internal thoracic artery. *J Thorac Cardiovasc Surg* 1999;118:496-502.
 30. Momin AU, Deshpande R, Potts J, et al. Incidence of sternal infection in diabetic patients undergoing bilateral internal thoracic artery grafting. *Ann Thorac Surg* 2005;80:1765-72; discussion 1772.
 31. Bonacchi M, Prifti E, Giunti G, et al. Respiratory dysfunction after coronary artery bypass grafting employing bilateral internal mammary arteries: the influence of intact pleura. *Eur J Cardiothorac Surg* 2001;19:827-33.
 32. Elmistekawy EM, Gawad N, Bourke M, et al. Is bilateral internal thoracic artery use safe in the elderly? *J Card Surg* 2012;27:1-5.
 33. Kieser TM, Lewin AM, Graham MM, et al. Outcomes associated with bilateral internal thoracic artery grafting:

- the importance of age. *Ann Thorac Surg* 2011;92:1269-75; discussion 1275-6.
34. Calafiore AM, Di Mauro M, Di Giammarco G, et al. Single versus bilateral internal mammary artery for isolated

first myocardial revascularization in multivessel disease: long-term clinical results in medically treated diabetic patients. *Ann Thorac Surg* 2005;80:888-95.

Cite this article as: Buxton BF, Hayward PA. The art of arterial revascularization—total arterial revascularization in patients with triple vessel coronary artery disease. *Ann Cardiothorac Surg* 2013;2(4):543-551. doi: 10.3978/j.issn.2225-319X.2013.07.14

Mitral valve repair for ischemic mitral regurgitation

Jahan Mohebbi, Frederick Y. Chen

Brigham and Women's Hospital, Harvard Medical School, Boston, USA

Introduction

Overview: mitral valve repair in cardiomyopathy

Since Bolling's seminal paper more than a decade ago (1) mitral valve repair for mitral regurgitation (MR) in cardiomyopathy remains controversial. The controversy exists primarily in the setting of ischemic cardiomyopathy (2). The pathophysiology of ischemic MR is now accepted to be the result of adverse left ventricular remodeling in the setting of a morphologically normal mitral valve (3). Ventricular dilatation secondary to ischemia leads to lateral papillary muscle displacement which effectively pulls the chordae and the valve leaflets apically (4). This tethering, combined with annular dilation, creates a central leaflet coaptation defect which causes MR in the form of a central regurgitant jet (4). Successful repair of the valve consequently relies on placement of an undersized ring to bring the annulus together and reestablish the coaptation plane (5).

Two distinct questions arise when operative intervention on the mitral valve is considered in the setting of ischemia: (I) should concomitant intervention be undertaken during coronary artery bypass grafting (CABG) and (II) what type of intervention (repair or replacement) should be undertaken.

When MR is moderate, controversy surrounds whether CABG alone to the ischemic myocardium would induce adequate reverse remodeling to restore the subvalvular geometry and consequently diminish or eliminate regurgitation (2). If valve repair accomplishes this, then does valve repair provide any survival advantage? Would this advantage outweigh the increased operative risk associated with concomitant repair?

When MR is severe, the need for valve intervention is not disputed. Rather, controversy surrounds whether repair versus replacement should be undertaken. The answer hinges upon whether elimination of regurgitant volume overload will arrest any further remodeling. If yes, then repair should suffice because the ventricle will not undergo additional remodeling and MR will not recur. If the ventricle continues to remodel despite elimination of

regurgitation at the time of operation, then replacement is necessary, as it would only be a matter of time before ongoing LV dilatation and remodeling would induce recurrent MR in the repaired valve.

The Cardiothoracic Surgical Trials Network (CTSN), sponsored by NIH and the Canadian Institutes of Health Research, is attempting to definitively answer these controversies by conducting multicenter, randomized surgical trials within the last seven years. The CTSN recently published short-term results on mitral valve repair versus replacement for severe MR (6). These results demonstrate that at 12 months follow up for severe MR, there was no difference in survival between repair versus replacement, but repair was associated with a much higher recurrence rate (6). The general consensus of the cardiac surgery and heart failure community was that this short-term data supported mitral valve replacement in the setting of severe MR.

For short-term results of CABG versus CABG and mitral valve repair in the setting of moderate MR, the CTNS will be publishing their results very soon.

Operative technique

Operative preparation

Exposure to the mitral valve is achieved via median sternotomy. This is our preferred positioning because of maximum flexibility in addressing any pathology that may be unexpectedly encountered or other concomitant procedures in these patients. Swan Ganz lines are utilized only for patients with poor ventricular function or severe pulmonary hypertension or right heart failure. TEE is utilized with every procedure to assess ventricular function and valvular interventions. We prefer to tuck the patient's arms while being careful of the ulnar nerve.

Exposition

Operative exposure of the mitral valve: Sondergaard's groove
The mitral valve is the hardest of the four heart valves

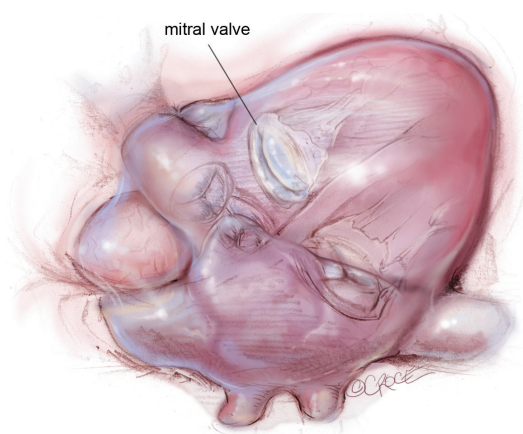


Figure 1 Transparency view of the mitral valve as seen from the surgeon's side of the operating table. It is the furthest valve from the operating surgeon and cannot be viewed *en face* in its natural anatomic state.

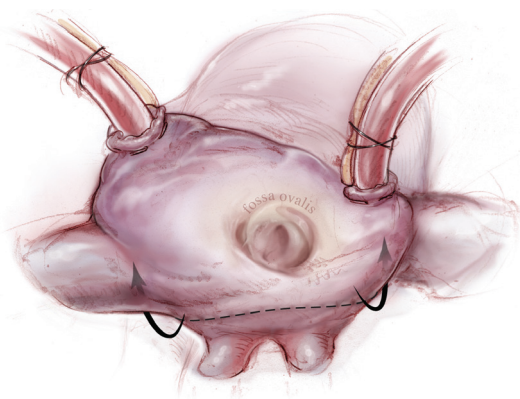


Figure 2 Sondergaard's Groove between the left and right atria. Dotted line indicates the starting position of the dissection plane. The arrows indicate how the dissection plane continues as the anterior RA is lifted off the posterior LA. The anatomic limit of the dissection plane inferior-medially is the fossa ovalis, the junction between the RA and LA.

to expose. Why is this? Anatomically, the mitral valve is furthest from the operating surgeon when approached from the right side of the operating table. The valve is deep and inferior to the surgeon; furthermore, in its natural anatomic state, it cannot be viewed *en face* (Figure 1). Proper exposure of the mitral valve consequently hinges upon understanding and manipulating this anatomy. Exposing the valve so that the surgeon sees it *en face* requires more distortion of the natural anatomy of the heart than any other valve. To achieve this *en face* view, the heart should be rotated

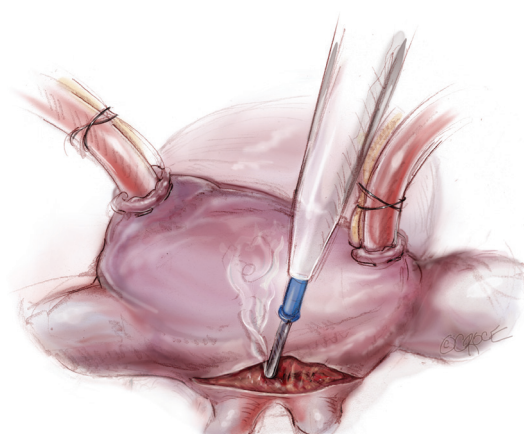


Figure 3 Bovie electrocautery, set to low voltage, is used to develop Sondergaard's Groove approximately 2-3 cm from the right superior pulmonary vein.

counterclockwise (looking down from the ceiling), and the apex should be pushed posteriorly and into the left pleural space as much as possible. This positioning is augmented by bringing up the right pericardium with stay sutures and facilitated by releasing any left pericardial stay sutures. In addition to achieving this critical *en face* view of the valve, these maneuvers will rotate the valve orifice such that the surgeon is looking directly into the LV cavity through an *en face* view of the mitral valve.

The first step in this exposure is as complete a development of Sondergaard's groove, between the right and left atria (Figure 2) as much as possible. Conceptually, from the operating surgeon's perspective, the right and left atria should be viewed as the anterior and posterior atria with respect to the groove. The surgeon is lifting the "anterior" right atrium off the "posterior" left atrium through a combination of blunt and electrocautery dissection. With the Bovie electrocautery set to low, development of the groove should be performed approximately 2-3 cm from the right superior pulmonary vein up to the atrial septum near the fossa (Figure 3). At this location, there is no plane to dissect and the dissection should stop. Next, an incision should be made into the top of the left atrium and care should be taken to maintain a distance of at least 1 cm from the right superior pulmonary vein in order to minimize the risk of injury to the vein (Figure 4). The incision should extend inferiorly between the IVC and the right inferior pulmonary vein and superiorly toward the center of the left atrial dome. Particular care should also be taken to avoid extending the atriotomy too high up and

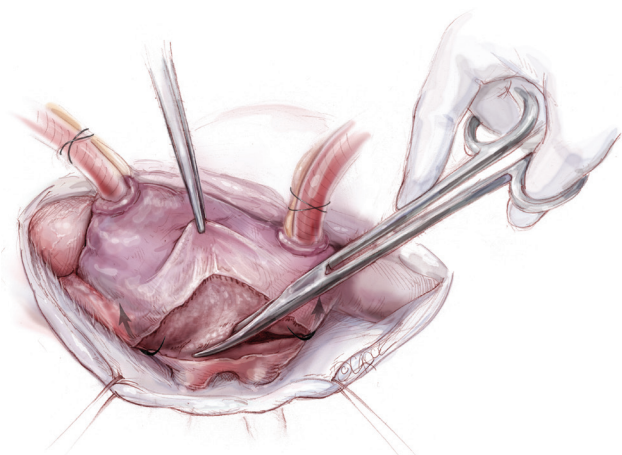


Figure 4 Incising the left atrium. Care should be taken to maintain a distance of at least 1 cm from the right superior pulmonary vein in order to minimize the risk of injury to the vein.

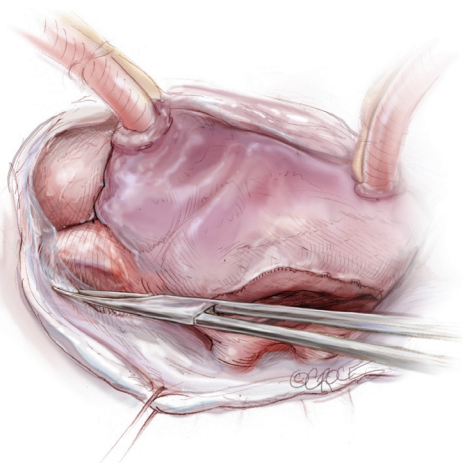


Figure 5 Division of SVC pericardial attachments superiorly facilitates achieving an *en face* view of the valve.

underneath the aorta, making a secure closure hazardous. In elderly female patients, this must be done very carefully. A left atrial dome tear, which continually propagates toward the left atrial appendage underneath the aorta ultimately requires repeat cross clamping and transection of the aorta and SVC for adequate repair, adding considerable morbidity and mortality to the procedure.

Once an atriotomy is made, further maneuvers are performed to facilitate an *en face* view of the mitral valve and to minimize the distance between valve and surgeon, include raising the head and tilting the left side of the operating table down. The superior vena cava inherently

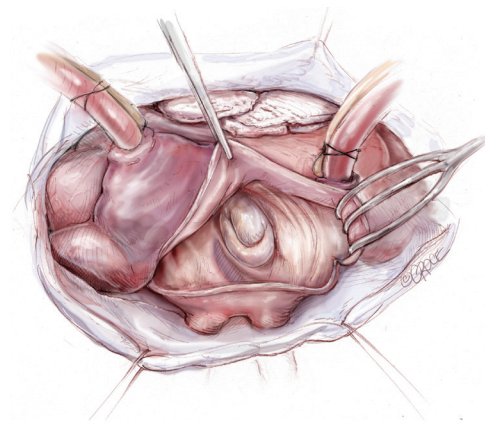


Figure 6 Additional maneuvers to achieving an *en face* view. A sponge stick is used to push the ventricles down and to the left to bring the mitral valve *en face*. The table is rotated to the left and the head of the bed is brought up.

tethers the heart down and hinders the dome from being lifted superiorly to expose the valve through Sondergaard's groove. To counter this tethering, the SVC pericardial attachments may be divided and dissected superiorly (*Figure 5*), while understanding the phrenic nerve is on the other side of the pericardium. To facilitate moving the apex towards the left, the left pericardium can be opened and the ventricular apex pushed into the left pleural space with a sponge, thereby rotating the mitral annular plane toward the surgeon's position (*Figure 6*). Of course, the best exposure may be obtained by complete transection of the SVC, but this is very rarely required. Finally, an additional maneuver is to place sponges on the LV anterior wall to physically push the apex of the heart down and away, moving the mitral valve up and toward the operating surgeon.

Operative exposure of the mitral valve: other approaches

Alternative exposures of the valve include a transeptal incision or approach via right thoracotomy. The transeptal incision has the advantage of allowing the surgeon to be closer to and right on top of the mitral valve. The disadvantage is the extra incision as well as greater postoperative conduction issues created by the extra incision in the right atrium (7). For patients with an extended antero-posterior (AP) dimension, the transeptal approach may be necessary because a large AP dimension accentuates the anatomic features that make mitral valve exposure difficult to begin with. For the right thoracotomy exposure, the advantage is avoiding the front (especially useful in

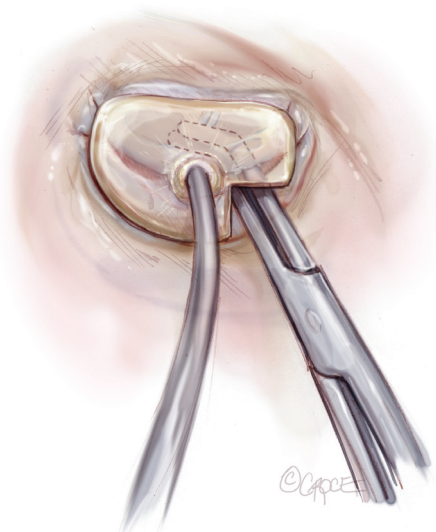


Figure 7 A notch may be cut out of the sizer in order to accommodate a right angle clamp which is used to pull the anterior leaflet chordae down during sizing.

the reoperative setting) and the fact that the surgeon, peering through the right rib cage, is more *en face* naturally than from the standard sternotomy. The disadvantage is complexity of bypass access and the much greater distance to the valve for the surgeon.

Operative exposure in cardiomyopathy

In dilated cardiomyopathy, the heart is large by definition and the left atrium is likely to be quite large as well. Because of this, there is rarely difficulty in exposing the mitral valve, given the remodeled myocardial substrate. Difficulty in mitral valve exposure occurs in patients with large AP dimension and a small left atrium, none of which typically occurs in cardiomyopathy. The authors have personally never been required to utilize the transseptal approach for cardiomyopathy patients.

Cardiopulmonary bypass

We typically utilize bicaval cannulation through the atria for better drainage compared to single stage cannulation. The arterial cannula is placed into the distal ascending aorta. We recommend both antegrade and retrograde cardioplegia given the need for meticulous protection in the setting of cardiomyopathy as well as the fact that concomitant coronary disease is present by definition when addressing ischemic functional MR. Once bypass has commenced, both cavae are placed to the patients left side. This helps to

expose the approach to Sondergaard's groove.

Operation

Assessment of valve dysfunction and repair strategy

Proper evaluation of the valve is critical to a successful repair (4) and begins prior to cardiac arrest with transesophageal echocardiography (TEE). The height of the anterior leaflet from the hinge point to the coaptation plane is measured. Once the valve is exposed, the leaflets should be examined closely to verify that they are morphologically normal and TEE findings should be confirmed by insufflating the ventricle with saline to test the valve and directly observe the central regurgitant jet. As noted previously, in contrast to degenerative or myxomatous disease that directly affects leaflet integrity and morphology, ischemic FMR results from a distortion and dilation of native ventricular geometry that normally supports normal leaflet coaptation. To counter this, the first and most crucial step in successful valve repair is placement of an undersized, complete remodeling annuloplasty ring to restore the annulus to its native geometry.

Annulus sizing and annuloplasty

Sizing is performed to the anterior annulus using a right angle placed in the right hand to pull the anterior chordae down and therefore pull the entire anterior leaflet down. The sizer is introduced with the left hand. Cutting out a notch in the sizers allows simultaneous placement of sizer and right angle in the operative field (*Figure 7*). Sizing is done with the goal of reestablishing the coaptation plane between anterior and posterior leaflet. One undersizes to bring the annulus together and the leaflets into alignment (*Figure 8*). While both partial (C-ring) and complete (O-ring) annuloplasty rings are currently described in the literature, we recommend that only a complete ring be used to treat ischemic functional MR to avoid recurrence as the anterior annulus may dilate as well (8). The anterior annulus does not dilate as much or frequently as the posterior annulus, but indeed it does dilate (8). Furthermore, the three-to-four additional anterior annular sutures required with a complete ring adds very little to procedure time and complexity.

A multitude of rings have been designed for the various annular geometries encountered in ischemic functional MR. In our experience, however, no consistent annular geometry predominates and with so much variation in individual anatomy and ventricular dilation, these rings add very little

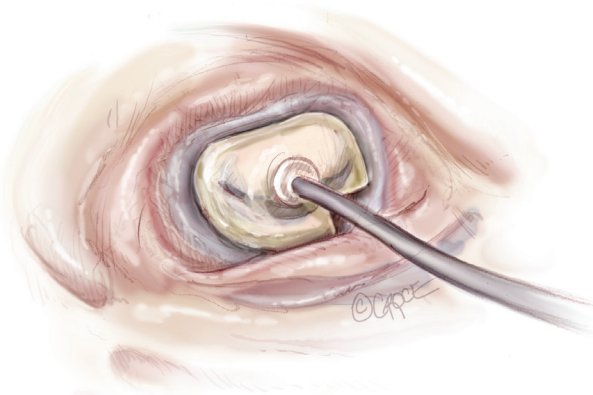


Figure 8 Successful repair of ischemic FMR hinges upon undersizing the annuloplasty ring in order to bring the annulus and leaflets together and into alignment, achieving the central line of coaptation.

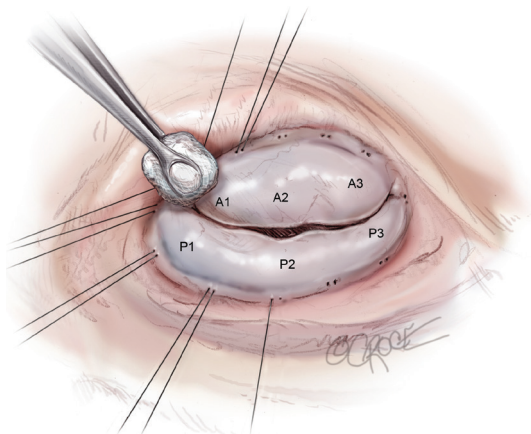


Figure 9 Placement of P1 and anterolateral trigone stitches are facilitated by using the uncut ends of previous sutures to pull down the annulus and using a “peanut” to retract the atrium up and off the trigone in order to expose it.

to the concept of repair. Rather, we continue to emphasize that a complete, undersized ring is of paramount importance to successful repair and will outweigh any minute advantage gained by employing a specially designed ring.

Initial annuloplasty sutures should begin at P2 and move clockwise to the middle of the anterior leaflet. Following these sutures, the next set should begin again at P2 this time travelling counterclockwise. Travelling around the annulus, the P1 stitches and the anterolateral trigone stitches are the most difficult to place. Placement of these sutures is facilitated by using the uncut ends of previous sutures to pull down the annulus while using a “peanut” to retract the

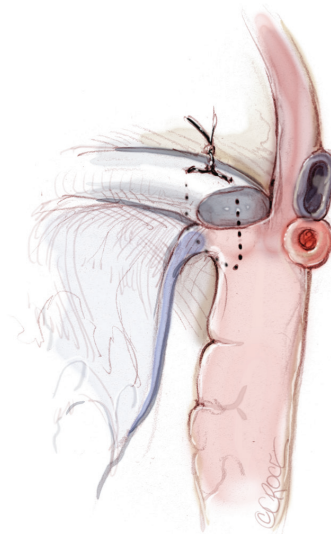


Figure 10 The circumflex artery is avoided by meticulously passing sutures in a plane parallel to the plane of the artery.

atrium up and off the trigone (*Figure 9*) in order to expose it. Additionally, sutures leading up to the trigone should be placed forehand with the surgeon’s palm facing the opposite wall. In this orientation, the needle should first be directed into the left ventricle and then turned back toward the annulus. Of critical importance during annuloplasty is avoiding the circumflex artery. This can be avoided by meticulously passing sutures in a plane parallel to the plane of the artery (*Figure 10*). In this way, when the stitches are tied, no radial component of force to the circumflex artery will be present to distort the artery. After all sutures are placed, the valve should be passively tested prior to closure of the atriotomy.

The aortotomy closure superiorly may be difficult, especially if the left atrial incision has torn superiorly during retraction. This is a common occurrence. At times, placing the first stitch out to in is impossible because of the overlying SVC and aorta. In this situation, the first stitch should be placed in to out, with the first knot being tied inside the left atrium. A dental mirror may be necessary to see the suture line from the inside and to ensure its integrity (*Figure 11*). Regardless of how it is performed, the superior incision must be closed meticulously and securely, because any tearing of the LA suture line underneath the aorta after removal of the cross clamp will typically necessitate re-arresting the heart to adequately address the problem. In an elderly female, this can have disastrous and fatal implications. Rarely, felt may be used to help buttress the fragile left atrial

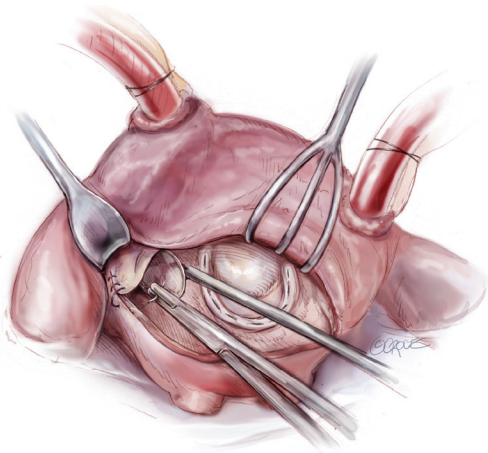


Figure 11 A dental mirror is used to visualize the suture line from the inside and to ensure its integrity. If the crotch of the LA is too high up underneath the SVC and aorta, the suture line may be begun by passing the needle in to out on the far side of the incision first. This necessitates the suture line now being placed inside the atria.

tissue in closing.

Operation conclusion and postoperative care

At the conclusion of the procedure, all suture lines should be meticulously checked, especially the LA suture line. Repair stitches to the suture line should be performed preferably with pledgeted mattress stitches. When performing mattress stitch repairs to the LA suture line, our preference is to use an 3-0 or 4-0 Prolene on an SH needle. Consideration should be given to inotropic support when weaning from bypass, given that repair of the valve may unmask further ventricular dysfunction. In the ICU, postoperative care is routine.

Conclusion: mitral valve repair in cardiomyopathy

Once regarded as anathema, mitral valve repair in cardiomyopathy is now clearly accepted as a viable

treatment option for MR. The recent CTSN trial for severe MR suggests that valve replacement is the treatment of choice for severe MR, but that for moderate MR, valve repair by annuloplasty will continue to have an important role. When repair is appropriate, excellent results can be achieved with undersized, complete ring annuloplasty.

Acknowledgements

Disclosure: The authors declare no conflict of interest.

References

1. Bolling SF, Deeb GM, Brunsting LA, et al. Early outcome of mitral valve reconstruction in patients with end-stage cardiomyopathy. *J Thorac Cardiovasc Surg* 1995;109:676-82;discussion 682-3.
2. Kwon MH, Cevasco M, Chen FY. Functional, ischemic mitral regurgitation: to repair or not to repair? *Circulation* 2012;125:2563-5.
3. Schmitto JD, Lee LS, Mokashi SA, et al. Functional mitral regurgitation. *Cardiol Rev* 2010;18:285-91.
4. Connell JM, Worthington A, Chen FY, et al. Ischemic mitral regurgitation: mechanisms, intraoperative echocardiographic evaluation, and surgical considerations. *Anesthesiol Clin* 2013;31:281-98.
5. Kwon MH, Lee LS, Cevasco M, et al. Recurrence of mitral regurgitation after partial versus complete mitral valve ring annuloplasty for functional mitral regurgitation. *J Thorac Cardiovasc Surg* 2013;146:616-22.
6. Acker MA, Parides MK, Perrault LP, et al. Mitral-valve repair versus replacement for severe ischemic mitral regurgitation. *N Engl J Med* 2014;370:23-32.
7. Lukac P, Hjortdal VE, Pedersen AK, et al. Superior transseptal approach to mitral valve is associated with a higher need for pacemaker implantation than the left atrial approach. *Ann Thorac Surg* 2007;83:77-82.
8. Kwon MH, Lee LS, Cevasco M, et al. Recurrence of mitral regurgitation after partial versus complete mitral valve ring annuloplasty for functional mitral regurgitation. *J Thorac Cardiovasc Surg* 2013;146:616-22.

Cite this article as: Mohebbi J, Chen FY. Mitral valve repair for ischemic mitral regurgitation. *Ann Cardiothorac Surg* 2015;4(3):284-290. doi: 10.3978/j.issn.2225-319X.2015.05.05

The butterfly technique

Tohru Asai

Division of Cardiovascular Surgery, Department of Surgery, Shiga University of Medical Science, Setatsukinowa, Otsu, Shiga, Japan

Introduction

Degenerative mitral valve disease is the most common cause of mitral regurgitation. Posterior leaflet prolapse repairs have been standard cardiac surgical procedures for many years. However, each degenerative mitral disease case can show different degrees of myxomatous changes in leaflet redundancy, chordal rupture and/or elongation. Classic quadrangular resection has been considered a reproducible technique, but is also known occasionally to cause systolic anterior motion (SAM) of the anterior leaflet of the mitral valve. This can also happen with triangular resection and artificial chordal implantation, mostly due to pathogenic change of the posterior leaflet height. The aim of the butterfly resection technique is to optimize the geometry of the resultant new leaflet, with controlled height reduction for each segment in a targeted approach without annular reduction (1). Prolapsing posterior leaflet segments exhibit various degrees of redundancy both in width and in height. Any design for appropriate resection should take account of the degree of redundancy in both dimensions. The goal of butterfly technique is to create an even, symmetrical coaptation zone at a safe distance from the ventricular septum (2). We believe that direct measurement of the height of each segment helps us design the appropriate shape of butterfly resection. The present article describes the step-by-step technical details of performance of a butterfly resection and demonstrates its results, advantages and caveats.

Operative technique

General preparation

Transesophageal echocardiography (TEE) is introduced for all mitral valve repair patients after induction of general anesthesia. We routinely and thoroughly assess the mitral valve leaflets, subvalvular apparatus, left ventricle and regurgitant jet prior to the mitral repair procedure. The cardiopulmonary bypass is instituted with aortic and bicaval cannulation. Cold blood cardioplegia is administered both

in antegrade and retrograde fashion every 20 min during aortic cross clamping. Adequate exposure of the mitral valve and subvalvular apparatus without distorting the left ventricle is crucially important for good mitral valve repair.

Direct measurement of leaflet heights

Prior to a water test, each component of the mitral valve is checked, step-by-step: the anterior leaflet, posterior leaflet, chordae tendineae, anterolateral and posteromedial papillary muscles, and left ventricle. At this point, we measure the heights of four segments (A2, P1, P2 and P3) of leaflets perpendicularly from the mitral annulus using a small paper scale. A water test confirms the location of any leaflet prolapse (*Figure 1*). When the prolapsing segment in the posterior leaflet is redundant and high (higher than 15 mm), we employ butterfly resection for that redundant prolapsing segment. As a degenerative mitral valve always has some deformed redundancy both in width and in height (*Figure 2*), butterfly technique is appropriate in approximately 75% of prolapsing posterior leaflet cases.

The concept of butterfly technique includes controlling the new height of the posterior leaflet without any reduction of the mitral annulus. Butterfly resection combines an initial triangular resection from the prolapsing edge to resolve leaflet tissue redundancy in width with a reverse triangular resection to the annulus, to remove leaflet tissue redundancy in height.

How to design and perform butterfly resection

Before starting leaflet resection, we measure and mark the incisional lines so as to design the remnant leaflet tissue with appropriate height at each side as demonstrated in *Figures 3-7*. By holding a small paper scale next to the leaflet, we mark the appropriate length (typically 15 mm for P2, 12-15 mm for P1 and P3) to set the intended height of the resulting leaflet. It is crucially important throughout the resection to foresee the height and shape which will be created using the tissue which will remain on each side; in

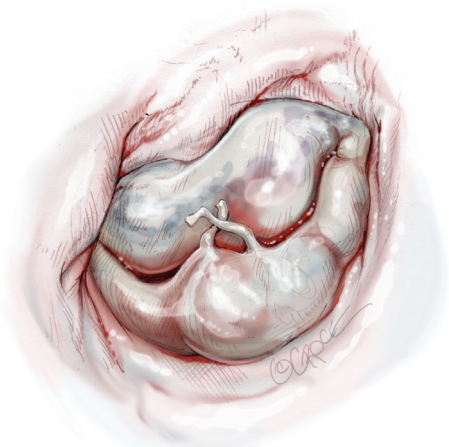


Figure 1 A middle segment of the posterior leaflet (P2) shows prolapse with ruptured chordae with an initial water test, and leaflet tissue has redundancy.

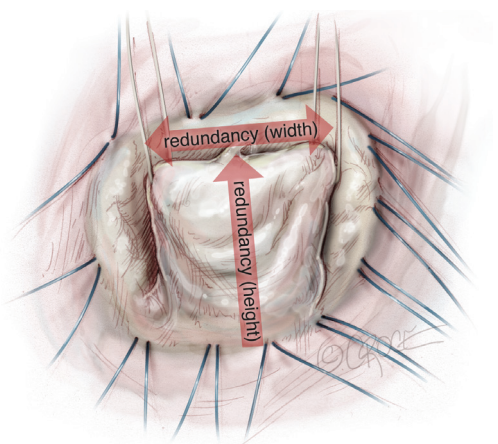


Figure 2 Leaflet tissue redundancy is commonly observed both in width and in height with degenerative mitral valve regurgitation.

other words, one cut only in order to create.

Subsequently, resection of the leaflet segment is carried out using a number 11 bladed knife or scissors (*Figure 8*). The conserved margins of leaflet are then rotated toward the annulus and secured with two knots of a 5-0 polypropylene suture (*Figure 9*). The free corners of the cut leaflet are then brought together and secured, at least temporarily, with another suture in figure-of-eight style. At this point, we confirm the shape of leaflet bulging and line of coaptation formed close and parallel to the posterior annular line, with a water test (*Figure 10*). If we notice unnatural bellowing of a new segment or an uneven coaptation line, it can safely and easily be revised with an additional cut. When we

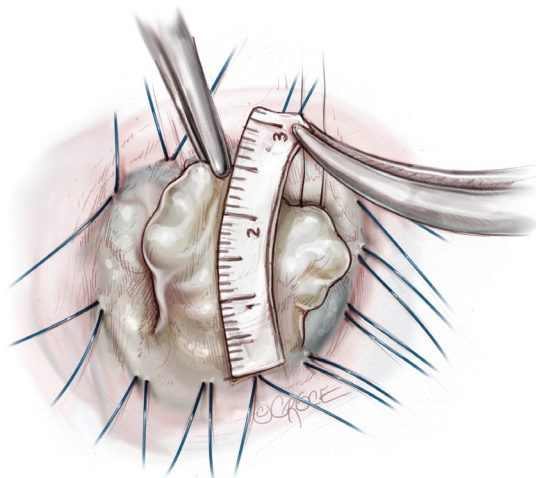


Figure 3 We measure the height of prolapsing P2 segment. When it is higher than 15 mm, we employ butterfly resection.

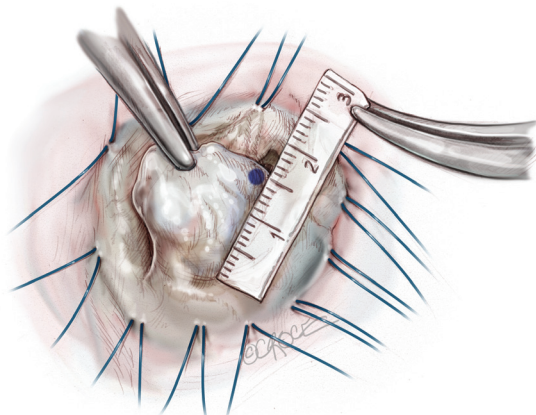


Figure 4 We mark the appropriate length (typically 15 mm for P2) of cut margin as well as of remaining side parts of leaflet tissues, to set the intended height of the resultant leaflet.

are satisfied with the geometry of the new leaflet and the location of coaptation, the cut edges already approximated to the annulus are then sutured to the annulus, using the free end of the first suture, in over-and-over fashion.

Completion and assessment of coaptation

The repair is always completed with a complete ring annuloplasty (*Figure 11*). We choose a Carpentier Physio II Annuloplasty Ring (Edwards LifeSciences, Irvine, CA) to fit the true size of the anterior leaflet, especially its height at A2. In each step, the water-test is repeated to check the overall leaflet appearance and the location of the coaptation

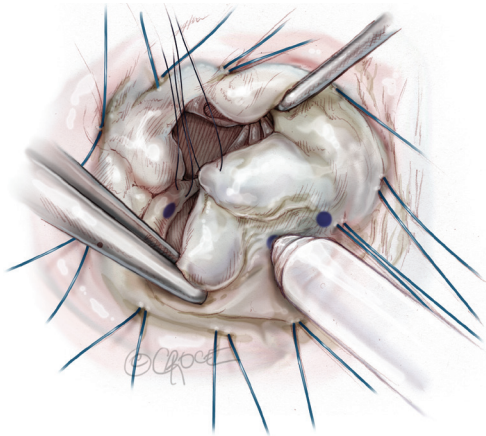


Figure 5 We use a marker pen to mark the design for each leaflet component.

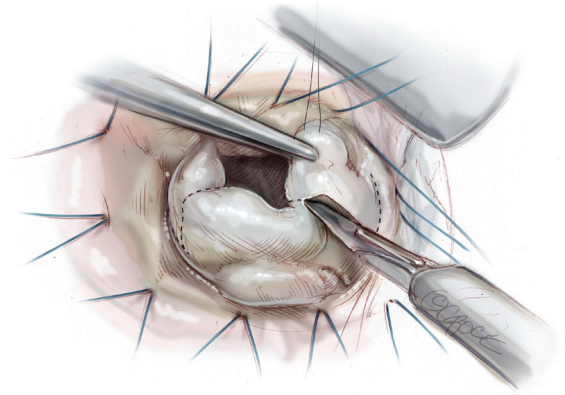


Figure 8 Resection of the prolapsing leaflet segment is carried out using a number 11 bladed knife or scissors

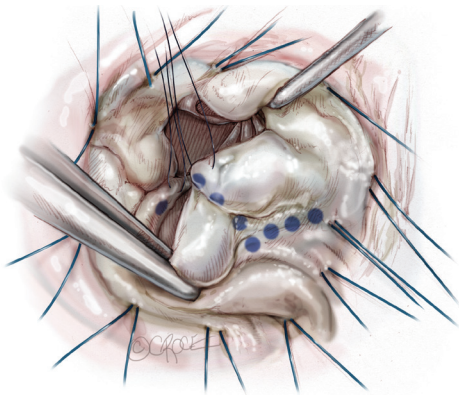


Figure 6 Dotted line demonstrates the right wing of the resultant new leaflet.

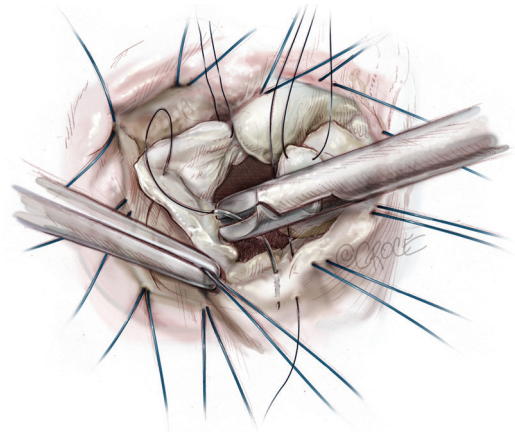


Figure 9 The conserved margins of leaflet are then rotated toward the annulus and secured at least temporarily with two knots of a 5-0 polypropylene suture.

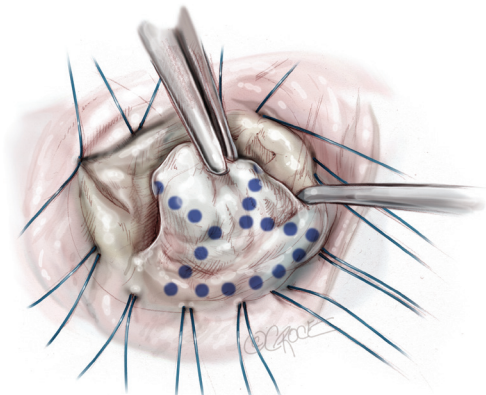


Figure 7 A butterfly design is completed to demonstrate as a shallow triangle at the free margin combined with a reverse triangle with its base at the annulus.

line. What is important is not only the good gross appearance and non-regurgitant new valve form, but also confirmation of the coaptation zone created by the repair. An ink test is always carried out to make sure of an even and adequate coaptation area (Figure 12). Usually we regard 7-10 mm in the vertical depth of the coaptation zone as adequate, however, over 15 mm as inappropriate due to increased risk of SAM.

Confirmation of the repair

The cardiopulmonary bypass is weaned off after we close the left atriotomy with adequate volume filled in the left ventricle and minimal dose of inotropic support.

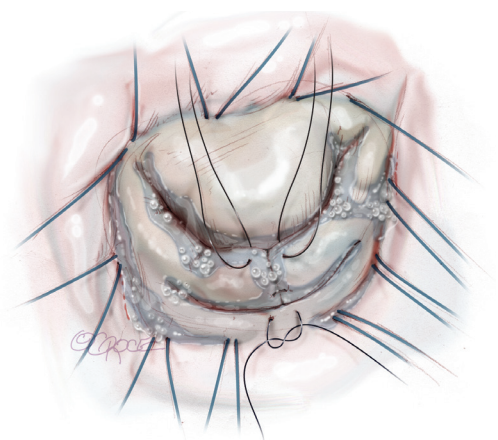


Figure 10 After temporary knot of another 5-0 polypropylene figure-of-eight suture in the free corners of the cut leaflet, we confirm the shape of leaflet bulging and line of coaptation form close and parallel to the posterior annular line, with a water test.

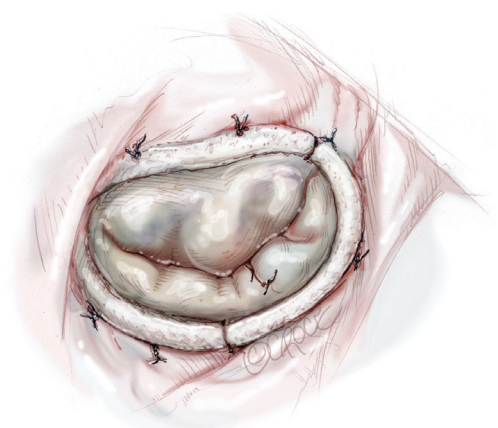


Figure 11 The repair is completed with a Carpentier Physio II Annuloplasty Ring to fit the true size of the anterior leaflet, especially its height at A2.

Assessment by TEE is crucial to detect any residual leakage through the repaired mitral valve or abnormal motion of the anterior leaflet toward the ventricular septum during systole (*Figure 13*). We consider a second procedure for revision of the repair if we find SAM and/or more than 1 cm² of regurgitant jet mosaic pattern by color Doppler mode of TEE. However, we have found a second procedure necessary in less than 3% of the whole series. With the butterfly technique, the distance between the coaptation and the ventricular septum becomes adequately long, and allows the anterior leaflet adequate excursion in the posterior direction.

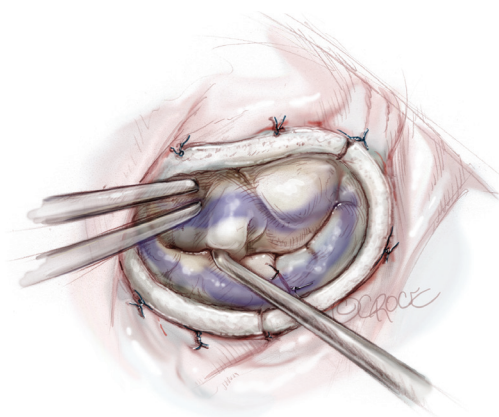


Figure 12 An ink test is used to confirm an even and adequate coaptation area throughout between two commissures.

Comments

Chronic mitral regurgitation with a prolapsed leaflet lesion is mostly associated with leaflet redundancy, and its degree varies considerably among patients (3). That redundancy occurs both in width and in height (*Figure 2*). Therefore classic resectional techniques, such as quadrangular resection and triangular resection, occasionally do not solve the morphological problem in degenerative deformities. The double benefit of butterfly technique is the correction of redundancy, creating appropriate morphometry in the resultant leaflet, but without annular reduction. Furthermore, the step-by-step approach described here prevents excessive resection of the leaflet tissue, generally feared by proponents of non-resectional repair.

A concern common to all resection techniques, including butterfly technique, is excessive resection. If too much tissue is removed, insufficient area in the remaining leaflet tissue might cause reduced area of coaptation and possibly opening of inter-segmental clefts. The butterfly technique is most safely performed with a step-by-step approach, relying on direct measurements of leaflet segmental heights. Fine adjustment is possible by securing the free corners of the cut leaflet temporarily, performing a water test, and making adjustments if shown necessary by the water.

We are aware that this resection technique not only optimizes the leaflet morphology but also brings the leaflet down toward the left ventricular cavity. However, this effect, the curtain effect, is counteracted by the pathological leaflet redundancy, and each step is visually confirmed by the water test. We believe that this “leaflet optimization” by butterfly technique creates an ideal three-dimensional geometry in

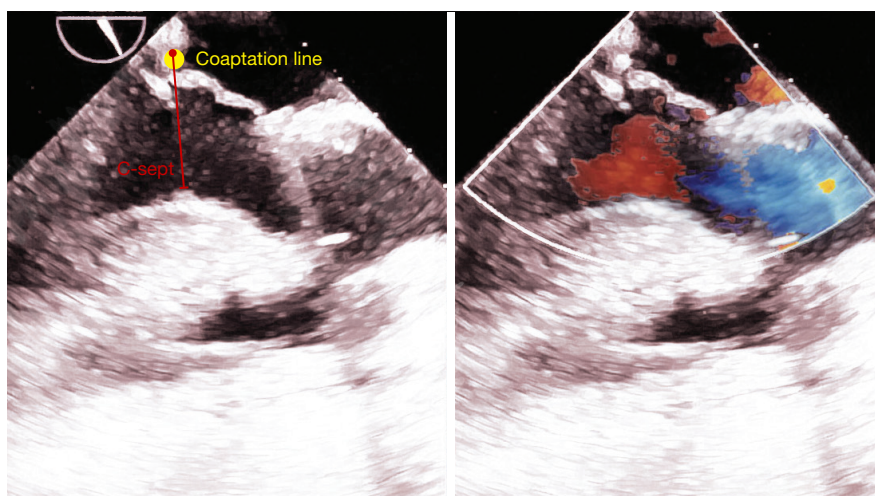


Figure 13 After cardiopulmonary bypass terminated, TEE revealed not only disappearance of mitral regurgitation but also adequately long distance between coaptation to septum (C-sept) in a long-axis view. TEE, transesophageal echocardiography.

each mitral valve leaflet for whatever degree of degenerative deformity.

The goal of butterfly technique is to create adequate leaflet coaptation zone in the appropriate location. We routinely complete the repair with an ink test, which clearly reveals the zone of coaptation, not clearly seen by a water test alone. The coaptation zone is generally thought by many surgeons to be “the deeper, the better”, but we strongly believe that this is not the case. Excessively long anterior leaflet tissue below the coaptation line in the left ventricle is one predisposing factor of SAM in some cases, especially with a small ventricle and a narrow left ventricular outflow. The coaptation line should be formed close to the posterior part of the annulus with adequate but not excessive redundant anterior leaflet tissue below the line.

The mitral annulus in degenerative mitral valve disease has also been reported to be abnormal. In some cases, it has been found considerably dilated, flattened and circular. Moreover the anterior portion of the mitral annulus is generally found to be quite dilated in degenerative disease (4). We should be aware that a Carpentier’s type II lesion is predominantly associated with a global annular dilatation to some degree. The butterfly technique is therefore appropriately completed with a full annuloplasty ring to restore the mitral valve morphology, and early and medium-term outcomes have proven excellent (3).

A quite specific advantage of the butterfly technique is its focus on each diseased segment. We have experienced more than a few cases with multiple prolapsed segments,

and these cases were simply treated by employing multiple butterfly resections. Conventional sliding leaflet technique is not easily applicable for multiple prolapse pathology. One caveat is to reserve the butterfly technique for appropriate cases only. It is not appropriate for a thin short prolapsing leaflet segment with no excess tissue. In contrast, a prolapsing posterior leaflet with a height greater than 15 mm is a safe indication and the outcome is satisfactory.

In summary, the butterfly technique is a method of combining controlled height-reduction and prolapse elimination, and offers advantages as a new standard resection method. We believe it is a valuable technique for every cardiac surgeon’s toolbox.

Acknowledgements

We thank Mr. Piers Vigers for reviewing our manuscript. We thank Ms. Beth Croce for drawing medical illustrations for our manuscript.

Disclosure: The author declares no conflict of interest.

References

1. Asai T, Kinoshita T, Nishimura O, et al. A novel design of posterior leaflet butterfly resection for mitral valve repair. *Innovations (Phila)* 2011;6:54-6.
2. Asai T, Kinoshita T, Hosoba S, et al. Butterfly resection is safe and avoids systolic anterior motion in posterior leaflet prolapse repair. *Ann Thorac Surg* 2011;92:2097-102;

- discussion 2102-3.
3. Asai T, Kinoshita T, Suzuki T, et al. Early and follow-up results of butterfly resection of prolapsed posterior leaflet in 76 consecutive patients. *J Thorac Cardiovasc Surg* 2015;149:1296-300.
 4. Jassar AS, Vergnat M, Jackson BM, et al. Regional annular geometry in patients with mitral regurgitation: implications for annuloplasty ring selection. *Ann Thorac Surg* 2014;97:64-70.

Cite this article as: Asai T. The butterfly technique. *Ann Cardiothorac Surg* 2015;4(4):370-375. doi: 10.3978/j.issn.2225-319X.2015.07.02

Alternative approaches for mitral valve repair

Andrew B. Goldstone, Y. Joseph Woo

Department of Cardiothoracic Surgery, Stanford University School of Medicine, Stanford, CA, USA

Introduction

Patients who undergo surgery for ischemic cardiomyopathy or infectious endocarditis often require concomitant intervention for coexistent mitral regurgitation. Such patients present unique opportunities for exposure and treatment of the mitral valve via alternative, less conventional approaches. Although the left ventriculotomy performed during ventricular aneurysm repair or ventricular assist device implantation provides an excellent view of the mitral valve, it is rarely used for mitral valve surgery. Similarly, the mitral valve is clearly visualized through the aorta after thorough debridement for aortic valve endocarditis. However, in such situations mitral valve surgery is still performed via left atriotomy or transeptally. We have previously reported a handful of series where a transventricular approach was utilized to surgically correct mitral regurgitation at the time of surgical ventricular restoration, repair of ventricular pseudoaneurysms, or implantation of a left ventricular assist device (1,2). We have also described transaortic repair of the mitral valve and aortomitral continuity during intervention for endocarditis (3,4). Each exposure facilitates mitral valve repair, although the standard repair procedures must be modified to accommodate these non-traditional exposures. Here, we detail the technical considerations required to perform transventricular and transaortic mitral valve repair, as well as discuss the advantages for employing these unconventional approaches.

Operative techniques

General preparation

Transesophageal echocardiographic assessment of the mitral valve is performed following induction of general anesthesia. For both alternative approaches, the patient is typically positioned supine for median sternotomy. Cardiopulmonary bypass is then instituted via cannulas in the right atrium and ascending aorta; bicaval cannulation is not necessary for these approaches. A left atrial vent is positioned through the right superior pulmonary vein. The transventricular approach may

also be performed through a left anterior thoracotomy with peripheral vessel cannulation for cardiopulmonary bypass.

Transventricular mitral valve repair

The indication for surgery will dictate the type of ventriculotomy performed. Once the ventricle is open, an off-pump coronary stabilizer is placed into the left ventricle and upward traction is applied to the anteroseptum just anterior to the aortic valve. The remaining aspects of the ventriculotomy orifice can be suspended and retracted with radially positioned silk sutures. Exposing the mitral valve in this fashion provides excellent visualization of the mitral valve annulus, aorto-mitral junction and aortic valve (*Figure 1*). The mitral valve annulus is then sized through the left ventricle with the intent of undersizing for a reduction ring annuloplasty. To begin the ring annuloplasty, mitral annuloplasty sutures are first placed through the annuloplasty ring (*Figure 2*). Carefully avoiding inadvertent interference with chordae tendineae, needles are then sequentially traversed across the mitral valve orifice and into the left atrium. The needle is then passed through the mitral annulus from the atrial side to the ventricular side and out through the ventriculotomy (*Figure 3*). After circumferential placement of all of the annuloplasty sutures, the ring is parachuted through the mitral valve orifice and seated on the atrial side of the mitral annulus in a supra-annular fashion (*Figure 4*). Sutures are then sequentially tied with the knots on the ventricular side of the annulus (*Figure 5*). Valve competence is then tested by injecting saline into the ventricle while the left atrial vent is on suction. If no leak is observed, the ventricular pathology can then be repaired while the ventricle is closed (such as a Dor ventriculoplasty for a ventricular aneurysm). Cardiopulmonary bypass is weaned, a complete transesophageal echocardiographic examination is performed, and the chest is closed.

Transaortic mitral valve repair

In our experience, this approach has been reserved for cases

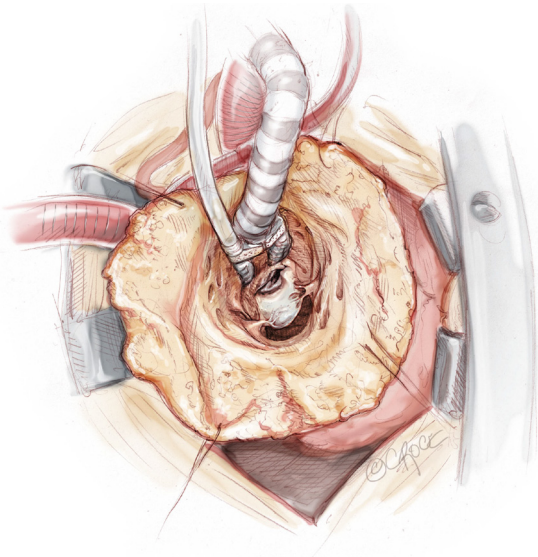


Figure 1 Transventricular exposure of mitral valve using an off pump coronary stabilizer.

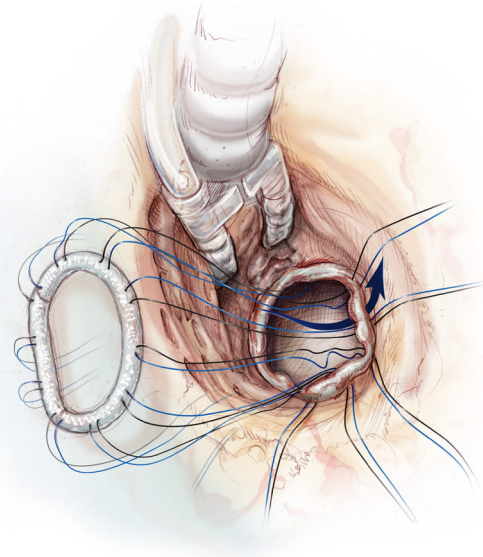


Figure 3 With careful attention to avoid entanglement with chordae tendineae, the needles from the annuloplasty sutures are then passed through the mitral annulus from the atrial side to the ventricular side and out through the ventriculotomy.

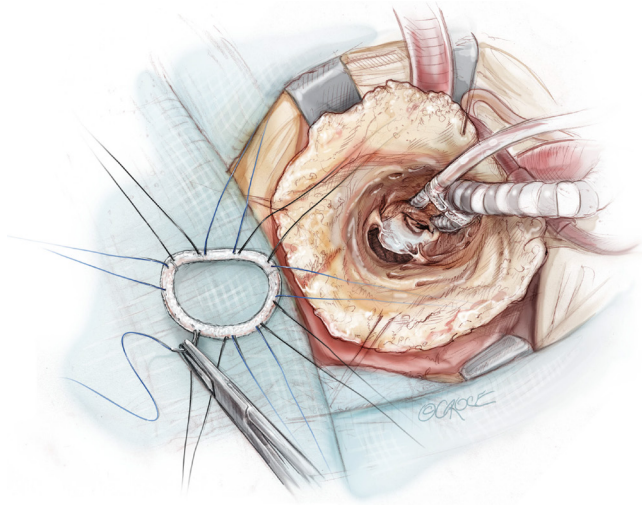


Figure 2 Mitral annuloplasty sutures are first placed circumferentially through the annuloplasty ring.

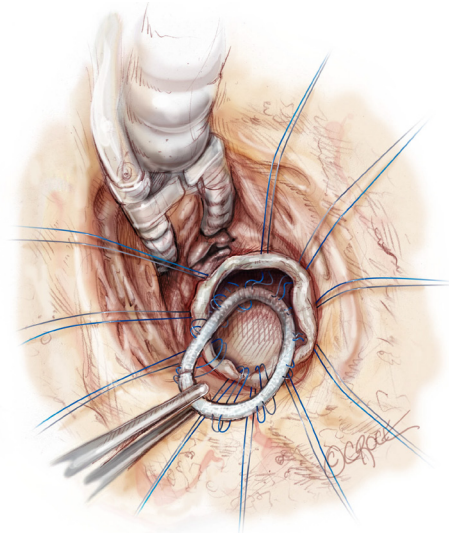


Figure 4 After circumferential placement of annuloplasty sutures through the mitral annulus, the ring is lowered through the mitral valve orifice to the atrial side of the annulus.

of aortic and mitral valve endocarditis. Therefore, adequate debridement of infected and necrotic tissue is paramount and this often includes the aortomitral continuity. If the mitral valve has not undergone irreparable damage, a repair can be attempted, particularly if the patient is young. The mitral valve should be well visualized through the aortic annulus following widespread debridement and excision of the aortic valve or infected prosthesis (*Figure 6*). Repair begins with placement of annuloplasty sutures

in the posterior mitral valve annulus (*Figure 7*). The anterior annulus is approached differently; annuloplasty sutures are first placed in a reverse fashion through the annuloplasty ring and placed on hemostats. The posterior annuloplasty sutures are then passed in a standard fashion

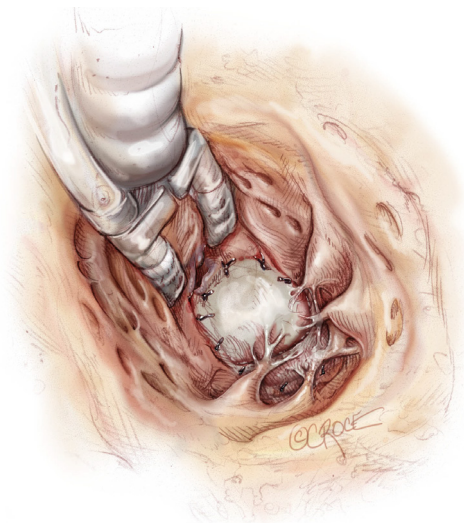


Figure 5 Annuloplasty sutures are tied with the knots resting the ventricular side of the annulus.

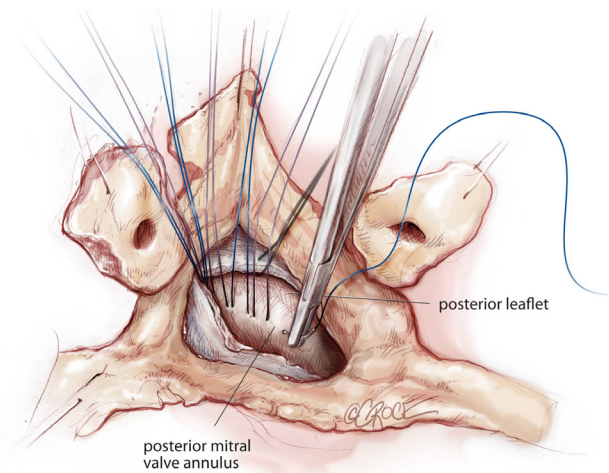


Figure 7 Annuloplasty sutures are first placed in the posterior mitral valve annulus.

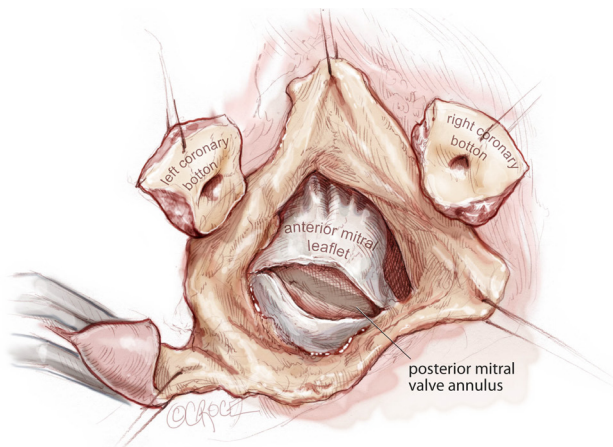


Figure 6 Following debridement of infected tissue, the mitral valve is easily viewed through the aorta.

through the posterior aspect of the annuloplasty ring. The ring is positioned in a supra-annular fashion and the posterior annuloplasty sutures are tied, leaving the anterior annuloplasty sutures emanating from the ring without an anchor to cardiac tissue (*Figure 8*). If the aortomitral continuity has been resected during debridement, the defect can now be repaired with a pericardial patch. At the appropriate positions, the reversed anterior annuloplasty sutures are then placed through the corresponding position on the pericardial patch, thereby recreating the aortomitral continuity (*Figure 9*). The remaining portion of the pericardial patch can then be sewn to the anterior

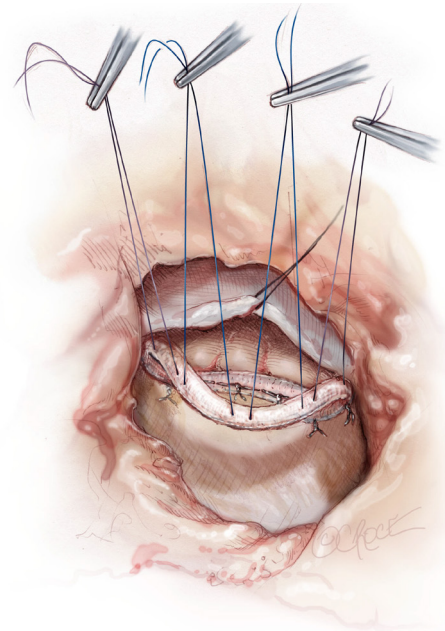


Figure 8 The posterior aspect of the annuloplasty ring is tied onto the posterior annulus. Sutures that were placed through the anterior aspect of the ring emanate out through the aortotomy.

leaflet of the mitral valve to restore the leaflet size and ensure coaptation (*Figure 10*). In the event of torn or resected chordae, an artificial neochordoplasty can be easily performed as transaortic visualization of the papillary muscles is excellent. The artificial neochord should be sized in comparison to other normal chordae. With this

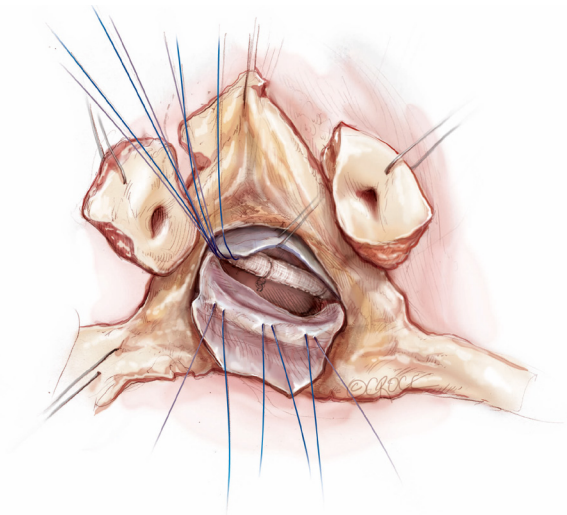


Figure 9 The annuloplasty sutures in the anterior ring are brought through the pericardial patch to reconstruct the aortomitral junction.

technique, it is not possible to test mitral valve competency before separating from cardiopulmonary bypass. Once the repair is complete, the aortic valve or aortic root, if necessary, can be replaced with standard techniques followed by aortotomy closure. Cardiopulmonary bypass is weaned, a complete transesophageal echocardiographic examination is performed, and the chest is closed.

Comments

The growing complexity of cardiovascular operations and reoperations, coupled with the increasing popularity of less invasive surgery, often requires surgeons to employ less traditional exposures and techniques. The present article describes two efficient, unconventional approaches for mitral valve surgery through which surgeons may repair or replace the mitral valve. Both approaches are techniques that prove extremely useful in unique situations, namely surgery in which the left ventricle must be opened, or in cases of aortic valve endocarditis with involvement of the mitral valve. These approaches are well described and offer distinct advantages over traditional left atrial or transeptal exposures.

We have successfully utilized the transventricular approach in a number of settings (1,2). In fact, with minor modifications, this approach may be employed for addressing the mitral valve during any type of ventricular operation. The transventricular approach to mitral valve repair avoids repositioning of the heart as well as an

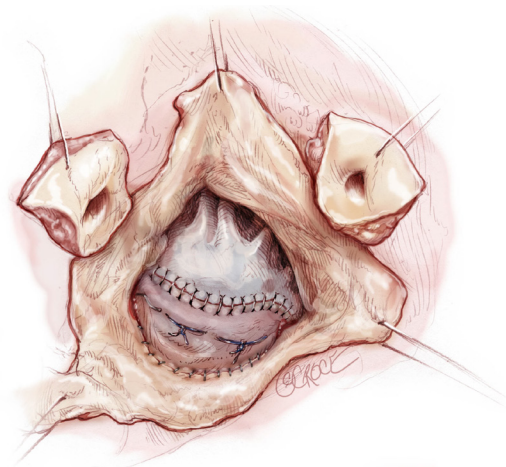

Figure 10 The pericardial patch is sewn to the coapting portion of the anterior mitral leaflet to complete the reconstruction of the mitral valve.

atriotomy. In more acute settings, such as postinfarction ventricular or papillary muscle rupture, the left atrium has not dilated yet because it has not been exposed to longstanding mitral regurgitation. In this setting, an atrial approach is more challenging than usual, while a transventricular approach permits easy visualization and manipulation of the entire mitral valve apparatus (1,5). The transventricular approach is particularly attractive, feasible, and effective in candidates undergoing left ventricular assist device implantation for a bridge to recovery, where correcting mitral regurgitation prior to attempting the device wean is extremely beneficial. Furthermore, streamlining and miniaturization of newer generation ventricular assist devices have led many surgeons to implant these devices in a minimally invasive fashion, thereby avoiding median sternotomy. Transventricular mitral valve surgery through a left anterior thoracotomy permits mitral repair even during these less invasive procedures.

The transaortic approach to reconstruction of the mitral valve and annulus is ideal in the setting of aortic valve endocarditis, where the full extent of the necessary procedure is not apparent until examined in the operative field. Compared to the traditional atriotomy and aortotomy, the transaortic approach may be preferred when an extensive debridement is performed because three-dimensional visualization of the key relationships necessary for reconstruction is possible through the single exposure. The anterior aspect of the annuloplasty ring can serve as the framework for reconstructing the anterior mitral

annulus and utilization of an annuloplasty ring with a curved anterior segment helps re-establish the physiologic shape of the neo-aortomitral junction. This approach is most applicable when mitral valve pathology is limited to the anterior leaflet, with or without involvement of chordae tendineae; however, standard posterior leaflet repair techniques can be performed. The transaortic approach may also be used in situations other than endocarditis. Although this approach is most easily employed through a dilated, elastic aortic annulus, as surgeon experience increases, these anatomic constraints become less of a factor and this approach can even be applied in the setting of bivalvular disease necessitating double valve surgery (6).

Alternative exposures for mitral valve surgery are safe and efficient, and offer distinct advantages over traditional approaches when employed in specific situations. As the complexity of the average cardiovascular surgical patient increases, and as more procedures are performed with minimal access, these alternative approaches may prove increasingly useful. As such, they are valuable assets every surgeon should have in his or her armamentarium.

Acknowledgements

We thank Beth Croce for her illustrative work and assistance.

Cite this article as: Goldstone AB, Woo YJ. Alternative approaches for mitral valve repair. *Ann Cardiothorac Surg* 2015;4(5):469-473. doi: 10.3978/j.issn.2225-319X.2015.08.10

Footnote

Conflicts of Interest: The authors have no conflicts of interest to declare.

References

1. Joseph Woo Y, McCormick RC. Transventricular mitral valve operations. *Ann Thorac Surg* 2011;92:1501-3.
2. Kaczorowski DJ, Blank M, Woo YJ. Intracardiac exposure for transventricular mitral valve ring annuloplasty repair during Dor ventriculoplasty. *J Heart Lung Transplant* 2012;31:1236-8.
3. Chiu P, Allen JG, Woo YJ. Transaortic aortomitral junction reconstruction and mitral valve leaflet repair for recurrent endocarditis. *J Heart Valve Dis* 2015;24:173-6.
4. Frederick JR, Woo YJ. Transaortic mitral valve replacement. *Ann Thorac Surg* 2012;94:302-4.
5. Cagli K, Gedik HS, Korkmaz K, et al. Transventricular mitral valve repair in patients with acute forms of ischemic mitral regurgitation. *Tex Heart Inst J* 2014;41:312-5.
6. Ma N, Liu H, Ding F, et al. Transaortic repair for the moderate functional mitral regurgitation. *J Thorac Cardiovasc Surg* 2014;147:526-7.

How to perform valve sparing reimplantation in a tricuspid aortic valve

Laurent de Kerchove¹, Zahra Mosala Nezhad¹, Munir Boodhwani², Gébrine El Khoury¹

¹Department of Cardiothoracic and Vascular Surgery, Cliniques Universitaires Saint- Luc, Université Catholique de Louvain, Brussels, Belgium;

²Division of Cardiac Surgery, University of Ottawa Heart Institute, Ottawa, Canada

Introduction

The technique of valve sparing root replacement is a desirable option for the treatment of aortic root pathology in the absence of significant aortic cusp disease. In this article, we describe and illustrate our approach to aortic valve (AV) sparing root replacement using the reimplantation technique, originally described by David and Feindel (1). We focus on technical aspects of the reimplantation technique in the setting of tricuspid aortic valve.

The surgical steps towards the reimplantation technique are described below as the following: (I) Aortic valve exposure and assessment; (II) Root preparation and dissection; (III) Graft sizing; (IV) Proximal suture line; (V) Graft preparation and fixation; (VI) Valve reimplantation; (VII) Valve testing and leaflet management; (VIII) Coronary reimplantation; (VIII) Distal closure.

Operative techniques - valve sparing reimplantation

Aortic valve exposure and assessment

After cardio-pulmonary bypass is initiated, the aorta is cross clamped at the level of the distal ascending aorta and the heart is arrested with warm blood cardioplegia. A horizontal aortotomy is performed 1 cm above the sinotubular junction (STJ) (*Figure 1*). Care is taken to avoid injuring the right coronary ostium, which can be misplaced cranially in certain cases of severe aortic root aneurysm or in bicuspid aortic valve. At this stage, the aortotomy is not circumferential and posterior wall above the main stem is left intact. This connection to the posterior sinus allows pulling the aortic valve from the depth by cranial traction on the ascending aorta with a traction stitch. Then, traction stitches (4-0 polypropylene) are placed at the tip of each of the three commissures. These stitches are maintained on artery forceps and are used to assess the valve coaptation and to expose the aortic root during external dissection.

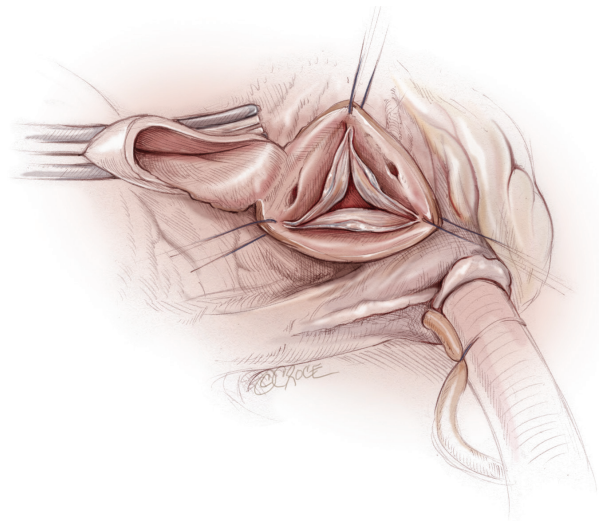


Figure 1 The aortotomy performed 1 cm above the sino-tubular junction and the three commissural traction stitches. The distal ascending aorta is pulled cranially.

Applying an axial traction on the three commissural stitches, assessment of the valve leaflets, sinuses and annulus is performed. Careful attention is paid to leaflet tissue quality, presence of stress fenestrations or leaflet prolapse. A transverse fibrous band on a leaflet and a lower free margin in comparison to adjacent leaflet are signs of leaflet prolapse. Prolapse identified at this stage is repaired after valve reimplantation.

Root preparation and dissection

The first step of the reimplantation procedure is dissection of the aortic root as low as possible, given the natural anatomic limitations of the heart structures. The root dissection is started along the non-coronary (NC) sinus and continued towards the NC/left coronary (LC) commissure (*Figure 2A, B*). In this area, the ventriculo-aortic junction

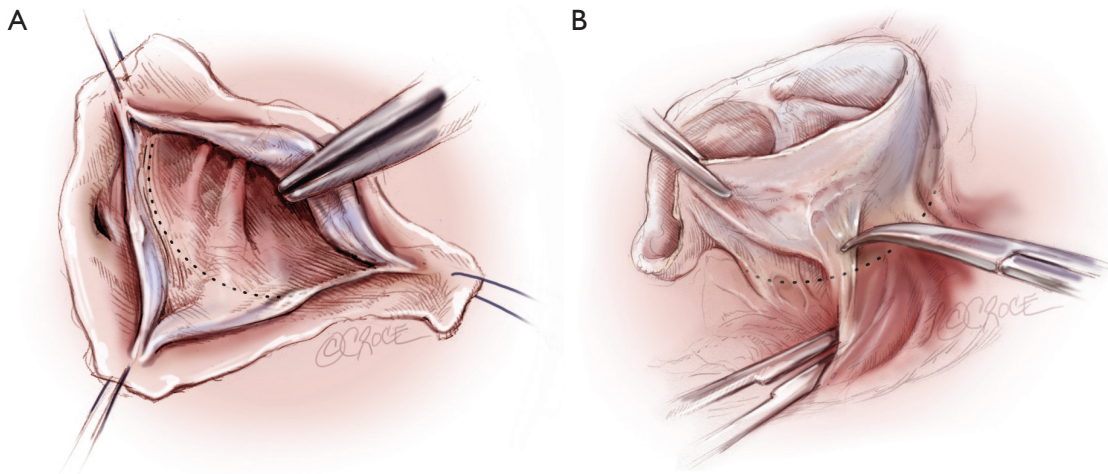


Figure 2 Illustration of root dissection at the level of the non-coronary sinus and non/left commissure. (A) The limit of external dissection reaches the plane (dotted line) passing through the nadir of leaflet insertion; (B) The external anatomical limit of the dissection (dotted line) is composed by the roof of the left atrium.

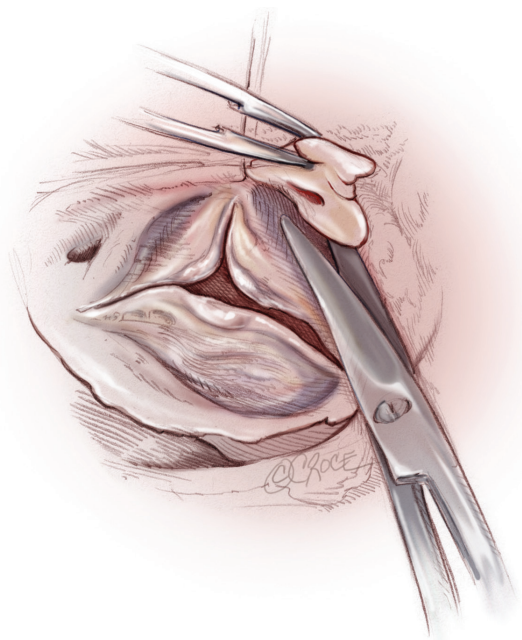


Figure 3 Isolation of right coronary button is performed from the inside of the aortic root before external dissection of the right sinus.

(VAJ) of the AV is fibrous and dissection can be carried to the level of insertion of the leaflets. The sinus of Valsalva is then resected leaving approximately 5 to 8 mm of the base of the sinus wall attached.

Before any external dissection of the right sinus, the right coronary button is harvested cutting it from the inside of the aortic root with a generous patch of sinus wall (Figure 3). Then,

the dissection is continued towards the base of NC/right coronary (RC) commissure (Figure 4A). In this area the anatomical limit of the dissection is composed of membranous septum in relation to the NC/RC commissure and the muscular septum, in regards to the right sinus. The limit of external dissection does not reach the plane passing through the nadir of leaflet insertion (Figure 4B).

Then surgical dissection is continued towards the RC/LC commissure and around to the left sinus (Figure 5). In this area, the anatomical limit of dissection is composed of the muscular portion (interventricular septum and right ventricular outflow tract muscle) of the VAJ in relation to the RC/LC commissure and the roof of the left atrium in regards to the left sinus (Figure 5A). The limit of external dissection reaches the plane passing through the nadir of leaflet insertion at the level of the left coronary leaflet, but not at the RC/LC commissure (Figure 5B).

The left coronary button is then harvested cutting it like the right coronary button from the inside of the aortic root with a generous patch of sinus wall. Both coronary ostia are cannulated with micro osteal cannulae (DLP®, Medtronic, Inc., Minneapolis, Mn) for intermittent blood cardioplegia. The cannulae are fixed with 4-0 polypropylene suture snugged through a tourniquet (Figure 6). Finally, the external dissection of the root is achieved by dissection of the base of the left sinus.

Graft sizing

Our current graft-sizing technique is based on the principle

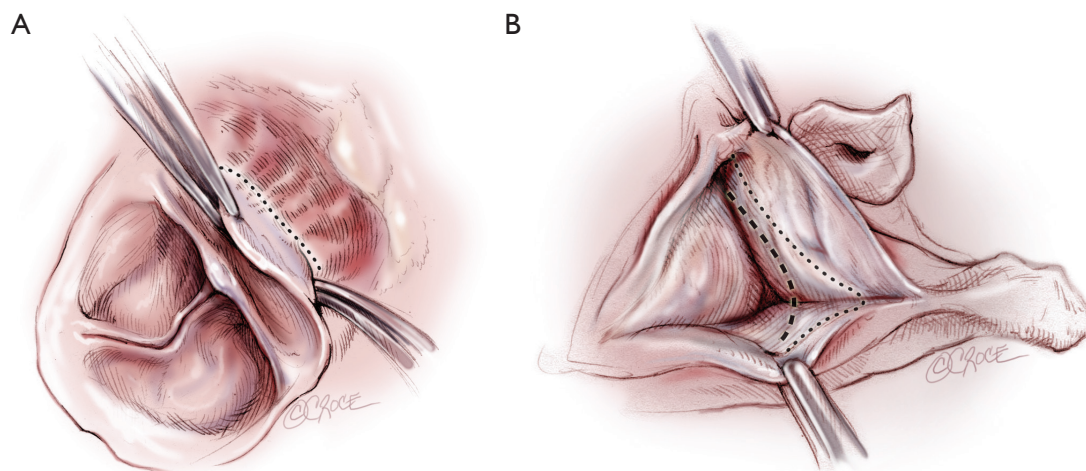


Figure 4 Illustration of root dissection at the level of the right coronary sinus and non/right commissure. (A) the anatomical limit of the dissection (dotted line) is composed by the muscular septum in relation to the right sinus and by the membranous septum in regards to the non/right commissure; (B) The limit of external dissection (dotted line) does not reach the plane passing through the nadir of leaflet insertion (interrupted line).

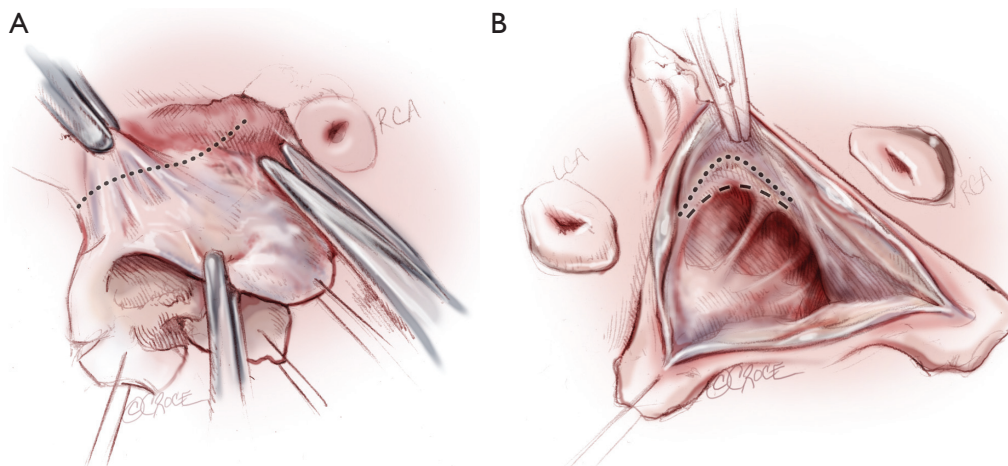


Figure 5 Illustration of root dissection at the level of the left coronary sinus and right/left commissure. (A) the anatomical limit of the dissection (dotted line) is composed of the roof of the left atrium in regards to the left sinus and the muscular septum in regards to the right/left commissure. (B) The limit of external dissection (dotted line) reaches the plane passing through the nadir of leaflet insertion at the level of the left coronary leaflet, but not at the right/left commissure (interrupted line).

that in a normally functioning aortic valve, the height of the commissure (measured from the base of the interleaflet triangle to the top of the commissure) is equal or slightly smaller to the diameter of the STJ. Although various components of the aortic root and the functional aortic annulus may dilate in the setting of root aneurysms, the height of the commissure remains relatively constant. The height of the commissure is most easily measured

with a ruler at the NC/LC commissure by first drawing a connecting line between the nadirs of the 2 adjacent cusps (base of interleaflet triangle) and measuring the distance between this line and the top of the commissure (*Figure 7A*). This measurement corresponds to the size of the graft chosen. When this measurement does not correspond to a labelled graft size, the next larger size graft is chosen. Although this technique can be applied for use with any

type of graft, this principle is further reinforced by the idea that in the Valsalva graft (GelweaveValsalva™ graft, Vascutek Ltd, a Terumo company, Renfrewshire, Scotland), the height of the sinus portion of the graft is equal to its diameter (Figure 7B).

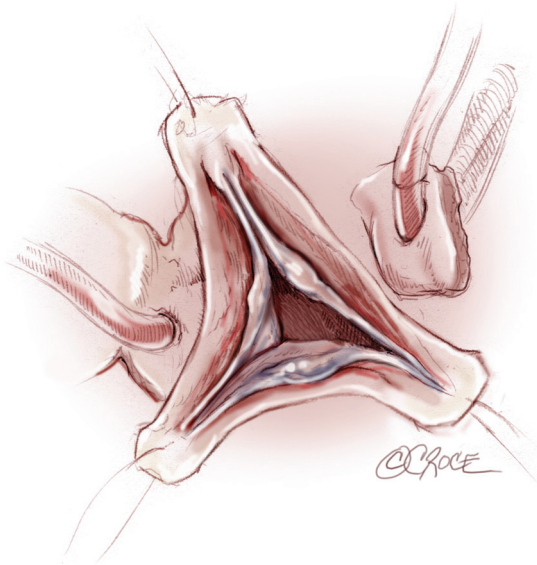


Figure 6 After isolation of the coronary buttons, both coronary ostia are cannulated with micro osteal cannulae. The cannulae are secured in place with 4-0 polypropylene suture snugged through a tourniquet.

Proximal suture line

Twelve 2-0 Tycron sutures with pledgets are generally used for proximal suture line. They are distributed along the circumference of the ventriculo-aortic junction. Sutures are passed from inside to outside the aorta with the pledgets on the inside, starting from the NC/LC commissure and moving clockwise (Figure 8A). Along the fibrous portion of the aortic annulus, these sutures are inserted along the horizontal plane formed by the base of the inter-leaflet triangles. Importantly, however, along the non-fibrous portions of the annulus where the external dissection of the aortic root is limited by muscle, these sutures are inserted along the lowest portion of the freely dissected aortic root making the proximal suture line slightly higher at the NC/RC and RC/LC commissures compared to the NC/LC commissure (Figure 8B). Attention must be paid to avoid contact between the pledgets and the cusp tissues. Thus it is safe to consider 2 mm distance in between them.

Graft preparation and fixation

A Dacron prosthesis with built-in neo-aortic sinuses is generally used. To prevent valve distortion, the three commissures must be attached to the prosthesis along the same plane that corresponds to the sinotubular junction of the graft. Due to the anatomy of the base of the aortic root, the proximal sutures are not in a plane and the proximal

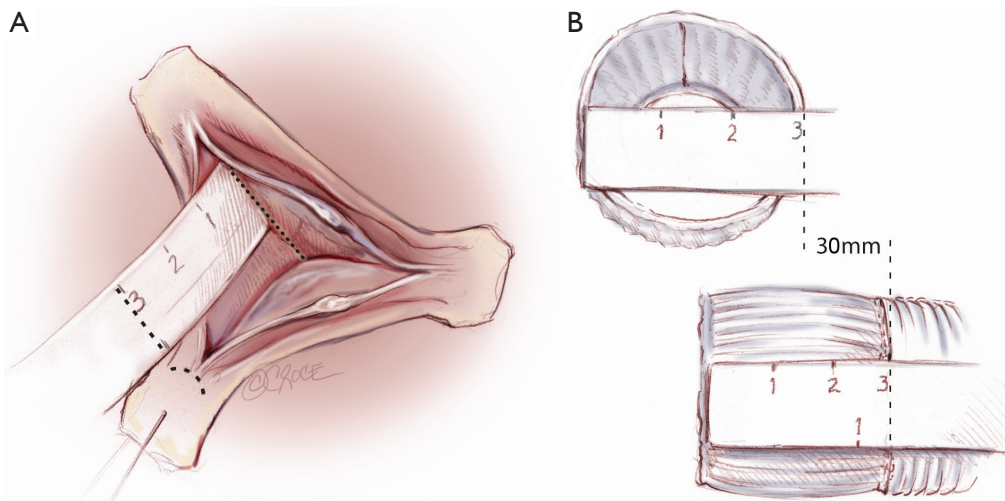


Figure 7 (A) The height of the non/left commissure is measured for graft sizing from a line connecting the nadirs of the two adjacent cusps (base of interleaflet triangle) to the top of the commissure. This measurement corresponds to the size of the graft chosen; (B) In the Gelweave Valsalva™ graft (Vascutek Ltd, a Terumo company, Renfrewshire, Scotland) the height of the sinus portion is equal to its diameter, which correspond to the labelled size.

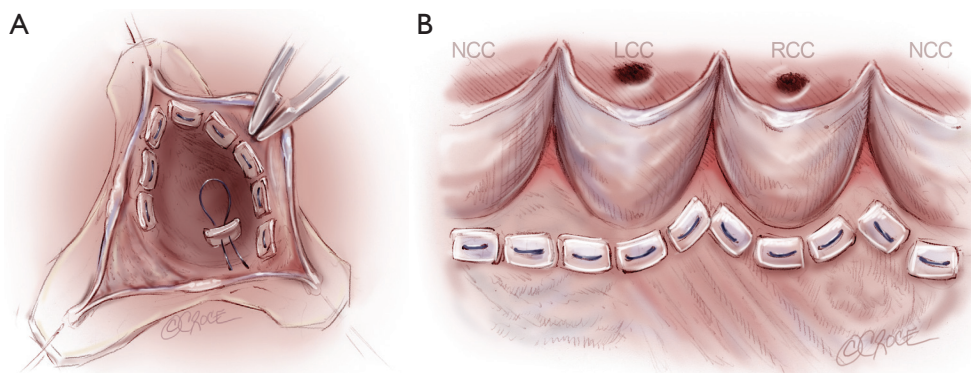


Figure 8 (A) The proximal suture line is performed with 2-0 Tycron sutures with pledgets passed from inside to outside the aorta; (B) Along the fibrous portion of the aortic annulus, these sutures are inserted along the plane formed by the nadir of leaflet insertion. Along the non-fibrous portions of the annulus where the external dissection of the aortic root is limited by interventricular structures, these sutures are inserted along the lowest portion of the freely dissected aortic root making the proximal suture line slightly higher at the non/right and right/left commissures compared to the non/left commissure.

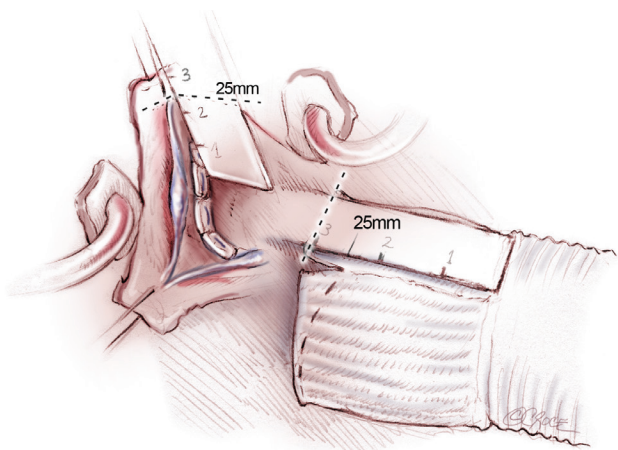


Figure 9 Tailoring of the proximal end of the graft: the heights of the freely dissected portions of the non/right and right/left commissures, corresponding to the distance from the proximal suture to the top of the commissure (left panel), are measured. These measures are reported on the graft from the sino-tubular junction and the exceeding length of the sinus skirt is split to the proximal end (right panel).

end of the graft need to be tailored in consequence. Therefore, the height of the freely dissected portion of the NC/RC and RC/LC commissures are measured. This height is the distance from the proximal suture to the top of the commissure (*Figure 9*). These measures are used to determine the amount of graft material that needs to be trimmed. Thus, the height of the trimmed portions on the

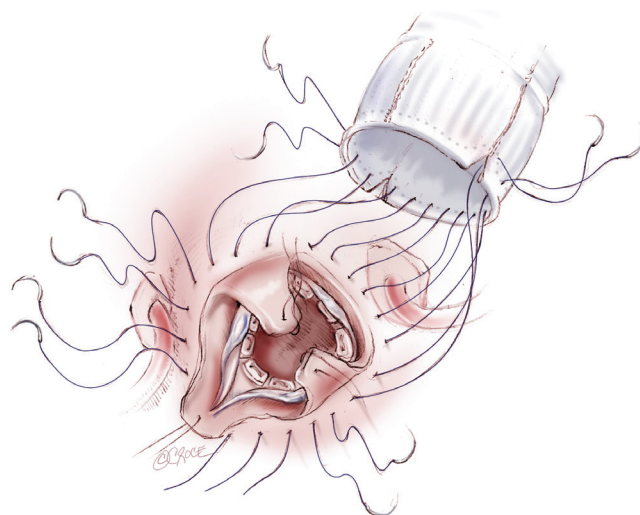


Figure 10 The sutures are passed through the base of the prosthesis respecting the curvilinear contour of the proximal suture line.

graft is the difference between height of the unrestricted NC/LC commissure and the distance from the proximal suture line to the top of the respective NC/RC and RC/LC commissures. The exact shape of the trimmed portions is less important as the prosthesis will accommodate to the external limitations of the aortic root.

The pledgeted sutures are then passed through the base of the prosthesis, respecting the spaces between sutures and importantly, the curvilinear contour of the proximal suture line (*Figure 10*). The commissural traction sutures are

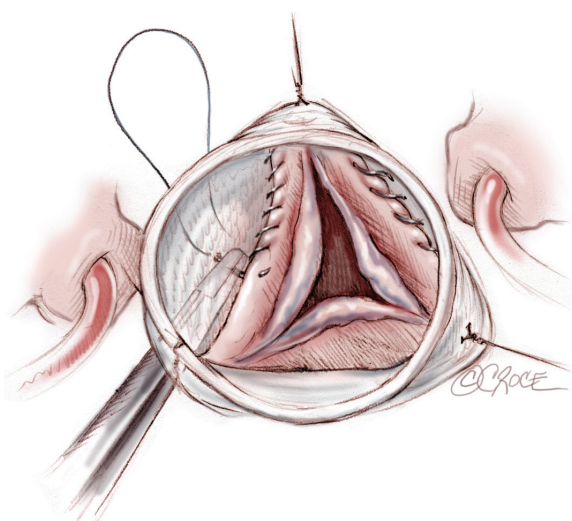


Figure 11 The 4-0 polypropylene running suture for valve reimplantation is performed in small regular steps passing the suture from outside the prosthesis to inside and through the aortic wall, staying close to the annulus, and then back out of the prosthesis.

passed through the graft and pulled up together while tying down the prosthesis to ensure appropriate seating around the aortic annulus.

Valve reimplantation

The commissures are reimplanted first using 4-0 polypropylene sutures while pulling up on the prosthesis and the native commissure and then tied into place. With our specific method of graft sizing and trimming, the tips of the three commissures should reach the same level/plane which correspond the neo-STJ in a Valsalva graft. Radial traction is then applied on two adjacent commissural sutures and this help to delineates the ‘line of implantation’. This running suture line is performed in small regular steps passing the suture from outside the prosthesis to inside and through the aortic wall, staying close to the annulus, and then back out of the prosthesis (*Figure 11*).

Valve testing and leaflet management

After valve reimplantation, it is critical to re-examine the leaflets for any unmasked prolapse, symmetry, and the height and depth of coaptation. After placing the leaflets into their closure position, using a syringe of water, the valve is flushed with force and observed after suction of the water (*Figure 12*). Attention is focused on the mid

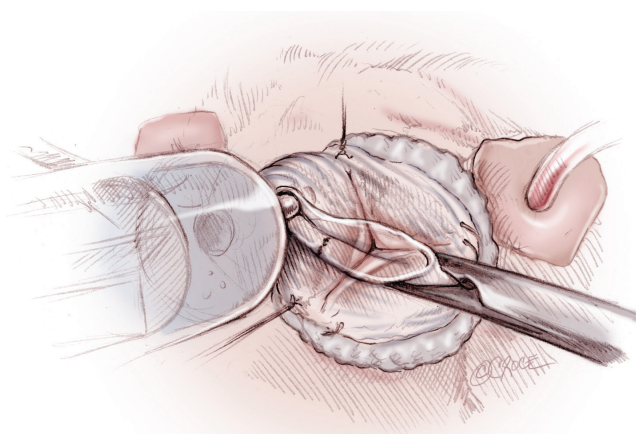


Figure 12 With a syringe of water, the valve is flushed with force and observed after suction of the water.

portion of the leaflets free-edges. Prolapse is present when the level of a free-edge is lower than the adjacent one(s). Prolapse can be confirmed by pushing gently the middle of the free-edge towards the ventricle. If one or two leaflet are prolapsing, the normal one(s) is taken as reference for the repair. If all three leaflets show low free-edge level (e.g., annulus level), then all three are repaired taking the mid-height of the sinus of Valsalva as reference. Prolapses are repaired using central free-edge plication technique with a 6-0 polypropylene suture. If an important amount of tissue needs to be excluded, the top of the plication may be resected and a blocked running 6-0 polypropylene suture is used to close the defect from the middle of the leaflet belly towards the free-edge. Free-edge resuspension technique, with running suture of 7-0 Goretex, may be used in presence of stress fenestrations to correct the prolapse, reinforce the free-edge and close the fenestration. The running suture is passed over and over the free-edge and the fenestration from one commissure to the other. The suture is then tied on the external side of the aorta after adjusting the free-edge length by pulling on each side of the suture.

Coronary reimplantation

The left coronary button is the first to be reimplanted. A hole of approximately 6 to 8 mm of diameter is made in the graft in regards to the coronary button. Reimplantation is performed with a running suture of 5-0 polypropylene (*Figure 13*). The suture starts on the inferior portion of the button (*Figure 13A*). The cannula can remain in the ostia

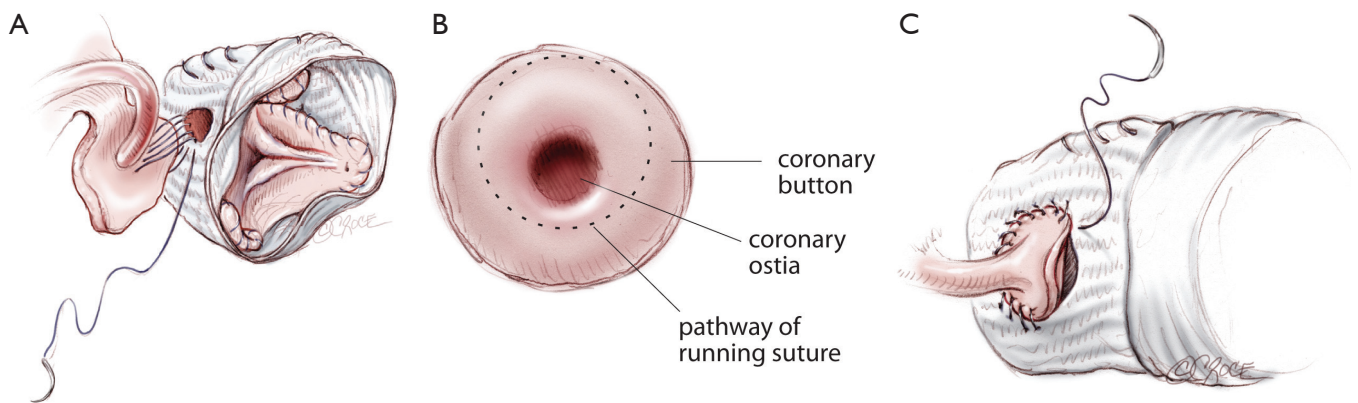


Figure 13 (A) Coronary reimplantation is performed with a 5-0 polypropylene running suture. For both coronaries, the suture starts on the inferior portion of the button. (B) At this level, the stitches are passed close to the opening of the ostium. (C) After several passages, the inferior portion of the button is approximated to the graft by tightening the suture. The suture is continued on both sides and on the superior portion of the button where stitches are passed distant from the opening of the ostium.

to avoid backflow from the coronary while suturing this portion. At this level, the stitches are passed close to the opening of the ostium (*Figure 13B*). After several passages, the superior portion of the button is cut from the ascending aorta and trimmed. The cannula is removed from the ostia and the inferior portion of the button is approximated to the graft by tightening the suture (*Figure 13C*). The suture is continued on both sides and on the superior portion of the button where stitches are passed distant from the opening of the ostia. A free autologous pericardial strip can be used on the button side to improve haemostasis. A similar technique is used for right coronary reimplantation. We believe this technique of suturing coronary buttons allows to minimize kinking or twisting of the proximal portions of the coronaries.

Cardioplegia is then administered through the distal end of the graft with partial clamping in order to distend the new aortic root. This maneuver allows to assess sutures haemostasis and valve competence by indirect sign such as root pressure and left ventricular dilatation. A limited echocardiographic view may also be obtained at this time. The cardioplegia solution is then slowly aspirated out of the prosthesis without distorting the leaflets for a last check of valve configuration.

Distal closure

Finally, the distal anastomosis is performed at the level of normal aorta with 4-0 polypropylene on a small needle. A Teflon felt strip is used as external reinforcement on the native aorta if this one is judged fragile.

Conclusions

The main concept of our valve sparing reimplantation technique is to restore the functional anatomy of the aortic valve and root while respecting heart's anatomy. Therefore, several key technical aspects are followed including adequate remodeling and support of the ventriculoaortic junction, creation of neo-aortic sinuses, cusp repair and respect of coronary anatomy. This results in a standard operative technique which is reproducible and when applied systematically can result in consistent and excellent long-term outcome (2).

Acknowledgements

Disclosure: The authors declare no conflict of interest.

References

1. David TE, Feindel CM. An aortic valve-sparing operation for patients with aortic incompetence and aneurysm of the ascending aorta. *J Thorac Cardiovasc Surg* 1992;103:617-21;discussion 622.
2. de Kerchove L, Boodhwani M, Glineur D, et al. Effects of preoperative aortic insufficiency on outcome after aortic valve-sparing surgery. *Circulation* 2009;120:S120-6.

Cite this article as: de Kerchove L, Mosala Nezhad Z, Boodhwani M, El Khoury G. How to perform valve sparing reimplantation in a tricuspid aortic valve. *Ann Cardiothorac Surg* 2013;2(1):105-112. doi: 10.3978/j.issn.2225-319X.2013.01.16

Minimally invasive valve sparing mitral valve repair—the loop technique—how we do it

Stephan Jacobs, Simon H. Sündermann

Division of Cardiovascular Surgery, University Hospital Zurich, Zurich, Switzerland

Introduction

Mitral valve reconstruction (MVR) is the gold standard therapy for the treatment of mitral regurgitation (MR) today (1). There is currently no reasonable alternative to surgery which is curative and results in the prevention of subsequent heart failure (2). MVR has been demonstrated to be superior to MV replacement with improved post-operative survival rates and preserved left ventricular function (3-5).

The MV is a complex structure made up of five different components: the mitral annulus, the anterior and posterior leaflets, the chordae tendineae, the papillary muscles and the left ventricle. A complex mechanism underlies the systolic and diastolic function of the MV. The two highest prevalence entities are primary (degenerative) and secondary (functional) MR. In primary MR, elongation or rupture of chordae tendineae and/or excessive tissue leads to repulsing or prolapsing of the leaflet into the atrium during systole with resulting insufficiency. Underlying pathologies are fibroelastic deficiency or myxomatous proliferation of the leaflet tissue as seen in Barlow's disease. In secondary MR, ischemic or idiopathic cardiomyopathy leads to alterations of the ventricular geometry, the subvalvular apparatus and of the mitral annular geometry leading to MR. The goal of a mitral valve repair procedure follows two fundamental principles: to restore a sufficient surface of leaflet coaptation and correct annular dilatation. Different techniques are used to repair the mitral valve: the "French correction" introduced in 1983 with resection of redundant tissue, chordal transfer, chordal shortening and remodelling annuloplasty (6), edge-to-edge repair, papillary muscle shortening, leaflet reduction plasty, and others (7-10).

The paradigm of 'respect rather than resect' tissue has emerged in recent years. Respecting this paradigm, the 'loop technique', where polytetrafluoroethylene (PTFE) chords are anchored into the tip of the papillary muscle and 'loops' are attached to the free edge mimicking a chordal fan (11,12), was developed.

In this article we will focus on minimally invasive repair

of primary mitral valve insufficiency due to prolapse of P2 using the "loop technique" without leaflet resection.

Surgical technique

Surgical access

The patient is positioned in a supine position with the right thorax slightly elevated (around 40°). Cardiopulmonary bypass is initiated via the right femoral vein and artery, after administration of heparin through a 3 to 4 cm incision in the right groin. The venous cannula is advanced into the junction between right atrium and superior vena cava under echocardiographic control. The arterial cannula is placed a few centimetres into the femoral artery.

Access to the intra-thoracic cavity is gained by a right lateral thoracotomy through the 4th intercostal space. A soft tissue retractor is placed into the access site to retain soft tissue from the visual field. Lungs have to be disconnected from the respirator for adequate exposure of the thoracic cavity and the left atrium (LA).

A camera port is placed in the second intercostal space lateral to the mid-clavicular line followed by insertion of the camera. In addition, CO₂-insufflation is initiated to improve de-airing at the end of the procedure. The transthoracic "Chitwood" clamp is used for cross clamping of the aorta and is introduced through an extra incision medial to the anterior axillary line. A strong retraction suture is placed deep into the inter-atrial groove to lift up the LA and is pulled through the thoracic wall close to the sternal bone but with a safe distance to the internal mammary artery (IMA). The same incision is used for introduction of the atrial roof retractor. The whole setup is illustrated in *Figures 1-4*.

Aortic clamping and delivery of cardioplegia

The pericardium is opened above the phrenic nerve, which must be identified. A stay suture is placed in the ascending aorta after blunt dissection with the stiff head of the

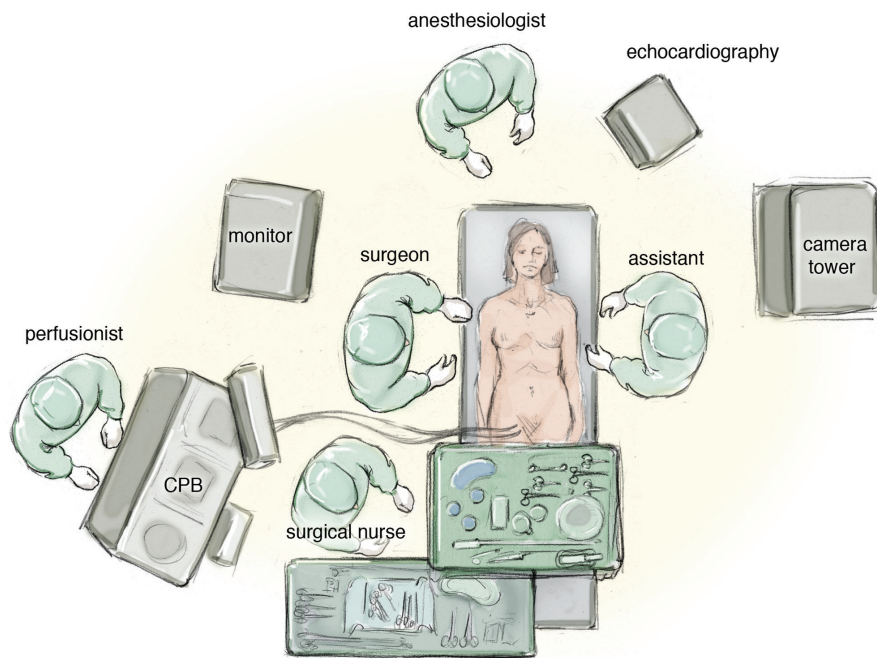


Figure 1 OR Setup.

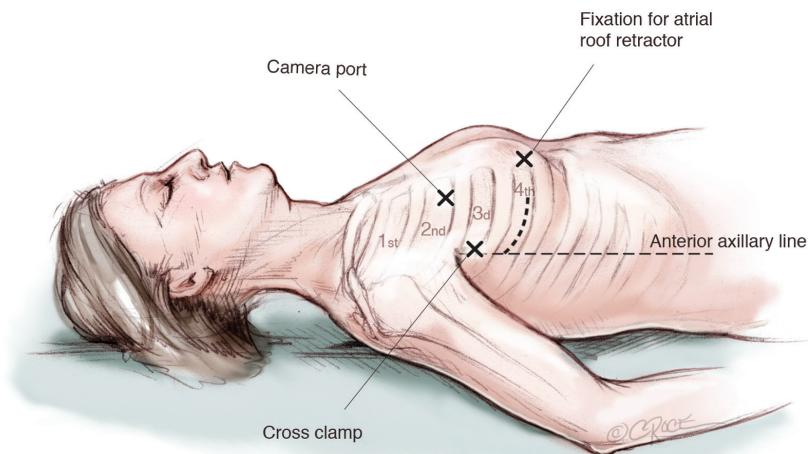


Figure 2 Chest wall landmarks before any incisions are made.

suction. A root-cannula is positioned and held in place with a tourniquet. The suction is placed below the aorta to lift it up around one centimetre to have space for the cross-clamp. The “Chitwood” cross-clamp is positioned around the aorta and administration of crystalloid Bretschneider’s cardioplegia follows after cross-clamping (*Figure 5*).

Atrial access

The LA is opened from the beginning at the height of the

pulmonary vein with a distance of around 4 mm to prevent constraining of the pulmonary vein when closing the atrium after the repair. The incision is extended up to one centimetre away from the superior vena cava and midway between the pulmonary vein and the inferior vena cava (*Figure 6*).

Maximal exposure of the MV is obtained using an atrial roof retractor. The size of the roof blade is chosen according to the size of the LA. If the exposure remains suboptimal, then the LA incision can be enlarged and/or another intercostal space is selected. A permanent pump-

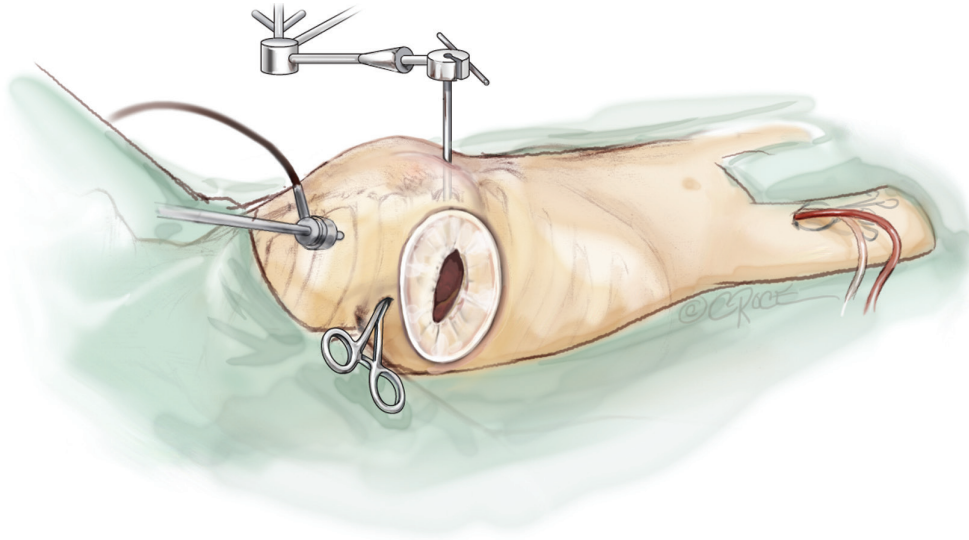


Figure 3 Incision with soft-tissue retractor, transthoracic Chitwood clamp, Camera with CO₂ supply and arm for the atrial roof retractor.

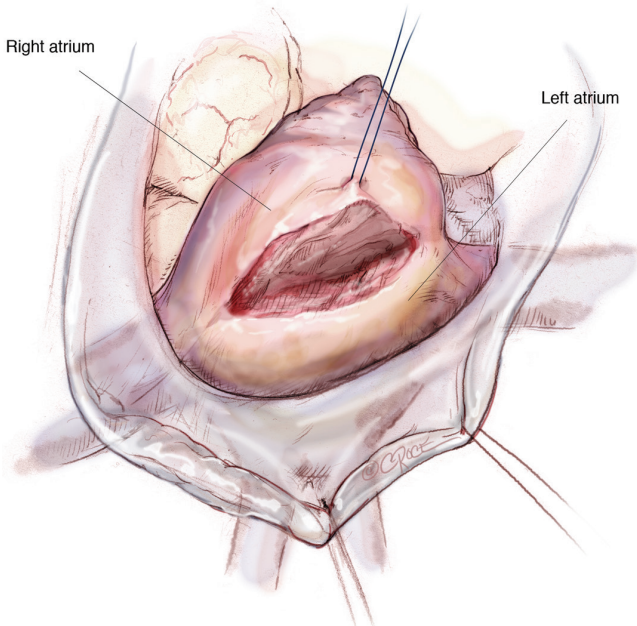


Figure 4 Pericardial incision site after putting two pericardial sutures and a suture in the epicardial fat above the interatrial groove.

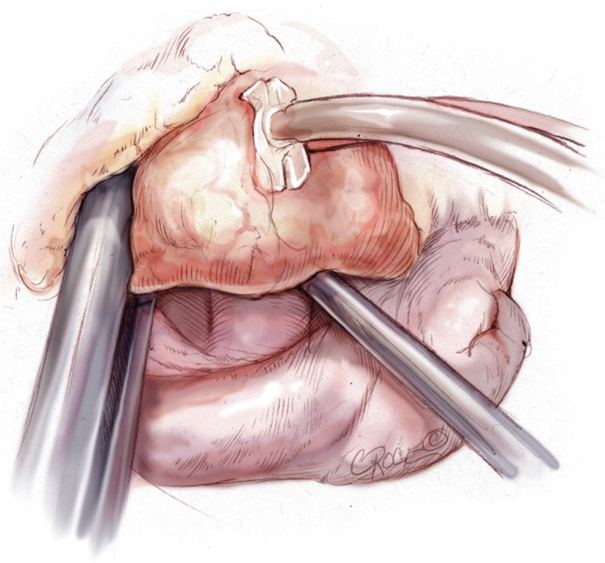


Figure 5 Cardioplegia insertion and cross clamp. Below the aorta, where suction is placed.

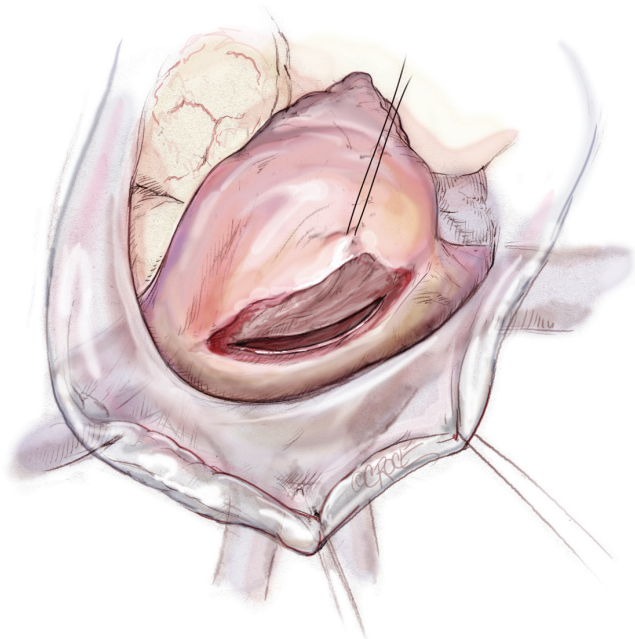

Figure 6 Left atriotomy to expose the mitral valve.

suction is positioned in the pulmonary veins to have a dry operative field.

Mitral valve repair

Mitral valve analysis

Nerve hooks are used to examine the segments of the anterior and posterior leaflets and the subvalvular apparatus (*Figure 7*). The preoperative echocardiographic diagnosis should be confirmed during this manoeuvre, including differentiation of primary and secondary pathology as well as the location of these findings. The analysis should be carried out in an organized manner, using P1 as reference point in most cases. The repair strategy should be clarified now. The primary aim is to correct any leaflet pathology, followed by implantation of a complete annuloplasty ring.

Neo-chord implantation

To restore the P2 prolapse, the loop technique is used and is the favoured repair technique in our and many other centres. A crucial step is to determine the required length of the loops. To determine the length of the neo-chords, the distance from the body of the papillary muscle to the free edge of a non-prolapsing portion of the MV leaflet is measured using a custom-made caliper (*Figures 8*).

The loops are commercially available (Santec Medical,

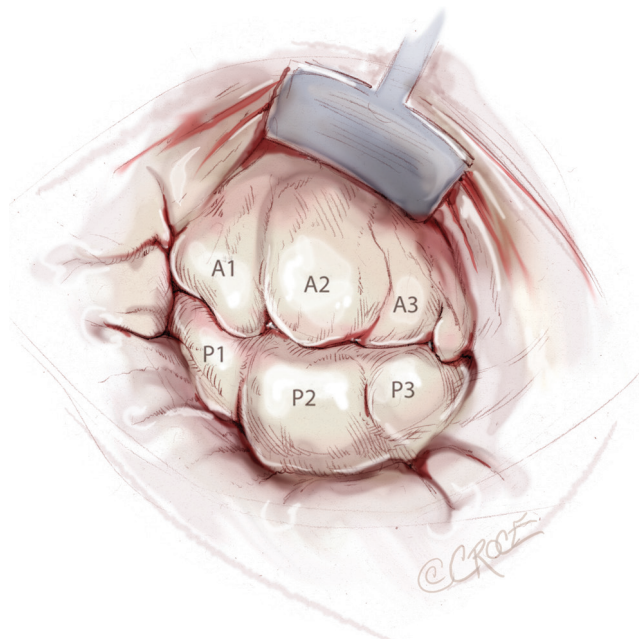


Figure 7 Segments of the mitral valve. A, anterior; P, posterior.

Grosswallstadt, Germany). A so-called “loop” consists of a central pledget with four premade single loops, ranging from 10 to 26 mm in length. The needles of the sutures originating from the pledget are passed through the tip of the respective papillary muscle and tied over a second pledget. The free loops are fixed to the prolapsing leaflet segment using 5/0 Gore-Tex sutures, placing the knot on the ventricular surface of the leaflet whenever possible (*Figure 9*).

Annuloplasty ring implantation

For restoring and remodelling the shape of the annulus, a prosthetic ring is implanted. Regardless of the type of ring, ring selection is based on the measurement of the anterior leaflet, first with regards to the basal portion (trigone to trigone), then with regards to the anterior-posterior diameter of the anterior leaflet (*Figure 10*), which should also be determined by transesophageal echocardiography preoperatively.

The annuloplasty ring is implanted by placing 12 to 15 2-0 mattress sutures through the mitral annulus and through the ring afterwards. Two issues are of highest importance. First, the sutures have to be placed properly in the fibrous annulus to avoid ring dehiscence. Secondly, the sutures have to be placed properly in the prosthetic ring with the same distances as in the ring to avoid annular distortion. The sutures are knotted outside the thoracic

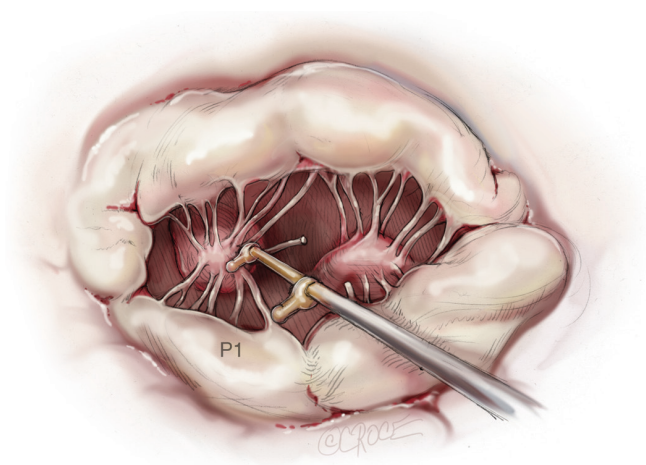


Figure 8 Estimation of necessary chordal length with a caliper.

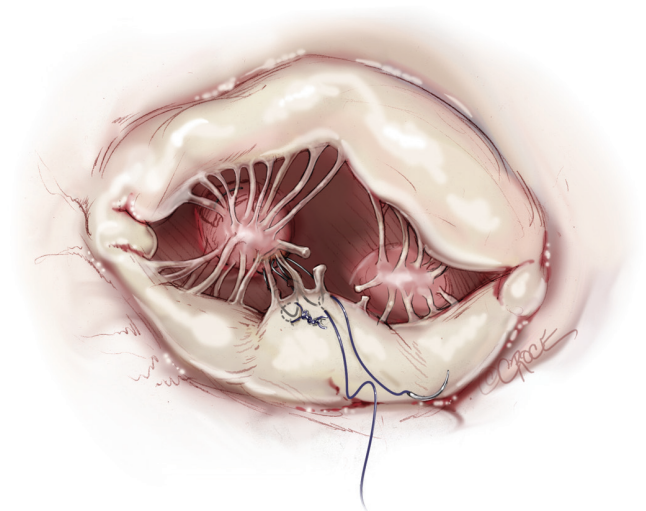


Figure 9 Neo-chordae insertion and fixation at the free margin of P2.

cavity and placed at the prosthetic ring with the help of a knot pusher (*Figure 11*).

Successful (or unsuccessful) repair is tested with the saline test by filling the left ventricle with saline until a certain pressure is achieved to test for sufficient closure of the valve. If there is no backflow from the ventricle and the mitral valve “smiles” at the surgeon, a successful repair can be assumed (*Figure 11*).

Atrial closure

The atrial roof retractor is released and the LA is closed

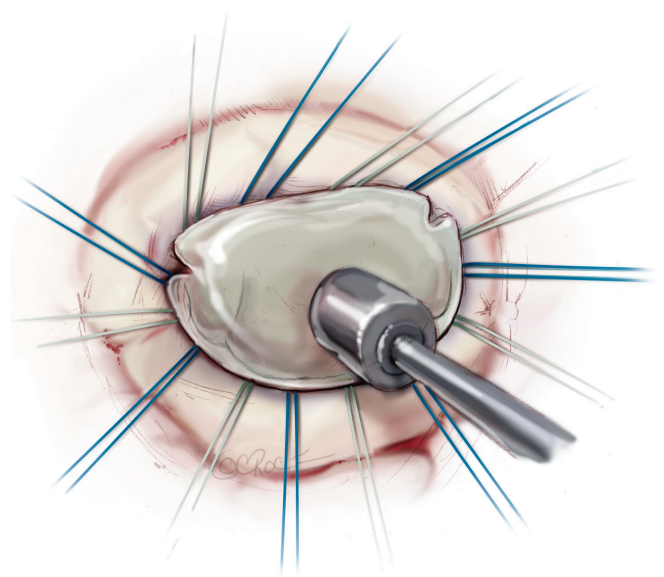


Figure 10 Measurement of the necessary annuloplasty ring size after implantation of ring sutures (green).

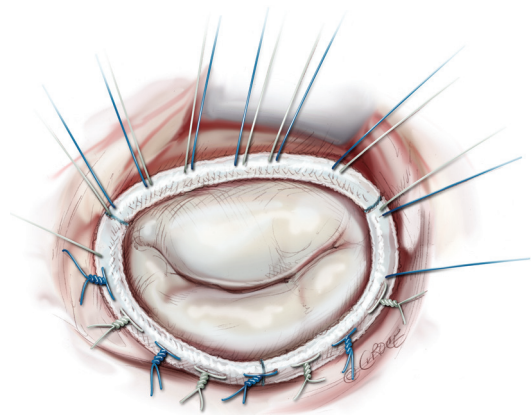


Figure 11 Implanted annuloplasty ring with the sutures partially knotted.

with standard 3-0 polypropylene suture starting from both sides of the atriotomy (*Figure 12*). Before final knotting, de-airing is performed by filling the heart while simultaneously inflating both lungs. Knotting is again performed with the help of the knot pusher. CO₂ insufflation can be terminated at this point in time.

Final steps

A temporary pacemaker wire is placed at the right ventricle

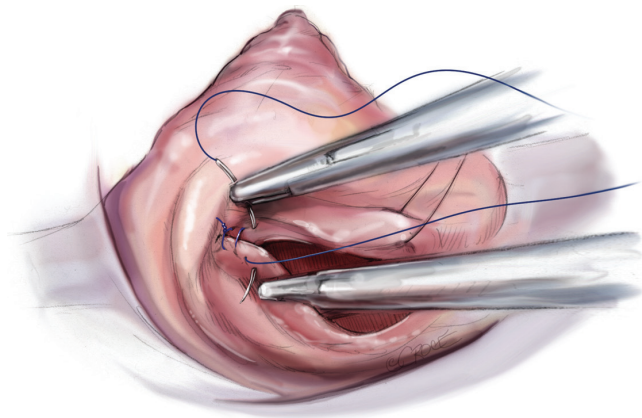


Figure 12 Left atriotomy closure.

before declamping because the beating heart would significantly limit the access. Subsequently, the aortic root vent is released and the purse string suture is closed. The aortic root clamp is released and the patient is re-warmed. Ventilation is recommenced and the extra-corporal bypass is reduced to 50% flow. Transoesophageal echocardiogram assesses the immediate success or failure of the procedure. To exclude impairment of the circumflex artery, flow in the circumflex artery should be verified and lateral wall motion should be monitored and needs to achieve a comparable level as seen preoperatively. For careful inspection of the suture lines, bypass flow is returned to 100% and ventilation is stopped to have good access to the thoracic cavity again. Afterwards, the pericardium is closed using the pericardial retraction sutures.

A chest tube is inserted through the initial camera port, any other access ports are closed and protamine is given. Extra-corporal weaning is followed by closure of the intercostal space and the lateral thoracotomy (*Figure 11*).

Transesophageal echocardiography should be performed now to determine the immediate result of the procedure. A finding of more than mild MR should lead the surgeon, except in certain high-risk patients, to perform valve re-exploration to identify and correct any source of potential residual regurgitation.

Summary

To date, neo-chord implantation along with annuloplasty is a preferred technique in many centres to treat primary mitral valve insufficiency despite the fact that there is no clear advantage in terms of mortality or durability of the

repair compared to resection of prolapsing segments. Surgical mitral valve repair offers a highly effective and safe treatment for patients with MR, even in those patients who require re-operative procedures. Minimally invasive technique shows similar reconstructive results to open repair, but the cosmetic results lead to a higher patient satisfaction and less blood transfusion. An explanation might be that implantation of chords is more straightforward especially when the operation is performed via a minimally-invasive and video-assisted approach. Additionally, this technique permits implantation of larger annuloplasty-rings and a larger area of coaptation can be achieved (13). Results show that the improvement of the techniques lead to better outcomes in terms of mortality and to a decrease in reoperation rates compared to the initial techniques.

Surgery can result in a complete correction of the MR and normalization of valve morphology, and thus represents the only curative treatment strategy for patients with mitral valve regurgitation. It therefore represents the current gold standard for the treatment of MVR.

Acknowledgements

We want to thank Stefan Schwyter for his tremendous efforts in preparing the medical illustrations.

Disclosure: The authors declare no conflict of interest.

References

1. Seeburger J, Borger MA, Doll N, et al. Comparison of outcomes of minimally invasive mitral valve surgery for posterior, anterior and bileaflet prolapse. *Eur J Cardiothorac Surg* 2009;36:532-8.
2. Carabello BA. The current therapy for mitral regurgitation. *J Am Coll Cardiol* 2008;52:319-26.
3. Jokinen JJ, Hippeläinen MJ, Pitkänen OA, et al. Mitral valve replacement versus repair: propensity-adjusted survival and quality-of-life analysis. *Ann Thorac Surg* 2007;84:451-8.
4. Goldstone AB, Atluri P, Szeto WY, et al. Minimally invasive approach provides at least equivalent results for surgical correction of mitral regurgitation: a propensity-matched comparison. *J Thorac Cardiovasc Surg* 2013;145:748-56.
5. Markar SR, Sadat U, Edmonds L, et al. Mitral valve repair versus replacement in the elderly population. *J Heart Valve Dis* 2011;20:265-71.
6. Carpentier A. Cardiac valve surgery--the "French

- correction". *J Thorac Cardiovasc Surg* 1983;86:323-37.
7. Maisano F, Torracca L, Oppizzi M, et al. The edge-to-edge technique: a simplified method to correct mitral insufficiency. *Eur J Cardiothorac Surg* 1998;13:240-5; discussion 245-6.
 8. Dreyfus GD, Bahrami T, Alayle N, et al. Repair of anterior leaflet prolapse by papillary muscle repositioning: a new surgical option. *Ann Thorac Surg* 2001;71:1464-70.
 9. Rankin JS, Sharma MK, Teague SM, et al. A new approach to mitral valve repair for rheumatic disease: preliminary study. *J Heart Valve Dis* 2008;17:614-9.
 10. Chu MW, Gersch KA, Rodriguez E, et al. Robotic "haircut" mitral valve repair: posterior leaflet-plasty. *Ann Thorac Surg* 2008;85:1460-2.
 11. von Oppell UO, Mohr FW. Chordal replacement for both minimally invasive and conventional mitral valve surgery using premeasured Gore-Tex loops. *Ann Thorac Surg* 2000;70:2166-8.
 12. Falk V, Seeburger J, Czesla M, et al. How does the use of polytetrafluoroethylene neochordae for posterior mitral valve prolapse (loop technique) compare with leaflet resection? A prospective randomized trial. *J Thorac Cardiovasc Surg* 2008;136:1205; discussion 1205-6.
 13. Lange R, Guenther T, Noebauer C, et al. Chordal replacement versus quadrangular resection for repair of isolated posterior mitral leaflet prolapse. *Ann Thorac Surg* 2010;89:1163-70; discussion 1170.

Cite this article as: Jacobs S, Sündermann SH. Minimally invasive valve sparing mitral valve repair—the loop technique—how we do it. *Ann Cardiothorac Surg* 2013;2(6):818-824. doi: 10.3978/j.issn.2225-319X.2013.11.09

Minimally invasive aortic valve replacement: the “Miami Method”

Joseph Lamelas

Division of Cardiothoracic Surgery, Mount Sinai Heart Institute, Mount Sinai Medical Center, Miami Beach, FL 33140, USA

Introduction

Aortic stenosis is the most common valvular disorder in the Western world, with a prevalence of 2% in patients over the age of 65 years to more than 4% in those greater than 85 years old (1). While disease progression is gradual, in asymptomatic patients with a peak systolic velocity ≥ 4 m/s, the probability of remaining free of cardiac events, including cardiac death or aortic valve surgery, is 80% at 1 year, 63% at 2 years, and 25% at 5 years (2).

Aortic valve replacement (AVR) remains the standard of care in symptomatic severe aortic stenosis and is also recommended for asymptomatic patients with left ventricular dysfunction or in those undergoing other cardiac surgery (3). However, studies have shown that up to 40% of elderly patients over the age of 70 are denied aortic valve surgery based on age and higher risk profiles (4). Advances in transcatheter aortic valve implantation have provided an alternative to inoperable high-risk aortic stenosis patients, with 1-year mortality rates reduced by at least a third compared to standard medical therapy (5-8).

First performed by Navia (9) and Cohn *et al.* (10), minimally invasive valve surgery has been shown to reduce morbidity (10-16) and decrease mortality in high-risk population such as the elderly and the obese, when compared with standard median sternotomy surgery (17,18). Herein, we describe our approach of minimally invasive AVR performed via a right anterior thoracotomy approach.

Operative technique

Preparation

A Swan-Ganz catheter and radial arterial line are inserted.

Exposition

Patients are placed in the supine position and undergo anesthetic induction and intubation with a single lumen endotracheal tube. A transesophageal echocardiography (TEE) probe is placed and a thorough echocardiographic

evaluation is performed.

Operation

A femoral platform is the preferred method utilized to establish cardiopulmonary bypass. A 2-3 cm longitudinal incision is made above the left inguinal crease. Limited dissection and identification of the lymphatics is performed in order to decrease the risk of groin complications. A 5-0 Prolene (Ethicon, Cincinnati, OH) purse string suture is placed on the femoral artery and vein. After heparinization, a Seldinger technique is utilized to cannulate the femoral vessels. The femoral artery is cannulated with a 15-19 French arterial cannula (Biomedicus, Medtronic, Minneapolis) and the femoral vein is cannulated with a 25 French venous cannula (Biomedicus, Medtronic, Minneapolis). With the aid of TEE guidance, the venous cannula is placed in the superior vena cava. This is essential to assure adequate drainage (*Figure 1*). Routine pre-operative computed tomography (CT) screening for aortic pathology or vascular disease is not performed. If peripheral vascular disease is suspected at the time of femoral cannulation or grade 4 or 5 atherosclerotic disease is evident by TEE, axillary artery cannulation or central aortic cannulation is performed.

Cardiopulmonary bypass is initiated using a closed membrane oxygenator and a roller pump. The patient's temperature is allowed to drift. Venous drainage is augmented with vacuum assistance applying negative pressures of 30-70 mmHg as needed to decompress the right heart.

A 5-6 cm transverse incision is then made over the right 2nd intercostal space. A basic external landmark is to locate the midway point of an imaginary line drawn from the suprasternal notch to the lowest portion of the body of the sternum. The xiphoid is not included. The incision should be made from this point laterally (*Figure 2*). The right internal mammary and vein are ligated and transected. The cartilage of the inferior rib is always transected and later reattached. Avoiding transection and stretching

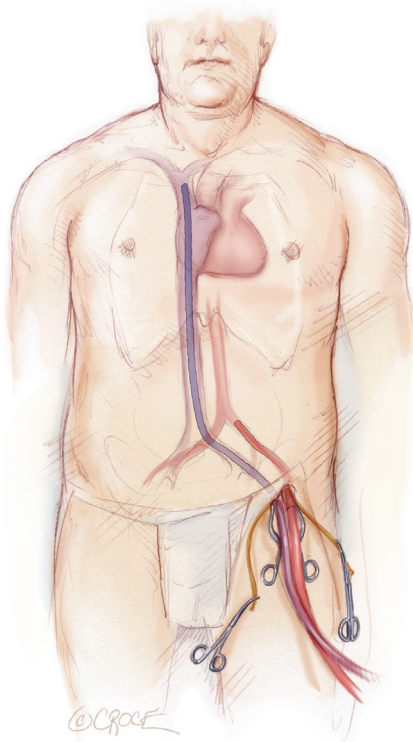


Figure 1 The femoral artery was cannulated with a 15-19 French arterial cannula and the femoral vein is cannulated with a 25 French venous cannula.

the interspace will create a large chest wall defect and potentially paradoxical chest wall motion (*Figure 3*). A soft tissue retractor (Alexis Wound Retractor, Applied Medical, Rancho Santa Margarita, CA, USA) and an intercostal rib spreader (Intercostal Rib Spreader, Miami Instruments, Miami, FL, USA) provide additional exposure. The pericardium is opened over the aorta and extended down towards the inferior vena cava (IVC). The pericardium is opened superiorly following the greater curvature of the aorta. The pericardium is not opened up to its attachment to the aorta as this will limit the ability to place stay sutures. Carefully planned placement of pericardial stay sutures is the key to obtaining adequate exposure of the aorta and valve. The sutures are placed on the pericardium over the pulmonary artery, aortopulmonary window and above the aorta. These sutures are crucial to provide the necessary exposure. Sutures are continually placed to further pull the aorta into the operative field. A CT scan of the chest to determine whether the aorta lies to the left of the midline is not performed nor necessary. This finding is not a contraindication to perform this procedure.

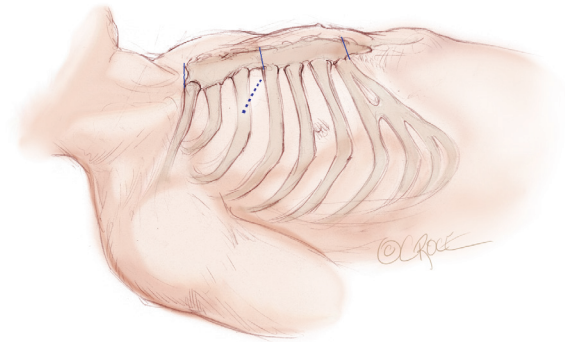


Figure 2 A 5-6 cm transverse incision is made over the right 2nd intercostal space.

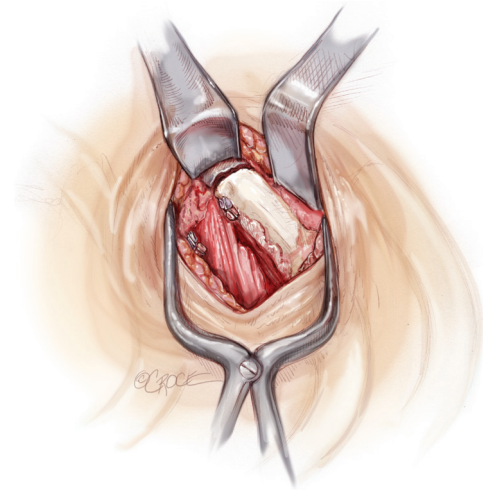


Figure 3 Accessing the interspace. The cartilage of the inferior rib is always transected and later reattached. A soft tissue retractor and an intercostal rib spreader provide additional exposure.

A retrograde cardioplegia cannula (Edwards Lifesciences, Minneapolis) is inserted directly through the right atrial appendage. This will facilitate exposure of the aorta when the appendage is retracted. If a retrograde cardioplegia cannula is not utilized, a snare is created with a number 2 silk and a red rubber catheter. This is passed through the chest tube incision and the appendage snared and pulled downward. A left ventricular vent (Ventricular Vent, Medtronic, Minneapolis, MN, USA) is then placed via the right superior pulmonary vein (*Figure 4*). Both are passed through the chest tube incision. This allows for a smaller incision to be performed and also decreases clutter in the operative field (*Figure 5*). Trans-incisional direct aortic cross clamping is then performed utilizing a flexible and

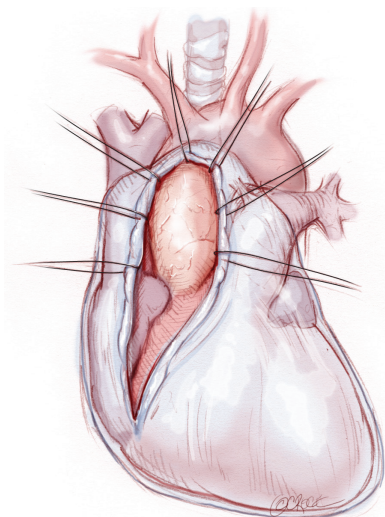


Figure 4 The pericardium is opened over the aorta and extended down towards the inferior vena cava. The pericardium is opened superiorly following the greater curvature of the aorta.

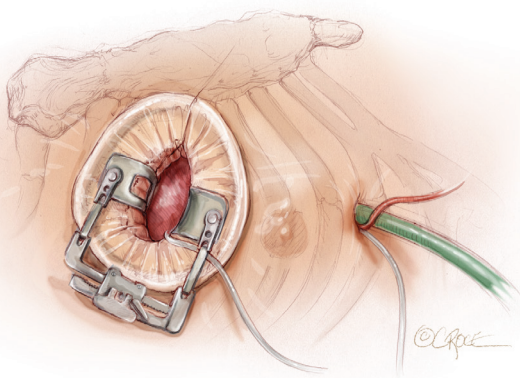


Figure 5 Left ventricular vent placement and right atrial appendage retraction and exteriorization of left ventricular vent.

retractable shaft cross clamp (Cygnet, Vitalitec, Plymouth, MA). Dissection between the aorta and pulmonary artery is not necessary and is a potential source of bleeding. One dose of antegrade modified Del Nido cardioplegia solution is given to establish electromechanical arrest of the heart (*Figure 6*). This 4:1 blood to modified Del Nido cardioplegia has allowed at least 90 minutes of myocardial protection before any additional doses are required. If retrograde cardioplegia cannulation is not possible or is not considered necessary and additional doses of cardioplegia are needed, this is delivered directly into the coronary ostia. Carbon dioxide is infused into the operative field at 2 L/min (*Figure 7*). A transverse aortotomy is made at the

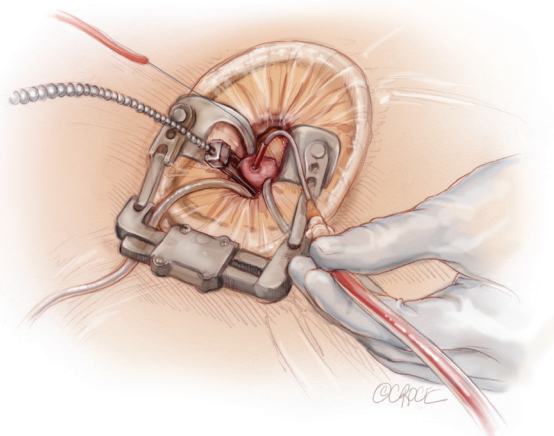


Figure 6 Direct trans-incisional aortic cross-clamping is performed utilizing a flexible and retractable shaft cross clamp.

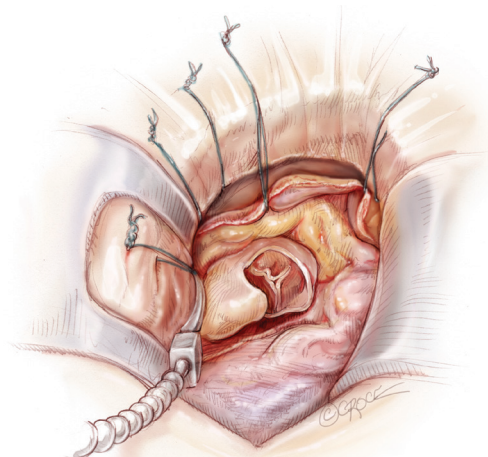


Figure 7 A transverse aortotomy is made at the level of the fat pad on the aorta.

level of the fat pad on the aorta. It is important to make the aortotomy at least 2 cm from the cross clamp in order to facilitate closure. A silk suture is placed on the superior aspect of the aorta to provide retraction and exposure of the aortic valve (*Figure 8*). Thereafter, sutures are placed on the commissures to provide additional retraction and exposure of the aortic valve. Resection of the valve leaflets and debridement of the annulus are carried out under direct vision utilizing standard techniques. All procedures are performed with specially designed long shafted minimally invasive instruments (Vitalitec, Plymouth, MA, USA). A specially designed aortic wall retractor (Aortic Cuff, Miami Instruments, Miami, FL, USA) is inserted and fixed in place

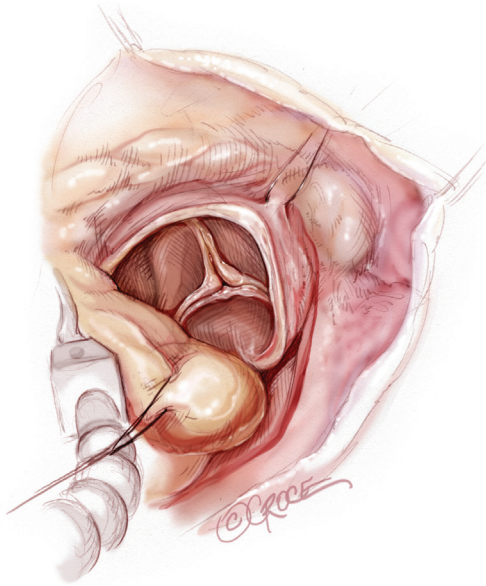


Figure 8 Facilitating exposure of the aortic valve.

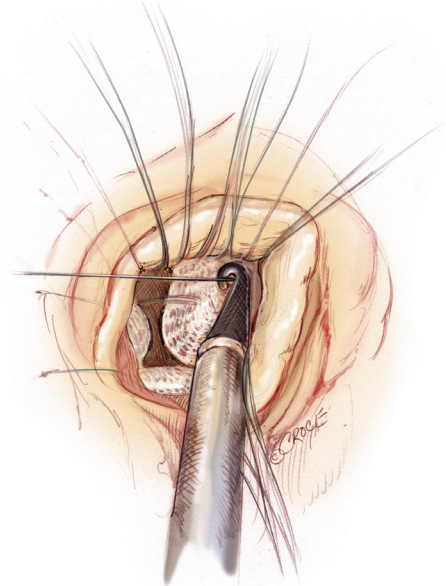


Figure 10 A knot setter is utilized for tying the valve sutures.

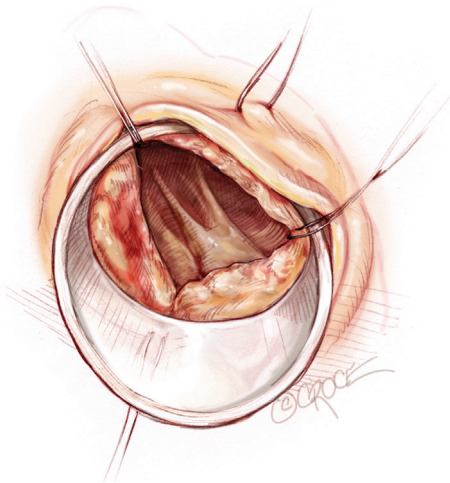


Figure 9 A specially designed aortic wall retractor is inserted and fixed in place with the suture supporting the commissure between the left and non-coronary cusp. This facilitates visualization of the annulus and suture placement.

with the suture supporting the commissure between the left and non-coronary cusp. This facilitates visualization of the annulus and suture placement (*Figure 9*). The aortic wall retractor is removed after the valve sutures are all placed. The valve is sized after suture placement. After the valve is delivered onto the annulus, the three commissural valve sutures are initially tied. A knot setter (Knot Setter, Miami Instruments, Miami, FL, USA) is utilized for tying the valve

sutures. Coordination and practice with an assistant will allow tying five knots with each suture in approximately 8 seconds (*Figure 10*). After closure of the aortotomy, before removing the cross clamp, a ventricular pacing wire was placed on the inferior wall of the right ventricle. This cannot be performed once the clamp is released.

In patients undergoing AVR, with previous coronary artery bypass surgery and a patent left internal mammary graft, we use moderate hypothermia (28 °C) with one induction dose of antegrade modified Del Nido cardioplegia. Thereafter, retrograde cardioplegia is delivered in a continuous fashion throughout the procedure. We do not identify nor dissect the left internal mammary artery (LIMA) pedicle. In the setting of a patent LIMA with a partially patent native vessel, a constant stream of blood return from the left main will obscure the operative field. In these cases we place a #10 French red rubber catheter directly into the left main connected to a pump suction to aspirate the blood.

Completion

TEE is utilized to assess the post-operative results as well as removal of air from the heart. This is performed with a needle placed in the root of the aorta (*Figure 11*). The heart is not directly manipulated during air removal maneuvers. If needed, external compression of the chest wall is performed to agitate the air bubbles. After discontinuing

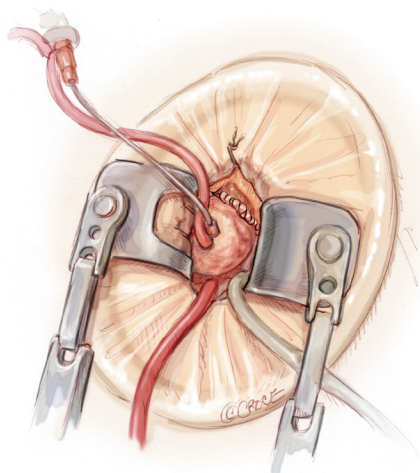


Figure 11 Aortotomy closure and air removal.

cardiopulmonary bypass and administering one half of the protamine, the femoral venous cannula is removed. When the entire dose of protamine is given and the patient is hemodynamically stable, the arterial cannula is removed and the purse string suture tied. A Blake chest tube (Ethicon, Cincinnati, OH, USA) is positioned in the posterior pleural space and another in the pericardial space. For pain relief, an On-Q pain system (I-Flow, Kimberly Clark Healthcare Company, Lake Forest, CA, USA) with two catheters is placed freely into the pleural space and 0.25% bupivacaine is administered for 72 hours. The chest tubes and catheters along with the pacing wire are passed through the chest tube incision (*Figure 12*). The pericardium is usually not closed, although if possible, it should be considered. Closing the pericardium will limit adhesions of the lung to the heart for future interventions. Thereafter, a large pericostal suture is placed in a figure of eight fashion to approximate the ribs. The transected rib is re-attached to the sternum with a number 2-0 Vicryl suture placed in a figure of eight fashion as well. The thoracotomy incision is closed in the routine fashion.

Comments

Clinical results

At our institution from November 2008 to April 2014, we have performed 3,738 cardiac surgeries, of which 2,344 were performed by a single surgeon utilizing a minimally invasive approach. During this time, 857 isolated primary AVRs were performed. This did not include minimally

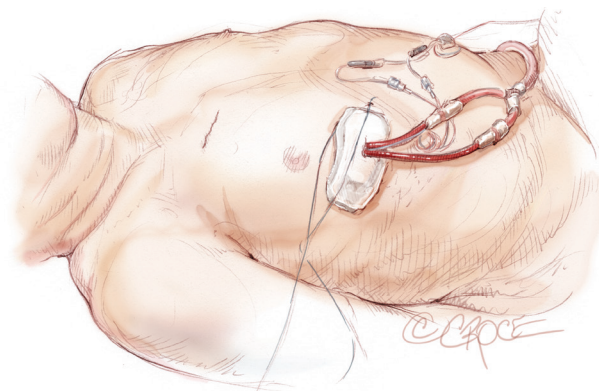


Figure 12 Skin closure, chest tube placement and pain management system.

invasive double valve procedures nor concomitant aortic valve and ascending aortic/hemi arch surgeries. The mean age of these patients was 72 ± 12 years, and there were 509 (59.4%) males and 348 (40.6%) females.

The median aortic cross clamp and cardiopulmonary bypass times were 83 minutes [interquartile range (IQR), 71-100] and 110 minutes (IQR, 95-132), respectively. Cerebrovascular accidents were noted in 8 (0.93%) patients. The median hospital length of stay was 6 days (IQR, 4-8), and the 30-day mortality was 14 (1.63%).

Advantages

Cardiac surgeons should pursue and perform mini thoracotomy, minimally invasive aortic valve surgery in order to offer a “true” minimally invasive platform. Avoiding a sternal splitting procedure decreases the potential of bleeding as well as the need for transfusions with its associated complications. Other advantages include improved chest wall stability which allows increased mobility as well as an accelerated recovery. This particular procedure and method is very competitive to transcatheter procedures in high risk, elderly, frail and obese patients. To my knowledge, to date, there are no robust studies comparing this particular approach to transcatheter AVR's, whether it be randomized or case-matched. Furthermore, expanded applications of this minimally invasive method addressing the ascending aorta as well as multivalve pathology will allow an extensive subset of patients to be treated. We will be approaching the panacea of minimally invasive aortic valve surgery once technical expertise and proficiency is further advanced with sutureless or rapid

deployment valves in combination with a mini thoracotomy approach.

Caveats

This method has definitive advantages, although there is a learning curve. There is a learning curve associated with any cardiac surgical procedure, despite what experienced surgeons now consider routine and simple. In order to overcome the conceptual “learning curve”, surgeons need to consider this the standard of care in isolated AVR surgery and make it reality. This will provide a clinical benefit to our patients, as well as advance our specialty. Adoption rates are low due to complacency with conventional sternotomy techniques and the rapidly changing health care environment. This should not deter cardiac surgeons from providing advanced minimally invasive techniques to our patients. Whether an AVR is performed via a sternotomy or a minithoracotomy, the size of the aortic annulus does not change. One needs to become comfortable working in a smaller space and become proficient with the use of long shafted instruments. Developing additional techniques and maneuvers within ones comfort zone will provide the necessary exposure. The devoted surgeon interested in developing a minimally invasive program needs to experience live case demonstrations, review videos of the procedure, read technical manuscripts, consider being proctored and finally begin the journey!

Acknowledgements

Dr. Chris Mihos and Dr. Andres Pineda for their contribution to this publication.

Disclosure: Dr. Joseph Lamelas receives honoraria for lectures and courses with Medtronic, St. Jude and On-Q and is a partner in Miami Instruments. All surgeries were performed by a single surgeon, Dr. Joseph Lamelas.

References

1. Stewart BF, Siscovick D, Lind BK, et al. Clinical factors associated with calcific aortic valve disease. Cardiovascular Health Study. J Am Coll Cardiol 1997;29:630-4.
2. Pellikka PA, Sarano ME, Nishimura RA, et al. Outcome of 622 adults with asymptomatic, hemodynamically significant aortic stenosis during prolonged follow-up. Circulation 2005;111:3290-5.
3. Nishimura RA, Otto CM, Bonow RO, et al. 2014 AHA/ACC guideline for the management of patients with valvular heart disease: a report of the American College of Cardiology/American Heart Association Task Force on Practice Guidelines. J Am Coll Cardiol 2014;63:e57-185.
4. Bouma BJ, van den Brink RB, Zwinderman K, et al. Which elderly patients with severe aortic stenosis benefit from surgical treatment? An aid to clinical decision making. J Heart Valve Dis 2004;13:374-81.
5. Eltchaninoff H, Prat A, Gilard M, et al. Transcatheter aortic valve implantation: early results of the FRANCE (FRench Aortic National CoreValve and Edwards) registry. Eur Heart J 2011;32:191-7.
6. Leon MB, Smith CR, Mack M, et al. Transcatheter aortic-valve implantation for aortic stenosis in patients who cannot undergo surgery. N Engl J Med 2010;363:1597-607.
7. Rodés-Cabau J, Webb JG, Cheung A, et al. Transcatheter aortic valve implantation for the treatment of severe symptomatic aortic stenosis in patients at very high or prohibitive surgical risk: acute and late outcomes of the multicenter Canadian experience. J Am Coll Cardiol 2010;55:1080-90.
8. Cribier A, Eltchaninoff H, Bash A, et al. Percutaneous transcatheter implantation of an aortic valve prosthesis for calcific aortic stenosis: first human case description. Circulation 2002;106:3006-8.
9. Navia JL, Cosgrove DM 3rd. Minimally invasive mitral valve operations. Ann Thorac Surg 1996;62:1542-4.
10. Cohn LH, Adams DH, Couper GS, et al. Minimally invasive cardiac valve surgery improves patient satisfaction while reducing costs of cardiac valve replacement and repair. Ann Surg 1997;226:421-6; discussion 427-8.
11. Mihos CG, Santana O, Lamas GA, et al. Incidence of postoperative atrial fibrillation in patients undergoing minimally invasive versus median sternotomy valve surgery. J Thorac Cardiovasc Surg 2013;146:1436-41.
12. Valdez GD, Mihos CG, Santana O, et al. Incidence of postoperative acute kidney injury in patients with chronic kidney disease undergoing minimally invasive valve surgery. J Thorac Cardiovasc Surg 2013;146:1488-93.
13. Mihos CG, Santana O, Lamas GA, et al. Outcomes of right minithoracotomy mitral valve surgery in patients with previous sternotomy. Ann Thorac Surg 2011;91:1824-7.
14. Pineda AM, Santana O, Lamas GA, et al. Is a minimally invasive approach for re-operative aortic valve replacement

- superior to standard full re sternotomy? *Interact Cardiovasc Thorac Surg* 2012;15:248-52.
15. Santana O, Reyna J, Benjo AM, et al. Outcomes of minimally invasive valve surgery in patients with chronic obstructive pulmonary disease. *Eur J Cardiothorac Surg* 2012;42:648-52.
 16. Pineda AM, Santana O, Reyna J, et al. Outcomes of reoperative aortic valve replacement via right mini-thoracotomy versus median sternotomy. *J Heart Valve Dis* 2013;22:50-5.
 17. Lamelas J, Sarria A, Santana O, et al. Outcomes of minimally invasive valve surgery versus median sternotomy in patients age 75 years or greater. *Ann Thorac Surg* 2011;91:79-84.
 18. Santana O, Reyna J, Grana R, et al. Outcomes of minimally invasive valve surgery versus standard sternotomy in obese patients undergoing isolated valve surgery. *Ann Thorac Surg* 2011;91:406-10.

Cite this article as: Lamelas J. Minimally invasive aortic valve replacement: the “Miami Method”. *Ann Cardiothorac Surg* 2015;4(1):71-77. doi: 10.3978/j.issn.2225-319X.2014.12.10

Illustrated techniques for transapical aortic valve implantation

Anson Cheung¹, Kevin M. Lichtenstein²

¹Division of Cardiothoracic Surgery, St. Paul's Hospital, University of British Columbia, Vancouver, Canada; ²Brighton and Sussex Medical School, Brighton, East Sussex, United Kingdom

Introduction

Within the last decade, transcatheter aortic valve replacement (TAVR) has come from relative obscurity to become a procedure that is practiced at most major health centres worldwide and the technical details of this procedure have been described by many (1-4). The rapid adoption of TAVR in medical practice makes it one of the fastest therapeutic modalities incorporated and evaluated by randomized control trial (5). Transfemoral (TF-TAVR) retrograde and transapical (TA-TAVR) antegrade approaches were the most widely practiced. TA-TAVR is the preferred procedure where the peripheral access is limited due to size, calcification and tortuosity. TA-TAVR provides a more stable platform for TAVR, due to the more direct and shorter distance to the native aortic valve. Access via the subcalvian artery and ascending aorta are emerging to be viable alternatives. Procedural technique can be very important in high-risk patients and remains among the few modifiable factors. Therefore, it is worthwhile to describe the intricacies of the TA-TAVR approach, with the aid of photographs. The technique described is intended for transapical implantation of the SAPIEN transcatheter valve using the Ascendra delivery system (Edwards LifeSciences, Irvine, CA, USA)

Successful TA-TAVR is discussed in eight sequential steps: (I) Patient selection; (II) Preparation; (III) Imaging; (IV) Surgical access; (V) Balloon valvuloplasty (BAV); (VI) Positioning; (VII) Deployment; and (VIII) Surgical closure.

Preoperative management

Patient selection

Patient selection is the single most important step that can determine success or failure of TA-TAVR. It will be discussed in depth by other authors in this special issue.

Preparation

The patient is placed in the supine position and elevation

of the left chest is not routinely required. All electrical cardiogram leads and defibrillator pads are placed appropriately but out of the way of the anticipated fluoroscopy sites and allow access to the sternum and left thorax. Lines for continuous arterial blood pressure monitoring and oximetry are placed before the patient goes under a general anaesthetic and is intubated. TA-TAVR can be performed without general anaesthesia, however, very limited experience has been reported at the present time (6).

Early in the development of the procedure, the left lung was collapsed to allow for better visualization of the left ventricular apex. However, it has subsequently been found that the left lung rarely interferes with exposure of the ventricular apex. Lung isolation is no longer required. Pulmonary arterial catheter for continuous cardiac output monitoring is reserved for patients with poor ventricular function.

For precautionary reasons, an important part of the preparation process is the presence of perfusionist and a primed cardiopulmonary bypass circuit, in the event of hemodynamic instability and surgical misadventures.

Operative techniques

Imaging

In our initial experience, TA-TAVR was performed in the operating room using a portable C-arm fluoroscope. However, the image quality was found to be rather poor to the point where it was difficult to visualize the aortic valve. A greater quantity of dye injection at the aortic root was used to better define the native aortic valve (AV) and this was of some concern as a large dye load can be hazardous in patients with compromised renal function. Moreover, poor visualization can be a major causative factor for valve malpositioning, paravalvular regurgitation and embolization. With this in mind, it is strongly advised that TA-TAVI should only be undertaken in a hybrid operating room or catheterization laboratory with high-definition fluoroscopic equipments and multiple monitors. *Figure 1* demonstrates the layout of our

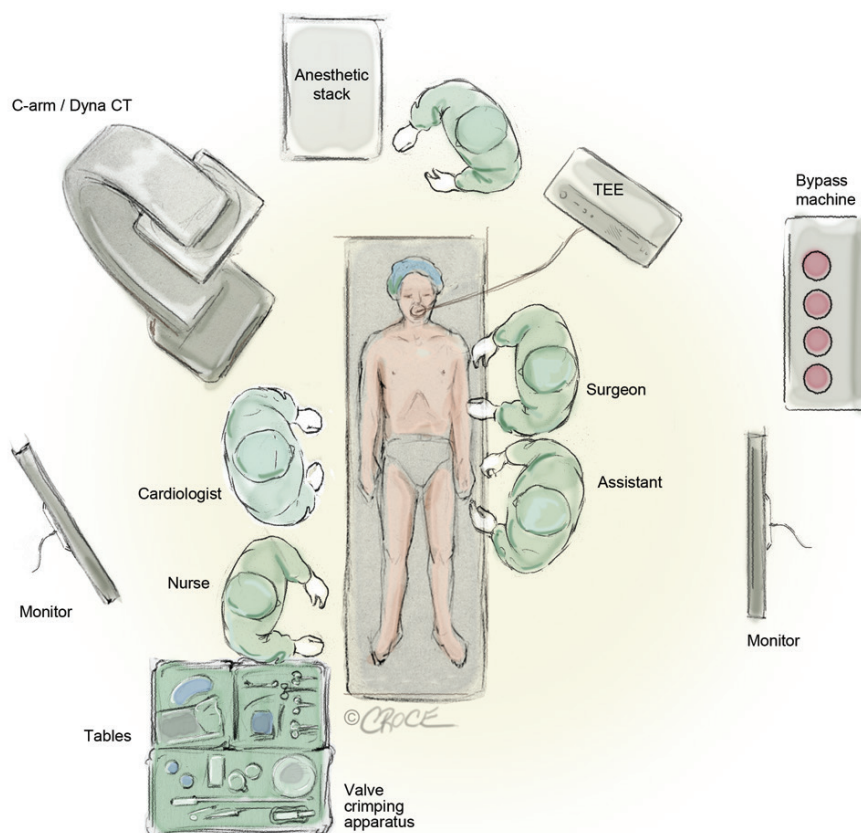


Figure 1 The layout of the hybrid theatre for transcatheter aortic valve implantation at the St. Paul's Hospital, University of British Columbia, Vancouver, Canada.

hybrid theatre. As well, it is imperative that transesophageal echocardiography (TEE) or intracardiac echocardiography (ICE) be available to assess ventricular, valvular functions and the annular size. In addition, TEE is an invaluable tool to help with the positioning of transcatheter valve stent prior to its deployment.

Defining the implant angle, where the bases of all three aortic cusps reside on the same plane is crucial to a successful implant (*Figure 2*). An initial root aortogram performed with a 7 French (F) pigtail catheter at the base of the non-coronary cusp at an angle of AP and caudal 10° should guide the operator to define the optimal line of perpendicularity (*Figure 3*). Several imaging software systems, such as DynaCT (Siemens AG, Erlangen, Germany), Innova HeartVision System (GE Healthcare, Chalfont St Giles, UK) and C-THV (Paieon Inc, Park Afek, Israel) utilize 3-D rotational angiography to better define the aortic root anatomy and identify the line of perpendicularity. Preoperative multi-slice computer

tomography (MSCT) can provide valuable information on annular size and implant angle.

Surgical access

The left ventricular apex is located by placing the tip of a hemostat on the patient at the apex location as seen on fluoroscopy (*Figure 4A, B*). This method has been found to be reproducible and more useful than palpation for the apex beat, particularly in patients of high body mass index. Preoperative CT guided or intra-operative surface echocardiography is used by some groups. Sixth intercostal space (ICS) is the most common access site, followed by 5th ICS. Over the previously determined location of the apex, a 3 cm incision is made. The incision is made over the top of the rib to avoid trauma to the neurovascular bundle. When it is possible, using the lower ICS is more convenient in terms of a straighter trajectory to the aortic valve. The left lung, as previously mentioned, does not usually interfere

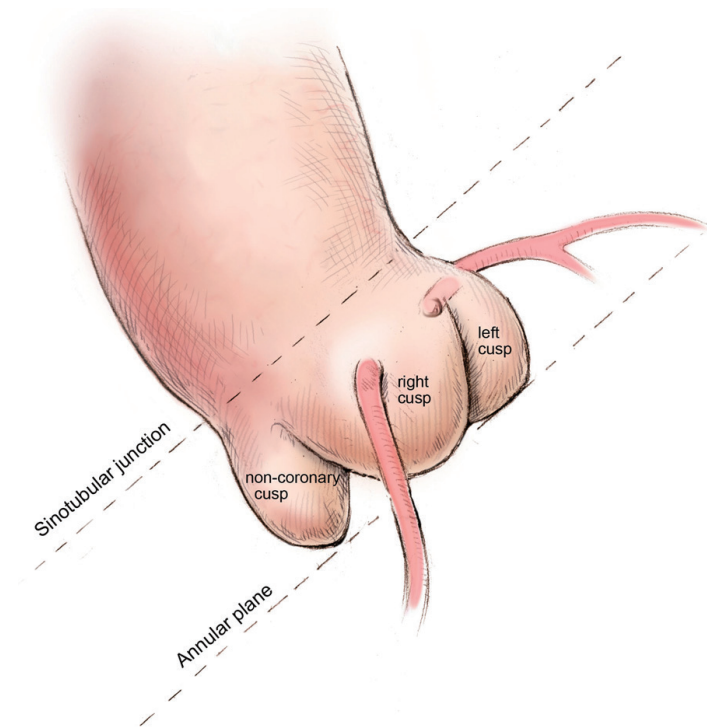


Figure 2 The bases of all three aortic cusps residing on the same plane is crucial to a successful implantation.

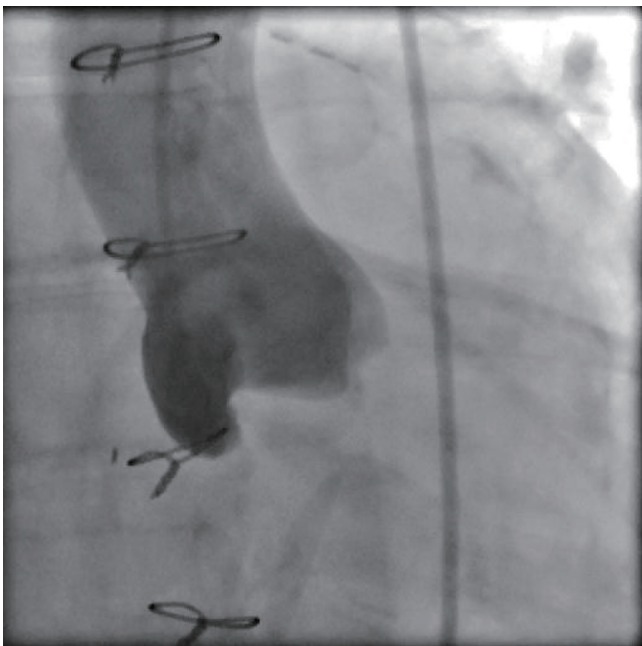


Figure 3 An initial root aortogram performed with a 7 French (F) pigtail catheter at the base of the non-coronary cusp at an angle of AP and caudal 10° should guide the operator to define the optimal line of perpendicularity, where the bases of all three aortic cusps reside on the same plane.

with the exposure of the left ventricular apex. A soft tissue retractor, Alexis Retractor (Applied Medical Corp., Rancho Santa Margarita, CA, USA) is inserted into the incision to retract the soft tissue without spreading the ribs. This method greatly reduces post-operative pain (*Figure 5*).

The pericardium is then incised and opened near the left ventricular apex and pericardial retraction sutures may aid further exposure. In cases where the patient has a history of previous cardiac surgery, dissection of pericardial adhesions is avoided.

As with all procedure, transapical TAVR has an Achilles heel and that is haemostatic control of the left ventricular apex. Particular care must be taken when placing two large pledgeted orthogonal mattress sutures using 3-0 MH polypropylene sutures (Ethicon, Somerville, NJ, USA) to obtain full thickness of the left ventricular wall. Each of the two mattress sutures are snared and passed through tourniquets that can be tensioned at the time of sheath removal (*Figure 6*). The sutures are appropriately placed to allow space for the largest sheath, initially an Ascendra sheath (Edwards LifeSciences, Irvine, CA, USA) with an internal diameter (ID) of 33 F sheath and more recently a smaller (24 F ID) Ascendra II Plus delivery system. The true apex should be avoided, as it is frequently thin and covered

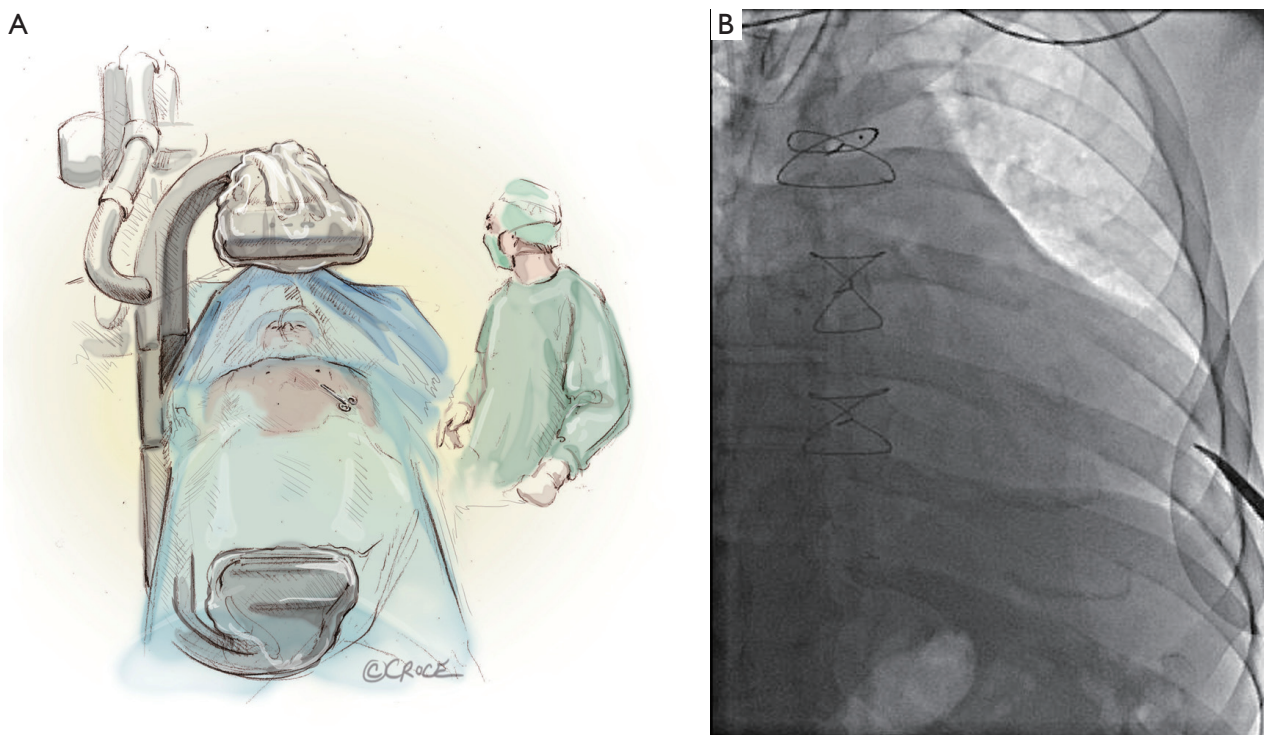


Figure 4 (A) The left ventricular apex is located by placing the point of a hemostat on the patient's chest at the apex location; (B) This is confirmed by fluoroscopy.

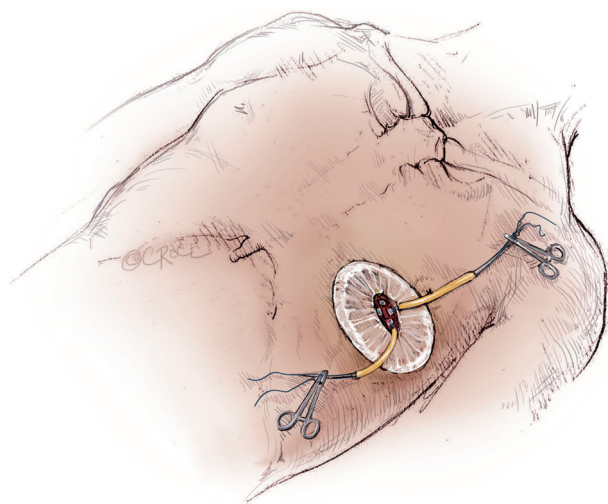


Figure 5 A 3 cm incision is made over the sixth intercostal space and a soft tissue retractor, Alexis Retractor (Applied Medical Corp., Rancho Santa Margarita, CA, USA) is inserted into the incision to retract the soft tissue without spreading the ribs.

by adipose tissue. A 'bare spot' lateral and cranial to the true apex should be used to avoid catastrophic ventricular rupture.

Rapid ventricular pacing is required for the implantation of balloon-expandable prosthesis, in order to decrease forward flow during the valvuloplasty and valve deployment. One unipolar epicardial pacing wire is placed directly onto the left ventricle and another on patient's chest wall. Alternatively, transvenous pacing lead can be implanted into the right ventricle. Pacing rate of 140 to 200 beat per minute frequently results in 1:1 ventricular capture and lowers the pulse pressure and forward flow. The rapid pacing periods and episodes must be minimized to ensure hemodynamic stability, especially in patients with depressed left ventricular function and/or non-revascularized coronary artery disease.

Hemostasis of the apex is ensured prior to the administration of unfractionated heparin to achieve an

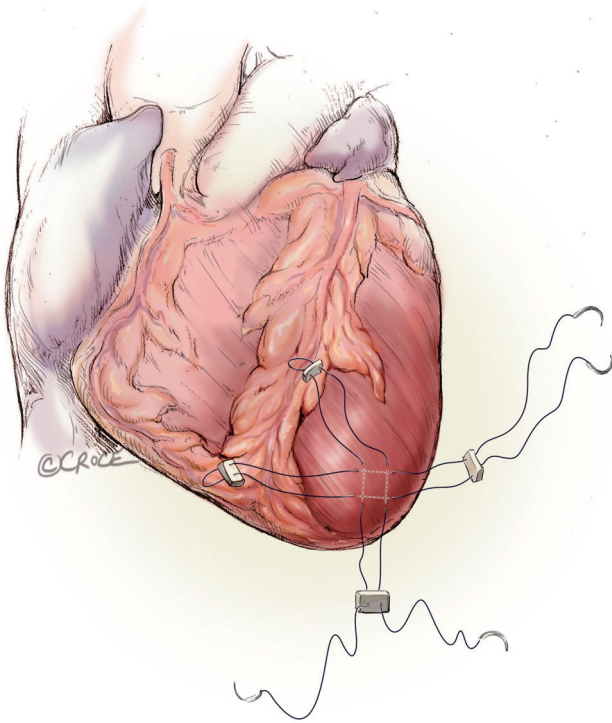


Figure 6 Two large pledgetted orthogonal mattress sutures using 3-0 MH polypropylene sutures (Ethicon, Somerville, NJ, USA) to obtain full thickness of the left ventricular wall and each of the two mattress sutures are snared and passed through tourniquets that can be tensioned at the time of sheath removal.

activated clotting time of greater 250 seconds. A 14-gauge Seldinger needle is positioned in the centre of the mattress sutures' square and advanced to enter the chamber of the left ventricle. The angle of entry should be pointing toward the right shoulder, whereby crossing of the native aortic valve can be easily achieved. Correct placement can be confirmed by the visualization of bright red blood spurting with each ventricular contraction (*Figure 7*). If oxygenated blood does not spurt despite advancement of the needle, this suggests the needle may be in the interventricular septum. Also, the needle could be inadvertently embedded into the hypertrophied ventricular wall if the angle of introduction was too obtuse. If pulsatile venous blood is visualized, this is indicative that the septum has been crossed and the needle has passed into the right ventricle. Once oxygenated blood is visualized, a soft wire is used to cross the native aortic valve. A 7F sheath is introduced over the short wire using Seldinger technique across the AV. A 260 cm, 0.035-inch Amplatz extra stiff wire (Boston Scientific Corp., Natick, MA, USA) is exchanged and maneuvered down the descending thoracic aorta.

Balloon valvuloplasty

Balloon valvuloplasty can be performed with a 14 F Cook or the Ascendra sheath under rapid ventricular pacing (*Figure 8*). A 3 cm, 20 cc BAV balloon from Edwards LifeSciences is

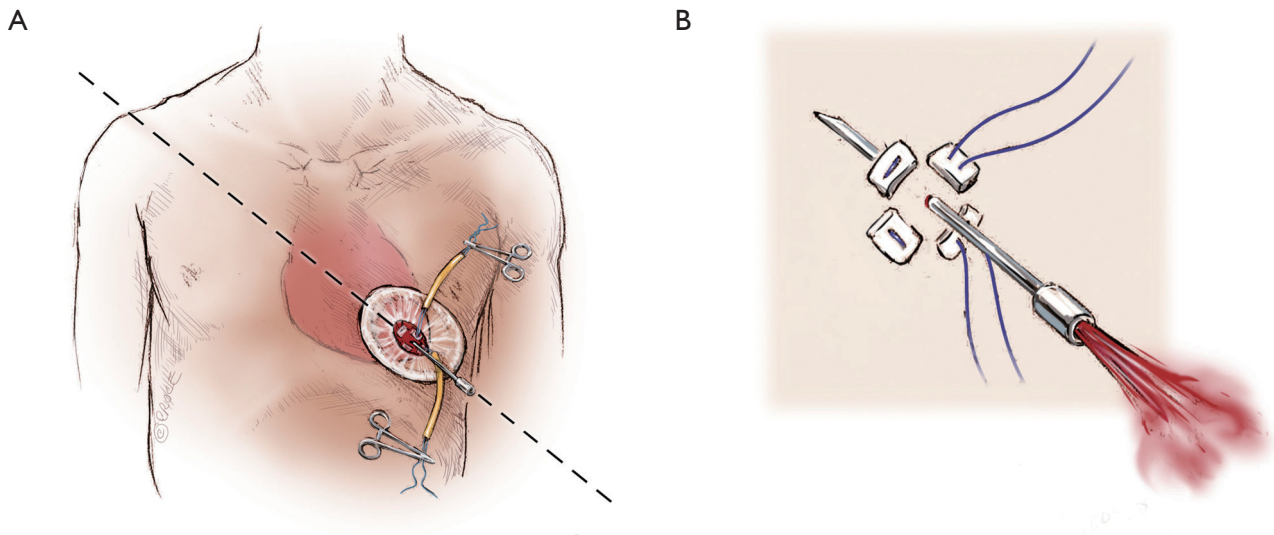


Figure 7 (A) A 14-gauge Seldinger needle is positioned in the centre of the mattress sutures square, advanced to enter the chamber of the left ventricle towards the right shoulder, whereby crossing of the native aortic valve can easily be achieved; (B) Correct placement can be confirmed by the visualization of bright red blood spurting with each ventricular contraction.

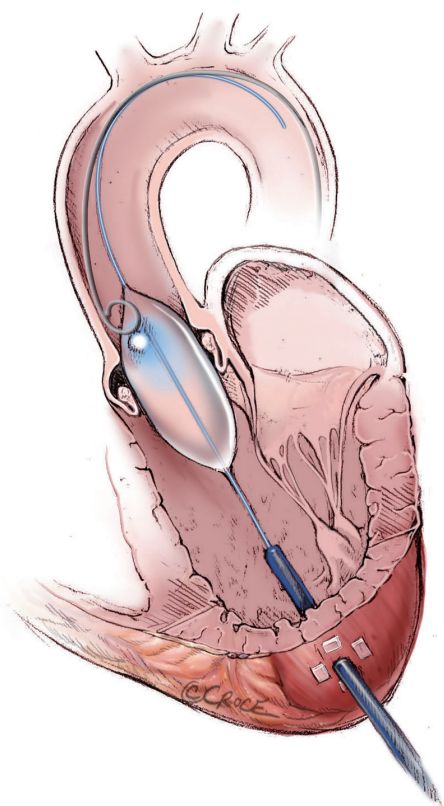


Figure 8 Transapical balloon Valvuloplasty is performed under rapid ventricular pacing.

used for all cases regardless the size of the annulus. BAV facilitates the crossing of the stenotic AV and retrieval of the transcatheter valve if it is accidentally advanced past the native valve. Further, BAV improves the aortic valve area and allows flow around the valve stent during positioning, thus minimizing hemodynamic instability. BAV also rehearses the deployment steps, allowing synchronization of the team.

Close observation of the movement of the calcified leaflets relative to the coronary Ostia during BAV may help to exclude patient with high-risk anatomy for coronary occlusion. A root aortogram can be performed with an inflated balloon in situ to better define the structures.

Positioning

The Edwards SAPIEN balloon expandable transcatheter valve is constructed of trileaflet bovine pericardium on a metal stent. It is crimped onto the delivery balloon. The

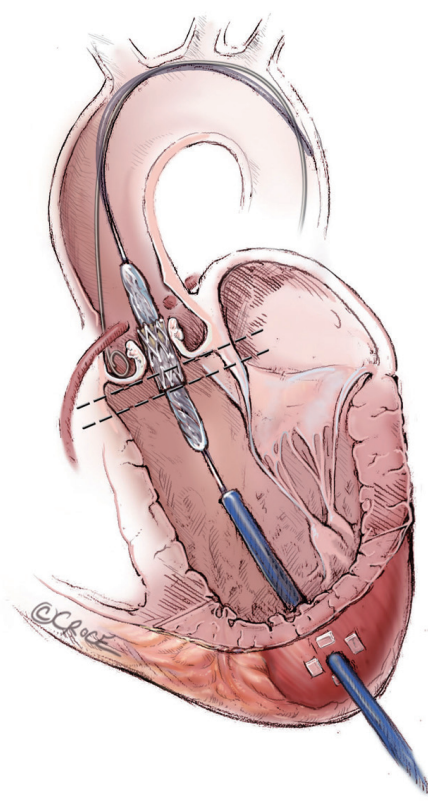


Figure 9 The SAPIEN prosthesis is ideally placed 1/3 below the base of aortic sinuses, the bottom of the valve stent ventricularly relative to the line of perpendicularity with the aide of repeat aortic root angiograms.

correct orientation of the transcatheter valve with the Dacron ring at the base of the valve on the ventricular outflow side and open stent on the aortic side must be ensured. After engaging the delivering system, the valve is advanced beyond the tip of the Ascendra sheath under fluoroscopic guidance. Withdrawal of the pusher catheter is then carried out. The SAPIEN valve is positioned within the native AV. The SAPIEN prosthesis is ideally placed 1/3 below the base of aortic sinuses (*Figure 9*), the bottom of the valve stent positioned ventricularly relative to the line of perpendicularity with the aide of repeat aortic root angiograms. TEE provides additional images that further refine the positioning. Aligning the ventricular end of the valve stent to the aorto-mitral fibrous curtain, the “hinge point” of the anterior leaflet of the mitral valve, confirms the ideal landing zone (*Figure 10*). If accurate positioning cannot be achieved due to brisk cardiac motion, rapid pacing with root injections may assist in positioning.

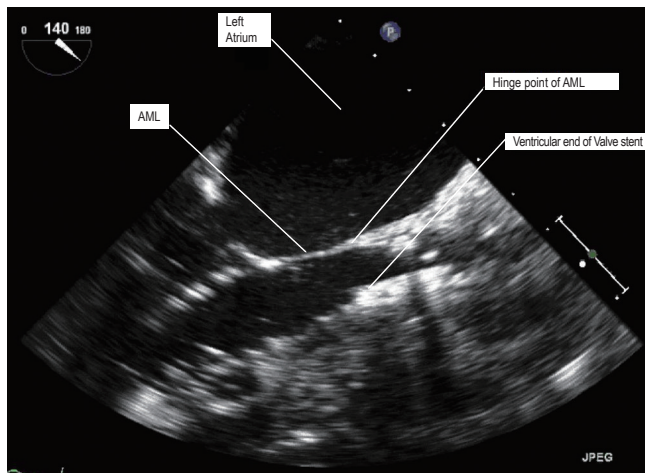


Figure 10 Transesophageal echocardiogram shows aligning the ventricular end of the valve stent to aorto-mitral fibrous curtain, the “hinge point” of the anterior leaflet of the mitral valve confirms the ideal landing zone.

Deployment

It is extremely important to ensure accurate positioning of the valve prior to its deployment to avoid malpositioning, embolization and significant perivalvular leak. Once acceptable positioning is confirmed using echocardiography and fluoroscopy, the pigtail catheter is withdrawn to the ascending aorta, the pacing protocol is again initiated and the valve is slowly deployed (*Figure 11*). During deployment, fine adjustment can be made to ensure optimal placement (*Figure 12A*). Full emptying of the inflation syringe and maintaining full pressure ensures symmetric deployment and prevents stent recoiling (*Figure 12B*). The balloon is quickly deflated and pacing is ceased. The balloon is pulled back out of the valve stent into the delivery sheath, preventing interference with leaflet function (*Figure 13*). Once the valve is deployed, echocardiography reports on the stability, location and function of the valve stent, and the degree of perivalvular regurgitation. If valve position is satisfactory and more than moderate degree of perivalvular regurgitation exists, a second attempt with slight higher balloon inflation volume may be attempted. If the degree of central regurgitation through the valve is difficult to evaluate with the Amplatz wire across the valve, it too is withdrawn into sheath. Completion aortogram is seldom perform to minimize the dye load that may adversely effect renal function.

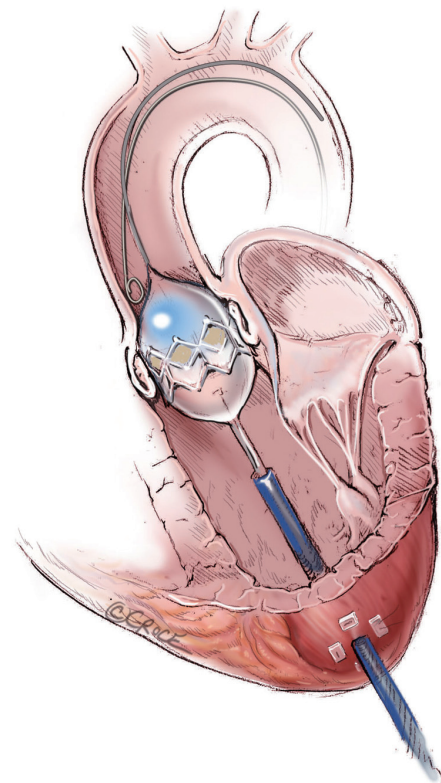


Figure 11 Once acceptable positioning is confirmed using echocardiography and fluoroscopy, the pigtail catheter is withdrawn to the ascending aorta, the pacing protocol is again initiated and the valve is slowly deployed.

Surgical closure

With systolic pressure less than 100 mmHg, the delivery sheath is removed with snugging of the mattress sutures. Then the other orthogonal mattress suture is subsequently tied (*Figure 14*). Persistent hypertension can be controlled with ventricular pacing at a rate of 100 to 140 bpm. Any blood collections are aspirated from the left chest and local bupivacaine is injected into the intercostal muscles. A small-bore chest drainage tube brought out through a small stab wound is left behind in the left chest. The intercostal muscles are approximated and the skin closed with absorbable subcuticular suture.

Comments

Transcatheter aortic valve replacement is an acceptable treatment option for non-surgical and high-risk surgical

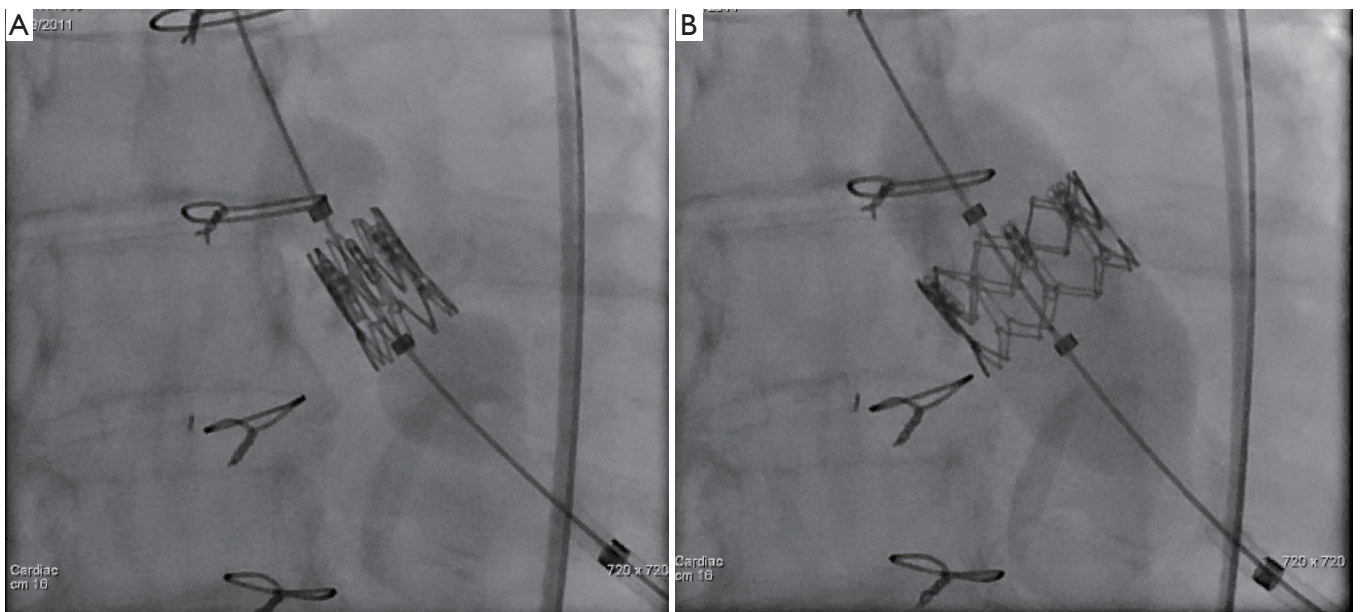


Figure 12 (A) Acceptable positioning is confirmed using echocardiography and fluoroscopy, the pacing protocol is once again initiated and slowly the valve is partially deployed, fine adjustment can be made to ensure optimal placement; (B) Full emptying of the inflation syringe and maintaining full ensures symmetric deployment and prevents stent recoiling.

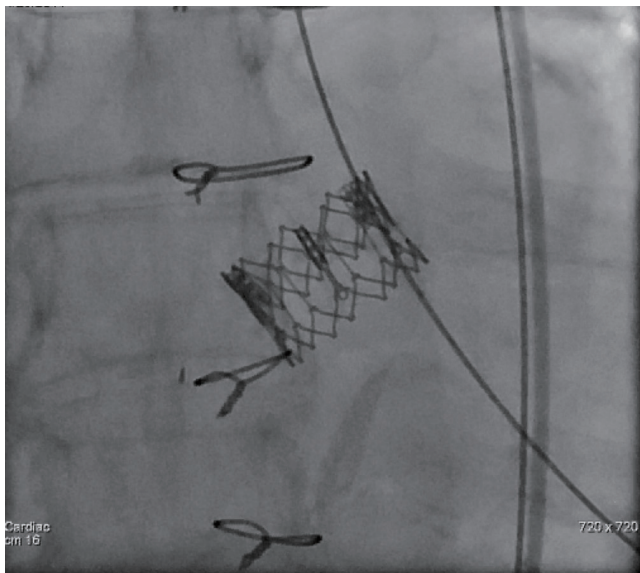


Figure 13 Final positioning post transapical deployment of SAPIEN valve.

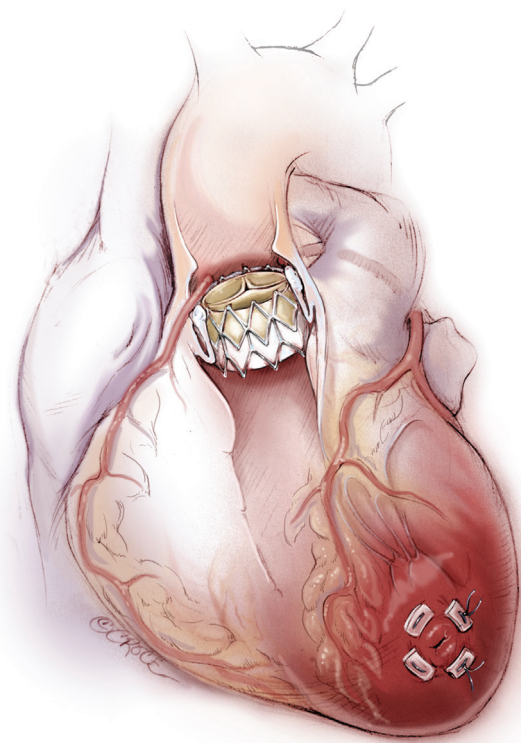


Figure 14 After valve deployment, the delivery sheath is removed and the orthogonal mattress sutures are tied.

candidates. Its clinical application will continue to expand. Transfemoral TAVI is the predominant route of delivery, however, transapical TAVI is a reliable and reproducible procedure in experienced hands.

Acknowledgements

Disclosure: The authors declare no conflict of interest.

References

1. Ye J, Cheung A, Lichtenstein SV, et al. Transapical aortic valve implantation in humans. *J Thorac Cardiovasc Surg* 2006;131:1194-6.
2. Lichtenstein SV, Cheung A, Ye J, et al. Transapical transcatheter aortic valve implantation in humans: initial clinical experience. *Circulation* 2006;114:591-6.
3. Walther T, Dewey T, Borger MA, et al. Transapical aortic valve implantation: step by step. *Ann Thorac Surg* 2009;87:276-83.
4. Cheung A, Ree R. Transcatheter aortic valve replacement. *Anesthesiol Clin* 2008;26:465-79.
5. Smith CR, Leon MB, Mack MJ, et al. Transcatheter versus surgical aortic-valve replacement in high-risk patients. *N Engl J Med* 2011;364:2187-98.
6. Mukherjee C, Walther T, Borger MA, et al. Awake transapical aortic valve implantation using thoracic epidural anesthesia. *Ann Thorac Surg* 2009;88:992-4.

Cite this article as: Cheung A, Lichtenstein KM. Illustrated techniques for transapical aortic valve implantation. *Ann Cardiothorac Surg* 2012;1(2):231-239. doi: 10.3978/j.issn.2225-319X.2012.07.12

The Jarvik-2000 ventricular assist device implantation: how we do it

Fabio Zucchetta, Vincenzo Tarzia, Tomaso Bottio, Gino Gerosa

Division of Cardiac Surgery, Department of Cardiology, Thoracic and Vascular Sciences, University Hospital of Padova, Padova, Italy

Introduction

The Jarvik-2000 (Jarvik Heart, Inc.; New York, NY, USA) is a valveless electrically powered non-pulsatile axial-flow left ventricular assist device (LVAD) that has been developed and refined over the last 25 years. It consists of a miniaturized intraventricular blood pump that lacks a real inflow conduit. The device is placed on the cardiac apex and creates a blood flow that can be directed either towards the ascending or descending aorta through its outflow conduit. Nowadays, it can be employed as a bridge to transplant or for permanent use (destination therapy) in case of untreatable end-stage heart failure (1-3).

The device

The Jarvik-2000 is 2.5 cm wide, 5.5 cm long and weighs 85 grams. The pump has one moving part, an impeller that is a neodymium-iron-boron magnet and which is housed inside a welded titanium shell. It is supported by ceramic bearings and spins blood to generate an average flow rate of 5 L/min (up to 7 L/min) with a rotation speed of 8,000-12,000 rpm (4). The device is connected to an external controller via a tunneled driveline that delivers power to the impeller. This controller permits manual adjustments of the pump speed and also visualizes the battery charge level.

Implantation strategies

Many different surgical approaches have been described for the Jarvik implantation. The first surgical techniques required total cardiopulmonary bypass (CPB) support, whether the case of a median sternotomy access (*Figure 1*) or a single left lateral thoracotomy approach (*Figure 2*) (5). Newer and less invasive strategies make an off-pump implantation feasible and reproducible, performed either through a single left thoracotomy (*Figure 2*) or a combined left antero-lateral mini-thoracotomy and upper minimal inverted T or J sternotomy (*Figure 3*) or a double mini-thoracotomy (left antero-lateral thoracotomy plus upper right thoracotomy) (6,7). Only if necessary, peripherally

inserted ECMO (ExtraCorporeal Membrane Oxygenation) can be used for hemodynamic support during the procedure instead of CPB institution. In both cases, it is necessary to create a subcutaneous tunnel to bring the power cable either to the abdominal region or the retro-auricular region (*Figure 2*); here, the external cable can be connected to the controller (8-10). The mastoid region is usually chosen to house the skull-pedestal for the power cable skin exit, as it is associated with minimal infective risk.

In the following paragraphs, we will describe how to perform the different steps of the Jarvik-2000 implantation using a left lateral thoracotomy or the combination of the mini-sternotomy plus the left antero-lateral thoracotomy. For the time being, the antero-lateral thoracotomy accompanied by the mini-sternotomy without CPB support has been used in eight cases out of 31 Jarvik device implantations at our institution; 15 patients were operated on through a left lateral thoracotomy, two cases through a median sternotomy and six patients were more recently approached through a double thoracotomy.

Operative technique

Anesthesia

The Jarvik implantation is performed under general anesthesia; induction is commonly achieved with sodium thiopental (midazolam and/or ketamine could be used alternatively), fentanyl and rocuronium, meanwhile maintenance drugs are generally propofol and sufentanil. Considering hemodynamic lability of the patients who require VAD implantation, an anesthetic conduction that aims to an early awakening and extubation with an adequate pain control can improve the patient management and lead to a good immediate postoperative course with a faster recovery. For this purpose, mild general anesthesia preparation with paravertebral analgesia has been used with clinical good results.

Positioning and preparation

The operative room is set up as for a conventional cardiac

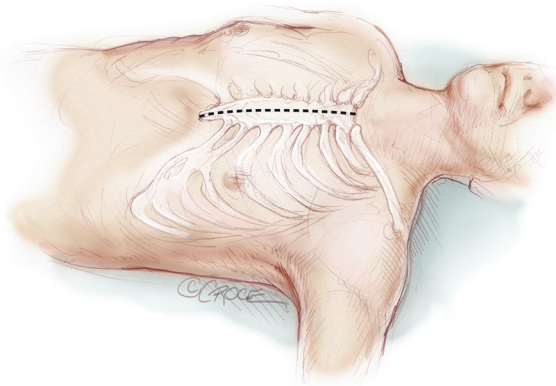


Figure 1 Median full sternotomy skin incision.

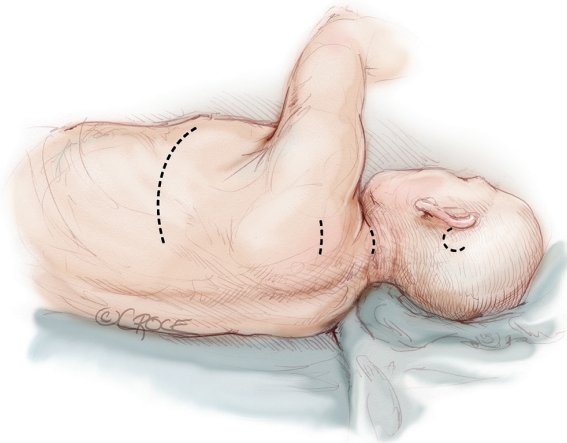


Figure 2 Left lateral extended thoracotomy skin incision for the mediastinal access, with additional incisions on the shoulder, neck and retroauricular area for the driveline tunneling and skull pedestal implantation.

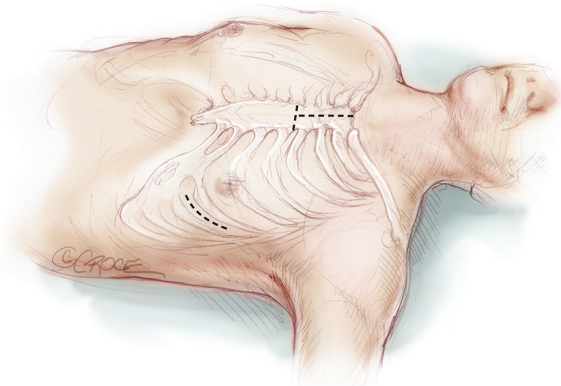


Figure 3 Left lateral mini-thoracotomy and upper mini-sternotomy skin incisions.

surgery, with a stand-by ECMO or CPB. Under general anesthesia (as mentioned before), the patient is intubated with a single lumen endotracheal tube; both central and peripheral venous lines are established (large volume infusion catheters are needed in case of significant hemorrhage) as well as an arterial line, followed by the insertion of a transesophageal echocardiography (TEE) probe. The patient position depends on the surgical approach: if the outflow conduit is connected to the ascending aorta, the combination of upper sternotomy and left lateral thoracotomy is necessary and the patient will be supine on the operating table (a roll is placed under the left chest in order to turn the patient slightly rightward—about 30 degrees). When the descending aorta is chosen as the outflow conduit connection site, a left thoracotomy will be performed and the patient will be positioned in the lateral decubitus position. In both cases, a sterile preparation of the temporo-occipital area, the neck, the thorax and the groin is mandatory; above all, free access of the left femoral vessels for percutaneous cannulation has to be available for all the procedures in case of hemodynamic instability and the need for ECMO support.

Surgical access 1: upper mini-sternotomy and left mini-thoracotomy

When the Jarvik-2000 is planned to convey blood towards the ascending aorta (*Figure 4*), the surgeon enters the mediastinum performing an anterior left mini-thoracotomy through the fifth intercostal space, in order to access the apex and an inverted T or J upper mini-sternotomy through the second/third intercostal space to access the ascending aorta. A tissue retractor can facilitate the surgical exposition of the apex, while a sternal retractor is used in the second access point.

Surgical access 2: left thoracotomy

The choice to connect the outflow graft of the pump to the thoracic descending aorta (*Figure 5*) requires a single extended left thoracotomy. Adequate space to control the left postero-lateral aspect of the mediastinum is necessary and the incision is generally made through the sixth intercostal space from the emiclavicular line to the left subscapular area, without sparing the serratus anterior muscle.

Retro-auricular site preparation

Before heparinization and starting the maneuvers on

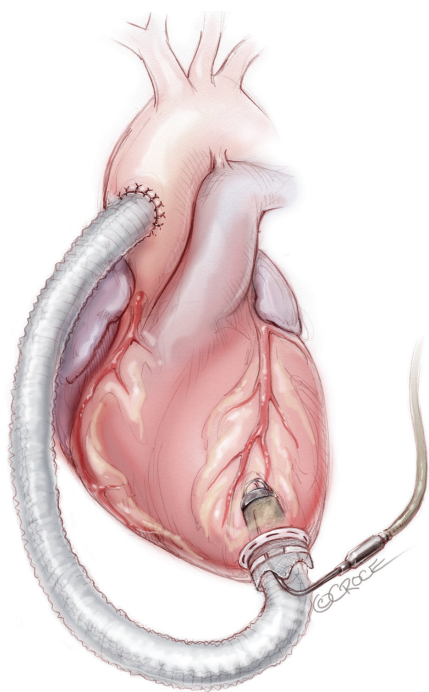


Figure 4 Implantation of the Jarvik pump into the left ventricular apex with distal outflow graft conduit anastomosis to ascending aorta.

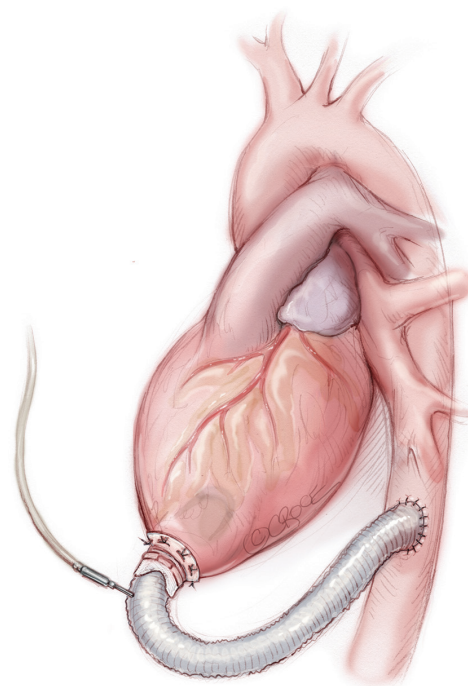


Figure 5 Implantation of the Jarvik pump into the left ventricular apex with distal outflow graft conduit anastomosis to descending thoracic aorta.

the heart and aorta, the skin exit for the power cable of the pump is created. A “C-shape” skin incision in the retro auricular region is performed in order to prepare a large-based flap slightly above the ear (*Figure 6*). The subcutaneous tissue is dissected and periosteum is slit (*Figure 7A*). Six holes are drilled in the bone with a specific 6 mm long drill (*Figure 7B*) and the pedestal is temporarily implanted to punch out the skin flap and identify the final exit for the external power connection.

When a left lateral thoracotomy is performed, two other skin incisions in the postero-lateral side of the neck and shoulder are made to create a subcutaneous tunnel which extends from the upper chest to the mastoid region (the lower skin incision is just above the superior medial scapular angle) (*Figure 2*). When the Jarvik is moved into the field, the power-cable with the three-pin connector is guided through this tunnel and connected to the pedestal. This action is achieved by inserting the driveline within the end of a thoracic drain tube which is brought out through the second intercostal space (between the medial border of the scapula and the spine) to the cranial site; tapes assist in pulling the tube across the tunnel exits. The three-pin connector is then inserted into the titanium pedestal, which

is eventually fixed with self-tapping screws (*Figure 8A*). More than one lateral cervical incision is useful in allowing more comfortable driveline positioning preserving neck motion without strain of the cable after the surgery. Once the pedestal is secured on the bone, the skin flap is repositioned, covering the skull implant but leaving the appropriate part of connector free for coupling with the external power support (*Figure 8B*). Testing of the pump concludes this phase.

Apical setting

The pericardium is horizontally opened anterior to the phrenic nerve and the apex is inspected; the appropriate site of the pump implantation is slightly anterior and 1-2 cm lateral to the descending coronary artery. The surgeon has to make sure that the ventriculotomy will be directed at the mitral valve, always keeping a parallel direction to the septum. A finger is pushed on the apex to confirm the insertion site for the Jarvik-2000 by using the TEE, also checking for parietal thrombi. Afterwards, the inflow sewing ring is sutured and tied to the myocardium using 10-12 interrupted pledgeted, double-armed 3-0 polypropylene

sutures (*Figure 9*). Suture penetration is deep enough to ensure the sewing ring stabilization, but the bites should not span the full thickness of the muscle, especially when the myocardium appears thin and weak due to dilation or previous ischemia.

Device implantation with outflow graft in the descending aorta

The distal graft anastomosis is made first: the thoracic descending aorta is isolated and a side-biting clamp is placed on it, right adjacent to the inferior left pulmonary vein, avoiding dilated areas or atheromatous plaques. Here, the clamped graft is sewn with a running 4-0 polypropylene

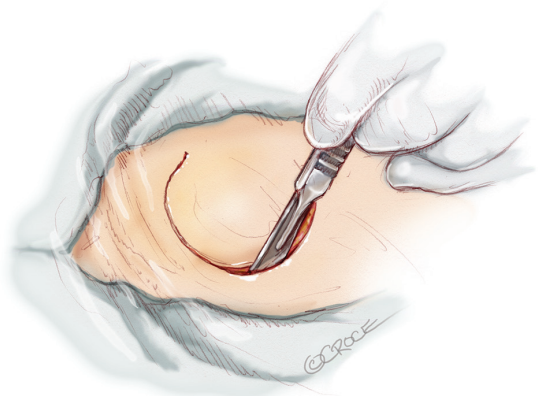
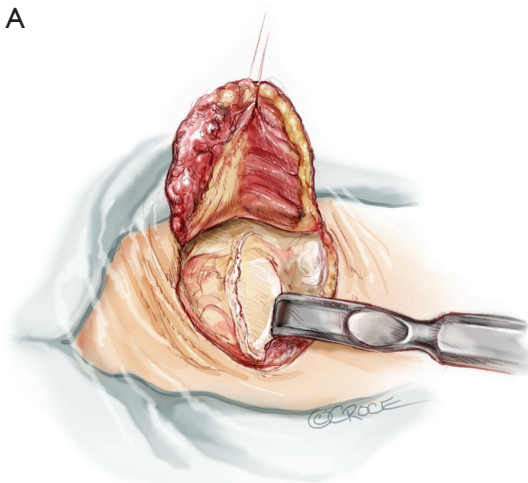


Figure 6 Retroauricular broad-base C-shape flap incision.

A



B

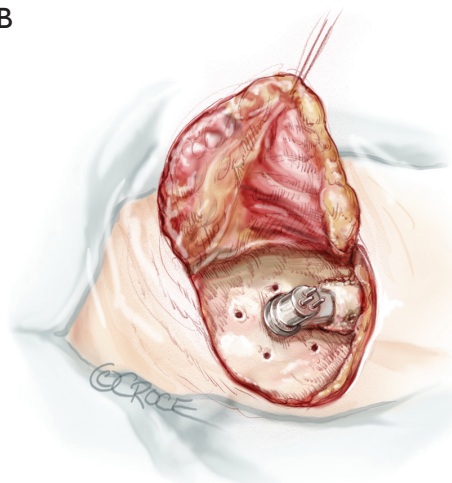


Figure 7 (A) Subcutaneous tissue is dissected in order to expose the mastoid bone. The periosteum is scraped (generally in four slices) in order to receive the pedestal and cover it after its implantation to promote bony apposition and a faster recovery; (B) six holes are drilled in the bone for the fastening screws of pedestal. The three-pin connector exits the skin from the latero-cervical subcutaneous tunnel.

suture. Two Teflon strips are usually employed as structural reinforcement of the anastomosis and to ensure hemostasis.

After placing the patient in Trendelenburg position, a transmural cruciate incision is performed inside the sewing ring. A coring knife is then inserted to excise a ring of muscle. In a continuous motion, the knife is removed and the pump is quickly pushed into the ventriculotomy, trying to lose as little blood as possible (this maneuver is made easy by the small size of the pump). As the pump is placed in the apex, the internal connecting umbilical strings attached to the sewing ring are tied; the pump is then switched on at a low speed to start the de-airing process and the device is definitely secured in the retaining cuff closing the external umbilical strings. The system de-airing is then completed with a medium gauge needle and the left cardiac cavity is evaluated by TEE for residual bubbles and for the correct intraventricular device position confirmation.

Device implantation with outflow graft in the ascending aorta

After the inverted T or J upper mini-sternotomy is performed, the ascending aorta is isolated. The pump is brought up to the field, and the outflow conduit is tunneled underneath the pericardium from the left thoracotomy to reach the partial sternotomy (*Figure 10*). The apical setting and implantation of the pump is practically unchanged

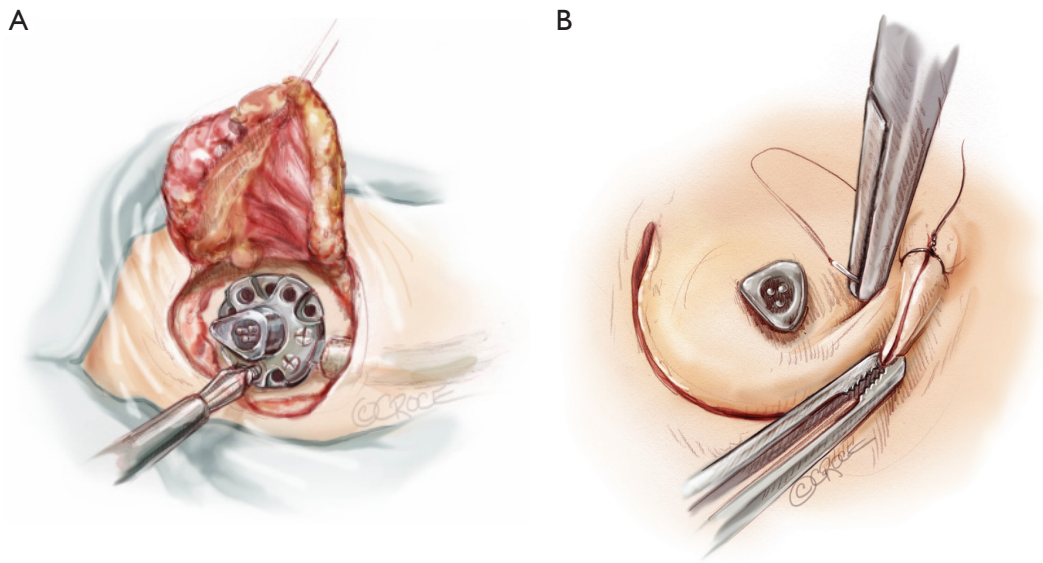


Figure 8 (A) The pedestal plug is mounted and fixed on the bone with the three-pin connector inside it. Self-tapping screws are utilized to allow a 1.5 mm safety-margin to prevent skull penetration; (B) cutaneous retroauricular flap is repositioned and the pedestal exits across the skin (the area is punched out for receive the connector and let it get through the skin layer).

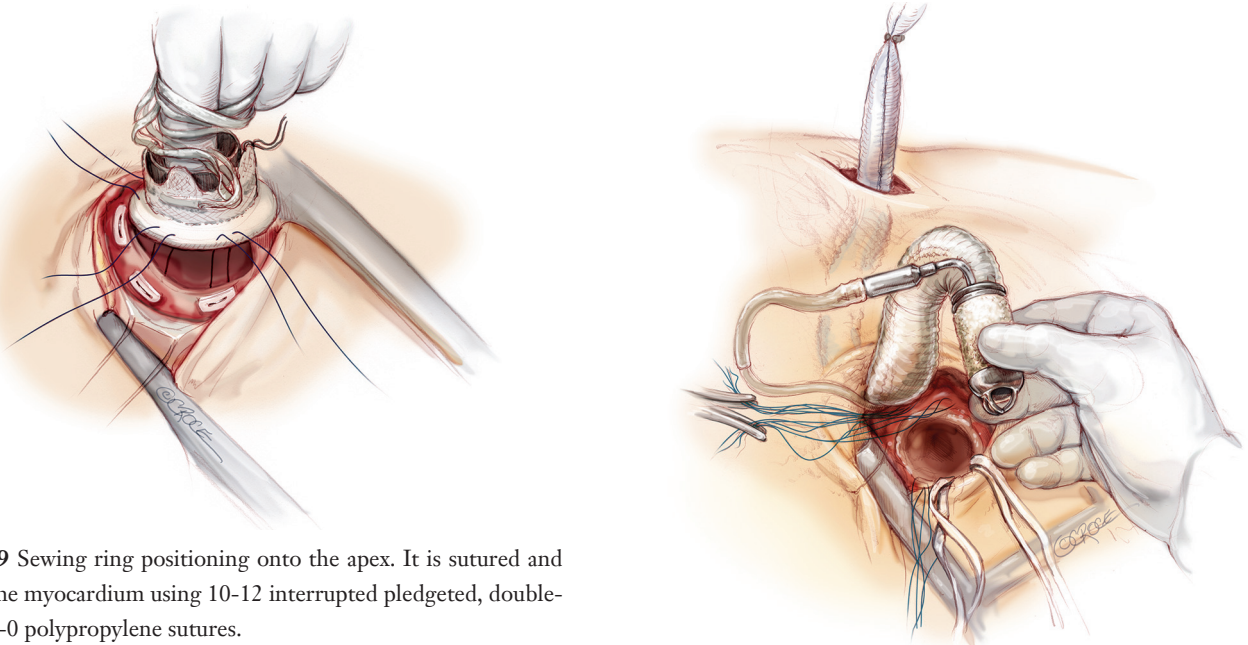


Figure 9 Sewing ring positioning onto the apex. It is sutured and tied to the myocardium using 10-12 interrupted pledgeted, double-armed 3-0 polypropylene sutures.

Figure 10 Outflow graft conduit of the pump is tunneled from the left thoracotomy toward the upper sternotomy in order to connect the apex and the ascending aorta. The conduit runs below the pericardium. In this picture, the surgeon's hand holds the Jarvik-2000 before its apical implantation.

from the previous description. De-airing is performed by activating the pump at low speed, allowing blood to fill the outflow conduit. Once the surgeon has secured the pump into the apex, the outflow graft conduit is gently stretched; the right length is assessed and the conduit is cut. A partial occlusion clamp is placed on the anterior-lateral aspect of the ascending aorta, a longitudinal arteriotomy is performed and the graft is sewn in place using running 4-0 polypropylene sutures. Completion of air removal is accomplished by using a needle inserted into the outflow graft before opening the side-biting clamp. After TEE inspection of the heart chambers, the Jarvik-2000 is left free to convey blood to the aorta.

Conclusions of the procedure

The device speed is titrated and gradually increased following the hemodynamic condition, providing an adequate cardiac index (>2.2 L/min/m²) and maintaining low filling pressure of the left ventricle. Inotropic and vasopressor drugs are used to support the right ventricle and adjust the peripheral vascular tone. Protamine sulfate is used to reverse the heparin, mediastinal pleural drainage tubes are placed and the chest is closed in layers. Scalp and skin incisions are securely closed.

Perioperative comments

We have presented our techniques of Jarvik-2000 LVAD implantation without using CPB or ECMO support. The favored site for power-connector is the retro-auricular region. What we have showed here is quite a similar technique to that used to implant an HeartWare or a HeartMate ventricular assist device, except in the details regarding the apical inflow part of the pump and the tunneling of the power cable outside the organism. Such a surgical procedure is safe and reproducible, provided that it is carefully planned and preoperative evaluation of other coexisting structural heart disease that can alter the pump functioning is undertaken. In particular, the presence of an atrial septal defect/patent foramen ovale (ASD/PFO), aortic insufficiency, mitral stenosis and tricuspid regurgitation must be corrected at the time of surgery.

The reason for correcting the above mentioned diseases are explained by the blood flow physiology related to the pump. Firstly, ASD/PFO can lead to a significant right-to-left shunt and generate severe hypoxemia; aortic insufficiency can reduce the forward flow creating a circular

flow circuit that involves the pump, outflow graft, aorta and left ventricle; mitral stenosis can reduce the pump preload, thus reducing the device performance; tricuspid regurgitation can affect the right ventricle function and again, reduce the adequate assist device preload.

Right ventricular failure is one of the most important concerns when a LVAD is implanted and is associated with increased postoperative morbidity and mortality. It is therefore crucial to evaluate the right ventricle risk profile preoperatively and predict whether stronger support strategies will be needed in the operative setting (inotropes, ECMO or even a temporary right ventricle assist device).

Even with the best medical and surgical care, complications can occur following Jarvik implantation, as with any other type of cardiac support device. The most frequent complications are (I) bleeding, due to coagulation factor alteration and activation, platelet modifications and abnormal liver function related to refractory heart failure; (II) cerebral and peripheral thromboembolism, for the same reasons as changes in coagulation state; (III) infections, related to foreign materials and the skin exit sites of cables; (IV) hemolysis, due to red blood stress created by the device impeller; and (V) arrhythmias, related to electrical instability of the myocardium, apical scarring and suction physiology.

Acknowledgements

Disclosure: The authors declare no conflict of interest.

References

1. Park SJ, Kushwaha SS, McGregor CG. State-of-the-art implantable cardiac assist device therapy for heart failure: bridge to transplant and destination therapy. *Clin Pharmacol Ther* 2012;91:94-100.
2. Mallidi HR, Anand J, Cohn WE. State of the art of mechanical circulatory support. *Tex Heart Inst J* 2014;41:115-20.
3. Hirsch DJ, Cooper JR Jr. Cardiac failure and left ventricular assist devices. *Anesthesiol Clin North America* 2003;21:625-38.
4. Jarvik R. Jarvik 2000 pump technology and miniaturization. *Heart Fail Clin* 2014;10:S27-38.
5. Westaby S, Frazier OH, Pigott DW, et al. Implant technique for the Jarvik 2000 Heart. *Ann Thorac Surg* 2002;73:1337-40.
6. Selzman CH, Sheridan BC. Off-pump insertion of

- continuous flow left ventricular assist devices. *J Card Surg* 2007;22:320-2.
7. Gerosa G, Gallo M, Tarzia V, et al. Less invasive surgical and perfusion technique for implantation of the Jarvik 2000 left ventricular assist device. *Ann Thorac Surg* 2013;96:712-4.
 8. Siegenthaler MP, Martin J, Frazier OH, et al. Implantation of the permanent Jarvik-2000 left-ventricular-assist-device: surgical technique. *Eur J Cardiothorac Surg* 2002;21:546-8.
 9. Siegenthaler MP, Martin J, Frazier OH, et al. Implantation of the permanent Jarvik-2000 left-ventricular-assist-device: surgical technique. *Eur J Cardiothorac Surg* 2002;21:546-8.
 10. Hohlweg-Majert B, Gutwald R, Siegenthaler MP, et al. Implantation of the Jarvik 2000 left-ventricular-assist-device: role of the maxillofacial surgeon. *Eur J Cardiothorac Surg* 2005;28:337-9.

Cite this article as: Zucchetta F, Tarzia V, Bottio T, Gerosa G. The Jarvik-2000 ventricular assist device implantation: how we do it. *Ann Cardiothorac Surg* 2014;3(5):525-531. doi: 10.3978/j.issn.2225-319X.2014.09.09

SynCardia: the total artificial heart

Gianluca Torregrossa¹, Anelechi Anyanwu¹, Fabio Zucchetta², Gino Gerosa²

¹Department of Cardiothoracic Surgery, Mount Sinai Health System, New York, USA; ²Department of Cardiac Surgery, University of Padua, Padova, Italy

Introduction

Initial efforts into creating an artificial complete cardiac replacement organ began in the mid-1960s (1). Several devices have been developed over the past 50 years; however, the SynCardia total artificial heart (TAH) is the only one currently commercially available and used in clinical practice.

Implanted in patients with biventricular failure, the SynCardia TAH has asserted itself as a reliable bridge to transplantation (2-4) and was approved by the United States Food and Drug Administration (FDA) in 2004 and the Centers for Medicare & Medicaid Services in 2008 (5).

Clinical indications for the SynCardia TAH include biventricular failure, left ventricular (LV) failure with prior mechanical heart valves, LV failure with severe anatomical damage (ventricular septal defect, atrioventricular disruption), intractable malignant arrhythmias, massive ventricular thrombus, cardiac allograft failure, hypertrophic or restrictive cardiomyopathy and complex congenital heart disease. Contraindications are generally attributed to size mismatch between the device and patients [body surface area (BSA) <1.7 m² or anteroposterior diameter of the chest at level of 10th vertebral body <10 cm].

In this article, we present the surgical technique for implantation of the SynCardia TAH.

Operative technique

Device preparation

The arterial outflow connectors are prepared and preclotted or sprayed with CoSeal (Baxter, Deerfield, Illinois, USA) on the back table. We prefer to use CoSeal sprayed with a special applicator onto the stretched graft, and letting the grafts dry while stretched.

The quick connections of the atrial cuffs are trimmed and cut in a circular fashion, leaving about three to five mm of sewing cuff.

All four connectors are stretched with a clamp to facilitate later connection to the device ventricle (*Figure 1*).

Surgery preparation

The patient is prepared in a supine position. Under general anesthesia, a central venous access and transesophageal echocardiogram (TEE) probe are inserted. No Swan-Ganz catheter is required; if the patient has a pulmonary artery catheter, this should be removed and exchanged for a short central venous catheter. Before prepping the patient, we mark any previous surgical scars as well as the future exit sites of the drivelines in the epigastrium: a first mark is pointed 7-10 cm below the costal margin along the left midclavicular line. A second mark for the exit of the right ventricle driveline is pointed five cm medially from the first one.

The chest and abdomen are prepared and draped in a routine fashion for cardiac surgery. Preoperatively, access to peripheral vessels for planned or emergent cannulation is obtained as necessary. If required, a high-risk sternotomy may be done under peripheral cardiopulmonary bypass.

Sternotomy and surgical access

The procedure is accomplished through a median sternotomy. Exposure and dissection of the heart and great vessels is similar to that for heart transplantation. Heparin is administered, and the ascending aorta is cannulated distally. We prefer to cannulate both cavae through the right atrium [as opposed to direct cannulation of the superior vena cava (SVC) and inferior vena cava (IVC)] to preserve those sites for use during subsequent transplantation. Dissection around the great vessels is limited in anticipation of additional future surgery. Snares may be placed around both cavae to facilitate total cardiopulmonary bypass. However, we do not find it necessary to snare the venae cavae with vacuum-assisted cardiopulmonary bypass. Cardiopulmonary bypass is instituted (*Figure 2*).

Cardiac excision

The aorta is clamped. In a large heart or where there are dense adhesions from prior surgery, cardiac dissection and excision may be facilitated through induced cardiac arrest

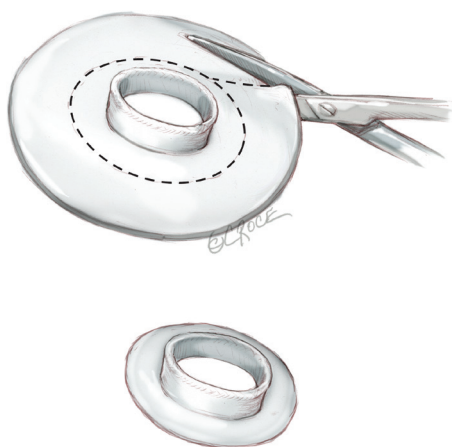


Figure 1 Device preparation: the quick connects of the atrial cuffs are trimmed and cut in a completely circular fashion leaving about three to five mm of sewing cuff. All four connectors are stretched with a clamp to facilitate later connection to the device ventricle.

either by administration of cardioplegia or by electrical fibrillation. Adhesions are divided to free the heart down to the pulmonary veins posteriorly. Excision of the heart begins (*Figure 3*). The purpose of the explantation of the heart is to leave both atria in place, as well as one to two cm of ventricle muscle around each atrioventricular valve plane, preserving both annuli of the mitral and tricuspid valves. The excision is started with a large blade (#10) scalpel by incising the right ventricle about one cm from and parallel to the right atrioventricular groove, extending to the acute margin of the right ventricle. This line is extended anteriorly across the right ventricular outflow tract. The pulmonary trunk is transected, preserving as much length of the pulmonary artery as possible. The original line on the acute margin of the right ventricle is then extended posteriorly toward the interventricular septum. Any pacing wires are divided. The left ventricle is entered again, preserving at least one to two cm of ventricular muscle attached to the mitral valve. This incision is continued circumferentially around the left ventricle. The ascending aorta is transected at the sinotubular junction. The aortic root is dissected caudally off the left atrial roof. The aortic valve is partly excised, preserving the aspect of the valve and aortic root attached to the mitral valve (mitral- aortic curtain), as that will be part of the left atrial cuff. The excised ventricles are now removed from the surgical field.

Preparation for anastomosis

Excess muscle is trimmed away to leave about 1 cm of

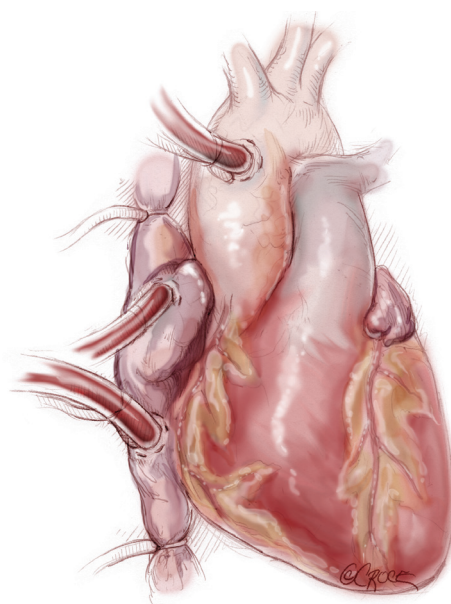


Figure 2 Cardiopulmonary bypass institution: the ascending aorta is cannulated distally. We prefer to cannulate both cavae through the right atrium [*vs.* direct cannulation of the superior vena cava (SVC) and inferior vena cava (IVC)] to preserve those sites for the heart transplantation surgery.

ventricular muscle attached to the atrioventricular valves. Any pacing leads are traced through the tricuspid valve into the SVC and dissected free from the endocardium, then divided at the level of the SVC. The external components of the pacemaker and remaining intravascular leads will be removed at a later stage after reversal of heparin and before chest closure. The right atrium is inspected for indwelling central venous catheters, and these are divided or retrieved if the tips lie close to the tricuspid valve. The cavae are snared at this stage if desired, taking care to maintain adequate positioning of the venous cannulae. The mitral and tricuspid valves are then excised, including all leaflet tissue, chordae and sub valvular apparatus. The coronary sinus is oversewn from within the atrium, as is the left atrial appendage. Alternatively, the appendage could be ligated externally, but this may promote adhesion formation, potentially complicating later transplantation. The atrial septum is inspected and any septal defects are closed (*Figure 4*).

Anastomosis

The left atrial connector is placed by the left atrial cuff.

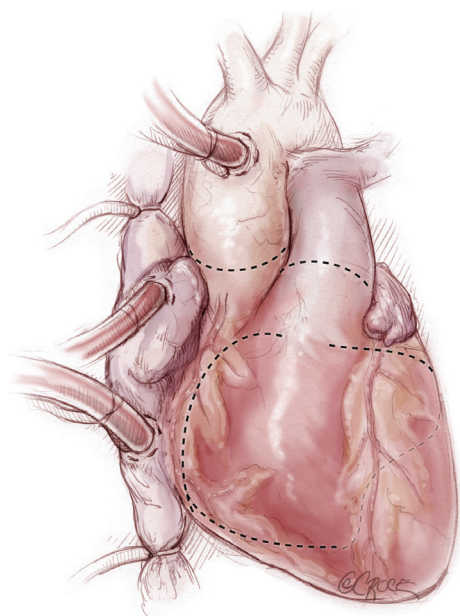


Figure 3 The excision of the heart proceeds along the lines depicted in the figure. The purpose of the explantation of the heart is to leave in place both atria and 1-2 cm of ventricle muscle around each atrioventricular valve plane preserving both annuli of the mitral and tricuspid valves.

Using a continuous 3-0 prolene suture the quick atrial connector is anastomosed to the left atrial cuff. In the area of the aortic-mitral curtain, the sutures will pass through the aortic root and the fibrous valve trigone. A second running 3-0 prolene suture is then applied to ensure total hemostasis. After completing the left side, a similar procedure is done with the right quick connector, also with a double layer of 3-0 prolene suture (*Figure 5*). In suturing, the surgeon must be aware that there will be intense scarring around this suture line and therefore if bites are taken deep into the atrium, this will compromise the amount of healthy tissue available for anastomosis at transplantation. This is especially important in the region of the left pulmonary veins. With the double layer suture technique, it is rare to experience bleeding or require any extra sutures on the atrial suture line. There is no need to test the anastomosis with pressurized saline injection. An alternative method of anastomosis involves using felt strips to reinforce the atrial cuffs, but this can result in intense inflammation and dense fibrous scarring, which can complicate cardiac excision at future transplantation. Therefore, we prefer the double suture technique.

Next, the anastomosis of the great arteries is performed

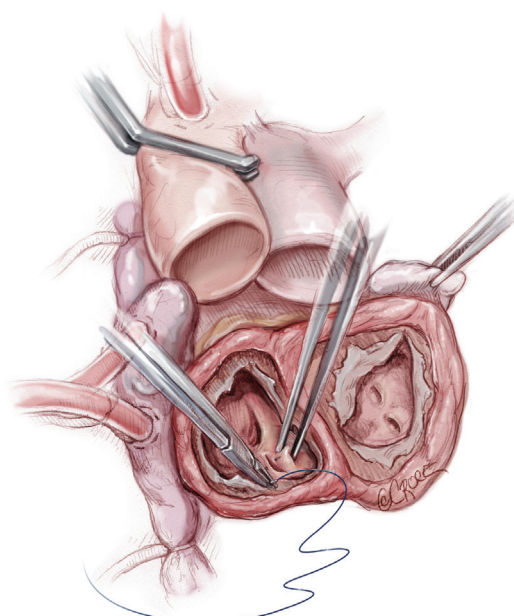


Figure 4 Native heart is removed. Preparation for anastomosis: the excess muscle is trimmed away around the atrioventricular junction. Coronary sinus and left atrial appendage are oversewn.

(*Figure 6*). The outflow conduits are trimmed to size; generally the length of the pulmonary conduit is about five to six cm while the aortic one is shorter around three to four cm. The distal sutures of each conduit are made with 4-0 prolene in a continuous end-to-end fashion suture. We use double layers of suturing for the atrial cuffs, to ensure adequate haemostasis.

Implantation of ventricles

Before placement of the ventricles, we suture two large sheets of Gore-Tex to the atrioventricular groove such that the entire ventricles and in particular, the atrial suture lines, will not be in direct communication with the posterior or lateral pericardium (*Figure 7*). This facilitates device explantation at transplantation. The drivelines for the ventricles are passed through the skin. First a one cm long curvilinear skin incision is made in the left side of the epigastrium along the midclavicular line, seven to 10 cm below the costal margin. This will represent the exit site for the left ventricle drive line. Another skin incision, for the right one, is made five cm medial to the previous one. This distance is important to avoid any skin necrosis between the two exit sites. The pathway is enlarged with a clamp and a size 40 F chest tube is grasped from the pericardium and

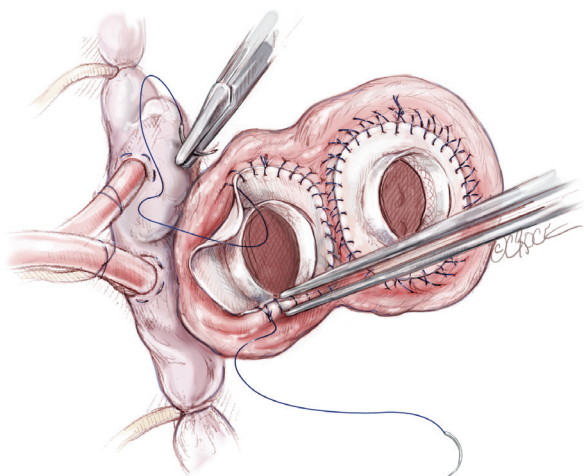


Figure 5 Atrial connectors are placed in the right and left cuffs with a double layer of prolene 3-0. We do not use any Felt Strip reinforcement around the atrial cuffs.

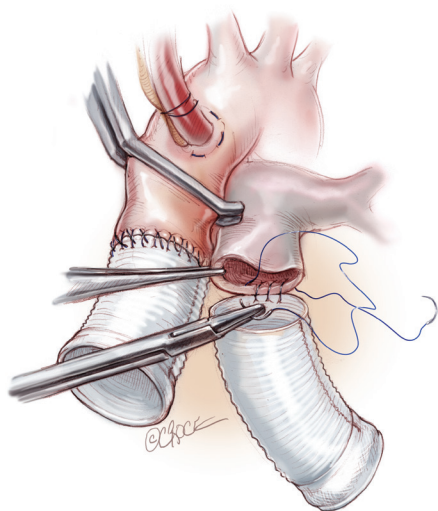


Figure 6 Anastomosis of the great arteries is performed. The outflow conduits are trimmed to size (3-4 cm for the aortic graft; 6-7 cm for the pulmonary one). The end-to-end anastomosis is done with a double layer 4-0 prolene.

pulled out through the skin. The driveline tubing of the left ventricle is placed in the chest tube and pulled out through the skin. A similar process is done for the right ventricle (*Figure 8*).

Connection and deairing

The left ventricle is connected first. Careful assessment

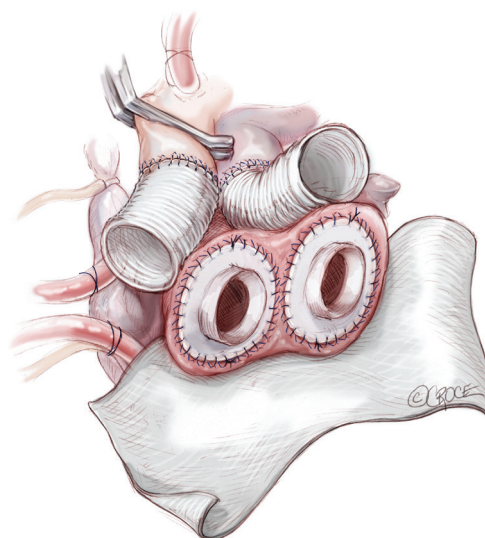


Figure 7 Before placement of the ventricles, we suture two large sheets of Gore-Tex to the atrioventricular groove in order to facilitate the reentry at the time of transplantation.

of the exact position of the ventricle and its orientation is crucial at this stage. The left atrial quick connector is grasped with two Mayo clamps and while pulling on them, the ventricle is pushed into the quick connector in its final position (*Figure 9*). The ventricle is rotated slightly to adjust position as necessary to allow a good course for the outflow graft. Ventilation is resumed to allow filling of the ventricle. The aortic cross clamp may be removed under low bypass flow for a few seconds to fill the aortic conduit. At this time, the aortic quick connection to the ventricle is accomplished, avoiding any twisting of the graft. The graft is examined. If there is felt to be a kink, the outflow conduit is disconnected by placing a spatula or flat instrument between the quick-connect and the ventricular connection to disarticulate the connection. Once the connection is deemed satisfactory, the patient is placed in a steep Trendelenburg position and a needle vent is placed in the aortic graft. Ventilation is restarted, as well as gentle suction through the vent. The right artificial ventricle is then connected in a similar fashion, starting with the atrial side first and then the pulmonary side. Before connecting the pulmonary graft, the right side is deaired by partially occluding the venous line (*Figure 10*).

A needle vent is placed in the aorta and another in the pulmonary outflow conduit. The cross clamp is removed. With the patient in Trendelenburg and lungs being ventilated, pumping is begun at a very slow rate with deairing through the aortic vent. Further de-airing,

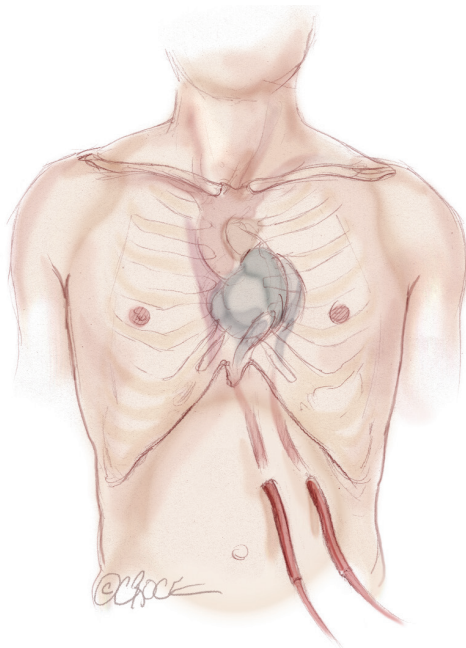


Figure 8 The two drivelines are tunnelled under the skin and the artificial ventricle brought into the surgical field. The exit of the left driveline is seven to 10 cm below the left costal margin along the mid clavicular line. The exit of the right driveline is generally five cm medially from the left one.

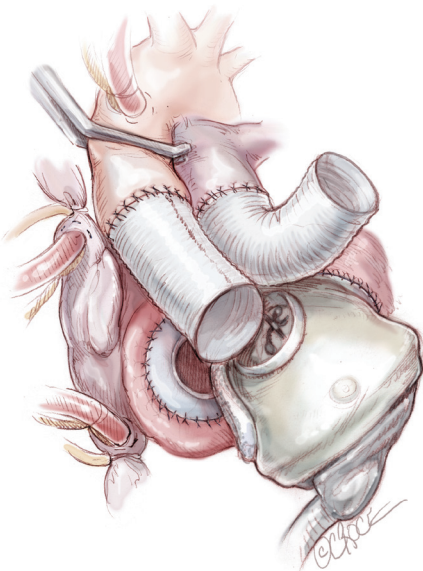


Figure 9 The left ventricle is connected first. Careful assessment of the exact position of the ventricle and its orientation is crucial at this stage. The left atrial quick connector is grasped with two Mayo clamps and while pulling on them, the ventricle is pushed into the quick connector in its final position.

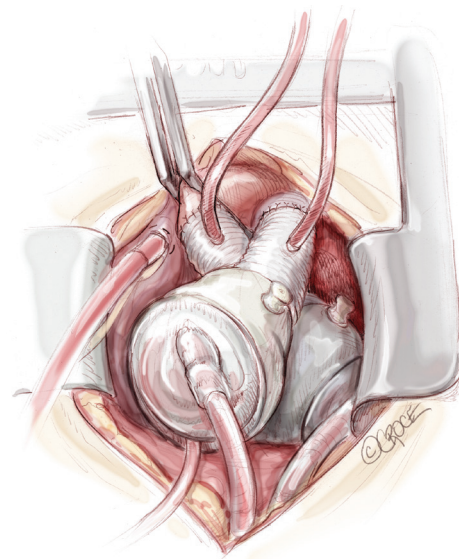


Figure 10 Total artificial heart in final position inside the chest. A vent is placed in the pulmonary graft and in the aortic graft before releasing the aortic cross clamp.

guided by TEE, is accomplished by gentle agitation of the ventricles and atria. This process takes generally 10 to 15 minutes. Meanwhile, the TAH is pumping, increasing the heart rate, and patient is weaned from the cardiopulmonary bypass.

Closure

Protamine is administered and cardiopulmonary bypass cannulae are removed. Careful hemostasis is accomplished—in the very coagulopathic patient, this process might be protracted, but it is imperative to aim to not to leave the operating room until the field is dry. Before chest closure, a Gore-Tex membrane is wrapped around the anterior surface of both artificial ventricles as well as the tunnelled drivelines. Contraction of the pericardial cavity around the device has been observed in numerous TAH patients and can limit the space available for subsequent transplantation. A saline filled breast implant or tissue expander may be used to maintain the apical pericardial space for subsequent transplant (*Figure 11*). The chest is then closed in standard fashion. Because sternal dehiscence and mediastinitis is catastrophic in the setting of the TAH, closure must be done in a meticulous fashion. For large patients, use of closure devices (other than simple wires) may be considered.

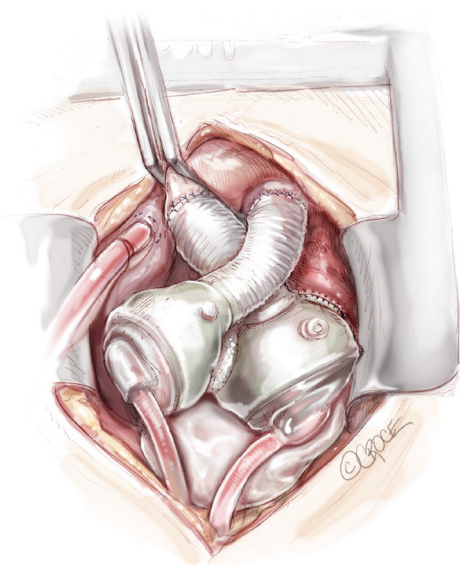


Figure 11 A breast implant is generally left in the pericardium to avoid contraction of the mediastinum around the total artificial heart (TAH) and leave space inside the chest cavity for the donor heart at the time of transplantation.

Challenging scenario

Small chest

Traditionally, a BSA less than 1.7 m^2 or a distance between the sternum and the anterior vertebral body of less than 10 cm were considered absolute contraindications to implant the SynCardia TAH. In recent years, some groups have reported successful implantation of SynCardia TAH in small patients with a BSA less than 1.7 m^2 (6). Specialized manoeuvres are generally required in this setting. It is critical to mobilize the diaphragmatic attachment of the pericardium to allow the device to sit more leftward and posteriorly in the chest. This requires opening of the left pleura and allows the TAH to slightly migrate into the left pleural space. The left ventricle should be wrapped with a Gore-Tex membrane preventing lung adherence to the device. The IVC is particularly susceptible to compression in patients with small chest cavities. The left sided pulmonary veins are also susceptible to compression by a tightly fitting device. Anchoring both ventricles to a rib on the left chest wall may be helpful in order to laterally displace the TAH away from the IVC and left pulmonary veins. The ventricles then lie mostly to the left of the sternum, with the left ventricle in the left pleural cavity, as opposed to the usual placement where the right ventricle is immediately posterior to the sternum.

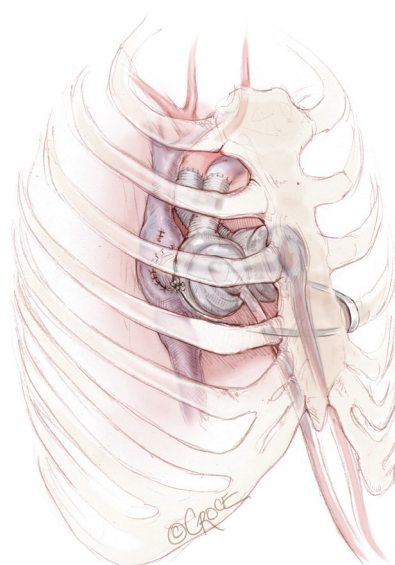


Figure 12 Umbilical tape or a heavy silk or polyester suture is generally wrapped two or three times around the main body of the left artificial ventricle; the two ends of the tape or suture are then tunneled outside the chest through an intercostal space and tied around one of the rib in order to displace the left artificial ventricle.

Umbilical tape or a heavy silk or polyester suture is generally wrapped two or three times around the main body of the left artificial ventricle; the two ends of the tape or suture are then tunneled outside the chest through an intercostal space and tied around one of the ribs in order to displace the left artificial ventricle (*Figure 12*). The ideal position of the ventricle is determined by a combination of echocardiographic and hemodynamic evaluation combined with observation of the TAH fill-volumes. Once the ideal position is identified, the suture or tape is tied. Further adjustments may still be required when the sternum is closed. It is critical for the echocardiographer to confirm laminar flow into all left-sided veins and the IVC prior to chest closure. Ventricular filling should also be maintained after closure. In some cases, all attempts to close the chest will result in venous obstruction despite corrective manoeuvres—in this case, the chest is left open and the patient returned to intensive care. Chest closure can be re-attempted at a later date. In rare cases, if chest closure cannot be accomplished, then musculocutaneous flap closure may be required.

Congenital heart disease

Patients with complex congenital heart disease and end-

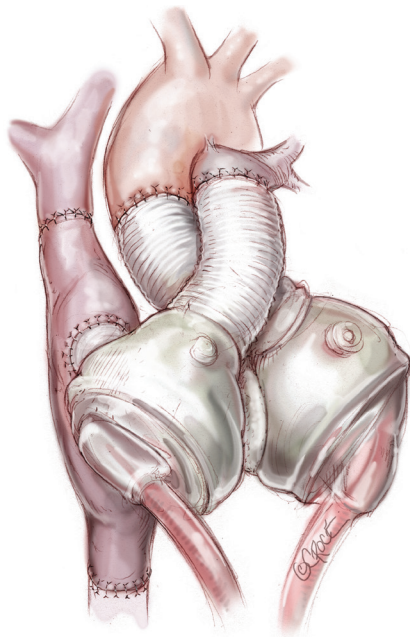


Figure 13 Total artificial heart (TAH) in a Fontan physiology patient.

stage cardiomyopathy are ideal for SynCardia TAH placement, as most intracardiac anomalies will be excluded by excision of the heart. Following cardiac excision, a TAH can usually be implanted in a similar way to orthotopic heart transplantation. This surgery is often easier than attempts at repeat technical correction. There are, however, some situations where congenital cardiac disease poses unique surgical challenges for TAH implantation. These are typically situations where a patient has a univentricular physiology or where there is transposition of the great vessels.

In case of failed 'Fontan' operations, the TAH has been implanted after constructing a 'neo right atrium' (neo RA) in order to fit the right atrial quick connector (7). The extracardiac conduit and IVC are both separated from the right pulmonary artery, which is reconstructed with a bovine pericardial patch or autologous tissue explanted from the failing heart. Next, a 24 or 26 mm Gore-Tex graft, is inserted as an interposition graft between the SVC and IVC to serve as 'neo RA'. The left atrial cuff is prepared in a standard fashion and any interatrial communication is carefully addressed at this stage. The 'neo RA' tubing graft is opened in a generous elliptical shape in order to accommodate the right atrial quick connector. The outflow grafts are then sutured in an end-to-end fashion on the aorta and end to

side fashion at the pulmonary artery bifurcation. The length of the pulmonary graft is generally longer than the usual six to seven cm and should be addressed carefully before proceeding with the distal anastomosis (7) (Figure 13).

The SynCardia TAH has also been used in cases of congenital corrected transposition of the great arteries (cc-TGA). In this congenital heart disease, the challenge of TAH implantation is represented by the position of the great arteries (aorta and pulmonary artery), with the aorta anterior and leftward to the pulmonary artery, which require the right and left pumps to be implanted in a parallel rather than normal criss-cross arrangement (8).

Extracorporeal membrane oxygenation (ECMO) at the time of TAH

Pulmonary edema, is often present in cardiogenic shock patients requiring biventricular support and may necessitate ECMO to maintain adequate oxygenation.

Veno-arterial ECMO may be undertaken but will result in two parallel circuits with reduced flow through the TAH. Flow is balanced to allow the lowest ECMO flow that will ensure an acceptable level of oxygenation. However, such set-up could predispose to thrombosis of the mechanical valves due to lower TAH flow and therefore not ideal if a prolonged period of ECMO is anticipated. Veno-venous ECMO is therefore preferable as it allows the ECMO and TAH circuits to run in series with maximal flows permissible on both. Veno-venous ECMO can be instituted in different ways while a TAH is in place. A single dual-lumen catheter (Avalon Elite[®], Maquet Cardiovascular, Germany) may be placed via the internal jugular vein. Care must be taken when introducing the cannula with the Seldinger technique, so as not to entrap the wire or the cannula into the mechanical right atrioventricular valve of the TAH. This technique is particularly suited to the patient who develops respiratory failure in the intensive care unit hours or days after TAH implant. For patients who require ECMO for weaning from cardiopulmonary bypass, other options are required, as the right internal jugular vein is generally not accessible. Our preferred approach is to place a femoral venous cannula and advance it such that the tip lies in the intrahepatic portion of the inferior IVC—this will serve as the inflow for the ECMO (9). For the ECMO outflow, a separate venous cannula via the other femoral or a subclavian vein, is placed and advanced a few centimeters into the right atrium under sonographic guidance. If ECMO is anticipated preoperatively, then cannulae are

placed before instituting cardiopulmonary bypass, with final adjustment of outflow cannula position made under direct vision after excision of the native heart to ensure adequate distance of the cannula tip from the right-sided atrioventricular valve. The ECMO circuit therefore draws blood from the infrahepatic IVC and returns it to the right atrium. Blood returning via the SVC is not oxygenated. This setting allows the explantation of veno-venous ECMO at the bedside of the patient. Adequate distance between the tips of both cannulae should be ensured to avoid short-circuit phenomenon.

An alternative approach which has been reported (10) involves placing a cannula in the main pulmonary artery for ECMO inflow and another in the left atrium for outflow. This allows a parallel circuit and has the theoretical advantage of excluding the lungs from a substantial part of cardiac output, thereby promoting recovery of the edematous lung. However, this approach is cumbersome and may risk systemic embolization, necessitating chest re-exploration for decannulation.

Comments

Methods for implanting the TAH are now well established, making this a versatile tool that can be applied to a diversity of patients with advanced biventricular cardiac failure. Operative results have improved considerably over the last two decades, and despite the severity of illness of recipients, several centers reported successful bridge to transplant rates of up to 70%. The SynCardia TAH therefore currently provides the most definitive option for most patients who are not candidates for isolated LV assist device placement. The techniques for implantation are adaptable to almost all patients with advanced heart failure, including those with severe biventricular cardiomyopathy; complex congenital heart disease; failed LV assist devices; failed transplantations; and acquired structural heart defects that have failed or are not amenable to conventional surgical treatment.

Cite this article as: Torregrossa G, Anyanwu A, Zucchetta F, Gerosa G. SynCardia: the total artificial heart. *Ann Cardiothorac Surg* 2014;3(6):612-620. doi: 10.3978/j.issn.2225-319X.2014.11.07

Acknowledgements

Disclosure: The authors declare no conflict of interest.

References

1. DeVries WC, Anderson JL, Joyce LD, et al. Clinical use of the total artificial heart. *N Engl J Med* 1984;310:273-8.
2. El-Banayosy A, Arusoglu L, Morshuis M, et al. CardioWest total artificial heart: Bad Oeynhausen experience. *Ann Thorac Surg* 2005;80:548-52.
3. Copeland JG, Smith RG, Arabia FA, et al. Cardiac replacement with a total artificial heart as a bridge to transplantation. *N Engl J Med* 2004;351:859-67.
4. Copeland JG, Copeland H, Gustafson M, et al. Experience with more than 100 total artificial heart implants. *J Thorac Cardiovasc Surg* 2012;143:727-34.
5. Kirsch ME, Nguyen A, Mastroianni C, et al. SynCardia temporary total artificial heart as bridge to transplantation: current results at la pitié hospital. *Ann Thorac Surg* 2013;95:1640-6.
6. Leprince P, Bonnet N, Varnous S, et al. Patients with a body surface area less than 1.7 m² have a good outcome with the CardioWest Total Artificial Heart. *J Heart Lung Transplant* 2005;24:1501-5.
7. Rossano JW, Goldberg DJ, Fuller S, et al. Successful use of the total artificial heart in the failing Fontan circulation. *Ann Thorac Surg* 2014;97:1438-40.
8. Adachi I, Morales DS. Implantation of total artificial heart in congenital heart disease. *J Vis Exp* 2014;(89).
9. Hosseinian L, Levin MA, Fischer G, et al. Hemodynamic deterioration during ECMO weaning in a patient with a total artificial heart. *Critical Care Medicine* 2014. (In press)
10. Anderson E, Jaroszewski D, Pierce C, et al. Parallel application of extracorporeal membrane oxygenation and the CardioWest total artificial heart as a bridge to transplant. *Ann Thorac Surg* 2009;88:1676-8.

Illustrated techniques for performing the Cox-Maze IV procedure through a right mini-thoracotomy

Jason O. Robertson, Lindsey L. Saint, Jeremy E. Leidenfrost, Ralph J. Damiano Jr

Division of Cardiothoracic Surgery, Department of Surgery, Washington University School of Medicine, Barnes-Jewish Hospital, St. Louis, MO, USA

Introduction

The first effective surgical procedure to treat atrial fibrillation (AF) was introduced by Dr James Cox in 1987 after extensive animal investigation. This procedure, now formally known as the Cox-Maze procedure, utilized a biatrial “cut-and-sew” technique in an attempt to guide the native sinus impulse to both atria and the atrioventricular (AV) node while blocking all possible macroreentrant circuits. By restoring sinus rhythm and AV synchrony while maintaining atrial transport function, the Cox-Maze procedure significantly reduced the risk of thromboembolism, stroke and hemodynamic compromise (1,2). It was designed to provide a standardized approach that would be effective in all patients. Unfortunately, the first version of the Cox-Maze procedure was complicated by late chronotropic incompetence and a high rate of pacemaker implantation (3). To address the problem, the Cox-Maze procedure underwent two further modifications, eventually resulting in the Cox-Maze III. This lesion set became the gold standard for the surgical treatment of AF (4). Despite its clinical success, however, the procedure was seldom performed due to its technical complexity and prolonged time on cardiopulmonary bypass (CPB).

In order to simplify the Cox-Maze procedure, our group replaced the majority of the incisions of the Cox-Maze III with a combination of bipolar radiofrequency (RF) and cryothermal ablation lines in a procedure termed the Cox-Maze IV, which was introduced clinically in 2002. This and the introduction of other ablation-based procedures have resulted in a dramatic increase in the number of operations performed annually for AF. In 2005, 12,737 patients were reported to the STS Database as having undergone a surgical procedure for AF, whereas one year prior the number of patients was 3,987 (5). Before 2004, the volume was so low that the operation was not reported. While exact numbers have not been published, the number of AF procedures performed annually has continued to increase over the last several years.

Several different lesion sets, including isolated pulmonary vein isolation (PVI), extended left atrial lesion sets and hybrid procedures have been performed with various results. Similarly, a variety of ablation technologies have been employed by different groups. Some of these devices have been removed from the market due to poor performance. Greater uniformity in both technique and follow-up standards (6) is needed if outcomes are to be compared. This review aims to clearly relate and illustrate proper techniques for successfully performing a Cox-Maze IV procedure, as well as to provide insight into our choice of ablation technology and the reasons why certain critical steps are performed.

Operative techniques

Preoperative evaluation

Patient-specific anatomical considerations, particularly left atrial substrate, may affect operative outcomes. The left atrial diameter and volume should be obtained in all patients using transthoracic echocardiography (TTE). Increases in these measurements are associated with a higher failure rate of the CMIV procedure (7). Once left atrial diameter is ≥ 8 cm, the failure rate is over 50%, and this may influence the decision as to whether to proceed with surgical ablation. TTE is also useful to characterize the degree and nature of concomitant valvular disease. Moreover, patients with prior failed catheter ablations should undergo a pulmonary vein (PV) protocol computed tomography (CT) scan in order to exclude PV stenosis. While rarely detected, PV stenosis would require repair if identified. Finally, coronary angiography is recommended in order to identify any existing lesions and to define the anatomy. The circumflex artery is at risk of injury during the mitral isthmus ablation in patients with a left-dominant circulation. Significant atrial fibrosis secondary to long-standing AF may also affect outcomes. However, there are not currently any validated methods available to assess this preoperatively. Delayed-

enhancement cardiac magnetic resonance imaging (DE-MRI) is one promising technique that is currently under investigation (8-10).

There are also a few preoperative considerations unique to performing a Cox-Maze IV through a right mini-thoracotomy. First, a detailed history of pulmonary disease and sleep apnea should be obtained, with further evaluation undertaken if there are any perceived difficulties with performing single-lung ventilation. Second, patients at risk of vascular disease and those over 65 years of age should undergo a CT angiogram of the thoracic and abdominal aorta, iliac and femoral vessels and a carotid Doppler ultrasound to assess the quality of aortic disease and the safety of femoral cannulation.

Most patients are referred for AF correction surgery with excellent documentation of their rhythm abnormalities. However, in patients for whom this is not the case, it is recommended that the surgeon obtain prolonged Holter monitoring. Event monitors are particularly helpful in patients with paroxysmal arrhythmias to determine whether symptoms are related to arrhythmia occurrence.

Management of anti-arrhythmic and anticoagulation therapies is also usually required in the immediate preoperative period. Generally, anti-arrhythmic and rate-control medications should be continued through the morning of surgery. Patients who have been anticoagulated with warfarin are typically managed with intravenous heparin or bivalirudin in the preoperative period.

Preparation

Typically, a large bore peripheral intravenous line and an intra-arterial pressure catheter are placed in the preoperative holding area. After induction, a 9 French introducer catheter is placed in the right internal jugular vein using ultrasound guidance. Generally, a pulmonary artery catheter (PAC) is not used since it often gets in the way of performing the right atrial lesions. If it is felt to be necessary for postoperative monitoring, the PAC is left in the superior vena cava (SVC) until the end of the case. Another strategy is to place a dual-lumen infusion catheter at the onset of the case and convert to a PAC if needed at the end of the procedure.

Although all patients undergo a TTE during preoperative assessment and planning, the left atrial appendage (LAA) is not well visualized with this modality, and, therefore, thrombus cannot be excluded with certainty. Prior to the start of the operation, the left

atrium is thoroughly examined with transesophageal echocardiography (TEE) using a variety of angles to exclude thrombus in the LAA. In patients with thrombus in the LAA, the sequence of the operation is altered so that there is minimal manipulation of the heart. At this time, the atrial septum is also assessed for the presence of a patent foramen ovale, which should be repaired if present. If the patient has concomitant mitral valve dysfunction noted on preoperative transthoracic echocardiography, it is confirmed using two-dimensional, color-flow Doppler and three-dimensional modalities. The rest of the heart is then examined for signs of concomitant disease. At the conclusion of the procedure, TEE is used to confirm successful exclusion of the LAA and, when appropriate, satisfactory repair or replacement of the MV.

In the absence of specific allergies, the patient is given intravenous cefazolin and vancomycin thirty minutes prior to skin incision. Intravenous cefazolin is re-dosed after separation from CPB, and both antibiotics are continued for 48 hours postoperatively.

Positioning

The patient is brought to the operating room and placed in the supine position on the operating room table. The patient is intubated using a regular endotracheal tube with a bronchial blocker for single-lung ventilation. In some patients, a double lumen endotracheal tube is used to achieve similar results. In preparation for a right mini-thoracotomy, the patient is positioned with the right chest elevated at approximately a 30-45° angle, with the hips as flat as possible against the operating room table (*Figure 1*). The right arm is brought over the patient's head and placed in an anatomic position on an elevated arm board.

The patient is prepped circumferentially from the chest to the ankles with multiple layers of chlorhexidine gluconate/isopropyl alcohol antiseptic solution. An antimicrobial surgical drape with an iodophor impregnated adhesive is then applied to the patient's chest, abdomen and groin.

Cannulation

In the absence of any contraindications, the right femoral vessels are used for CPB. The femoral pulse is palpated at the level of the inguinal ligament, and the location is marked on the skin (*Figure 1*). A 2 cm subinguinal incision is performed parallel to the skin creases, overlying the

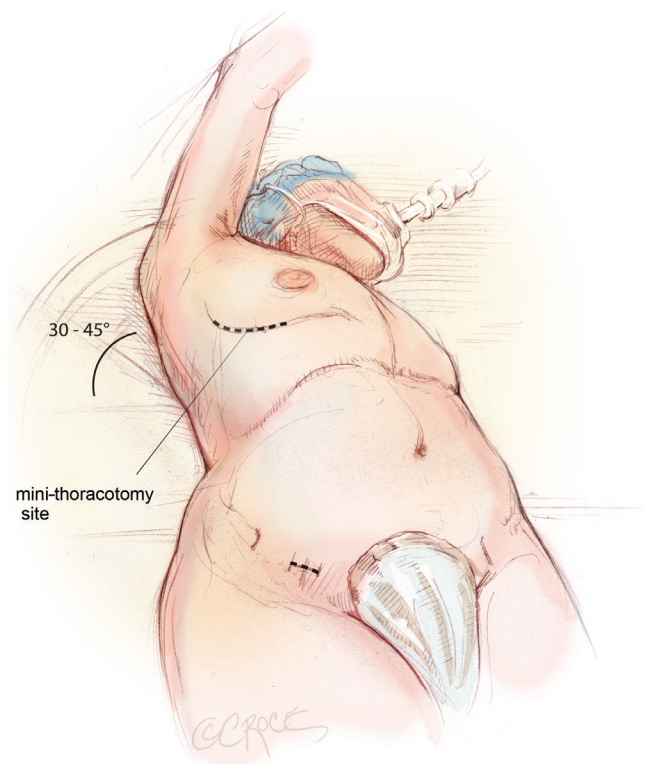


Figure 1 Positioning and marking in preparation for a Cox-Maze IV procedure performed through a right mini-thoracotomy. This depiction of the procedure on a woman demonstrates a submammary incision, as well as a subinguinal incision that is used to dissect the femoral vessels and initiate cardiopulmonary bypass (CPB).

area of the femoral pulse, and the femoral artery and vein are exposed. Proximal and distal control of the vessels is obtained, and the patient is cannulated using a 25 French venous cannula and either a 17 or 19 French arterial cannula, depending on the size of the femoral artery. The arterial cannula is placed first and TEE is used to confirm placement of the guidewire in the descending thoracic aorta in order to prevent an aortic injury. The venous cannula is then advanced into the right atrium until resistance is felt. It is ultimately advanced to the SVC by palpation or TEE guidance. The patient is fully anticoagulated with heparin to obtain an ACT ≥ 500 , and systemic anticoagulation is maintained throughout the procedure according to the standardized heparin protocol used for CPB.

Postoperative bleeding is a relatively rare event with the Cox-Maze IV (11). However, in order to further minimize this risk, the patient is routinely given intravenous

tranexamic acid at a dose of 10 mg/kg prior to the initiation of CPB, with further infusion of 5 mg/kg up to a total dose of 3 gm. If the patient has other independent risk factors for bleeding, the dose of intravenous tranexamic acid is increased to as high as 30 mg/kg. In the setting of renal insufficiency or independent risk factors for thrombosis, the bolus and infusion doses are reduced or eliminated, as appropriate.

Surgical approach

When the CMIV is performed as a lone operation or as a concomitant procedure to mitral valve surgery, we favor a less invasive right mini-thoracotomy approach in the absence of any contraindications. This is the approach that we will focus on in this review. We reserve a median sternotomy for patients with peripheral vascular disease that precludes femoral cannulation, a history of previous right thoracotomy, severe left ventricular dysfunction, or chest wall deformities such as pectus excavatum.

The 5-6 cm right mini-thoracotomy incision is made over the fourth intercostal space lateral to the nipple in the mid-axillary line in men, whereas a submammary incision is used in women (*Figure 1*). The chest is entered through the fourth intercostal space, and a small segment of the posterior fifth rib is divided. Access to the fourth intercostal space requires tunneling to the appropriate level when a submammary incision is used. A soft tissue retractor is used to provide exposure through the mini-thoracotomy, and it is further secured to the skin using additional Ioban adhesive sheets. It is important not to use a metal retractor for rib spreading, as this increases postoperative pain.

CBP is established with the patient initially maintained at normothermia, and the right lung is deflated. A Blake drain is placed percutaneously via a stab wound on the lateral chest wall, usually overlying the right seventh intercostal space along the mid-axillary line, and positioned into the posterior pleural space. Carbon dioxide is infused into this drain throughout the entire case to prevent air embolism. If needed, a pledgeted 0 Tevdek suture is then used to retract the diaphragm and provide exposure. The stitch should be placed superficially so as to avoid liver injury, and retraction is performed by passing the suture through the incision created for placement of the Blake drain.

Initial exposure and pulmonary vein isolation (PVI)

The pericardium is opened from the diaphragm to the mid-

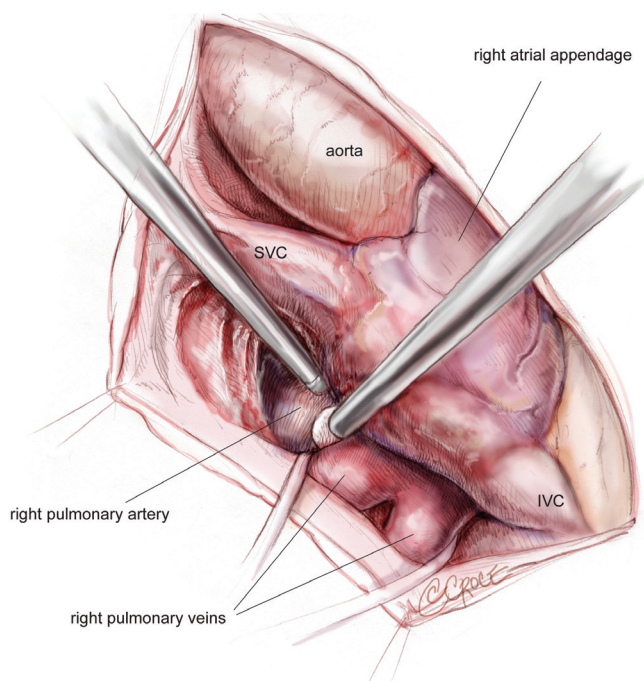


Figure 2 Mobilization of the space between the right superior pulmonary vein and the right pulmonary artery from underneath the SVC, entering into the oblique sinus. SVC, superior vena cava.

ascending aorta, with care taken to make the pericardiotomy about 2-4 cm away from the phrenic nerve in order to avoid subsequent traction injury. The heart is suspended in a pericardial cradle. A 5 mm, 30-degree endoscope is then placed through a port in the 6th intercostal space close to the posterior-axillary line. The SVC and inferior vena cava (IVC) are mobilized. The space underneath the SVC, the area between the right superior PV and the right pulmonary artery, and the oblique sinus are developed (*Figure 2*). It is important to bluntly divide the tissue between the posterior wall of the aorta and the anterior wall of the pulmonary artery in order to create room for the aortic cross-clamp. Dissections of the transverse sinus and Waterson's groove (indicating the position of the interatrial septum) are also completed from below the SVC. The LAA will be visible through the transverse sinus. It must be remembered that these planes may be replaced with significant amounts of scar in patients who have had multiple previous ablations. All of these dissections are typically performed using Bovie electrocautery and an endoscopic Kittner.

The right PVs are bluntly dissected and encircled with umbilical tape using a renal pedicle clamp. Once the exposure is complete, amiodarone is administered, and the

patient is electrically cardioverted to normal sinus rhythm if necessary. Pacing thresholds are obtained from the right superior and inferior PVs using a bipolar pacing probe. The right PVs are then isolated using a bipolar RF clamp, such that a linear line of ablation surrounds as large a cuff of atrial tissue around the PVs as possible (*Figure 3*). Three sequential ablations are performed with slight adjustments in position, effectively forming three closely approximated concentric circles. Importantly, if the surgeon is using a non-irrigated bipolar clamp, the jaws must be cleaned of char every 2-3 ablations in order to ensure creation of transmural lesions. PV isolation is documented by pacing at 20 mA from both the right superior and inferior PVs in order to confirm exit block. Further ablations are performed as needed until exit block is obtained.

Right atrial lesion set

The right-sided lesions of the CMIV are created on CPB before aortic cross-clamping. A purse-string suture is placed just above the interatrial septum, midway between the SVC and IVC. Care should be taken to avoid the crista terminalis due to the thickness of the tissue in that area. A stab incision is created in the center of the purse-string, and one jaw of the bipolar RF clamp is introduced into the right atrium. Using the clamp, ablation lines are performed up onto the SVC, down onto the IVC, and across the right atrial free wall toward the AV groove near the acute margin of the heart (*Figure 4*). The IVC ablation line should travel as far as possible onto the IVC, and the ablation line onto the SVC should be performed as lateral/posterior as possible to minimize risk of injury to the sinus node complex. For each of these lines and all subsequent lines created using the bipolar RF clamp, three discrete ablations are performed with slight adjustments in clamp position in order to ensure isolation.

From the superior aspect of the right atrial free wall ablation line, a second purse-string suture is placed near the AV groove, being careful to avoid ensnaring the right coronary artery. This purse-string should be at the end of the prior right atrial free wall ablation in order to connect that lesion with the next. Placement of this purse-string is facilitated by allowing volume to temporarily fill the heart, which pushes the atrium towards the surgeon. A stab incision is then made in the center of the purse-string, and a 3-cm reusable linear cryoprobe is used to create an endocardial cryoablation down to the tricuspid valve annulus at the 1 o'clock position (*Figure 5*). The

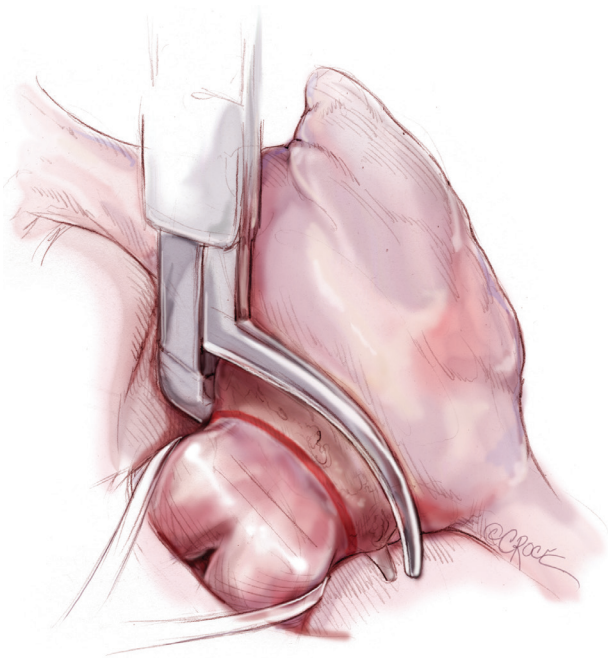


Figure 3 Right-sided pulmonary vein isolation using a bipolar RF clamp. RF, radiofrequency.

cryoprobe should be palpated in the right ventricle prior to freezing, and further confirmation that placement is correct is obtained when the beating heart deflects the probe. Cryoablations are all performed at -60°C for three minutes each.

A third purse-string suture is placed at the base of the right atrial appendage. One jaw of the bipolar RF clamp is introduced through a stab incision created in the center of the purse-string, and a right atrial free wall ablation is created for several centimeters down toward the SVC (*Figure 6*). At least two centimeters should be left between the end of this ablation line and the SVC line in order to avoid the sinus node. The linear cryoprobe is then placed into the right atrium and used to create a second endocardial cryoablation down to the tricuspid annulus at the 11 o'clock position (*Figure 7*).

A transthoracic cross-clamp is then positioned via a stab wound in the right lateral chest wall. An aortic purse-string is placed, and a catheter for the administration of antegrade cardioplegia and aortic root venting is inserted into the proximal ascending aorta. The aorta is then cross-clamped, and the patient is cooled to 34°C . Cold blood cardioplegia is given in an antegrade fashion to obtain myocardial protection, and additional doses of cardioplegia are

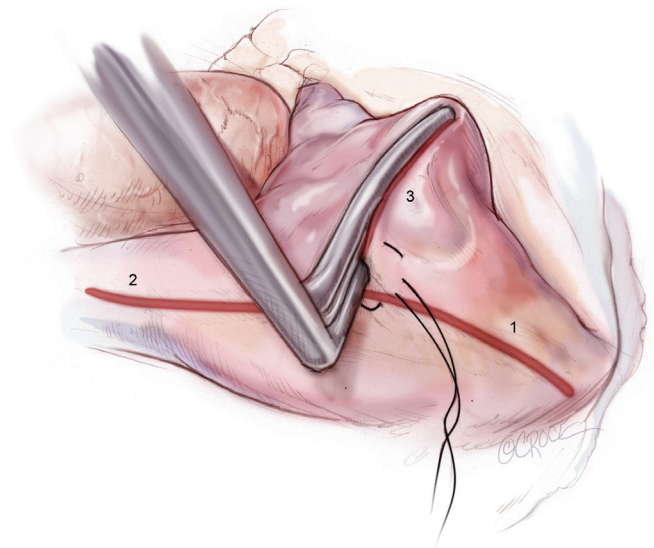


Figure 4 Ablations of the [1] IVC, [2] SVC and [3] right atrial free wall directed towards the AV groove near the acute margin of the heart. Ablations are performed using a bipolar RF clamp through a purse-string suture placed midway between the SVC and IVC. IVC, inferior vena cava; SVC, superior vena cava; AV, atrioventricular; RF, radiofrequency.

administered at regular intervals throughout the remainder of the case.

Left atrial lesion set

A left atrial lift system is positioned through a stab wound in the anterior chest wall at the 4th intercostal space. It is necessary to create this stab wound under direct visualization in order to prevent injury to the right internal mammary artery. Once placed, the left atrium is opened, and the lift system is used to expose the MV and the posterior left atrium (*Figure 8*). The LAA is oversewn in two layers using a pledgeted, running 4-0 non-absorbable, monofilament polypropylene suture placed from the endocardial surface (*Figure 9*).

Complete posterior LA isolation is achieved by completing a “box” lesion set. From the inferior aspect of the left atriotomy, the bipolar RF clamp is used to create an ablation line across the floor of the left atrium towards the orifice of left inferior PV (*Figure 10*). From the superior aspect of the left atriotomy, the bipolar RF clamp is used to create another ablation line across the roof of the left atrium towards the left superior PV (*Figure 10*).

The next step is completion of the mitral isthmus line.

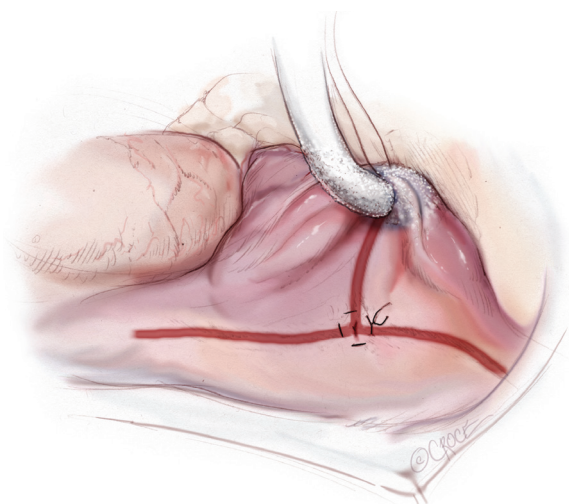


Figure 5 Cryoablation towards the tricuspid annulus at the 1 o'clock position through a second purse-string suture that is placed near the AV groove at the end of the right atrial free wall ablation line. AV, atrioventricular.

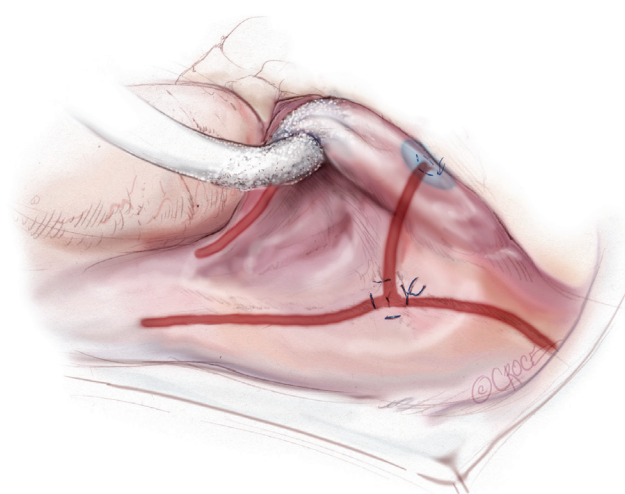


Figure 7 Completion of the right atrial lesion set with creation of an endocardial cryoablation to the 11 o'clock position of the tricuspid annulus. This is performed using a linear cryoprobe inserted through the purse-string at the base of the RAA.

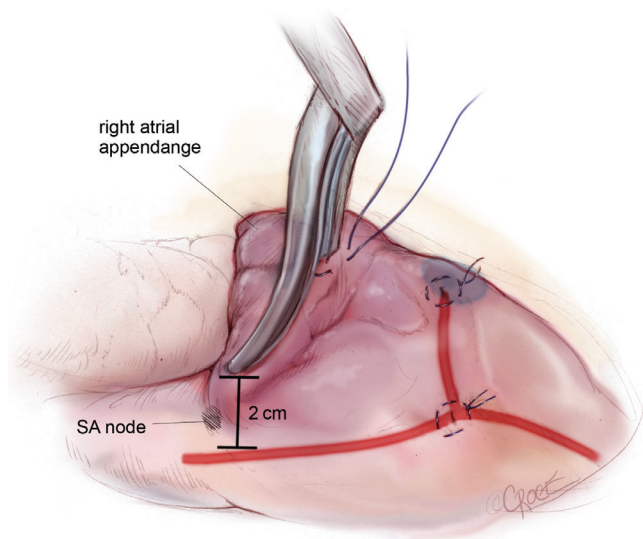


Figure 6 Second right atrial free wall ablation performed using a bipolar RF clamp. The clamp is placed through a third purse-string at the base of the RAA. At least two centimeters should be left between this ablation line and the SVC line in order to avoid injury to the sinus node. RF, radiofrequency; SVC, superior vena cava.

In order to ablate the complex anatomy of the mitral isthmus, it is necessary to use a combination of bipolar RF and cryothermal energy. The bipolar RF clamp is unable to create a lesion all the way to the mitral annulus because

of the thickness of the AV groove in that area. Therefore, the bipolar RF clamp is used from the inferior aspect of the left atriotomy to create an ablation line across the floor of the left atrium, down towards the MV annulus and across the coronary sinus when possible (*Figure 10*). In order to connect the bipolar ablation line to the annulus, it is usually necessary to bridge a 1-2 cm gap. The end of the bipolar ablation line is marked with methylene blue to provide a starting point for further ablations down to the annulus (*Figure 11*). We prefer to perform an endocardial cryoablation with a T-shaped cryoprobe (*Figure 11*) because cryoablation preserves the fibrous skeleton of the heart, making it ideal for ablation near valvular tissue. Of note, a lap pad is placed underneath the shaft of the cryoprobe during this ablation because frost forming along the shaft of the device has potential to injure the phrenic nerve. The coronary sinus must be ablated in line with the isthmus lesion in order to ensure a complete line of block. We typically accomplish this with an epicardial cryoablation overlying the coronary sinus that is performed with a linear probe (*Figure 12*). The cryoprobe that was used to ablate the annulus is left in place during the coronary sinus ablation so that tissue can be compressed between the shaft of the endocardial probe and the active portion of the epicardial probe. This ensures that a full thickness ablation is achieved. The bipolar clamp is not always successful in ablating the full thickness of the coronary sinus due to

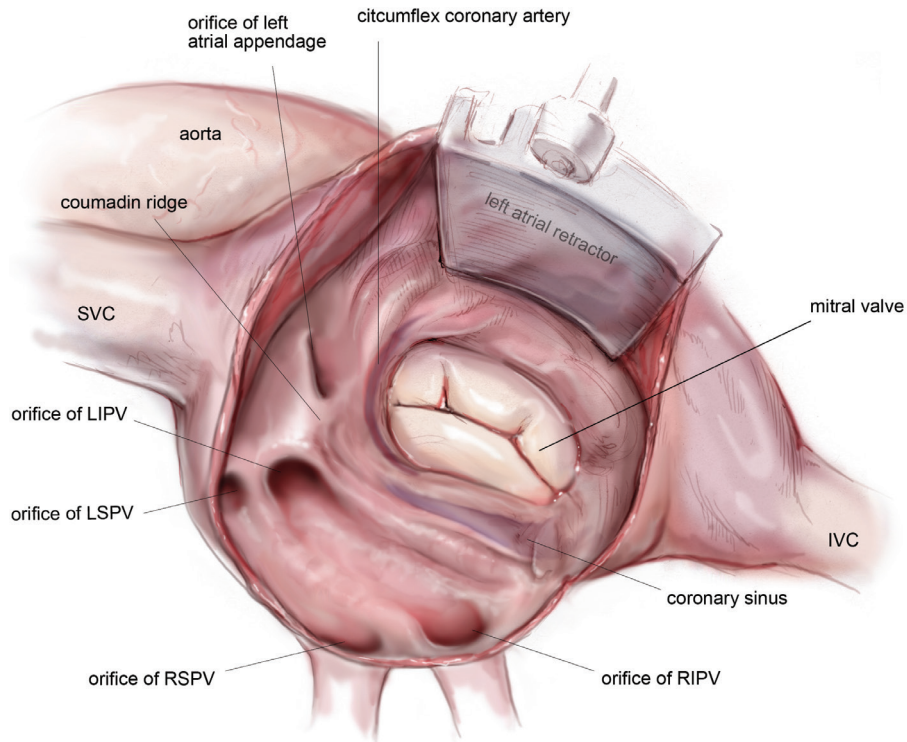


Figure 8 Anatomy of the left atrium following an atriotomy. Exposure is obtained using a left atrial lift system. In a left dominant system, the circumflex artery wraps further around the mitral valve, parallel to the coronary sinus. SVC, superior vena cava; LIPV, left inferior pulmonary vein; LSPV, left superior pulmonary vein; RSPV, right superior pulmonary vein; RIPV, right inferior pulmonary vein; IVC, inferior vena cava.

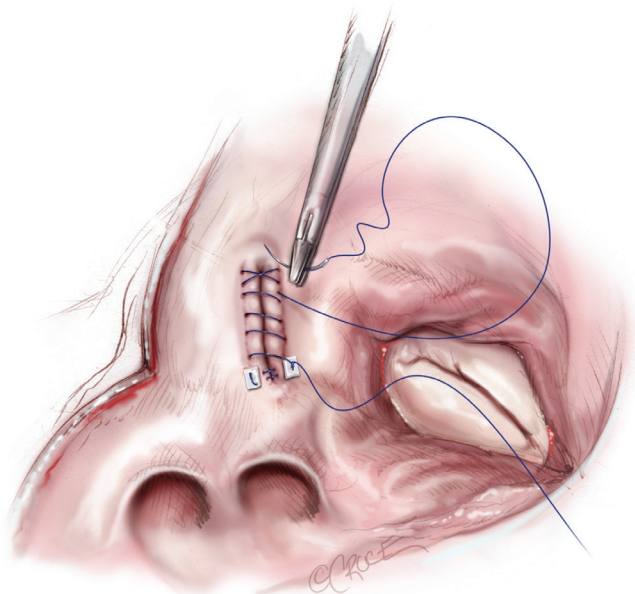


Figure 9 Closure of the left atrial appendage from the endocardial surface of the left atrium. The appendage is oversewn in two layers using a running suture, starting with a pledgeted horizontal mattress stitch at the inferior corner of the orifice.

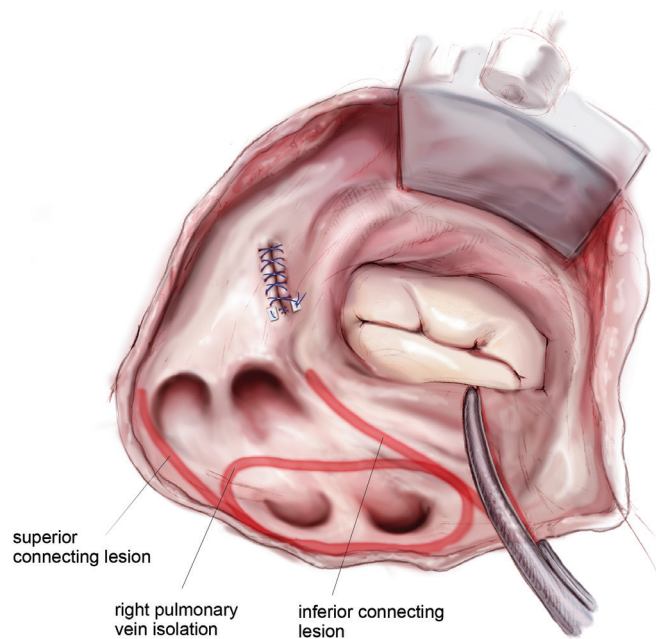


Figure 10 Ablation to the mitral isthmus using a bipolar RF clamp. The inferior and superior connecting lesions are also depicted after creation with the same device. RF, radiofrequency.

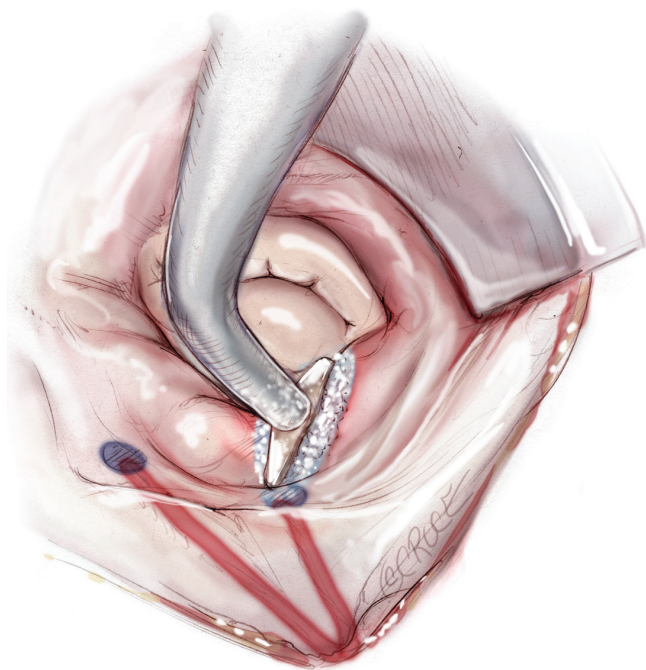


Figure 11 Endocardial cryoablation using a T-shaped cryoprobe to connect the mitral isthmus line to the mitral annulus. The ends of the mitral isthmus and inferior connecting lesions that were created with the bipolar RF clamp are marked with methylene blue in order to provide starting points for this cryoablation, as well as subsequent ones designed to completely isolate the posterior left atrium. RF, radiofrequency.

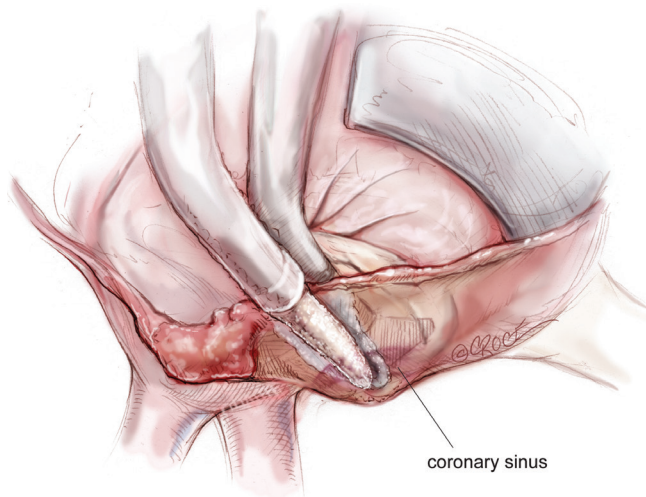


Figure 12 Epicardial ablation of the coronary sinus in line with the mitral isthmus line using a linear cryoprobe. This is performed with the T-shaped cryoprobe still in place in order to compress the tissue and ensure a full thickness ablation.

the anatomic variations in this structure and the thickness of the AV groove. Moreover, it is not possible to ablate the coronary sinus from the endocardial surface with a monopolar device. Of note, there is a risk to the circumflex artery when creating the left atrial isthmus lesion at the mitral annulus if patients have a left-dominant system. If a patient has a right-dominant system, the isthmus line is generally directed towards the junction of the P2 and P3 scallops of the posterior leaflet, but in patients with a left-dominant system, injury can be avoided by directing the ablation towards the posteromedial commissure.

The two ablation lines down towards the left superior and inferior PVs are connected with a sequence of endocardial cryoablations created with a T-shaped cryoprobe positioned behind the left PVs and along the lateral ridge (Figure 13). This ensures complete isolation of the four PVs and the posterior left atrium. If needed, a linear cryoprobe is used from the epicardial surface to ensure ablation of all tissue.

The left atriotomy is then closed with a pledgeted, running 4-0 non-absorbable monofilament polypropylene suture. The aorta is unclamped and, after rewarming, the heart is examined with TEE for retained air, as well as ventricular and valvular function. The patient is subsequently weaned from CPB.

Closure

At the conclusion of the procedure, epicardial pacing wires are routinely placed on the right atrium and ventricle and brought out percutaneously below the fourth intercostal space. The Blake drain placed at the beginning of the case is left in the pleural space for drainage. A second drainage tube is placed through the incision previously used for the endoscope port and positioned inside the pericardium.

The femoral arterial and venous cannulas are removed and a Doppler flow probe is used to demonstrate flow in the distal femoral artery. The groin wound is irrigated with copious amounts of antibiotic-containing saline solution and meticulous hemostasis is obtained. The incision is closed in layers and a sterile dressing is applied.

Attention is then turned to the right mini-thoracotomy incision. The chest is irrigated with copious amounts of antibiotic-containing saline solution. Meticulous hemostasis is obtained, and the pericardium is loosely reapproximated with heavy silk suture. The ribs are reapproximated with 2-3 pericostal sutures. A drill is used to puncture the lower rib and the pericostal sutures are placed through the holes. This prevents entrapment of the intercostal nerve by the

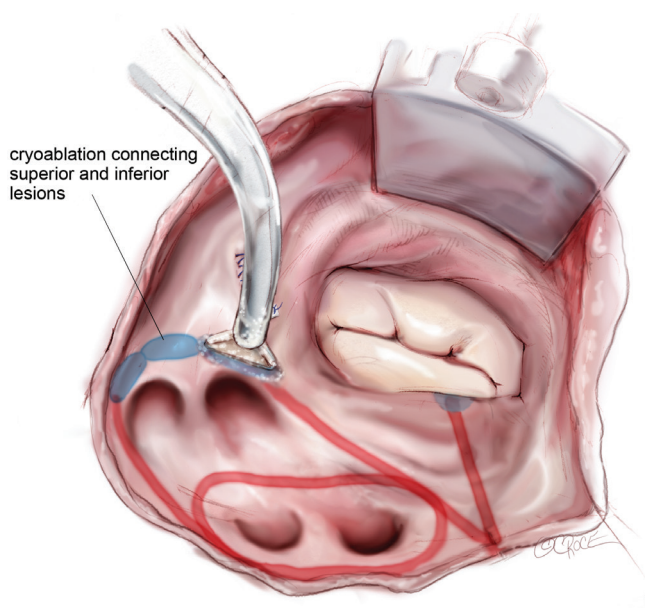


Figure 13 A sequence of endocardial cryoablations behind the left pulmonary veins is created with a T-shaped cryoprobe in order to connect the left inferior and superior connecting lesions and ensure complete isolation of the posterior left atrium.

pericostal sutures and reduces postoperative pain. The fascia, subcutaneous tissues and skin are closed in layers. After skin closure, a sterile dressing is applied.

Median sternotomy approach

A median sternotomy may be performed if a right mini-thoracotomy is contraindicated or if the patient requires concomitant surgery that cannot be performed through a right mini-thoracotomy. A few differences should be noted in this approach. First, pacing thresholds and measurements to confirm exit block are taken from all four PVs due to ready access to both the left and right sided PVs. Second, PVI is performed on both the right and left side using a bipolar clamp instead of using a combination of cryoablation and bipolar RF ablation to complete the left sided PVI, as described above. Third, the sequence of ablations is altered. The ablation to the right atrial free wall is performed through a purse-string at the base of the right atrial appendage at the beginning of the right atrial lesion set, and the remaining purse-string sutures are replaced with a vertical atriotomy that is created from just above the interatrial septum to the AV groove near the free margin of the heart. This atriotomy should be at least 2 cm from

the first free wall ablation. Through this incision, a bipolar RF clamp is used to create ablation lines up the SVC and down the IVC, and a linear cryoprobe is used to create an endocardial ablation to the tricuspid valve at the 2 o'clock position. Finally, the LAA is typically amputated instead of oversewn.

Postoperative management

One of the unique considerations in the postoperative period is rhythm management. After the CMIV, the p-wave amplitude is often small, but atrial capture is not frequently a problem. The pacemaker is set at a rate between 80 to 100 beats per minute. However, if there is first- or second-degree AV block, AV sequential pacing (DDD mode) may be required. Most patients have junctional rhythms immediately following a CMIV procedure. This has been attributed to the fact that the CMIV lesion set denervates the sinus node. This usually resolves in the first several postoperative days. Prior to resolution, however, patients should be paced in order to restore AV synchrony. Anti-arrhythmic medications should not be initiated until sinus rhythm is achieved, particularly in patients with bradyarrhythmias. This practice has evolved over the years away from more liberal use of anti-arrhythmic drugs following surgery in an attempt to minimize the incidence of postoperative permanent pacemaker insertion. Currently, only 5% of patients require a permanent pacemaker following a lone Cox-Maze IV, but this number increases with age (12). In general, sinus node function fails to recover in these patients.

Another significant consideration is management of early atrial tachyarrhythmias. In our experience, almost half of patients will experience these, although they are usually transient and frequently resolve over the first postoperative month. Stable atrial arrhythmias are managed with attempted pharmacologic cardioversion and rate-control, and, if persistent, elective direct current cardioversion is performed. Amiodarone is usually continued for the first two postoperative months. The QT interval on the EKG should be carefully followed in patients receiving amiodarone, and the drug should be discontinued if the QT interval is greater than or equal to 550 msec.

Warfarin is initiated several days after surgery, once a stable sinus rhythm has been achieved and the temporary pacing wires have been removed. It is continued for three months in all patients without contraindications to systemic anticoagulation. However, given the known risks of

warfarin, we recommend discontinuation after this period if the patient has no evidence of AF, has discontinued antiarrhythmic medications, does not manifest atrial stasis on echocardiogram, and is without another indication for systemic anticoagulation. This can be done without increasing stroke risk in this population (13).

Comments

Results obtained with a Cox-Maze IV lesion set have been excellent and comparable to those obtained with the “cut-and-sew” Cox-Maze III operation (14). A prospective, single-center study from our institution followed 100 consecutive patients undergoing a lone Cox-Maze IV procedure and reported postoperative freedom from AF of 90% at both 12 and 24 months with postoperative freedom from AF and anti-arrhythmic drugs of 82% and 84% at these same time points (11). Results were similar for patients undergoing concomitant cardiac surgery (7). These results were obtained despite the fact that some patients included in this study had complex disease substrate and risk factors that would have precluded durable success with approaches such as catheter ablation. Forty percent of patients had previously failed catheter ablation, and over 60% of patients had long-standing persistent AF. Average LA diameters were 4.7 ± 1.1 cm for lone maze patients to 5.5 ± 1.2 cm for concomitant surgery patients.

Success of this operation is dependent on both the lesion set and the ablation technology employed. While controversial, a meta-analysis of the published literature demonstrated that biatrial lesion sets result in a significantly higher 1-year freedom from AF when compared with LA lesion sets alone (89% *vs.* 76%, $P=0.001$) (15). Moreover, we have previously demonstrated that patients who underwent a “box” lesion set had a higher freedom from AF (96% *vs.* 86%) and a higher freedom from AF off anti-arrhythmic drugs (79% *vs.* 47%) at one year compared to patients who underwent PV isolation alone or PV isolation plus a single connecting lesion. Finally, if the mitral isthmus line is either incomplete or omitted, patients are at risk for the development of late atrial flutter (16,17).

Choice of ablation technology is also critical and it should be based on the ability of each device to safely and effectively create transmural lesions without damaging important nearby structures. We have shown that gaps in ablation lines as small as 1.1 mm are still capable of propagating AF (18). Transmurality of lesions varies depending on the technology used, but animal studies have

demonstrated that bipolar RF clamps and cryoablation produce transmural lesions approaching 100% of the time. Moreover, cryothermal ablation is safe around valvular tissue. The sinus node artery typically arises off of the right coronary artery and, while its course varies, it crosses the superior posterior border of the interatrial septum in 54% of cases (19). In 34-56% of cases it may alternatively arise from the left circumflex artery (19,20). Care should be taken to avoid injury to this structure. However, we have shown that bipolar RF ablation clamps do not cause significant coronary stenoses or occlude the microcirculation. In one study from our laboratory, purposeful lesions across the coronary arteries did not result in significant stenoses or thromboses, as evidenced by postoperative cardiac MRI and histology (21). We have further demonstrated via injection of lissamine green dye injection into an isolated LA preparation, that bipolar clamps do not cause any perfusion abnormalities in the microcirculation (22). These findings are supported clinically by the fact that complete isolation of the LAA across the base does not result in appendage ischemia, only electrical isolation. It is still possible that these devices create late endothelial injury.

The choice of some centers to use monopolar RF ablation technology may result in a higher incidence of nontransmural lesions and resultant higher failure rates. Moreover, while some of the cryothermal ablations could be replaced with a monopolar RF device, it would not be possible to complete the lesion set using this right mini-thoracotomy approach with just bipolar and unipolar RF technology.

In conclusion, it has been the development of ablation technology that has made this procedure both approachable in a minimally invasive fashion and accessible to the majority of surgeons. Future advances in diagnostic technologies that can precisely identify the arrhythmogenic substrate may allow us to tailor lesion sets to the pathophysiology of individual patients. At present, however, we advocate for standardization of the approach to treat AF, as well as standardization of follow-up methodology so that future advances can be appropriately compared to current standards.

Acknowledgements

Ralph J. Damiano Jr receives research grants and educational funding from AtriCure, Esteck and Edwards. Ralph J. Damiano Jr also receives consultant fees from AtriCure and Medtronic.

Disclosure: The authors declare no conflict of interest.

References

1. Cox JL, Ad N, Palazzo T. Impact of the maze procedure on the stroke rate in patients with atrial fibrillation. *J Thorac Cardiovasc Surg* 1999;118:833-40.
2. Feinberg MS, Waggoner AD, Kater KM, et al. Restoration of atrial function after the maze procedure for patients with atrial fibrillation. Assessment by Doppler echocardiography. *Circulation* 1994;90:II285-92.
3. Cox JL, Schuessler RB, Lappas DG, et al. An 8 1/2-year clinical experience with surgery for atrial fibrillation. *Ann Surg* 1996;224:267-73; discussion 273-5.
4. Prasad SM, Maniar HS, Camillo CJ, et al. The Cox maze III procedure for atrial fibrillation: long-term efficacy in patients undergoing lone versus concomitant procedures. *J Thorac Cardiovasc Surg* 2003;126:1822-8.
5. Gammie JS, Haddad M, Milford-Beland S, et al. Atrial fibrillation correction surgery: lessons from the Society of Thoracic Surgeons National Cardiac Database. *Ann Thorac Surg* 2008;85:909-14.
6. Calkins H, Kuck KH, Cappato R, et al. 2012 HRS/EHRA/ECAS expert consensus statement on catheter and surgical ablation of atrial fibrillation: recommendations for patient selection, procedural techniques, patient management and follow-up, definitions, endpoints, and research trial design: a report of the Heart Rhythm Society (HRS) Task Force on Catheter and Surgical Ablation of Atrial Fibrillation. Developed in partnership with the European Heart Rhythm Association (EHRA), a registered branch of the European Society of Cardiology (ESC) and the European Cardiac Arrhythmia Society (ECAS); and in collaboration with the American College of Cardiology (ACC), American Heart Association (AHA), the Asia Pacific Heart Rhythm Society (APHRS), and the Society of Thoracic Surgeons (STS). Endorsed by the governing bodies of the American College of Cardiology Foundation, the American Heart Association, the European Cardiac Arrhythmia Society, the European Heart Rhythm Association, the Society of Thoracic Surgeons, the Asia Pacific Heart Rhythm Society, and the Heart Rhythm Society. *Heart Rhythm* 2012;9:632-696.e21.
7. Damiano RJ Jr, Schwartz FH, Bailey MS, et al. The Cox maze IV procedure: predictors of late recurrence. *J Thorac Cardiovasc Surg* 2011;141:113-21.
8. Akoum N, Daccarett M, McGann C, et al. Atrial fibrosis helps select the appropriate patient and strategy in catheter ablation of atrial fibrillation: a DE-MRI guided approach. *J Cardiovasc Electrophysiol* 2011;22:16-22.
9. Kuppahally SS, Akoum N, Burgon NS, et al. Left atrial strain and strain rate in patients with paroxysmal and persistent atrial fibrillation: relationship to left atrial structural remodeling detected by delayed-enhancement MRI. *Circ Cardiovasc Imaging* 2010;3:231-9.
10. Oakes RS, Badger TJ, Kholmovski EG, et al. Detection and quantification of left atrial structural remodeling with delayed-enhancement magnetic resonance imaging in patients with atrial fibrillation. *Circulation* 2009;119:1758-67.
11. Weimar T, Bailey MS, Watanabe Y, et al. The Cox-maze IV procedure for lone atrial fibrillation: a single center experience in 100 consecutive patients. *J Interv Card Electrophysiol* 2011;31:47-54.
12. Robertson JO, Cuculich PS, Saint LL, et al. Predictors and risk of pacemaker implantation after the Cox-Maze IV procedure. *Ann Thorac Surg* 2013;95:2015-20; discussion 2020-1.
13. Pet M, Robertson JO, Bailey M, et al. The impact of CHADS2 score on late stroke after the Cox maze procedure. *J Thorac Cardiovasc Surg* 2013;146:85-9.
14. Lall SC, Melby SJ, Voeller RK, et al. The effect of ablation technology on surgical outcomes after the Cox-maze procedure: a propensity analysis. *J Thorac Cardiovasc Surg* 2007;133:389-96.
15. Barnett SD, Ad N. Surgical ablation as treatment for the elimination of atrial fibrillation: a meta-analysis. *J Thorac Cardiovasc Surg* 2006;131:1029-35.
16. Gaita F, Riccardi R, Caponi D, et al. Linear cryoablation of the left atrium versus pulmonary vein cryoisolation in patients with permanent atrial fibrillation and valvular heart disease: correlation of electroanatomic mapping and long-term clinical results. *Circulation* 2005;111:136-42.
17. Gillinov AM, McCarthy PM, Blackstone EH, et al. Surgical ablation of atrial fibrillation with bipolar radiofrequency as the primary modality. *J Thorac Cardiovasc Surg* 2005;129:1322-9.
18. Melby SJ, Lee AM, Zierer A, et al. Atrial fibrillation propagates through gaps in ablation lines: implications for ablative treatment of atrial fibrillation. *Heart Rhythm* 2008;5:1296-301.
19. Berdajs D, Patonay L, Turina MI. The clinical anatomy of the sinus node artery. *Ann Thorac Surg* 2003;76:732-5; discussion 735-6.
20. Zhang ZJ, Chen K, Tang RB, et al. Impact of the origin of sinus node artery on recurrence after pulmonary vein isolation in patients with paroxysmal atrial fibrillation.

- Chin Med J (Engl) 2013;126:1624-9.
21. Gaynor SL, Ishii Y, Diodato MD, et al. Successful performance of Cox-Maze procedure on beating heart using bipolar radiofrequency ablation: a feasibility study in animals. *Ann Thorac Surg* 2004;78:1671-7.
 22. Byrd GD, Prasad SM, Ripplinger CM, et al. Importance of geometry and refractory period in sustaining atrial fibrillation: testing the critical mass hypothesis. *Circulation* 2005;112:I7-13.

Cite this article as: Robertson JO, Saint LL, Leidenfrost JE, Damiano RJ Jr. Illustrated techniques for performing the Cox-Maze IV procedure through a right mini-thoracotomy. *Ann Cardiothorac Surg* 2014;3(1):105-116. doi: 10.3978/j.issn.2225-319X.2013.12.11

Mini-Bentall procedure

Tristan D. Yan

The Collaborative Research (CORE) Group, Macquarie University, Sydney, Australia; University of Sydney, Royal Prince Alfred Hospital and Sydney Adventist Hospital, Sydney, Australia

Introduction

The Bentall procedure is a cardiac surgical operation involving composite graft replacement of the aortic valve, aortic root and ascending aorta, with re-implantation of the coronary arteries into the graft. This technique was first described by Hugh Bentall and Antony De Bono in 1968 (1), using a median sternotomy approach. To minimize surgical trauma and enhance patient recovery, cardiac surgeons are increasingly performing aortic valve replacement via upper hemi-sternotomy or right mini-thoracotomy incisions (2-5). The Mini-Bentall procedure consists of an aortic root and ascending aortic replacement with re-implantation of coronary buttons, performed via an upper hemi-sternotomy. The skin incision extends from the angle of Louis to the third intercostal space, usually measuring 5-7 cm in length, depending on the body size of the patient. Through this incision, it is possible to perform isolated aortic root surgery or in conjunction with hemi-arch replacement. The present article describes the technical details on how I perform a Mini-Bentall procedure and hemi-arch replacement.

Methods

Computed tomography

A careful review of three-dimensional reconstructed images of the thoracic aorta in relation to the sternum and the rib cage is necessary. This will greatly facilitate the planning for the upper hemi-sternotomy. The upper hemi-sternotomy should be terminated at one intercostal space above the plane of the aortic annulus, usually the 4th (sometimes the 3rd) intercostal space. The degree of aortic wall calcification and evidence of atheromatous disease are evaluated in both contrast and non-contrast phases. A decision regarding the most appropriate cannulation strategy is sought with the aim to minimize potential embolic risks.

Preparation

Following induction of anaesthesia, a radial arterial pressure

monitor line, central venous line, pulmonary arterial sheath/catheter and urinary catheter are inserted. The patient is placed in the supine position. The body surface anatomy is clearly marked with a permanent marking pen depicting the positions of supra-sternal notch, sterno-manubrial junction, 2nd to 4th intercostal spaces, the inferior extent of xiphoid cartilage and bilateral femoral arteries. The body is painted with an antiseptic solution. Sterile drapes are placed, exposing the precordium laterally to the mid-clavicular lines and bilateral groin regions.

Skin incision

A midline skin incision is performed from the manubrio-sternal junction to the level of the third intercostal space. The incision is usually 5-7 cm in length depending on the body size of the patient. It is developed through the subcutaneous fat onto the body of the sternum using a diathermy. A cutaneous flap is developed with a diathermy hand-piece along the prepectoral fascia. This flap is extended superiorly above the supra-sternal notch and laterally to the limits of the sternum. A Kocker retractor is used to elevate the skin flap superiorly to expose the bridging vein over the manubrium and inferiorly to the 4th intercostal space. The bridging vein is clipped and cut. A 14 Fr Jackson Pratt drain (Cardinal Health, McGaw Park, IL, USA) is inserted through the skin at the level of 4th parasternal space on the left side and positioned in the subcutaneous space. This is used for CO₂ inflow during the case to prevent air embolism and as a subcutaneous drain at the completion of the operation.

Mini-sternotomy

A mini-sternotomy is performed using a hand-held electrical saw from the superior extent of the manubrium. The division is terminated either to the left or right parasternal space. In this illustrated article, a left-sided, reversed "J" hemi-sternotomy is demonstrated (*Figure 1*). Hemostasis is achieved by applying a small amount of wax to the bone

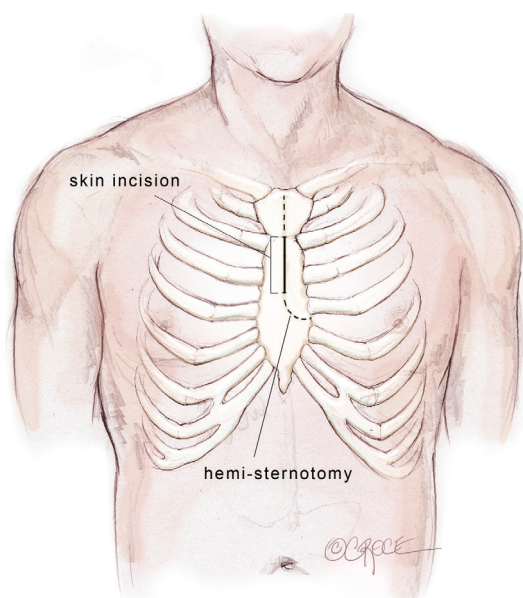


Figure 1 A midline skin incision is performed from the manubriosternal junction to the level of the third intercostal space. A reversed “J” upper hemi-sternotomy is terminated to the left fourth intercostal space.

marrow. The thymic fat pad is completely mobilized to the innominate vein superiorly. The pericardium is opened longitudinally to the pericardial reflection superiorly and the level of 4th intercostal space inferiorly. Three pericardial traction sutures are placed on each side; hitched up and tied securely to the edges of the skin incision. A minimally invasive sternal retractor is placed over the pericardial edges and opened up gradually. In doing so, the sternum is spread open, together with the pericardium, which anteriorizes the ascending aorta. A Semb clamp is passed around the ascending aorta by bluntly developing a plane between the mid-ascending aorta and the right pulmonary artery posteriorly and pulmonary artery trunk medially. The mid-ascending aorta is slung with a Nylon tape (Johnson & Johnson Intl, St-Stevens-Woluwe, Belgium). Downward traction on the Nylon tape provides additional exposure of distal ascending aorta to facilitate aortic cannulation. The access would adequately expose the aorta from the level of sinotubular junction to that of the distal ascending aorta (*Figure 2*).

Cannulation strategy

A vacuum-assist device is built in the cardiopulmonary

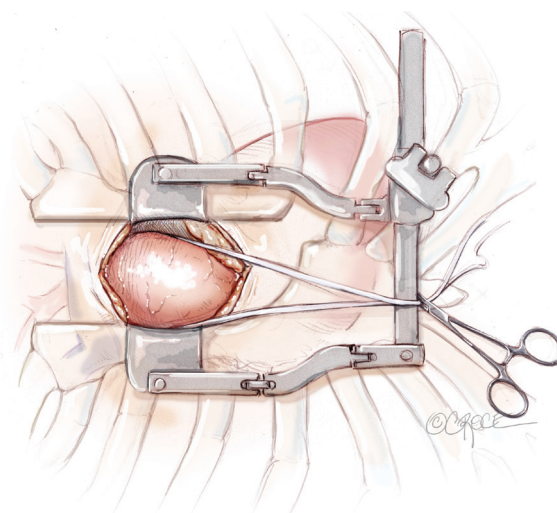


Figure 2 The mid-ascending aorta is slung with a Nylon tape. The access should adequately expose the aorta from the level of sinotubular junction to that of the distal ascending aorta.

bypass (CBP) circuit to maximize venous drainage. Full systemic heparinization is achieved with activated clotting time (ACT) greater than 450 seconds. Peripheral venous cannulation is established first, using a Seldinger technique. After puncture of a femoral vein, a guide wire is passed up to the superior vena cava. The position of the wire is confirmed with transesophageal echocardiography (TEE) through a bicaval view. The femoral vein puncture site is then progressively dilated. A 23 or 25 Fr multi-stage venous cannula (Maquet Getinge Group, Rastatt, Germany) is introduced. The pointy-tipped insert is not advanced further once it enters the right atrium. Only the venous cannula itself is now advanced forward over the insert, strictly under the TEE guidance. It is essential that the cannula tip be placed in the superior vena cava to ensure satisfactory bicaval venous return. The venous cannula is subsequently connected to the CPB circuit.

Arterial cannulation can be established either via distal ascending aorta or femoral artery. In this illustrated article, a distal ascending aortic cannulation is depicted. The Nylon tape slung around the mid-ascending aorta is retracted inferiorly. The superior edge of the skin incision is elevated cephalad using a Kocker tractor. Two 2-O Ti-Cron purstrings for the aortic cannula are placed in the distal ascending aorta at the level of pericardial reflection. The aorta is carefully cannulated with an Elongated One-Piece Arterial (EOPA) cannula (Medtronic Inc, Minneapolis, MN, USA), which is secured in position and connected to

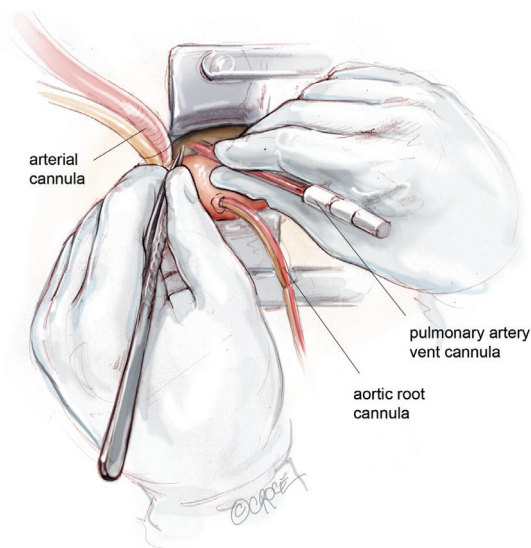


Figure 3 Cardiopulmonary bypass is established via central aortic cannulation and femoral venous cannulation. A 16 Fr DLP pulmonary artery vent cannula (Medtronic Inc, Minneapolis, MN, USA) is inserted in the main pulmonary trunk.

the CPB circuit.

A 16 Fr DLP pulmonary artery vent cannula (Medtronic Inc, Minneapolis, MN, USA) is inserted in the main pulmonary trunk (*Figure 3*). Once CPB is established, the heart is off-loaded. Systemic temperature is maintained at 32 degrees centigrade for aortic root replacement or 25 degrees if hemi-arch replacement is anticipated. In the latter, splitting the arterial line is necessary beforehand to provide additional cerebral perfusion.

Aneurysm resection

Under a low-flow condition, an atraumatic aortic cross-clamp is applied across the distal ascending aorta. Diastolic arrest is achieved with antegrade cardioplegia delivered via a DLP aortic root cannula (Medtronic Inc, Minneapolis, MN, USA) or direct coronary ostial balloon tip cannula (Maquet Getinge Group, Rastatt, Germany) in the presence of aortic regurgitation. Either cold-blood cardioplegia solution or Custodial cardioplegia solution is suitable.

After aortotomy, the blood in the aortic root is salvaged. The aneurysmal segment of the ascending aorta is resected, leaving 1 cm cuff of aortic tissue proximal to the cross-clamp and 1 cm above the sinotubular junction (*Figure 4*). The inside of the aortic root is assessed and the positions of the coronary arteries are visualized. The aortic root

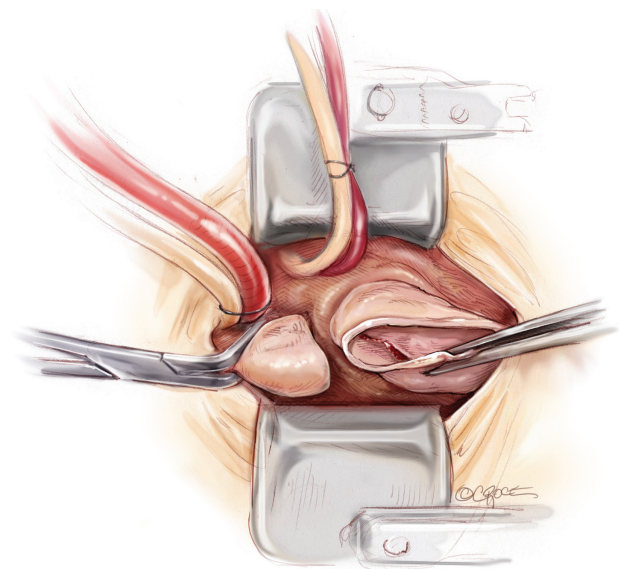


Figure 4 The ascending aortic aneurysm is resected, leaving 1 cm cuff of aortic tissue proximal to the cross-clamp and 1 cm above the sinotubular junction.

is carefully mobilized circumferentially. First, the non-coronary sinus is resected, leaving an 8 mm rim of aortic wall just above the non-coronary annulus. Then, the right coronary button flap is prepared. Two vertical incisions are made from the sinotubular junction down along both sides of the right coronary ostium and connected inferiorly (*Figure 5*). A 4-0 polypropylene suture is passed through the top end of the right coronary button flap to provide gentle traction when required. Similarly, the left coronary button flap is also fashioned. Often only limited mobilization of the coronary buttons from the surrounding connective tissue is required.

Aortic root exposition

In order to provide an excellent exposure, the aortic root is brought in a cephalad direction. This is achieved by putting the first pledgeted 2-0 Ti-Cron horizontal mattress suture above the non-/left-coronary commissure. The needles are then passed through the edge of the skin incision on the right side, at the 10 o'clock position. The traction suture is snared and clipped. The needles of the next pledgeted 2-0 Ti-Cron suture are passed through just above the left-/right-coronary commissure and the skin edge on the left side at the 2 o'clock position. The third pledgeted 2-0 Ti-Cron traction suture is used to elevate the right-/

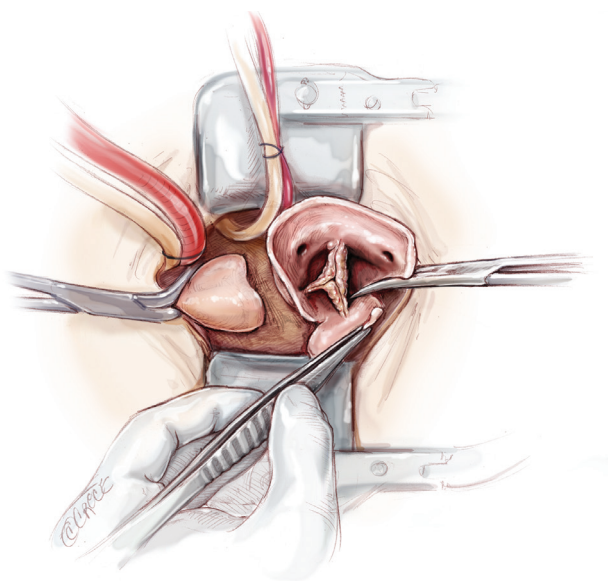


Figure 5 The aortic root is carefully mobilized circumferentially and resected, leaving a rim of aortic wall just above the aortic annulus. The coronary buttons are prepared.

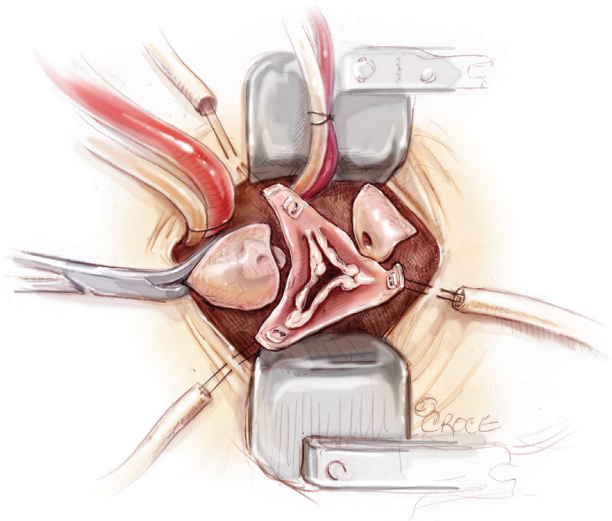


Figure 6 To provide an excellent exposure, the aortic root is brought in the cephalad direction by pulling on three commissural traction sutures.

non-coronary commissure and attached to the skin edge on the right side at the 7 o'clock position. These three commissural traction sutures are hitched up and snared in position. This simple manoeuvre provides an excellent exposure of the aortic valve for the minimal access surgical approach (*Figure 6*).

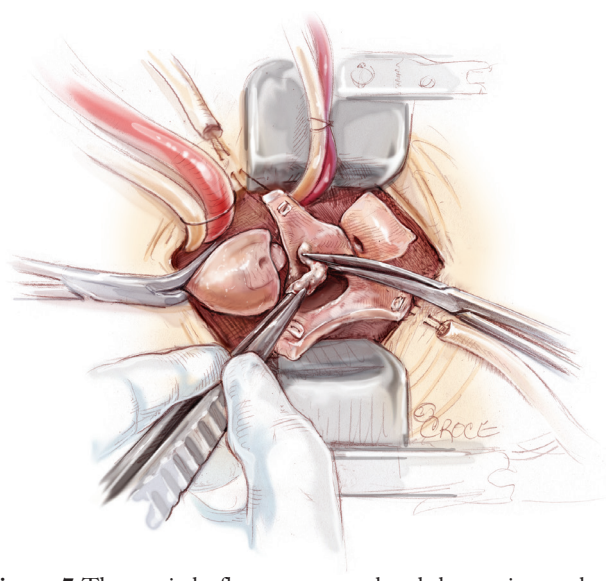


Figure 7 The aortic leaflets are resected and the aortic annulus is decalcified.

Aortic root implantation

The aortic leaflets are resected and the aortic annulus is decalcified (*Figure 7*). 2-0 Ethibond *Excel* annular sutures with or without pledgets are used. Horizontal mattress sutures are placed neatly below the aortic annulus. Pledgets are used to reduce the tension created by the sutures when the valve conduit is tied down, especially at the nadirs. The placement of these sub-annular sutures needs to be precise, both in terms of the spacing and whether or not the needle is passed through the annulus at a perpendicular angle (*Figure 8*). The sutures are evenly distributed.

The annulus is sized for its intra-annular and supra-annular dimensions. An appropriate valve conduit is selected. It is advisable not to oversize the valve. The annular sutures are passed through the sewing cuff of the prosthesis. Once all the sutures are passed through the sewing cuff, they are clipped and cut. The valve conduit is parachuted down by gently pulling the sutures vertically upwards with one hand and firmly pushing the valve conduit down onto the annulus with the other hand (*Figure 9*). Before tying each suture, it is important to check that there are no redundant loops of the sutures below the sewing cuff. The sutures are tied and cut one by one, starting from the three sutures at the nadirs of the annulus to ensure that the prosthesis is seated properly to the lowest points of the annulus. Then, the remaining sutures are tied and cut around the sewing cuff.

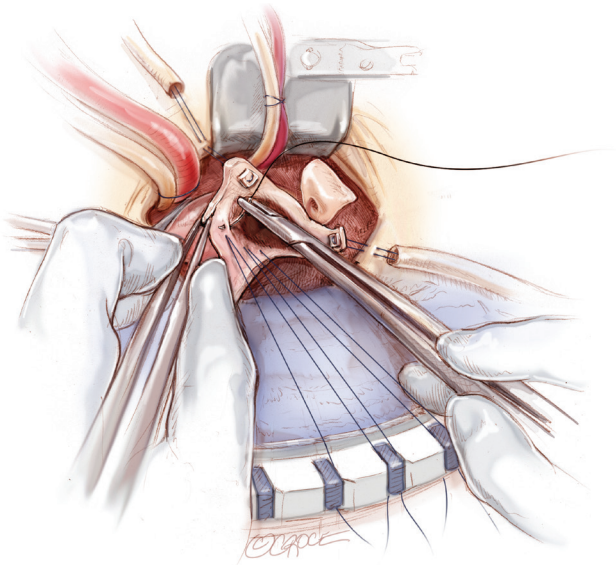


Figure 8 Horizontal mattress sutures are used, with pledgets placed neatly below the aortic annulus.

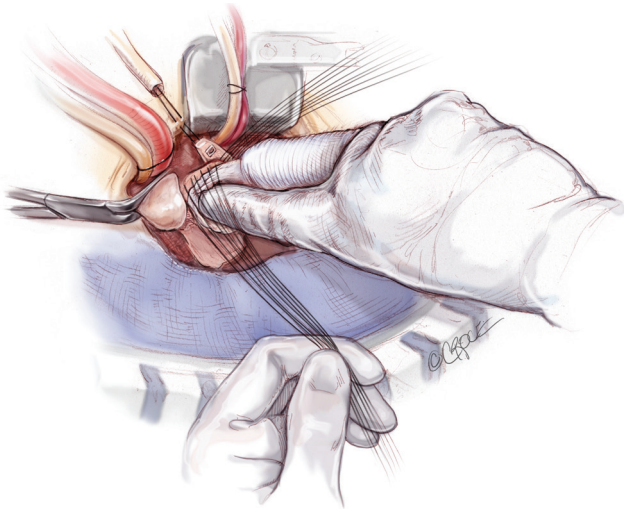


Figure 9 The valve conduit is parachuted down by gently pulling the sutures vertically upwards with one hand and firmly pushing the valve conduit down onto the annulus with the other.

Coronary button re-implantation

The left coronary artery button is rested in its anatomical position. The appropriate site on the valsalva graft (Vascutek Ltd, Renfrewshire, Scotland) for left coronary button re-implantation is determined with the heart fully loaded, so that there is no tension or rotation of the left coronary button anastomosis. Once the position of the anastomosis

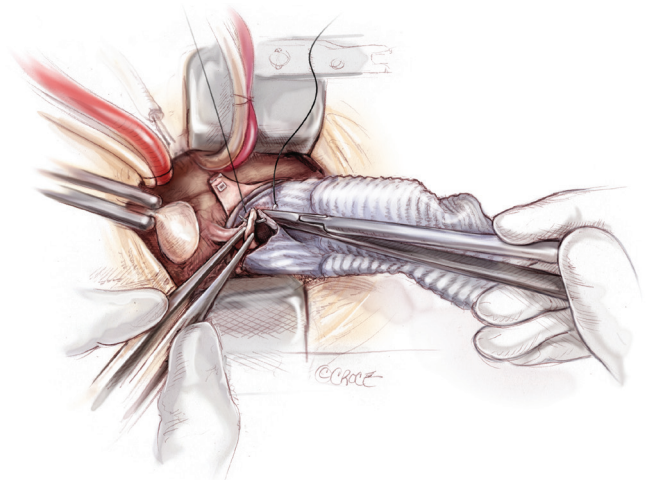


Figure 10 The left coronary button is trimmed, leaving a 3 mm circumferential cuff and re-implanted using a 5-0 running polypropylene suture.

is marked, the heart is off-loaded. A Bovie electrocautery (Bovie Medical Corporation, Clearwater, FL, USA) is used to create a circular hole for receiving the left coronary button. The coronary button is trimmed, left with a 3 mm circumferential cuff and re-implanted using a 5-0 running polypropylene suture. The cuff of the coronary button needs to be attached snugly to the outside of valsalva graft (*Figure 10*). In a similar fashion, the right coronary button is prepared and re-implanted (*Figure 11*). It is imperative to ensure that a full thickness bite with each stitch is achieved. Failing to do so may cause bleeding in a very difficult site to access once the cross-clamp is taken off. The aortic root is pressurized and the anastomoses are tested by delivering a full dose of antegrade cardioplegia. Systemic rewarming is subsequently initiated.

Distal anastomosis

The distal aortic anastomosis is reconstructed with the aortic cross-clamp on. The length of the graft is determined by filling the heart up and pulling the graft upwards on a stretch to meet distal ascending aorta. The graft is trimmed and anastomosed to the distal ascending aortic cuff by using a 3-0 running polypropylene suture. The anastomosis is started from the point furthest away from the operating surgeon. The posterior wall is completed first from 4 o'clock to 11 o'clock position on the aorta (*Figure 12*). A nerve hook is used to tighten the posterior wall suture progressively towards the operating surgeon. The anterior half of the

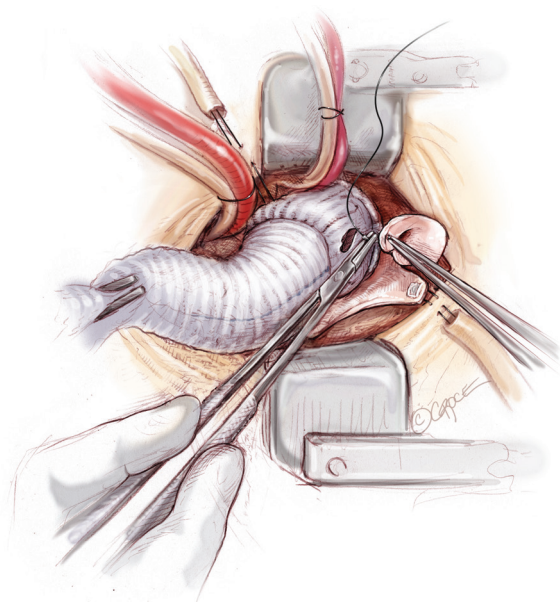


Figure 11 The right coronary button is prepared and re-implanted using a 5-0 running polypropylene suture.

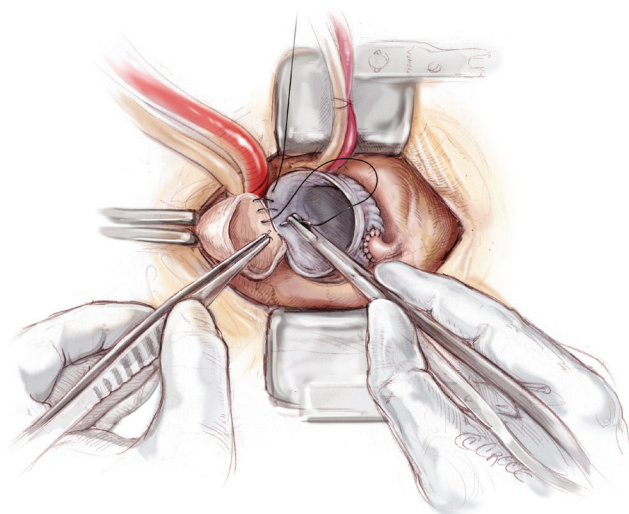


Figure 12 The graft is trimmed and anastomosed to the distal ascending aortic cuff by using a 3-0 running polypropylene suture.

anastomosis is completed by picking up the other end of the suture and sewing towards the operator. An aortic root vent is inserted before the two ends of the suture are tied. The table is put in a Trendelenburg position, the heart is filled and lungs are inflated, the arterial flow is turned down, aortic cross-clamp is released and the graft is de-aired from the aortic root vent.

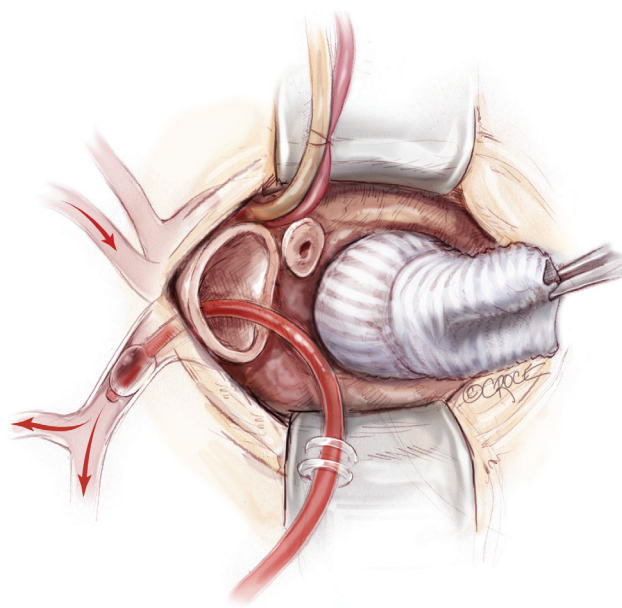


Figure 13 The mid to distal ascending aorta is resected completely, together with the cannulation site. Selective antegrade cerebral perfusion is achieved by cannulating the innominate artery with or without left common carotid artery.

Hemi-arch replacement

If the distal ascending and/or proximal arch are aneurysmal, a hemi-arch replacement with an open distal anastomosis is performed. Two cerebral perfusion cannulae are prepared at the beginning of the case in readiness for antegrade cerebral perfusion. Systemic cooling down to 25 degrees is initiated. As soon as the systemic temperature reaches 25 degrees, attention is then turned to the distal hemi-arch replacement. The head is packed in ice, the antegrade flow is ceased, the aortic cannula is clamped, the aortic cross clamp is removed and the patient's blood is drained into the reservoir. The mid to distal ascending aorta is resected completely, together with the cannulation site. The under surface of the proximal aortic arch is beveled. The inside of the aortic arch and the origins of epi-aortic vessels are inspected for any evidence of atheromatous disease. Selective antegrade cerebral perfusion is achieved by cannulating the innominate artery with or without left common carotid artery (*Figure 13*). The open distal anastomosis is performed using a separate Ante-Flo graft with a single side arm (Vascutek Ltd, Renfrewshire, Scotland). A continuous 3-0 running polypropylene suture is used, starting from the point furthest away from the operating surgeon and completing the posterior aortic

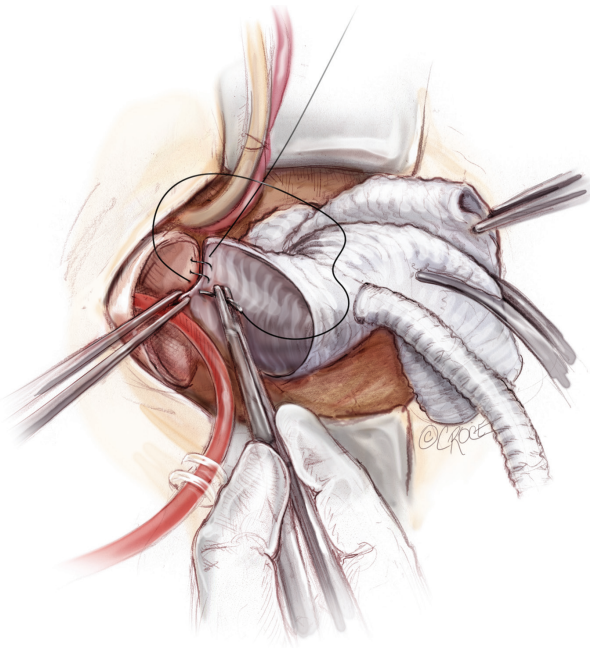


Figure 14 The open distal anastomosis is performed with a separate Ante-Flo graft with a single side arm (Vascutek Ltd, Renfrewshire, Scotland), using a continuous 3-0 running polypropylene suture.

wall first (*Figure 14*). A nerve hook is used to tighten the suture along the posterior wall. The anterior half of the anastomosis is completed by picking up the other end of the suture and sewing towards the operator. This distal anastomosis is reinforced with pledgeted 4-0 prolene sutures where necessary to ensure an absolute hemostasis. After completion of the open distal anastomosis, antegrade systemic perfusion is resumed via the side-arm perfusion limb of the Ante-Flo graft. The patient is rewarmed towards 37 degrees centigrade.

Once the root procedure is completed, the proximal valve conduit is trimmed just above the valsalva portion of the graft. The distal Ante-Flo graft is put under a stretch and cut to an appropriate length. A graft-to-graft anastomosis is performed using a continuous 3-0 running prolene suture (*Figure 15*). The spacing between the adjacent stitches needs to be narrow and precise when doing a graft-to-graft anastomosis, usually a couple of millimeters apart. Finally, the aortic root vent is inserted, the aortic cross clamp is slowly released and a 21-gauge needle is used to de-air the graft. In order to ensure an absolute hemostasis, pledgeted 4-0 prolene sutures are applied to reinforce the proximal anastomosis when necessary.

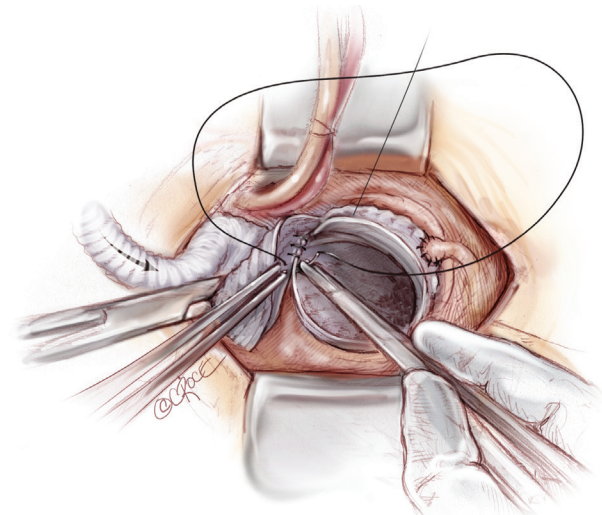


Figure 15 A graft-to-graft anastomosis is performed using a continuous 3-0 running polypropylene suture and reinforced using pledgeted 4-0 polypropylene sutures where necessary.

Completion

A bi-polar temporary pacing wire is inserted in the epicardium over the right ventricular outflow tract. One 28 Fr soft drain is inserted and brought out below the xiphoid cartilage. Hemostasis is carefully checked and the patient is weaned from CPB. Protamine is given to reverse the Heparin effect. Topical Floseal Hemostatatic Matrix (Baxter Healthcare, Zurich, Switzerland) is applied around the anastomotic sites. The surgical site is packed with small gauze sponges for a period of 10-minute hemostatic pause. Once the hemostasis is deemed satisfactory, four stainless steel wires are used to approximate the sternum. No. 1 Vicryl suture is used to close the fascia and the subcutaneous fat. The skin is closed with a 5-0 Monocryl subcuticular suture. This completes the Mini-Bentall procedure.

Discussion

An important goal in modern cardiovascular and thoracic surgery is reducing surgical trauma to achieve faster recovery for our patients. The benefits of minimally invasive surgery are evident (4,6-8). More surgeons are comfortable with aortic valve replacement via upper hemi-sternotomy or right mini-thoracotomy, and thus naturally there is a growing interest in performing aortic surgery via a minimal access incision. The present illustrated article described the technical details of Mini-Bentall procedure and hemi-

arch replacement for selected patients with aortic root and ascending aortic aneurysms.

The mini-sternotomy is performed using a hand-held electrical saw from the superior extent of the manubrium. The division is terminated either to the left or right parasternal space. One advantage to the right (a “J” mini-sternotomy) is avoiding any potential injury to the left internal mammary artery, should it be used for coronary bypass surgery in the future. In addition, access to the right superior pulmonary vein for venting is made easier. The main advantage of doing a mini-sternotomy to the left (a reverse “J”) is increasing the exposure of proximal arch, especially if a concomitant hemi-arch replacement is anticipated. Under this circumstance, a pulmonary artery vent is used instead of right superior pulmonary vein vent. It should be cautioned that when inserting a pulmonary artery vent, the heart needs to be kept full or even before going on CPB. This will avoid injury to the posterior wall of the pulmonary trunk with the tip of the pulmonary artery cannula.

Arterial cannulation can be established either via distal ascending aorta or femoral artery. It is preferable to have a central arterial cannulation whenever possible to provide adequate antegrade systemic perfusion and avoid potential retrograde embolization and vascular complications that may be associated with peripheral cannulation (9). Should femoral arterial cannulation be used, a 2.5 cm oblique incision is performed in the groin, exposing the anterior aspect of the common femoral artery. A 5-0 polypropylene purse-string suture is placed in the anterior aspect of the common femoral artery. The artery is cannulated using a Seldinger technique. A guide wire is passed up in the descending thoracic aorta. Its presence within the descending aorta is confirmed with TEE. After progressive manual dilatation of the femoral artery puncture site, a wire-reinforced femoral arterial cannula should be inserted without any resistance.

In order to provide adequate exposure and surgical accessibility, it is important to anteriorize the aortic root, as well as bring the aortic annulus cephalad. This is achieved by placing three pledgeted 2-0 Ti-Cron horizontal mattress sutures above the commissures and hitching them up to the skin edges. This simple manoeuvre provides an excellent exposure of the aortic valve for the minimal access surgical approach. Even though the mini-sternotomy terminating at the level of sinotubular junction, this manoeuvre could bring the aortic annulus forward in the cephalad direction by 2 to 3 cm.

Composite graft replacement of the ascending aorta and aortic valve was first introduced by Bentall and De Bono in 1968 (1). According to this technique, the aortic tissue surrounding the coronary ostia is directly sutured to the openings in the composite graft. These anastomoses were all made within the ascending aorta, and then the aortic wall is tightly wrapped over the conduit. This technique has been known as the wrap/inclusion technique (1). Coronary artery dehiscence and coronary false aneurysms may result from tension created by bleeding into the space between the graft and the wrap (10). A few technical modifications have been implemented, including the use of a reinforcement suture joining the cut edge of the aortic wall and the prosthetic sewing ring (11). This technique described two separate proximal suture lines, an interrupted one between the most proximal part of the valve sewing ring and the aortic valve annulus, and a continuous one between the more distal portion of the sewing ring and the cut edge of the proximal aorta. In a Mini-Bentall procedure, absolute hemostasis must be achieved. If there are any concerns regarding the hemostasis along the annulus (due to suture spacing or severely calcified annulus), a second ‘hemostatic’ layer is achieved by using a continuous 4-0 running polypropylene suture that incorporates the 8 mm remnant of the aortic wall and the sewing cuff of the valve conduit. This technique works well for a mechanical valve conduit (St. Jude Medical, St. Paul, MN, USA), as the sewing cuff is big enough to accommodate two rolls of anastomoses. However, when a bioprosthetic valve is used inside of a valsalva graft, whereby the sewing ring of the tissue valve is narrow and the second ‘hemostatic’ layer is difficult to achieve, a ‘French Cuff’ technique is used (12).

In the strategy presented, the fundamental principles of a traditional aortic root replacement are respected and it cannot be emphasized enough that a meticulous surgical technique to ensure absolute hemostasis is utmost important in minimally invasive surgery. This results in a complete aortic repair via a minimal access incision and successful treatment in selected patients with aortic root and/or ascending aortic aneurysm.

Acknowledgements

Disclosure: The author declares no conflict of interest.

References

1. Bentall H, De Bono A. A technique for complete

- replacement of the ascending aorta. *Thorax* 1968;23:338-9.
2. Navia JL, Cosgrove DM 3rd. Minimally invasive mitral valve operations. *Ann Thorac Surg* 1996;62:1542-4.
 3. Cohn LH, Adams DH, Couper GS, et al. Minimally invasive cardiac valve surgery improves patient satisfaction while reducing costs of cardiac valve replacement and repair. *Ann Surg* 1997;226:421-6; discussion 427-8.
 4. Phan K, Xie A, Di Eusanio M, et al. A meta-analysis of minimally invasive versus conventional sternotomy for aortic valve replacement. *Ann Thorac Surg* 2014;98:1499-511.
 5. Phan K, Xie A, Tsai YC, et al. Ministernotomy or minithoracotomy for minimally invasive aortic valve replacement: a Bayesian network meta-analysis. *Ann Cardiothorac Surg* 2015;4:3-14.
 6. Borger MA, Moustafine V, Conradi L, et al. A randomized multicenter trial of minimally invasive rapid deployment versus conventional full sternotomy aortic valve replacement. *Ann Thorac Surg* 2015;99:17-25.
 7. Phan K, Zhou JJ, Niranjana N, et al. Minimally invasive reoperative aortic valve replacement: a systematic review and meta-analysis. *Ann Cardiothorac Surg* 2015;4:15-25.
 8. Phan K, Tsai YC, Niranjana N, et al. Sutureless aortic valve replacement: a systematic review and meta-analysis. *Ann Cardiothorac Surg* 2015;4:100-11.
 9. Benedetto U, Raja SG, Amrani M, et al. The impact of arterial cannulation strategy on operative outcomes in aortic surgery: evidence from a comprehensive meta-analysis of comparative studies on 4476 patients. *J Thorac Cardiovasc Surg* 2014;148:2936-43.e1-4.
 10. Nezic D, Cirkovic M, Knezevic A, et al. Modified Bentall procedure - 'a collar technique' to control bleeding from coronary ostia anastomoses. *Interact Cardiovasc Thorac Surg* 2008;7:709-11.
 11. Copeland JG 3rd, Rosado LJ, Snyder SL. New technique for improving hemostasis in aortic root replacement with composite graft. *Ann Thorac Surg* 1993;55:1027-9.
 12. Yan TD. Modified Bentall Procedure - the 'French Cuff' technique. (In Press).

Cite this article as: Yan TD. Mini-Bentall procedure. *Ann Cardiothorac Surg* 2015;4(2):182-190. doi: 10.3978/j.issn.2225-319X.2015.03.08

Surgical techniques of total arch replacement using selective antegrade cerebral perfusion

Yutaka Okita, Kenji Okada, Atsushi Omura, Hiroya Kano, Hitoshi Minami, Takeshi Inoue, Toshihito Sakamoto, Shunsuke Miyahara, Tomonori Shirasaka, Katsuhiro Yamanaka, Taimi Ohara, Yoshikatsu Nomura, Hidekazu Nakai

Division of Cardiovascular Surgery, Department of Surgery, Kobe University Graduate School of Medicine, Kobe, Japan

Introduction

This detailed illustrated article describes our preferred surgical technique of total arch replacement using selective antegrade cerebral perfusion (SACP). Our current approach includes: (I) meticulous selection of arterial cannulation site and type of arterial cannula; (II) SACP for neuro-protection; (III) whole body hypothermia with minimal tympanic temperatures between 20 and 23 °C and minimal rectal temperatures below 30 °C; (IV) early re-warming after distal anastomosis with SACP flow adjustment while monitoring brain oxygenation by near infrared spectroscopy (NIRS); and (V) after 2006, maintaining strict fluid balance below 1 L by the extracorporeal ultrafiltration method (ECUM) during cardiopulmonary bypass (CPB), with the expectation of more rapid pulmonary functional recovery.

Operative techniques

Preparation

The patient is placed in the supine position and the diodes of NIRS are attached on the foreheads bilaterally. For NIRS, we use INVOS 5100C (Somanetics, Troy, MI), which provides continuous regional cerebral oxygen saturation (rSO₂). The rSO₂ readings are expressed as an index, measuring differences from an unknown baseline. A standard median sternotomy is performed and there is no need for extension of the skin incision to the left neck.

Before going on the CPB, the innominate vein is fully mobilized with division of several branches to facilitate exposure of the aneurysm. The vein is seldom divided (*Figure 1*). Dissection of the aneurysm, aortic arch branches, or the vagus nerve is not usually performed to minimize aortic manipulation and recurrent laryngeal neuropexia. Taping around the arch or arch vessels is not necessary (*Figure 2*). The serrated balloon tipped cannulae usually sit well in

the neck vessels without snaring or can be fixed with a silk suture.

Cannulation

Preoperative CT scan is done in every patient to assess the atheromatous lesions in the ascending aorta. Both transesophageal and epi-aortic echocardiography are applied to interrogate the ascending aorta and determine cannulation site. CPB is established with bi-caval drainage. The left ventricle is vented through the right upper pulmonary vein. Femoral artery cannulation is applied particularly in patients with aortic dissection. For the diseased ascending aorta/aortic arch, a 24 Fr dispersion arterial cannula (Durafluo II, Edwards Lifesciences LLC, Irvine, CA) is used. Otherwise a straight tip cannula in the ascending aorta (DLP, Medtronic, Minneapolis, MN, USA) is used. Cannula tip is always set towards the aortic valve to avoid direct flow to the arch (*Figure 2*). All patients receive 100 mg of betamethasone sodium phosphate, and 100 mg of sivelestat sodium hydrate is added to the pump circuit at the initiation of CPB.

Exposition

After tympanic temperature has dropped down to 23 °C with rectal temperature below 30 °C, the aortic arch aneurysm is opened while raising the central venous pressure to 10 mmHg or brief periods of retrograde cerebral perfusion. By using four traction sutures, including one at the root of each arch vessel and one in the lesser curvature of the arch, the inside of the aortic arch is exposed (*Figure 3*).

SACP is then initiated. A 14- or 16-Fr balloon-tipped cannula is inserted from inside the aorta into the brachiocephalic artery, and 12-Fr cannulae are positioned in the left common carotid and left subclavian arteries

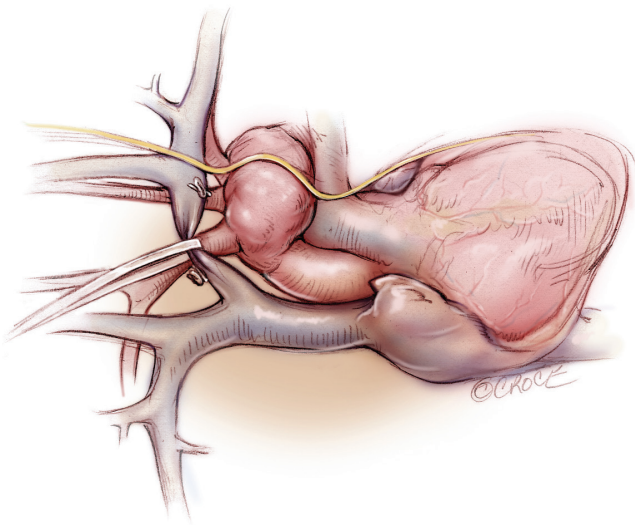


Figure 1 The innominate vein is fully mobilized with division of several branches to facilitate exposure of the aneurysm. The vein is seldom divided.

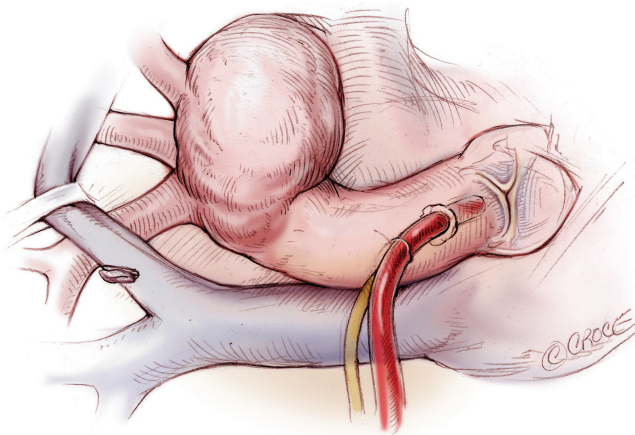


Figure 2 The aortic arch is exposed. Taping around the arch or arch vessels is not necessary. The tip of aortic cannula is always set towards the aortic valve in order to avoid direct flow to the arch.

individually. We routinely use self-inflating serrated-balloon-tipped cannulae (Fuji systems, Tokyo). Snaring of neck vessels is strictly prohibited. Stay stitches are applied to secure the cannulae (*Figure 3*). After insertion, cannulae are fixed to the right skin edge towels, to prevent hindering exposure of the orifice of the descending aorta. Avoiding cerebral embolism is particularly important in SACP cannulation. For the ostium of severely atherosclerotic arch vessels, arteriotomy is extended distally from the diseased

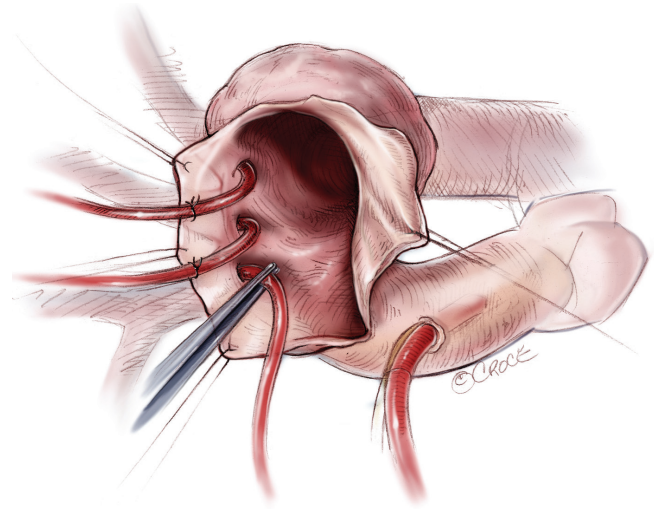


Figure 3 Aortic arch is opened under circulatory arrest. Selective antegrade cerebral perfusion from inside the aortic arch is established and stay sutures are used to secure the cannulae in position.

ostium so that cannulae can be placed in position under direct vision. SACP flow is maintained at 10-12 mL/kg/min using an independent roller pump, and balloon tip pressure is maintained between 30 and 40 mmHg. Myocardial protection is achieved by antegrade or retrograde cardioplegia. Gauze sponges are placed in the aortic root and in the descending aorta to catch atheromatous debris.

Aortic arch reconstruction

The vagal nerve is never dissected out to prevent left recurrent laryngeal nerve injury and to alleviate inadvertent injury of the esophagus. Direct circumferential transection of the proximal end of the descending aorta, distal to the aneurysm is usually performed starting at 3 o'clock position. Incising back of the aortic arch may not be necessary and can be rather harmful sometimes to the left recurrent laryngeal nerve (*Figure 4*). It is very important not to lose the adventitia in this maneuver. Further dissection of the descending aorta, at least 3-5 cm, is necessary in order to have enough suture bites and for placement of a 25 mm wide Teflon felt strip around the proximal descending aorta. Usually the bronchial arteries are divided, and sometimes the upper intercostal arteries, in order to mobilize the descending aorta (*Figure 5*). The thoracic duct often lies along the descending aorta in this level and should not be injured. Every attempt is made to leave the left pleura intact

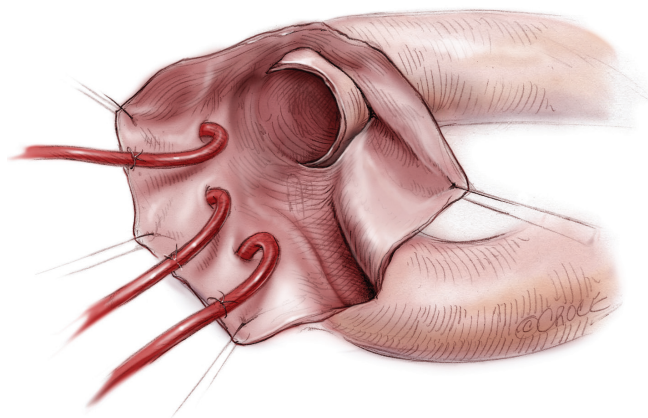


Figure 4 The orifice of the descending aorta is enucleated from the inside of the arch. Direct circumferential transection of the proximal end of the descending aorta, distal to the aneurysm is usually performed starting at 3 o'clock position. Incising back of the aortic arch may not be necessary and rather harmful sometimes to the left recurrent laryngeal nerve.

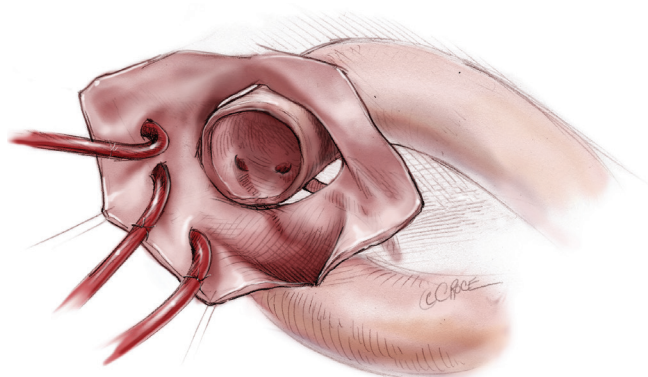


Figure 5 The right and left bronchial arteries are divided and sometimes the upper intercostal arteries are also divided in order to mobilize the descending aorta.

otherwise inadvertent bleeding from the distal anastomosis may escape into the deep in the left pleural cavity and go unnoticed.

A sealed four-branched (10, 8, 8, 8 mm) graft (J graft. Japan Lifeline, Tokyo or Triplex, Terumo Corporation, Tokyo, Japan) is used. Open distal aortic anastomosis is performed with a flexible sucker being placed inside the graft to collect blood in the descending aorta (Figure 6). A 4-0 monofilament suture on a 22 mm needle is used. The suture starts at 9 o'clock position, progressing counter-clockwise. Suture is tied first and bites are taken at least

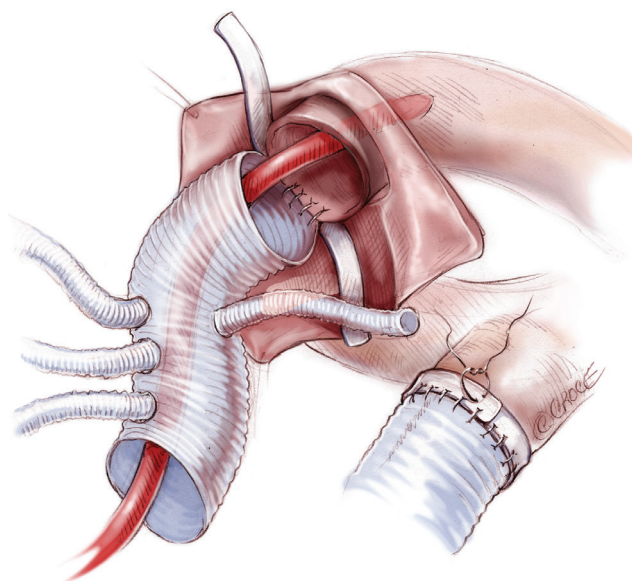


Figure 6 A 25 mm wide Teflon felt strip is placed around the descending aorta. A sealed four branched (10, 8, 8, 8 mm) graft (J graft. Japan Lifeline, Tokyo or Triplex, Terumo Corporation, Tokyo, Japan) is used. The open distal aortic anastomosis is performed with a flexible sucker being placed inside the graft to collect the blood in the descending aorta. The suture starts at 9 o'clock position, going counter-clockwise. The suture is tied first and suture bites are taken at least 10 mm. After completing anastomosis, a 4-0 compacting suture is placed to fasten the Teflon felt.

10 mm apart. After completing the anastomosis, a 4-0 compacting suture is placed to fasten the Teflon felt (Figure 6).

Lower body circulation is then reinstated through one branch of the graft, sometimes after flushing from the femoral arterial cannula, and whole body rewarming is started with antegrade perfusion (Figure 7). At this stage, secure hemostasis in the distal suture line must be obtained. Concurrent with re-warming, SACP flow is gradually increased while maintaining the baseline values of rSO_2 . However, SACP flow is limited below 1,200 mL/min at all times to prevent brain edema.

Proximal anastomosis is then accomplished using 4-0, 17 or 22 mm needle, monofilament suture with 10 mm wide Teflon felt reinforcement. After the heart is de-aired, the graft clamp is released and coronary reperfusion is resumed.

Epi-aortic vessel reconstruction

Aortic arch is divided to make vessel buttons with

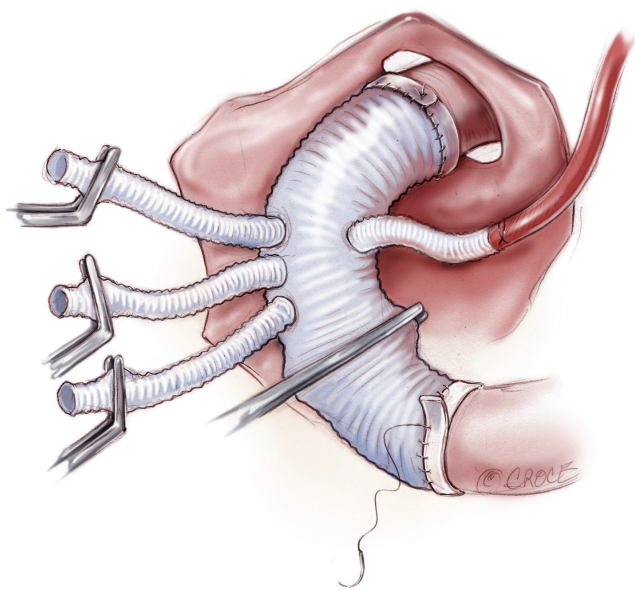


Figure 7 Lower body reperfusion is re-established through the branch graft and early re-warming is initiated while monitoring near infrared spectroscopy. This is followed by proximal anastomosis, with Teflon felt reinforcement externally.

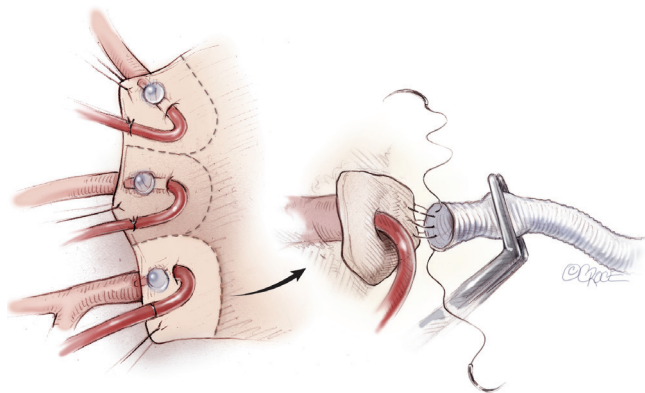


Figure 8 Aortic arch is divided to make vessel buttons with each traction suture. Three arch vessels are reconstructed tandem to the graft branches using a 5-0, 17 mm needle, monofilament suture. Usually the parachute technique is used and each vessel is perfused after completion of the anastomosis.

each traction suture (*Figure 8*). Three arch vessels are reconstructed tandem to the graft branches using a 5-0, 17 mm needle, monofilament suture. Usually the parachute technique is used and each vessel is perfused after completion of the anastomosis. CPB is then weaned-

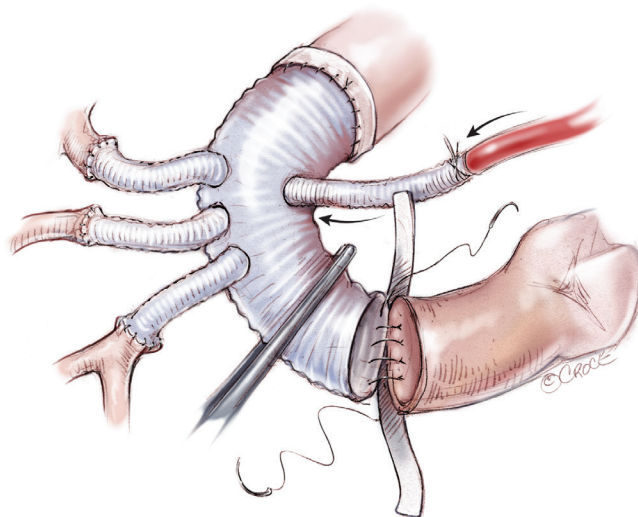


Figure 9 If the patient also has carotid artery or intracranial artery stenosis/occlusion, epi-aortic vessel reconstruction is performed prior to re-warming. After distal anastomosis to the descending aorta, while perfusing the brain in 23 °C degree, the left subclavian artery, the left common carotid artery, and the brachiocephalic artery are anastomosed and perfused tandem. Rewarming is then started and proximal anastomosis is performed as same fashion.

off. The left pleura is now opened longitudinally near the sternum to monitor unexpected bleeding into the left pleural cavity.

If the patient also has carotid artery or intracranial artery stenosis/occlusion, epi-aortic vessel reconstruction is performed prior to re-warming (*Figure 9*). After distal anastomosis to the descending aorta, while perfusing the brain at 23 °C, the left subclavian, left common carotid, and brachiocephalic arteries are anastomosed and perfused. Rewarming is then started and proximal anastomosis is performed in the same fashion.

Aortic dissection

In patients with acute aortic dissection, requiring total arch replacement, hypothermic circulatory arrest is achieved and the arch is opened. SACP is initiated by inserting three balloon-tipped catheters in the true lumen of the arch branches. No tourniquet around the arch vessels is necessary. The arch is transected just distal to the left subclavian artery and the adventitia of the descending aorta is carefully dissected without injuring it (*Figure 10*).

A 5 cm long, 16 to 20 mm wide, Dacron graft is inserted

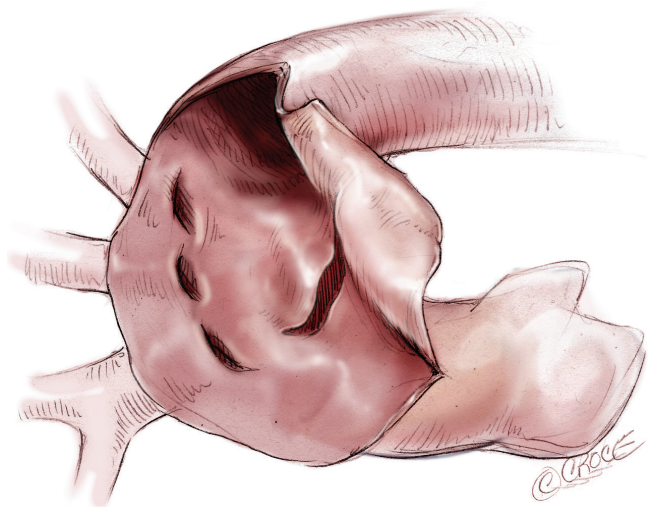


Figure 10 In an acute aortic dissection case, hypothermic circulatory arrest is initiated through femoral cannulation and the arch is opened longitudinally.

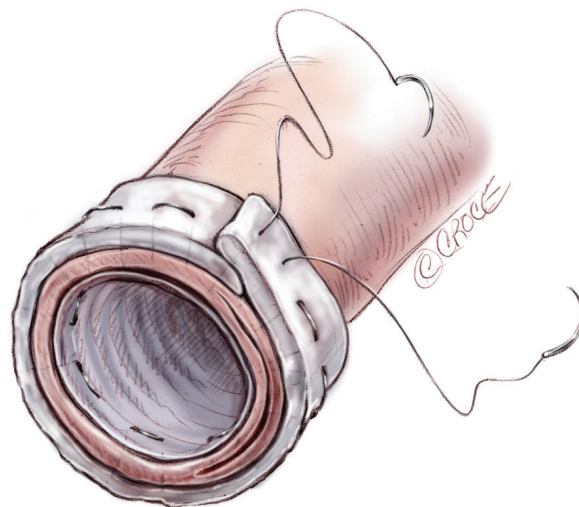


Figure 12 A continuous horizontal mattress suture of 5-0 polypropylene sutures with straight needle is used to secure the elephant trunk, dissection flap, and the adventitia.

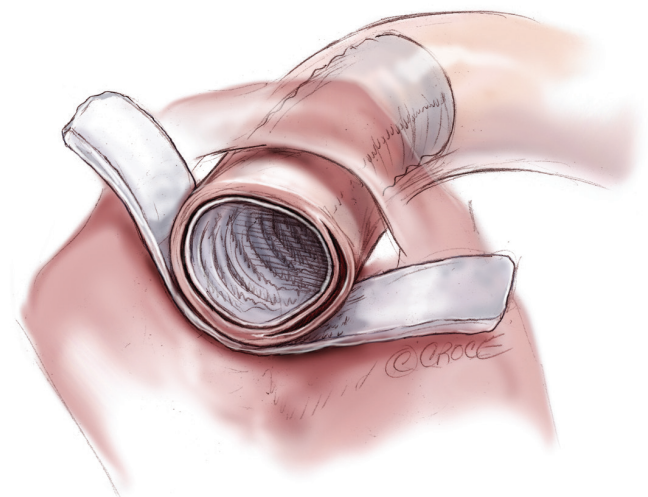


Figure 11 As an elephant trunk, a 5 cm-length, 16 to 20 mm in diameter, Dacron graft is inserted in the true lumen of the descending aorta and a wider, 3 cm, Teflon felt strip is seated outside the adventitia.

in the true lumen of the descending aorta and a wider, 3 cm, Teflon felt strip seated outside the adventitia (*Figure 11*). A continuous 5-0 polypropylene horizontal mattress suture with straight needle is used to secure the elephant trunk, dissection flap, and the adventitia (*Figure 12*). At this stage, all circulation is stopped for 3 minutes to dry-

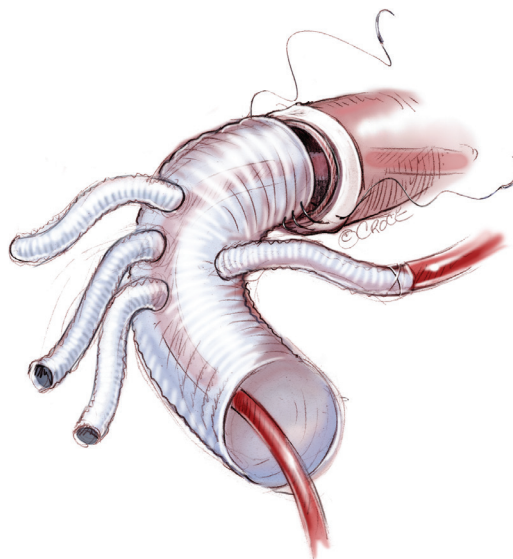


Figure 13 Distal anastomosis with four-branched graft to the descending aorta, including the elephant trunk, aortic wall, and the felt strip, is then performed using 4-0 polypropylene sutures.

up the lumen of the descending aorta, and biological glue (Bioglue) is used to obliterate the false lumen.

Distal anastomosis with four-branched graft to the descending aorta, including the elephant trunk, aortic wall, and the felt strip, is then performed using 4-0 sutures (*Figure 13*).

The circulation of the lower body is then initiated. The

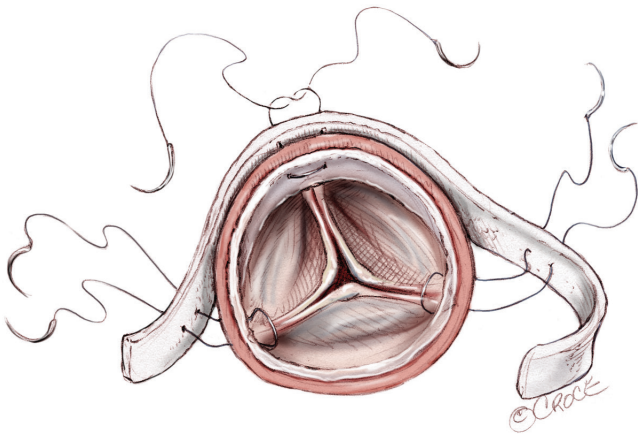


Figure 14 The proximal aortic stump is incorporated with the aortic valve commissures, the false lumen, and the inner and outer Teflon felt using same 5-0 polypropylene horizontal mattress sutures.

proximal aortic stump is incorporated with the aortic valve commissures, the false lumen, and the inner and outer Teflon felt using same 5-0 polypropylene horizontal mattress sutures (Figure 14). Proximal anastomosis is done in the same manner. Aortic arch branches are also reconstructed using small pieces of Teflon felt strips.

The fluid balance during CPB is strictly controlled and kept below 1,000 mL by the ECUM (Capiiox Hemoconcentrator HC11, Terumo Co., Tokyo, Japan). After completion of total arch replacement, the patient is weaned off CPB, receives protamine and decannulated as per routine.

Comments

For surgical approaches to the arch aneurysm, especially for the distal arch aneurysm, both median sternotomy and left thoracotomy can be applied. However, we have been using median sternotomy exclusively to avoid several complications associated with left thoracotomy. Patients with chronic obstructive lung disease or chronic aortic dissection tend to have some adhesions between the aneurysm and the left lung. Lung injury secondary to surgical manipulation, especially after deep hypothermia, can add further risk to the postoperative pulmonary complications (1). Also, the incidence of left recurrent laryngeal nerve damage was higher in patients who had left thoracotomy than those with midsternotomy. We reported that the level of carina or 17 cm from the sternum level to

the back was approachable from the median sternotomy (2).

The selection of an arterial cannulation site and type of cannula are very important in preventing atheroembolic events, particularly neurological complications. In most instances we select the ascending aorta as an arterial cannulation site after inspection of the epiaortic echographic scan. In an experimental study, Fukuda *et al.* (3) confirmed that directing the cannula tip of the Dispersion cannula towards the aortic root generated slower and less turbulent flow in the transverse arch of the glass models of both healthy and aneurysmal aortic arches.

Selective antegrade cerebral perfusion is now considered to be most reliable brain protection method and has been widely used in the field of aortic surgery, albeit with variations (4,5). We have always used three cannulae, which are inserted from inside of the arch without snaring. Urbansky *et al.* (6) used only one cannula to perfuse the whole brain and reported a low incidence of postoperative stroke. Many surgeons perfuse only the brachiocephalic and left common carotid artery, and not the left subclavian artery. However, incompleteness of the circle of Willis has been reported as 20% to 30% in normal population (7), with the vertebral arteries sometimes hypoplastic or stenotic, especially in elderly patients. Also the left subclavian artery often supplies collateral vessels to the spinal cord.

As noted by Kouchoukos *et al.* (8), the exclusion technique for aortic anastomosis or aortic branches is securer than the inclusion technique. We always transect the aorta just distal from the aneurysm and divide several bronchial arteries. This may also alleviate inadvertent injury to the esophagus or left lung. Technically, transection of the aorta is usually performed by incision circumferentially from inside of the aorta, not by incising the aortic arch wall anteriorly or posteriorly.

Usage of the four-branch graft has several potential advantages over the “island” aortic cuff technique to reconstruct the arch vessels. Individual anastomosis of each arch vessel can provide secure anastomosis. By also dividing the arch cuff into the three buttons, more liberal exposure of the aortic arch can be obtained. Consequently, proximal anastomosis of the ascending aorta can precede the arch anastomosis and the resultant reduction in the cardiac ischemic time is beneficial.

In summary, we have found that SCAP is a reliable neuro-protection strategy during aortic arch surgery. In our hands, SACP is associated with low perioperative morbidity and mortality.

Acknowledgements

Disclosure: The authors declare no conflict of interest.

References

1. Asimakopoulos G, Smith PL, Ratnatunga CP, et al. Lung injury and acute respiratory distress syndrome after cardiopulmonary bypass. *Ann Thorac Surg* 1999;68:1107-15.
2. Asano M, Okada K, Nakagiri K, et al. Total arch replacement for aneurysm of the aortic arch: factors influencing the distal anastomosis. *Interact Cardiovasc Thorac Surg* 2007;6:283-7.
3. Fukuda I, Fujimori S, Daitoku K, et al. Flow velocity and turbulence in the transverse aorta of a proximally directed aortic cannula: hydrodynamic study in a transparent model. *Ann Thorac Surg* 2009;87:1866-71.
4. Bachet J, Guilmet D, Goudot B, et al. Antegrade cerebral perfusion with cold blood: a 13-year experience. *Ann Thorac Surg* 1999;67:1874-8; discussion 1891-4.
5. Okita Y, Minatoya K, Tagusari O, et al. Prospective comparative study of brain protection in total aortic arch replacement: deep hypothermic circulatory arrest with retrograde cerebral perfusion or selective antegrade cerebral perfusion. *Ann Thorac Surg* 2001;72:72-9.
6. Urbanski PP, Lenos A, Lindemann Y, et al. Carotid artery cannulation in aortic surgery. *J Thorac Cardiovasc Surg* 2006;132:1398-403.
7. Merkkola P, Tulla H, Ronkainen A, et al. Incomplete circle of Willis and right axillary artery perfusion. *Ann Thorac Surg* 2006;82:74-9.
8. Kouchoukos NT, Wareing TH, Murphy SF, et al. Sixteen-year experience with aortic root replacement. Results of 172 operations. *Ann Surg* 1991;214:308-18; discussion 318-20.

Cite this article as: Okita Y, Okada K, Omura A, Kano H, Minami H, Inoue T, Sakamoto T, Miyahara S, Shirasaka T, Yamanaka K, Ohara T, Nomura Y, Nagai H. Surgical techniques of total arch replacement using selective antegrade cerebral perfusion. *Ann Cardiothorac Surg* 2013;2(2):222-228. doi: 10.3978/j.issn.2225-319X.2013.03.07

Total aortic arch replacement: current approach using the trifurcated graft technique

Scott A. LeMaire^{1,2}, Scott A. Weldon^{1,2}, Joseph S. Coselli^{1,2}

¹Division of Cardiothoracic Surgery, Michael E. DeBakey Department of Surgery, Baylor College of Medicine, Houston, Texas, USA; ²Cardiovascular Surgery Service, The Texas Heart Institute at St. Luke's Episcopal Hospital, Houston, Texas, USA

Introduction

Since the pioneering work of DeBakey, Cooley, and colleagues more than 50 years ago, surgical treatment of aneurysms involving the transverse aortic arch (*Figure 1*) has been associated with substantial morbidity and mortality. As highlighted throughout this issue of *Annals of Cardiothoracic Surgery*, many surgeons have dedicated their careers to improving outcomes for patients who undergo these complex procedures. At our center, techniques for replacing the diseased aortic arch have evolved substantially over the past 15 years. Previously, our approach involved femoral cannulation, profound-to-deep hypothermic circulatory arrest and retrograde cerebral perfusion, and the island technique for reattaching the brachiocephalic vessels. In contrast, we currently use innominate artery cannulation, deep-to-moderate hypothermic circulatory arrest with antegrade cerebral perfusion, and the trifurcated graft (Y-graft) technique for reattaching the arch branches (1,2). We have recently described the rationale for these changes in detail (3-5). For those patients who have an arch aneurysm that extends into the descending thoracic aorta, we generally repair the aneurysm by using the elephant trunk technique, which we have also previously described in detail (3,4,6). Many patients, however, have aneurysms that are confined to the ascending aorta and transverse aortic arch, without involvement of the descending thoracic aorta; such patients undergo total aortic arch replacement with the techniques described in this report.

Operative techniques

Exposure and cannulation

We perform aortic arch repair through a standard median sternotomy. Meticulous hemostasis is maintained to reduce problems with bleeding after the aortic repair. We currently favor using the innominate artery as the inflow site for cardiopulmonary bypass. When the innominate artery is not

suitable for this purpose because of aneurysm, dissection, or severe atherosclerotic disease involving the vessel, we cannulate the right axillary artery (7). In such cases, access to the axillary artery is obtained through an incision in the right deltopectoral groove, with separation of the pectoralis major muscle fibers, division of the pectoralis minor muscle, and careful mobilization of the adjacent vein and cords of the brachial plexus. Regardless of the inflow access site, we use bilateral cerebral near-infrared spectroscopy sensors to monitor brain oxygenation throughout the procedure.

When using the innominate artery as the inflow site, we administer intravenous heparin and apply a partial occluding clamp to the distal aspect of the vessel to achieve both proximal and distal vascular control (*Figure 2*) (5). After creating a longitudinal arteriotomy, we suture an 8-mm gelatin-sealed, woven polyester graft to the vessel. We use polypropylene sutures for this and all other anastomoses during the procedure. After the graft is carefully flushed and de-aired, it is attached to the inflow line from the cardiopulmonary bypass circuit.

Other cannulas placed in preparation for cardiopulmonary bypass generally include a two-stage venous cannula placed via the right atrium, a left ventricular sump placed via the right superior pulmonary vein, and a coronary sinus retrograde cardioplegia cannula. After cardiopulmonary bypass is initiated, systemic cooling commences to establish deep hypothermia; our target temperature generally ranges between 18 and 23 °C. If the patient has significant aortic valve regurgitation, it is often possible to cross-clamp the ascending aorta to prevent ventricular distension and enable delivery of cardioplegia while maintaining systemic flow and cooling through the innominate artery graft.

Branch vessel reconstruction

During the cooling phase, we begin the process of reconstructing the brachiocephalic vessels. We have found that it is easier to approach the left subclavian artery after

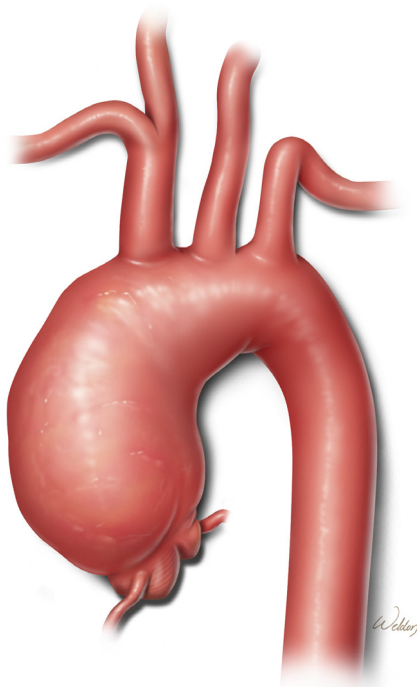


Figure 1 Preoperative anatomy. This aneurysm involves the ascending aorta and transverse aortic arch, tapering to a relatively normal diameter immediately distal to the origin of the left subclavian artery.

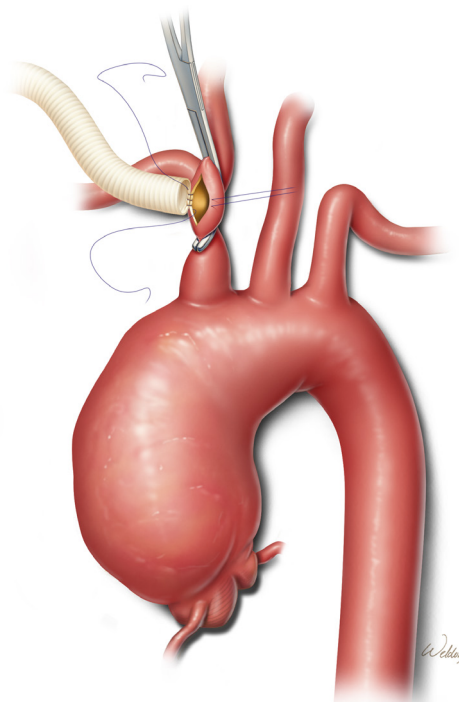


Figure 2 Innominate artery perfusion graft. After a partial occluding clamp is applied to the distal aspect of the artery and a longitudinal arteriotomy is created, an 8-mm graft is sutured to the vessel. The graft is then carefully flushed and de-aired, and attached to the inflow line from the cardiopulmonary bypass circuit.

the arch aneurysm has been decompressed than during the initial cooling period. Therefore, we generally address the left common carotid artery first and save the left subclavian artery for later. After the mid-portion of the left common carotid artery is clamped and its base is ligated, the artery is divided and sutured end-to-end to the middle branch (which has been stretched and trimmed to an appropriate length to avoid kinking) of a prefabricated trifurcated graft (*Figure 3*). This anastomosis is performed while full flow from the cardiopulmonary bypass circuit is maintained.

After the left common carotid artery anastomosis is completed and the desired degree of hypothermia has been reached, systemic hypothermic circulatory arrest is established. The proximal aspect of the innominate artery is occluded with a snare, and flow from the pump is reduced to approximately 10 mL/kg/min. The ascending aorta and transverse aortic arch are then opened. To provide perfusion to the left common carotid artery, a balloon-tipped cannula is connected to a Y-limb from the inflow tubing and placed in the proximal aspect of the trifurcated

graft (*Figure 4*). This is particularly important when near-infrared spectroscopy indicates a substantial decline in left brain oxygenation during antegrade perfusion through the right common carotid artery. After the left subclavian artery is transected, the first branch of the trifurcated graft is trimmed to an appropriate length and sutured end-to-end to the vessel. This branch of the graft is de-aired and its clamp is removed, thereby enabling antegrade perfusion to the left subclavian artery.

Finally, the distal end of the trifurcated graft is cut to appropriate length and sutured end-to-end to the transected innominate artery (*Figure 5*). After this anastomosis is completed, the balloon cannula is removed, the innominate artery snare is released, the trifurcated graft is fully de-aired, and the main trunk is clamped (*Figure 6*). This establishes antegrade cerebral perfusion to all three branches through the innominate inflow graft. Each anastomosis is inspected and selectively reinforced as needed to ensure hemostasis. The trifurcated graft is then reflected in a superior direction, providing unobstructed access to the aortic arch.

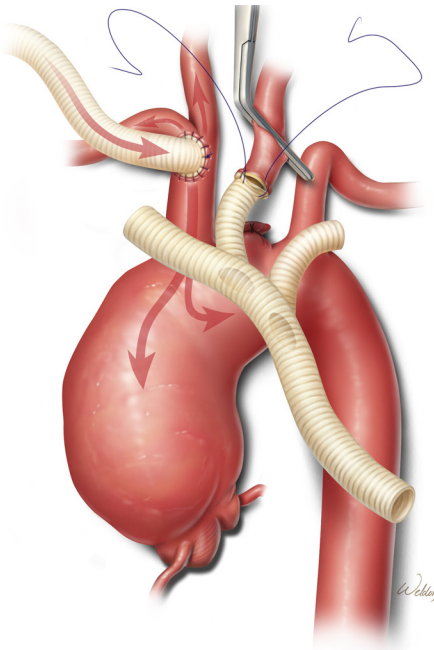


Figure 3 Left common carotid artery anastomosis. After cardiopulmonary bypass and systemic cooling are established, the left common carotid artery is clamped, ligated, and divided. The middle branch of a trifurcated graft is trimmed to an appropriate length and sutured end-to-end to the left common carotid artery while full cardiopulmonary bypass flow is maintained.

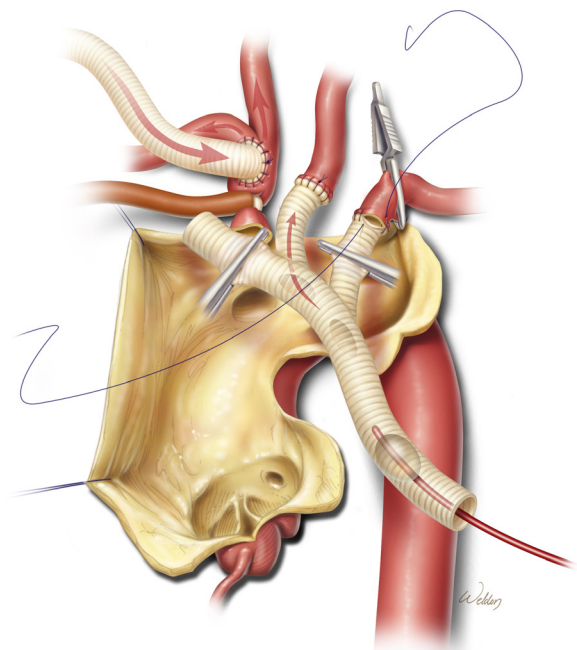


Figure 4 Left subclavian artery anastomosis. After the initiation of systemic hypothermic circulatory arrest and antegrade cerebral perfusion via the innominate artery graft and a balloon-tipped cannula in the proximal aspect of the trifurcated graft, the aortic aneurysm is opened and the left subclavian artery is transected. The first branch of the trifurcated graft is then sutured end-to-end to the left subclavian artery.

Aortic reconstruction

A gelatin-sealed, woven polyester graft with a suitable diameter and a single side-branch is cut to an appropriate length so that the branch is positioned near the distal end. The distal anastomosis is then created (*Figure 6*). Our current preferred technique for reinforcing this anastomosis is to run a second continuous suture over the first suture line. Alternatively, individual pledgetted mattress sutures can be placed along the circumference of the anastomosis.

After the distal anastomosis is completed, the inflow Y-limb from the cardiopulmonary bypass circuit is connected to the side-graft. The graft is de-aired and then clamped, which restores distal perfusion (*Figure 7*). The distal anastomosis is inspected to ensure hemostasis. Attention is then directed to completing the proximal portion of the aortic reconstruction. When this involves an end-to-end anastomosis at the sinotubular junction, we reinforce the suture line with a second running suture or

with individual pledgetted mattress sutures.

After the proximal anastomosis is completed, an oval opening is created in the right lateral aspect of the ascending aortic graft. It is important to position the opening so that the trifurcated graft will not be kinked and will not be compressed by the sternum after closure. Further, the opening is positioned distal enough to enable safe clamping of the proximal portion of the aortic graft in the event that subsequent cardiac surgery is needed. Gradual rewarming is initiated, and the proximal aspect of the trifurcated graft is cut to an appropriate length in a beveled fashion and sutured to the opening in the aortic graft (*Figure 8*). The aortic graft is then thoroughly de-aired, and the clamps are removed.

After adequate rewarming and separation from cardiopulmonary bypass, the perfusion grafts in the distal arch and innominate artery are ligated and divided (*Figure 9*). It is important to use non-absorbable suture to ensure durable occlusion of the transected graft material. The remainder of the procedure, including securing hemostasis and

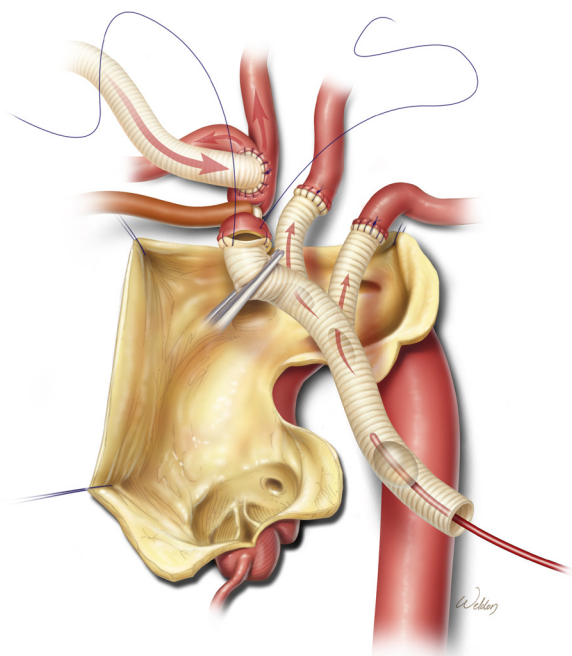


Figure 5 Innominate artery anastomosis. While antegrade cerebral perfusion is delivered to all three arch branches, the distal end of the trifurcated graft is sutured end-to-end to the transected innominate artery.

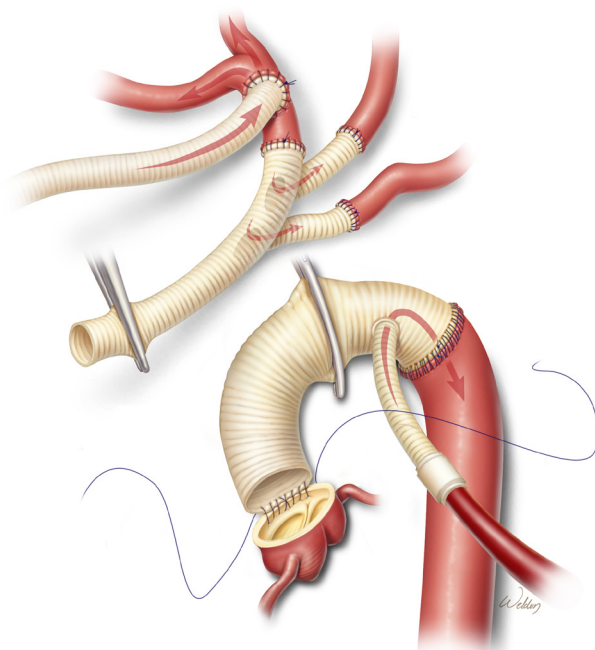


Figure 7 Proximal aortic anastomosis. The aortic graft has been de-aired and clamped, and systemic perfusion has been established through the side-graft. The proximal end of the aortic graft is sutured to the aorta at the sinotubular junction.

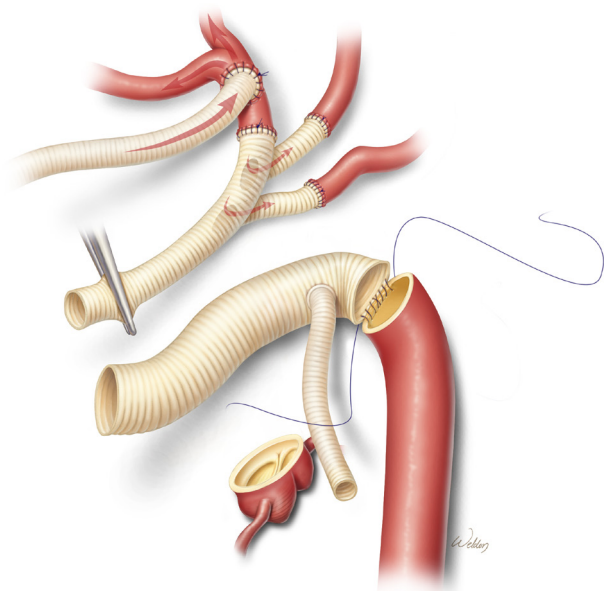


Figure 6 Distal aortic anastomosis. After the branch vessel reconstruction is completed, the trifurcated graft is reflected in a superior direction, providing unobstructed access to the aortic arch. An aortic graft with a single branch is then sutured to the proximal aspect of the descending thoracic aorta. Throughout the arch reconstruction, antegrade cerebral perfusion is delivered via the innominate artery inflow graft.

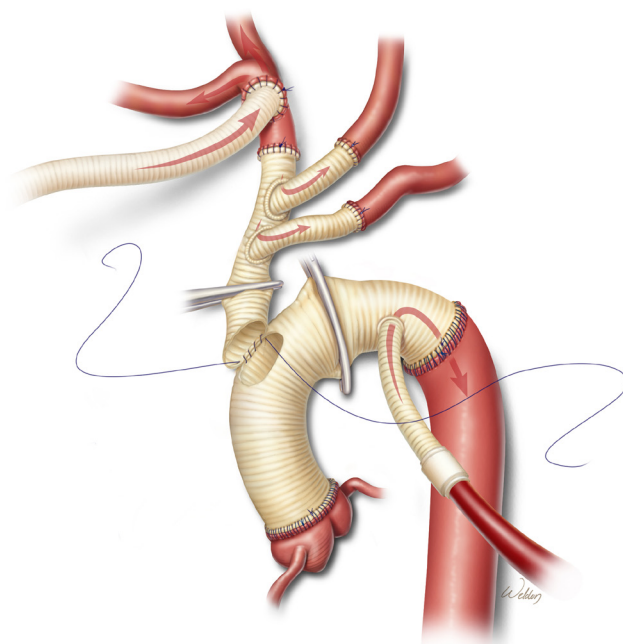


Figure 8 Attachment of trifurcated graft to aortic graft. After an oval opening is created in the right lateral aspect of the ascending aortic graft, the proximal aspect of the trifurcated graft is cut to appropriate length in a beveled fashion and sutured to the opening.

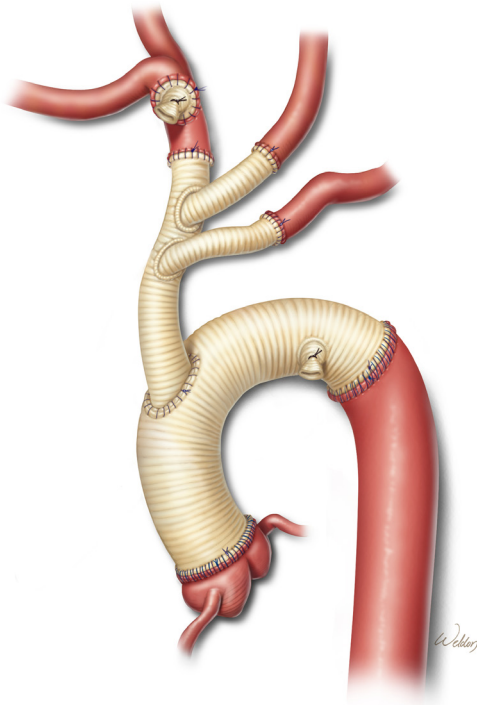


Figure 9 Completed repair. After the trifurcated graft is attached to the aortic graft and the grafts are thoroughly de-aired, the remaining clamps are removed, systemic rewarming is achieved, and the patient is weaned from cardiopulmonary bypass. The perfusion grafts in the distal arch and innominate artery are ligated and divided.

sternotomy closure, proceeds in a standard fashion.

Comments

Our current approach to open total aortic arch repair reflects the incorporation of several new techniques over the past decade. Compared to previous techniques, the recent advances are meant to reduce cerebral ischemia, improve hemostasis, and eliminate residual aortic arch tissue. Early outcomes after aortic arch repair with these techniques have been encouraging, such as those described in our recent retrospective reports (4,5). For example, among 55 patients who recently underwent open total arch repair—including 12 patients (22%) who underwent emergent or urgent operations, 33 (60%) who had a previous sternotomy, and 27 (49%) who underwent a concomitant aortic valve procedure—there was only one (2%) 30-day/in-hospital death (4). Although the median systemic circulatory arrest time was 65 minutes in this cohort, the median cerebral circulatory arrest time was

0 minutes. The median lowest nasopharyngeal temperature was 22.0 °C. Five percent of patients had a stroke, 5% developed renal failure necessitating hemodialysis, and 7% needed reoperation for bleeding. Larger series will be necessary to further evaluate outcomes after these procedures.

Acknowledgements

The authors thank Stephen N. Palmer, PhD, ELS, and Susan Y. Green, MPH, for editorial support. Figures used with the permission of Baylor College of Medicine.

Disclosure: Dr. Coselli serves as a consultant and receives royalties from Vascutek Ltd., a subsidiary of Terumo Corporation.

References

1. Spielvogel D, Halstead JC, Meier M, et al. Aortic arch replacement using a trifurcated graft: simple, versatile, and safe. *Ann Thorac Surg* 2005;80:90-5; discussion 95.
2. Spielvogel D, Strauch JT, Minanov OP, et al. Aortic arch replacement using a trifurcated graft and selective cerebral antegrade perfusion. *Ann Thorac Surg* 2002;74:S1810-4; discussion S1825-32.
3. de la Cruz KI, Coselli JS, LeMaire SA. Open aortic arch replacement: a technical odyssey. *J Extra Corpor Technol* 2012;44:P42-7.
4. LeMaire SA, Price MD, Parenti JL, et al. Early outcomes after aortic arch replacement by using the Y-graft technique. *Ann Thorac Surg* 2011;91:700-7; discussion 707-8.
5. Preventza O, Bakaeen FG, Stephens EH, et al. Innominate artery cannulation: an alternative to femoral or axillary cannulation for arterial inflow in proximal aortic surgery. *J Thorac Cardiovasc Surg* 2013;145:S191-6.
6. LeMaire SA, Carter SA, Coselli JS. The elephant trunk technique for staged repair of complex aneurysms of the entire thoracic aorta. *Ann Thorac Surg* 2006;81:1561-9; discussion 1569.
7. Wong DR, Coselli JS, Palmero L, et al. Axillary artery cannulation in surgery for acute or subacute ascending aortic dissections. *Ann Thorac Surg* 2010;90:731-7.

Cite this article as: LeMaire SA, Weldon SA, Coselli JS. Total aortic arch replacement: current approach using the trifurcated graft technique. *Ann Cardiothorac Surg* 2013;2(3):347-352. doi: 10.3978/j.issn.2225-319X.2013.05.02

Sun's procedure for complex aortic arch repair: total arch replacement using a tetrafurcate graft with stented elephant trunk implantation

Wei-Guo Ma^{1,2}, Jun-Ming Zhu¹, Jun Zheng¹, Yong-Min Liu¹, Bulat A. Ziganshin^{2,3}, John A. Elefteriades², Li-Zhong Sun¹

¹Department of Cardiovascular Surgery, Beijing Anzhen Hospital, Beijing Aortic Disease Center, Capital Medical University, Beijing 100029, China;

²Aortic Institute at Yale-New Haven, Yale University School of Medicine, New Haven, Connecticut, USA; ³Department of Surgical Diseases # 2, Kazan State Medical University, Kazan, Russia

Introduction

Patients with extensive aortic dissections or aneurysms involving the ascending aorta, aortic arch and the descending aorta remain a great challenge for many cardiovascular surgeons due to the complex surgical strategy for arch repair and the limited access to the descending aorta. A combination of surgical and endovascular techniques has enabled the development of the “stented or frozen elephant trunk” procedure (1,2), which aims to eliminate the second stage of the conventional elephant trunk or other procedures on the remaining thoracoabdominal aorta (3).

In 2002, the senior author (L.Z.S.) designed a novel stented graft (Cronus[®]) and proposed a modified technique of total arch replacement using a tetrafurcated graft with implantation of this new stented elephant trunk as a treatment for complex pathologies of the arch and beyond. Since its introduction in 2003, this modified technique has produced satisfactory early and long-term results (4-6). Owing to its innovative design, widespread usage and excellent outcomes, this technique was named after Dr. Sun by domestic and international colleagues in 2008 (7,8).

In this paper, we seek to demonstrate the technical essentials of the Sun's procedure, including implantation of the stented elephant trunk, total arch replacement with a 4-branched graft, right axillary artery cannulation, selective antegrade cerebral perfusion for brain protection, moderate hypothermic circulatory arrest at 25 °C, a special sequence of arch vessel reconstruction, and early rewarming and reperfusion after distal anastomosis to minimize cerebral and cardiac ischemia (8).

Operative techniques

Exposure and cannulation

The Sun's procedure is performed through a standard

median sternotomy under cardiopulmonary bypass (CPB) and selective cerebral perfusion through the right axillary artery. General anesthesia is induced with the patient in the supine position. Blood pressure in the left radial artery and left femoral artery is monitored. We use transcranial Doppler sonography and electroencephalogram to monitor the flow velocity and electrical activity of the brain throughout the procedure. During sternotomy, great care is taken to avoid aortic rupture caused by changes in blood pressure, especially in patients with acute dissections.

The right axillary artery is our preferred inflow site for CPB. The right axillary artery is exposed through an oblique 5-8 cm incision in the right deltopectoral groove 1 cm below the clavicle, with separation of the pectoralis major muscle fibers, retraction of the pectoralis minor muscle, and careful mobilization of the adjacent vein and cords of the brachial plexus. The arterial line is bifurcated in order to perfuse the brain through the right axillary artery and the descending abdominal aorta and lower extremities through the branch of a tetrafurcate graft. In most cases, the right axillary artery can provide adequate perfusion for both brain hemispheres via the circle of Willis and extracranial collateral vessels. Other cannulae for CPB include a two-stage venous cannula placed via the right atrium and a left heart vent placed via the right superior pulmonary vein or the main pulmonary artery.

The innominate vein is mobilized and in some cases, divided for better exposure (9). The arch vessels are exposed, mobilized and surrounded. After heparinization, CPB is initiated with a flow of 2.0-2.4 L/m²/min, and systemic cooling commenced to induce hypothermia. The left phrenic and left vagus nerves are identified and protected by gentle dissection away from the anterior surface of the aorta. The distal ascending aorta is

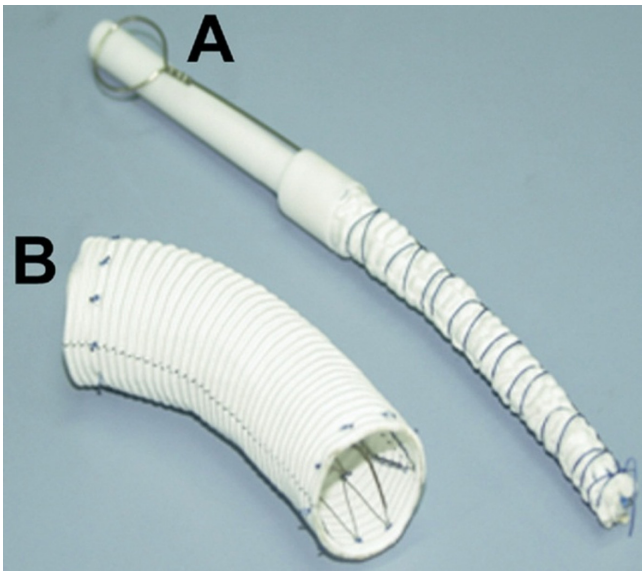


Figure 1 Photos of the stented graft designed by Dr. Sun, Cronus®, before implantation (A) and after deployment (B). There is an extra centimeter of attached regular vascular graft on the distal and proximal ends. The delivery system consists of a grip handle, a guide wire and a pull string of 2-0 silk.

cross-clamped and cold blood cardioplegia is infused intermittently in an antegrade fashion via the coronary ostia. During the cooling phase, the ascending aorta (and the aortic root or valve in some patients) is replaced and other concomitant procedures are performed if indicated. When the nasopharyngeal temperature reaches 25 °C, the patient is put in a Trendelenburg position at a tilt of about 20 °C and circulatory arrest is instituted. After the three arch vessels are cross-clamped, antegrade cerebral perfusion through the right axillary artery is started at a flow rate of 5-10 mL/kg/min. During CPB, a mean perfusion pressure of 40-60 mmHg should be maintained. Arterial blood pH is managed with an alpha-stat strategy. A pressure of 20 mmHg or higher in the left radial artery is considered sufficient for cerebral perfusion.

Stented elephant trunk implantation

The longitudinal opening of the ascending aorta and transverse arch is extended distally to a location between the left carotid and left subclavian arteries, where the descending aorta is transected. Care should be taken to protect the vagus nerve, which lies on the surface of the distal arch. The arch vessels are transected at their origins from the aortic

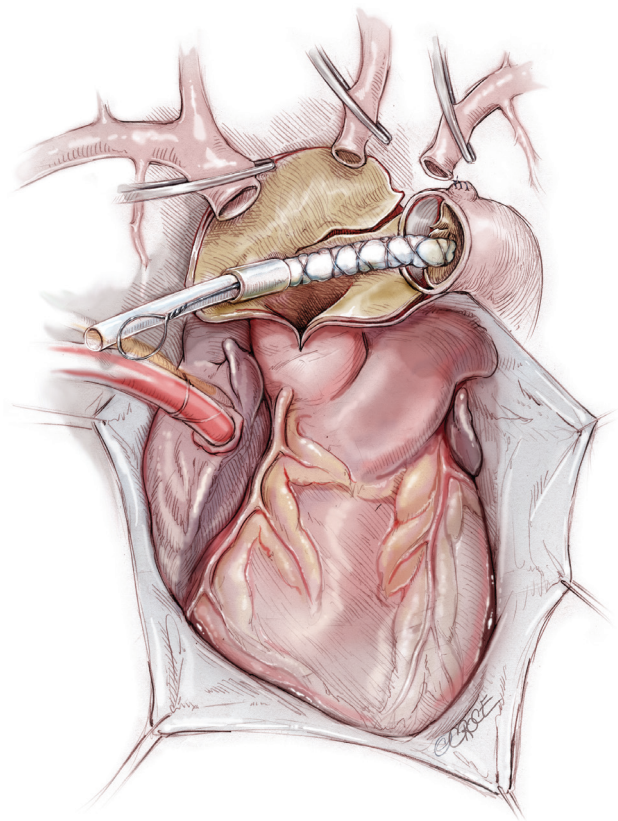


Figure 2 Insertion of the stented graft. The aortic arch is transected between the left carotid artery and left subclavian artery. The stented graft is inserted into the true lumen of the descending aorta.

arch. A stented graft, Cronus® (MicroPort Medical Co. Ltd, Shanghai, China) (*Figure 1*), is inserted into the true lumen of the descending aorta (*Figure 2*) and deployed to compress the false lumen, and most importantly, to enlarge the true lumen (*Figure 3*). It has an extra centimeter of attached regular vascular graft on both ends, to which a conventional hand-sewn anastomosis can be performed. The delivery system consists of a grip handle, a guide wire and a pull string of 2-0 silk. During deployment, the handle is gripped in one hand, the guide wire is pulled out with the other hand, and the stent expanded automatically.

The stented graft implanted in the descending aorta is 10-15 cm in length, depending on the location of intimal tear, diameter of the aneurysmal neck, and size of the patient. In most cases, the distal end of a 10 cm stented graft will reach the level of left atrium, which can be located by preoperative computed tomography angiographic findings. For most patients with dissection, this length will suffice for closing the intimal tear located between the origin of

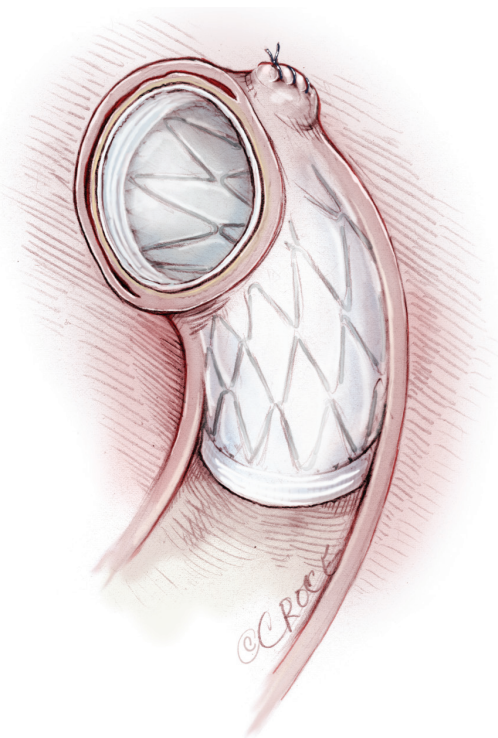


Figure 3 Deployment of the stented graft. The stented graft is deployed inside the true lumen of the descending aorta.

the left subclavian artery and the descending aorta at the level of left atrium, and enlarging the true lumen of the descending aorta. In some patients with a descending aortic aneurysm, a longer 12-15 cm stented graft should be used to reach 2 cm distally beyond the aneurysmal neck.

The diameter of the stented graft should also be tailored to different aortic pathologies. In most dissection patients, we use a 24-28 mm stented graft, which is within the normal anatomic ranges of the Chinese population and can often sufficiently enlarge the true lumen, which is either severely compressed in acute settings or narrowed as a result of true lumen collapse in chronic settings. In aneurysmal patients, however, the diameter of the stented graft should be at least 15-20% greater than that of its distal neck.

The distal transverse arch is trimmed, and the stented graft is anastomosed to a 4-branched graft (Maquet Cardiovascular, Wayne, NJ) in an end-to-end fashion using continuous stitches of 3-0 or 4-0 polypropylene without pledgets. In most cases, this anastomosis is located between the left carotid and left subclavian arteries (10); this is a more superficial site than one that is distal to the left subclavian artery and allows for easier suturing and hemostasis. The

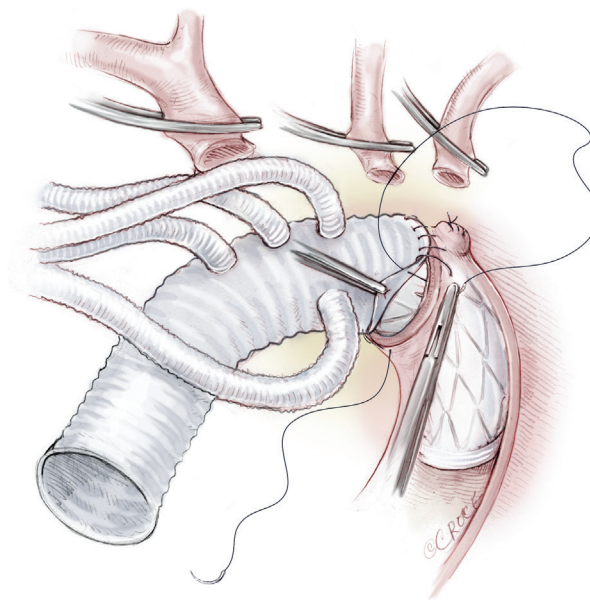


Figure 4 Distal anastomosis. The 4-branched graft is anastomosed distally to the stented graft in an end-to-end fashion. The suture line should include the stented graft, the native aorta, and the 4-branched graft, joining all three layers firmly together. Upon completion, perfusion of the descending aorta and lower body is restarted through the perfusion limb of 4-branched graft.

suture line should include the stented graft, the native aorta and the tetrafurcate graft, so that all these structures are joined firmly together (*Figure 4*). When the distal anastomosis is completed, perfusion of the lower body is resumed through the perfusion limb of the tetrafurcate graft, and the CPB flow is gradually returned to 2.0-2.4 L/m²/min.

In patients with acute dissections, great care must be taken to avoid creating a new intimal tear while inserting the stent graft because the aortic wall is extremely weak and fragile. Our approach is to bend the flexible stent graft and insert it along the curvature of the arch and descending aorta so that it fits well within the true lumen, thereby reducing the risk of intimal tear. Moreover, when performing anastomoses in cases of acute dissections, we prefer using a thinner polypropylene, i.e., 4-0 for suturing the aorta, proximally and distally, and 6-0 for aortic arch branches.

Arch vessel reconstruction

To minimize the time of cerebral and cardiac ischemia, the left common carotid artery is reconstructed first. The middle 8 mm arch branch of the tetrafurcate graft is trimmed to

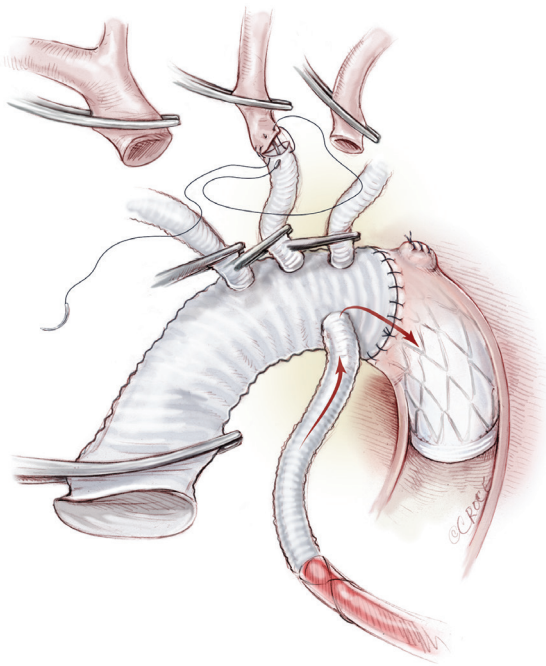


Figure 5 Left carotid reconstruction. The left 8 mm arch branch of the 4-branched graft is anastomosed distally to the left carotid artery in an end-to-end fashion. Upon completion, selective cerebral perfusion is continued bilaterally through the right axillary artery and the left common carotid artery, and rewarming begins.

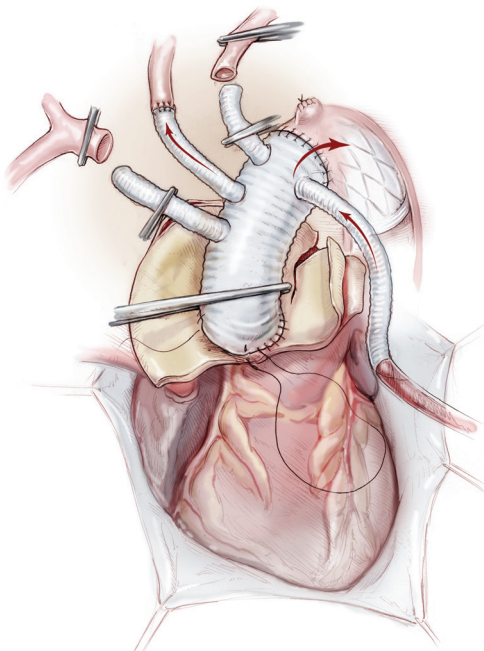


Figure 6 Proximal anastomosis. The 4-branched graft is anastomosed proximally to the ascending aorta (or graft) in an end-to-end fashion. Then, the ascending aorta is deaired and unclamped to restore coronary perfusion.

an appropriate length and anastomosed to the left common carotid artery end-to-end with continuous stitches of 5-0 or 6-0 polypropylene (*Figure 5*). Upon completion of the anastomosis, this branch of the graft is de-aired, its clamp removed and rewarming initiated, thereby enabling bilateral antegrade cerebral perfusion through both the right axillary and left common carotid arteries.

The proximal end of the tetrafurcate graft is then sutured to the ascending aortic graft in an end-to-end fashion with continuous stitches of 3-0 or 4-0 polypropylene (*Figure 6*). After the ascending aorta is thoroughly de-aired, the graft clamp is removed to restore coronary perfusion and cardiac activity, thus minimizing the time of myocardial ischemia. Finally, the left subclavian and innominate arteries are trimmed to an appropriate length and sutured in turn to the 8 and 10 mm branches of the 4-branched graft in an end-to-end fashion with running stitches of 5-0 or 6-0 polypropylene (*Figures 7,8*).

To further reduce the time of lower body ischemia, we also adopted an alternative approach for arch vessel reconstruction. Firstly, the innominate and left carotid arteries are transected at the origins from the aortic arch. Stented graft implantation, distal anastomosis, left carotid reconstruction and ascending aortic anastomosis are done in the same manner. Then, the left subclavian artery is transected 5-10 mm distal to its origin from the arch. After its proximal end is oversewn and ligated, the distal end of left subclavian artery is attached to the right 8 mm branch of the 4-branched graft end-to-end using continuous stitches of 5-0 or 6-0 polypropylene. Similarly, the innominate artery is reconstructed as previously described.

After completion of the repair and adequate rewarming, the patient is weaned from CBP, and the perfusion limb of the tetrafurcate graft is ligated and divided. For better hemostasis, we prefer approximating the residual aortic wall and in some cases, taking a pericardial patch from the patient's native pericardium, to cover the surgical site and create a Cabrol fistula from the perigraft space to the right atrium so that any postoperative bleeding will not be problematic. Biological or chemical glue may be used to reinforce the suture lines. The remainder of the procedure, including securing hemostasis and sternal closure, is performed in a routine fashion.

Comments

The key advantage of Sun's procedure lies in its unique stented graft, which we believe is superior to other

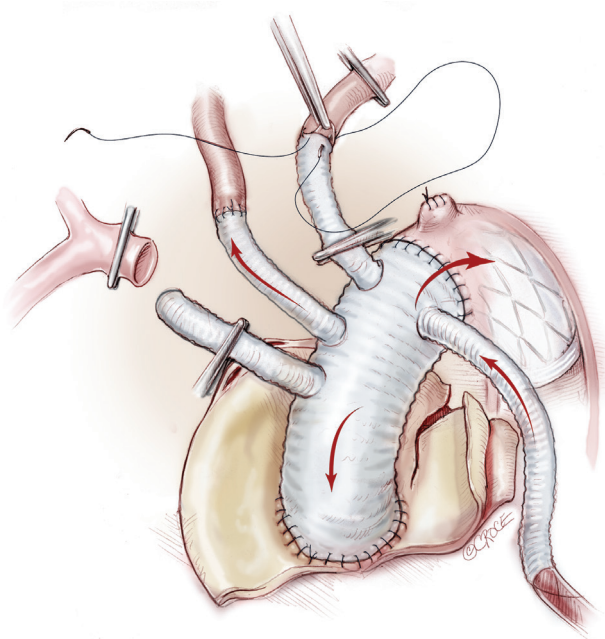


Figure 7 Left subclavian reconstruction. The middle 8 mm arch branch of the 4-branched graft is connected distally to the left subclavian artery in an end-to-end fashion.

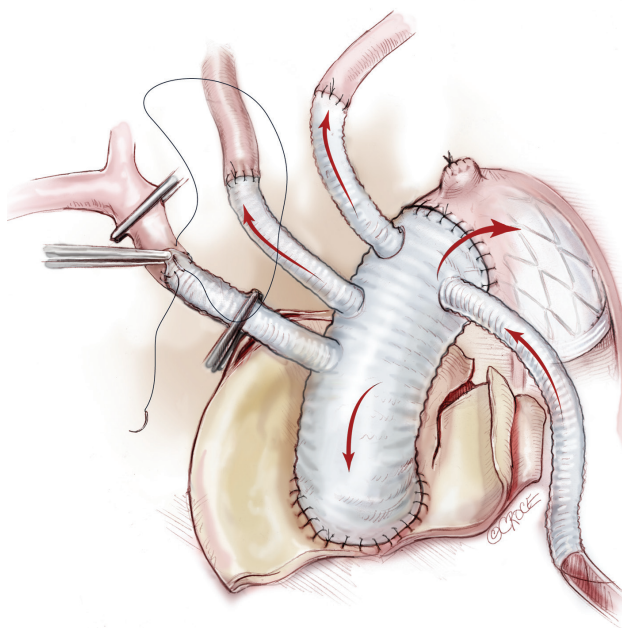


Figure 8 Innominate artery reconstruction. The right 10 mm arch branch of the 4-branched graft is connected distally to the innominate artery in an end-to-end fashion.

commercially available or custom-made stented grafts, including the Chavan-Haverich (2001-2005), Jotec E-vita open and E-vita open plus (2005-2010), and the newly emerging Thoraflex Hybrid (11). The superiority of this stented graft lies in its technical simplicity, as it can be deployed very easily and quickly, often within seconds. It is highly flexible, and can tolerate the forces of bending, cross-clamping and all other surgical manipulations very well. More importantly, this special stent graft has an extra centimeter of attached regular vascular prosthesis, proximally and distally, to which a conventional hand-sewn anastomosis can be performed. This is helpful for minimizing the risk of proximal endoleak and facilitating manipulations in second-stage operations. Our results have shown that implantation of a 10-15 cm graft promotes false lumen thrombosis - which may obviate the need for surgical reintervention - and is not associated with increased incidence of paraplegia or malperfusion syndromes. (4-6).

Due to the technical complexity of the frozen elephant trunk technique, some pitfalls may occur in Sun's procedure, these include difficulties in dissecting and mobilizing the right axillary artery and arch vessels, cannulating the right axillary artery, anastomosing the left subclavian artery, and inserting the stented graft into small true lumens, as well as injury to adjacent organs and tissues (12). Specifically, extensive mobilization of a 3-5 cm segment of the left carotid artery will greatly facilitate exposure and anastomosis of the left subclavian artery. Great caution must be taken when performing the distal anastomosis between the 4-branched graft and the stented graft because bleeding at this site is very difficult to control afterwards. Each anastomosis should be inspected and selectively reinforced as needed with individual pledgetted mattress sutures to ensure hemostasis. It is important to trim and position the 4-branched graft and its arch branches appropriately so that they will not be kinked or compressed by the sternum after closure (12).

As of June 2013, we have performed Sun's procedure in 1,092 cases, the largest series in China with an in-hospital mortality rate of 6.27% (7.98% in emergent or urgent versus 3.98% in elective cases). The incidence of second-stage operation was 4%, mostly in patients with Marfan syndrome (5). This is lower than most contemporary reports (6). At 42 ± 18 months postoperatively, complete thrombus formation around the stented graft—extending to the diaphragmatic surface in 70% of patients—was observed in 93% of patients (5).

With increasing experience, the indications of Sun's

procedure have evolved considerably. Currently, Sun's procedure is chiefly indicated in extensive dilating pathologies involving the ascending aorta, aortic arch, descending aorta and beyond. The most common indications include: (I) type A dissections, either with the primary entry located in the arch and descending aorta, or that involving the arch vessels, with intimal intussusception in the arch or complicated by Marfan syndrome; (II) thoracic aortic aneurysms of the ascending aorta, arch and descending aorta; (III) some type B dissections, such as those involving the aortic arch or with concomitant heart disease requiring surgical treatment and complications of endovascular repair for type B dissections, including retrograde type A dissection, endoleak, etc; (IV) congenital aortic lesions requiring repair of the arch and descending aorta (8).

At present, more than 8,000 cases of Sun's procedure have been performed in China, and cardiac surgeons in South American countries have successfully performed this procedure in over 200 patients (8). The Sun's procedure is now becoming increasingly applied and utilized worldwide (8), and "may become the next standard treatment in patients with type A aortic dissection involving repair of the aortic arch" (5).

Acknowledgements

Disclosure: The authors declare no conflict of interest.

References

1. Kato M, Ohnishi K, Kaneko M, et al. New graft-implanting method for thoracic aortic aneurysm or dissection with a stented graft. *Circulation* 1996;94:II188-93.
2. Karck M, Chavan A, Hagl C, et al. The frozen elephant trunk technique: a new treatment for thoracic aortic aneurysms. *J Thorac Cardiovasc Surg* 2003;125:1550-3.
3. Borst HG, Walterbusch G, Schaps D. Extensive aortic replacement using "elephant trunk" prosthesis. *Thorac Cardiovasc Surg* 1983;31:37-40.
4. Liu ZG, Sun LZ, Chang Q, et al. Should the "elephant trunk" be skeletonized? Total arch replacement combined with stented elephant trunk implantation for Stanford type A aortic dissection. *J Thorac Cardiovasc Surg* 2006;131:107-13.
5. Sun L, Qi R, Zhu J, et al. Total arch replacement combined with stented elephant trunk implantation: a new "standard" therapy for type a dissection involving repair of the aortic arch? *Circulation* 2011;123:971-8.
6. Sun L, Qi R, Zhu J, et al. Repair of acute type A dissection: our experiences and results. *Ann Thorac Surg* 2011;91:1147-52.
7. Zhu XD. Preface. In: Sun LZ, Zhu JM, Liu YM, et al. eds. *Surgery of the aorta* (ed 1st). Beijing: People's Medical Publishing House, 2012:5.
8. Ma WG, Zheng J, Liu YM, et al. Dr. Sun's procedure for type A aortic dissection: total arch replacement using tetrafurcate graft with stented elephant trunk implantation. *Aorta* 2013;1:59-64.
9. Sai Sudhakar CB, Elefteriades JA. Safety of left innominate vein division during aortic arch surgery. *Ann Thorac Surg* 2000;70:856-8.
10. Ziganshin B, Elefteriades JA. Does straight deep hypothermic circulatory arrest suffice for brain preservation in aortic surgery? *Semin Thorac Cardiovasc Surg* 2010;22:291-301.
11. Ius F, Fleissner F, Pichlmaier M, et al. Total aortic arch replacement with the frozen elephant trunk technique: 10-year follow-up single-centre experience. *Eur J Cardiothorac Surg* 2013. [Epub ahead of print].
12. Zhu JM, Zheng J. The Sun's procedure. In: Sun LZ, Zhu JM, Liu YM, et al. eds. *Surgery of the aorta* (ed 1st). Beijing: People's Medical Publishing House, 2012:301-9.

Cite this article as: Ma WG, Zhu JM, Zheng J, Liu YM, Ziganshin BA, Elefteriades JA, Sun LZ. Sun's procedure for complex aortic arch repair: total arch replacement using a tetrafurcate graft with stented elephant trunk implantation. *Ann Cardiothorac Surg* 2013;2(5):642-648. doi: 10.3978/j.issn.2225-319X.2013.09.03

Emergent treatment of aortic rupture in acute type B dissection

Santi Trimarchi, Sara Segreti, Viviana Grassi, Chiara Lomazzi, Carlo de Vincentiis, Vincenzo Rampoldi

Thoracic Aortic Research Center, Cardiovascular Surgery, Policlinico San Donato IRCCS, Milan, Italy

Aortic rupture with massive left hemothorax is a catastrophic complication of acute type B aortic dissection (*Figure 1*). This is associated with high mortality, due to primarily hemorrhagic shock and hypotension. In this setting, treatment is usually represented by open surgery and/or thoracic endovascular repair (TEVAR). TEVAR is currently the most frequently adopted management; however, its planning in these emergent patients may be very difficult. In emergency, important issues include: (I) presence of a proximal intimal tear in the left hemiarch and absence of useful and safe proximal aortic neck; (II) undersized aortic diameter at preoperative CT scan related to the hypotension; and (III) unavailability of the proper endograft size in that moment.

First stage-TEVAR

Clinical presentation

Hypotension: hemorrhagic shock (mean arterial pressure <50/0 mmHg, Hb <5 g/dL).

Sizing and preparation

The patient is placed in a supine position. Under general anesthesia, right femoral artery access is achieved, and the appropriate endograft size selected (*Figure 2*).

Operation

The stent-graft is introduced with a percutaneous or cut-down technique to cover promptly the proximal entry tear and rupture (*Figure 3*).

The stent-graft is placed in the left hemi-arch, zone 2 based on the Ishimura classification, between the origin of the left common carotid artery and the origin of the left subclavian artery (LSA) (*Figure 3*).

LSA endovascular closure is performed to avoid type II endoleak (*Vascular Plug*). In emergency there's no indication to left carotid-subclavian artery bypass (*Figure 4*).

Hemothorax drainage can then be achieved via left

thoracotomy (*Figure 5*).

Postoperative course

The primary endpoint is to treat the aortic rupture, stop the bleeding and stabilize the hemodynamic status, with the aim to prevent mortality and major cardiac, cerebral, visceral and renal complications. Nevertheless, sub-optimal result may be evident at post-operative examination (CT and MRI): partial apposition of the proximal segment of the endograft (bird beak), evidence of undersized endograft, presence of endoleaks (*Figure 6*).

In such cases, a second operative stage need to be planned. This is performed in a patient with a total clinical recover. In order to fix the proximal endograft in a safe and durable way, open aortic arch repair is managed. The distal arch anastomosis is sutured with the proximal tip of the stent graft.

In patients with type B aortic dissection who were already managed with TEVAR, endovascular approach includes the necessity to extend the proximal landing zone into the ascending/arch, using hybrid techniques. However, patients who suffered aortic dissection may have a fragile arch and TEVAR represents only an alternative to surgical management.

Second stage-ascending aorta and total arch replacement (frozen elephant-trunk technique)

Clinical presentation

Normotension (MAP 120/60, Hb >12 g/dL), general good condition.

Exposure and cannulation

Standard median sternotomy is done with aortic care. The exposure and mobilization of supra-aortic vessels is performed. The innominate vein is mobilized or ligated and divided. Intravenous heparin is administered.

The arterial cannulation is approached via ascending

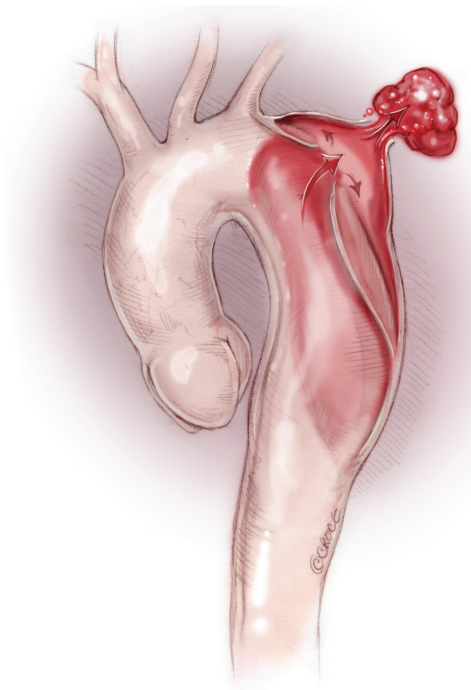

Figure 1 Ruptured acute type B dissection with massive left hemothorax.

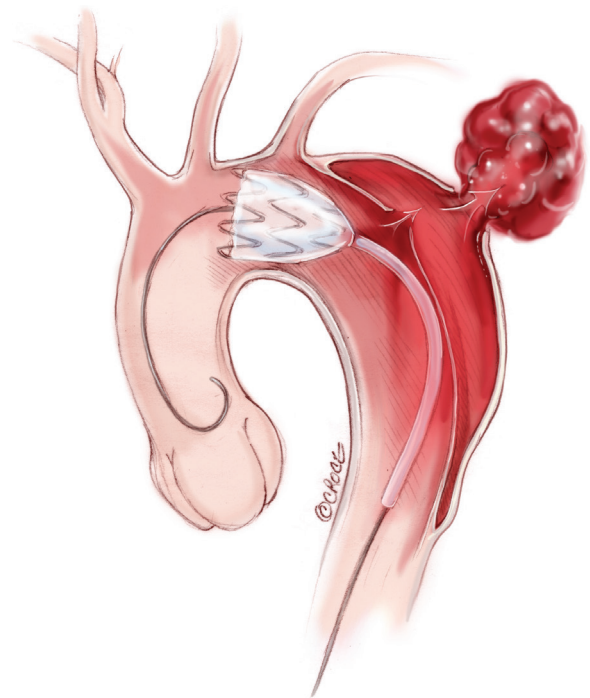


Figure 3 Endograft deployment to cover the entry tear and treat the aortic rupture.

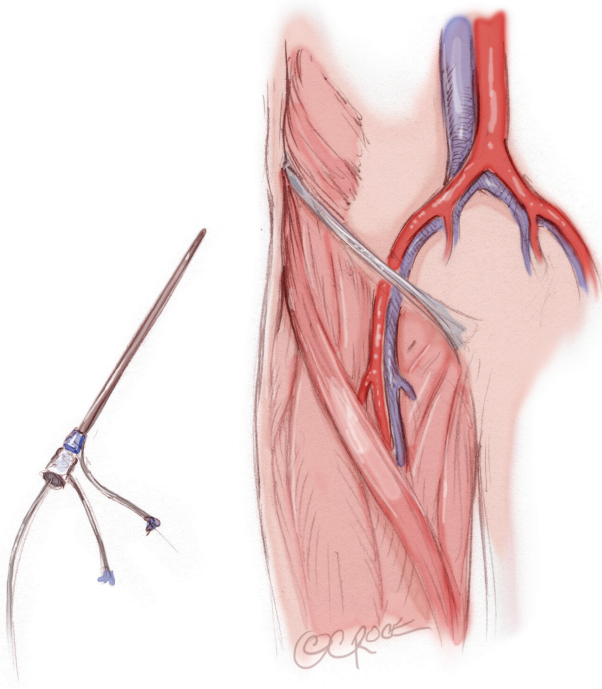


Figure 2 Percutaneous approach avoids the surgical cut-down of the femoral artery.

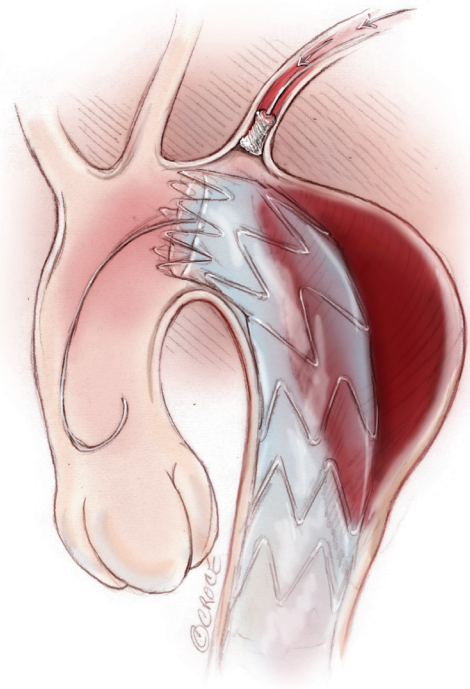


Figure 4 Vascular plug positioning to avoid type 2 endoleak from left subclavian artery.

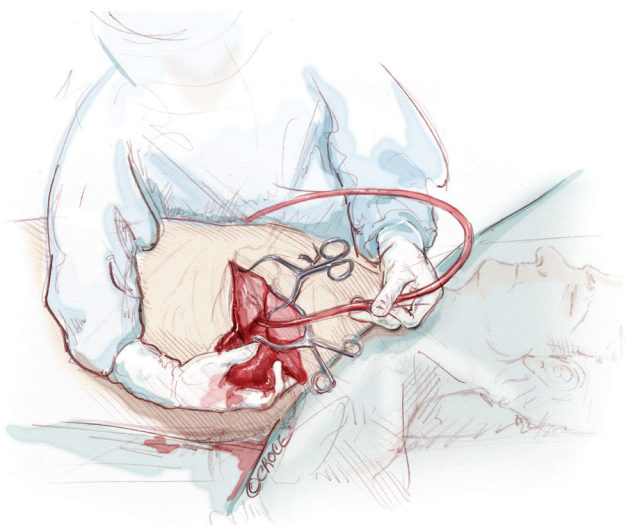


Figure 5 Massive hemothorax drainage via left thoracotomy.

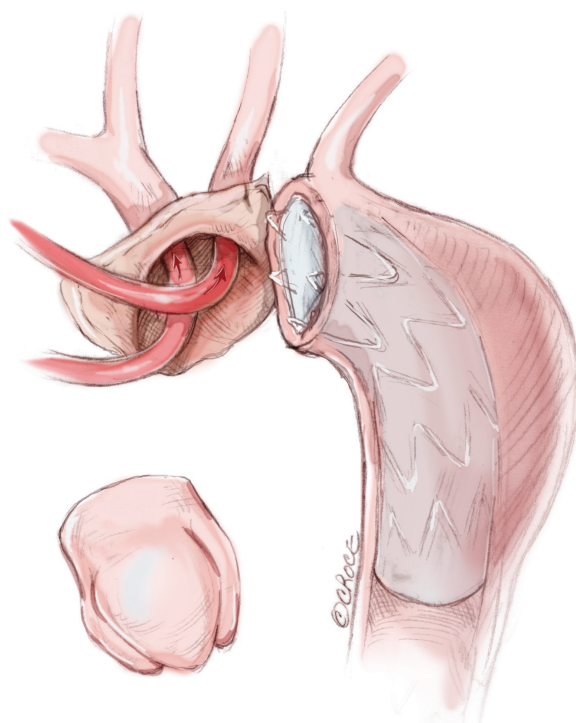


Figure 7 Opened aortic arch.

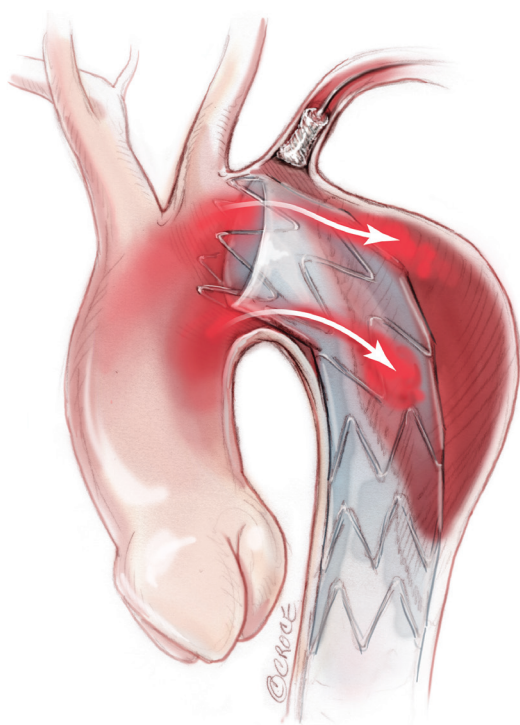


Figure 6 Partial apposition of the proximal segment of the endograft (bird beak) favoring type Ia endoleaks.

aorta or axillary artery. This procedure facilitates the administration of continuous antegrade cerebral perfusion during deep or moderate hypothermia.

Two staged venous cannula is placed via inferior vena

cava and right atrium; left heart vent via right superior pulmonary vein. After cardiopulmonary bypass is initiated, systemic cooling is established. Circulatory arrest is performed between 22-26 °C (bladder temperature).

Bilateral cerebral near-infrared spectroscopy sensors (NIRS) are placed to monitor brain oxygenation during the procedure.

Operation

The ascending aorta and transverse aortic arch are opened. Two balloon-tipped cannulas are placed into the left common carotid artery and the innominate artery to provide selective antegrade cerebral perfusion (*Figure 7*). In case axillary arterial cannulation, right selective cerebral perfusion is obtained clamping the innominate artery. A cold crystalloid cardioplegia is administered via the coronary ostia.

If present, proximal uncovered stents are cut and removed from the endograft (*Figure 8*).

Distal anastomosis is sutured between endograft and Dacron surgical graft and reinforced with outer Teflon strip (*Figure 9*). Three or four interrupted stitches with pledgets

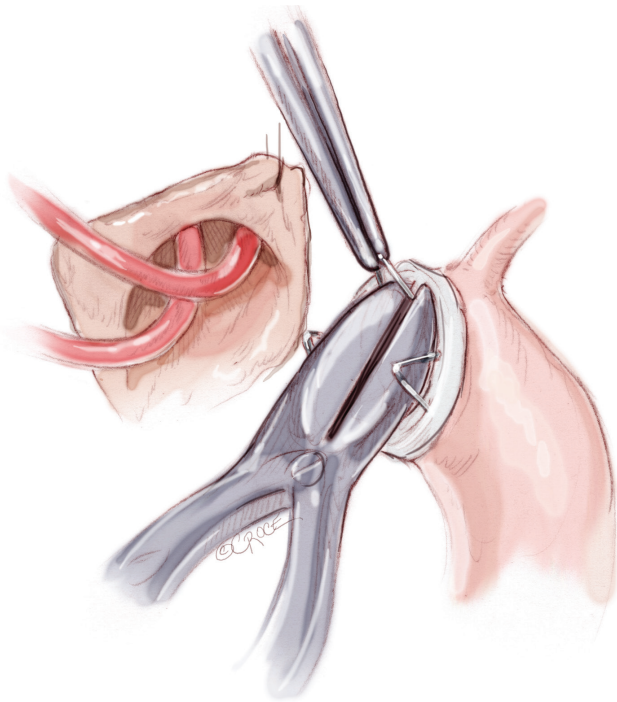


Figure 8 Stent-graft cutting.

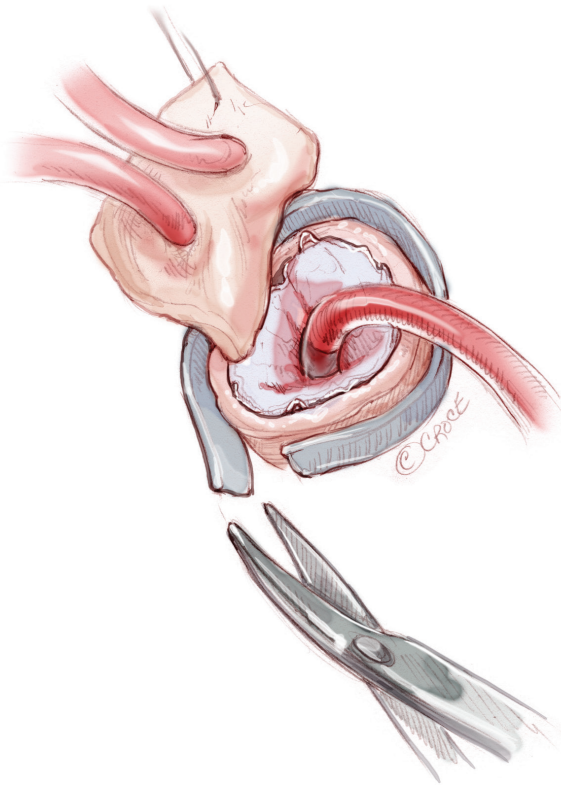


Figure 9 Outer Teflon felt positioning.

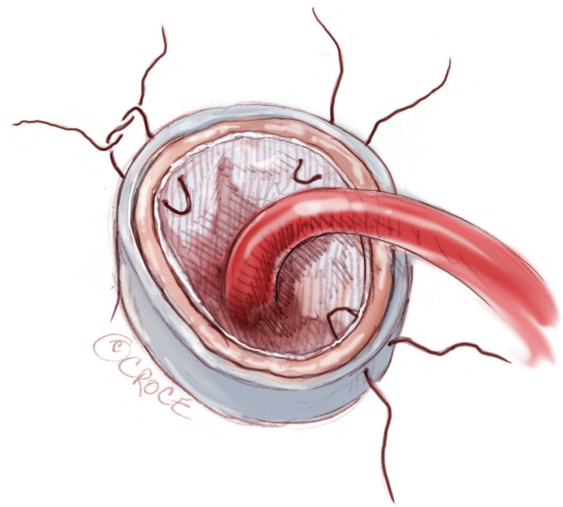


Figure 10 Endograft fixing using Teflon felt stitches.

are sutured at polar points to fix the stent-graft before the continuous suture (*Figures 10,11*). When feasible, the re-implantation of the innominate artery and left carotid artery is managed with an island technique (*Figure 12*).

Surgical graft is clamped before the origin of the supra-aortic vessels and total cardiopulmonary bypass restarts re-warming the patient. The proximal ascending aorta anastomosis is then sutured.

The ascending aorta is de-aired and unclamped to restore myocardial perfusion.

After adequate re-warming, the cardiac activity is restarted by shock and the CPB is stopped when the temperature reaches 35-36 °C. The CPB cannulas are removed. Atrial and ventricular temporary pacemaker and drainage tubes are placed. Accurate hemostasis and sternal closure are performed at the end of the intervention.

Comments

Ruptured acute type B dissection presenting with hemodynamic instability or shock condition have poor outcome. In this setting, the primary aim is to control the aortic bleeding preventing mortality and major morbidity. The possibility to treat such catastrophic event with endovascular procedures allowed to obtain better in-hospital results compared to open surgery. However planning TEVAR in emergency setting can face with important issues like presence of proximal intimal tear in the left hemiarch and absence of useful and safe proximal aortic neck, undersized aortic diameter at preoperative CT

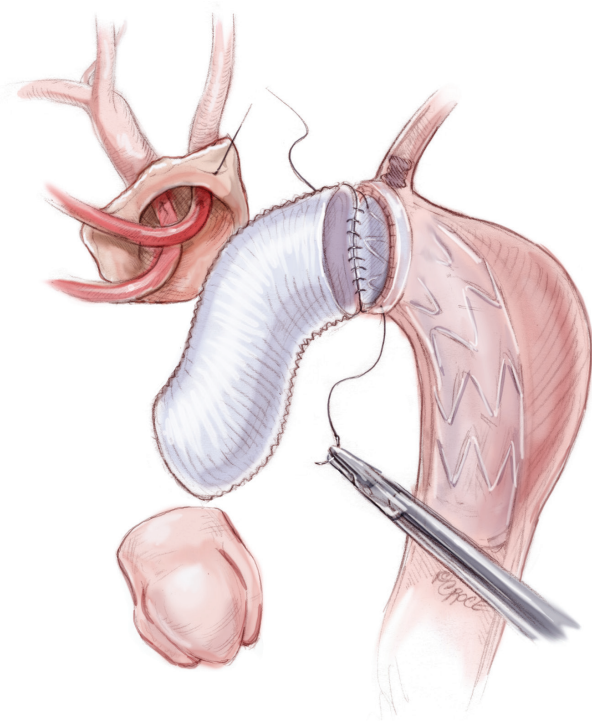


Figure 11 Distal graft-endograft anastomosis.

scan related to the hypotension and unavailability of the proper endograft size in that moment.

In some cases, TEVAR represents both the resolution of the acute status and the definitive treatment of the aortic disease.

In other patients, TEVAR can be associated with suboptimal image results, although it is able to stabilize the hemodynamic status, permitting a temporary patient recover. In this situation TEVAR represents the first step

Cite this article as: Trimarchi S, Segreti S, Lomazzi C, Grassi V, de Vincentiis C, Rampoldi V. Emergent treatment of aortic rupture in acute type B dissection. *Ann Cardiothorac Surg* 2014;3(3):319-324. doi: 10.3978/j.issn.2225-319X.2014.05.05

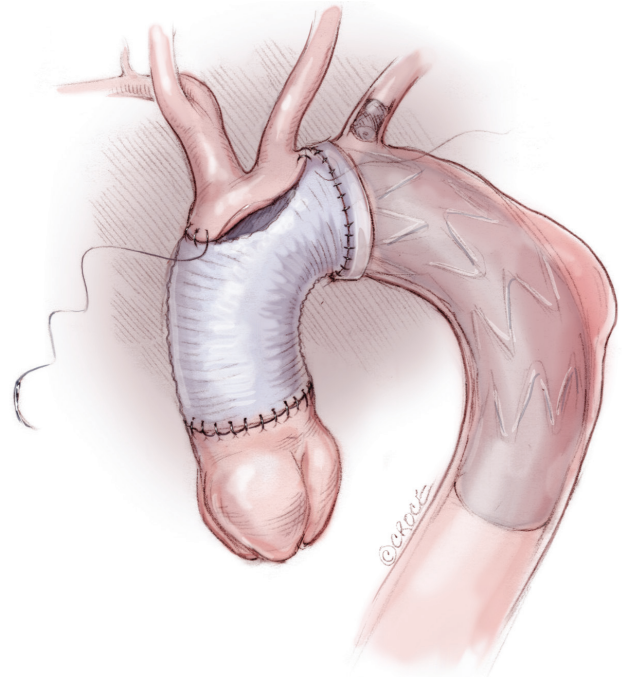


Figure 12 Island technique.

of the aortic treatment. The following second stage consists of an open arch repair procedure, that is safer managed in elective status.

In acute and dramatic circumstances, like ruptured type B dissection, TEVAR is a valid and suitable bridge procedure to open surgery, reducing the overall risk for mortality and major complications.

Acknowledgements

Disclosure: The authors declare no conflict of interest.

Open fenestration for complicated acute aortic B dissection

Santi Trimarchi¹, Sara Segreti¹, Viviana Grassi¹, Chiara Lomazzi¹, Marta Cova¹, Gabriele Piffaretti², Vincenzo Rampoldi¹

¹Thoracic Aortic Research Center, Cardiovascular Surgery, Policlinico San Donato IRCCS, Milan, Italy; ²Section of Vascular Surgery, Department of Surgery and Morphological Sciences, Circolo University Hospital, University of Insubria School of Medicine, Varese, Italy

Introduction

Acute type B aortic dissection (ABAD) is a serious cardiovascular emergency in which morbidity and mortality are often related to the presence of complications at clinical presentation. Visceral, renal, and limb ischemia occur in up to 30% of patients with ABAD and are associated with higher in-hospital mortality. Surgical or endovascular interventions for ABAD are indicated in case of malperfusion syndromes, extension of dissection, and/or aortic rupture. Surgical aortic fenestration was the first operation for the management of complicated aortic dissection, performed for the first time in 1935 by Gurin and colleagues (1). The technique is based on the concept of creating a single lumen, which is believed to resolve malperfusion and limits the risks of intestinal infarction, acute renal failure, and limb ischemia.

Malperfusion syndrome occurs when there is end-organ ischemia secondary to aortic branch compromise from the dissecting process. This can involve one or more aortic branches simultaneously. As consequence, the morbid clinical events will vary as a function of the vascular territory involved.

In the presence of a proximal tear and absence of distal re-entries, the false lumen pressure increases, leading to compression of the true lumen. Such mechanisms can potentially lead to impaired perfusion of distal organs, increasing the risk for visceral and renal ischemia (*Figure 1*). In acute dissections, treatment priority should be assigned to the most life-threatening condition. In acute dissections, treatment priority should be assigned to the most life-threatening conditions. Among these, mesenteric ischemia is highly associated with poor outcome, and may require initial urgent management also in type A dissections, before central aortic repair.

In the current era, endovascular procedures, such as thoracic endovascular aortic repair (TEVAR) or fenestration, represent the first line of treatment in ABAD complicated by malperfusion. Open surgical

fenestration may be used as an alternative treatment should contraindications or failure of endovascular management arise. It has been associated with favorable short and long-term outcome.

Two mechanisms for aortic branch vessel compromise have been identified, each of which has specific treatment implications in the management of malperfusion syndromes (*Figure 2*).

Dynamic obstruction

Dynamic obstruction is the more common mechanism of aortic branch malperfusion, caused by the prolapse of the dissection flap into the vessel ostium (*Figure 3*). Such occlusion is usually evident during the aortic systole, and causes about 80% of malperfusion syndromes. Dynamic obstruction can be determined by cardiac output, blood pressure, heart rate, peripheral resistance of the outflow vessel, and the circumference involvement of the dissected aorta. Typically, in ABAD with peripheral malperfusion, arterial pulses may not be continuously present because of the variability of these hemodynamic and anatomic conditions. Management of the aortic true lumen, based on the coverage of the proximal entry tear using stent-grafts, usually restores an adequate branch inflow.

Static obstruction

In ABAD, obstruction of the aortic branch vessels may be related to a blind end of false lumen, which can compress and thrombose aortic branches (*Figure 4A*). In other cases, the intimal flap may extend into the branch vessels. The simultaneous presence of the true and false lumen within the artery can be associated with compression and the subsequent reduction or loss of the proper area for the blood flow (*Figure 4B*). Additionally, false lumen may be thrombosed due to the blind end of the arterial branch dissection in absence of distal re-entry tears. Thrombosis of

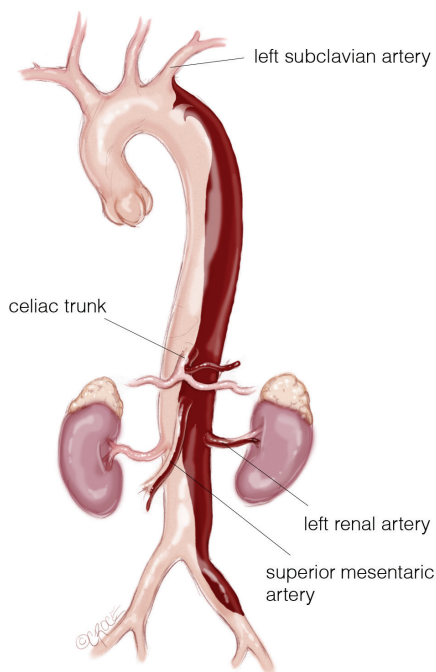


Figure 1 Complete dissection of the thoraco-abdominal-aorta (type B) below the origin of the subclavian artery to the left common iliac artery. In this case the celiac trunk and the superior mesenteric artery are dissected and the left renal artery is excluded.

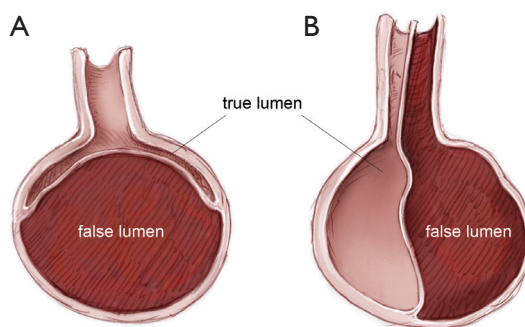


Figure 2 Aortic axial view showing dynamic (A) dynamic and (B) static obstruction.

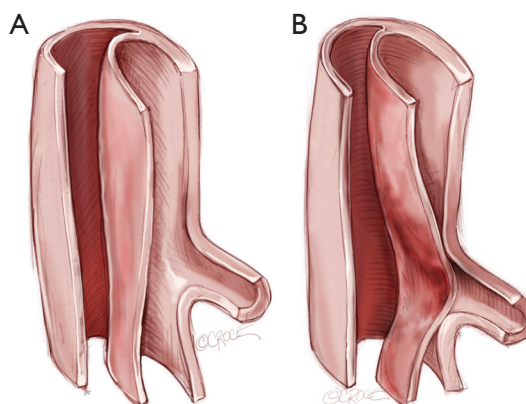


Figure 3 In dynamic obstruction (A,B), the septum may prolapse into the vessel ostium during the cardiac cycle, and the compressed true lumen flow is inadequate to perfuse branch vessel ostia, which remain anatomically intact.

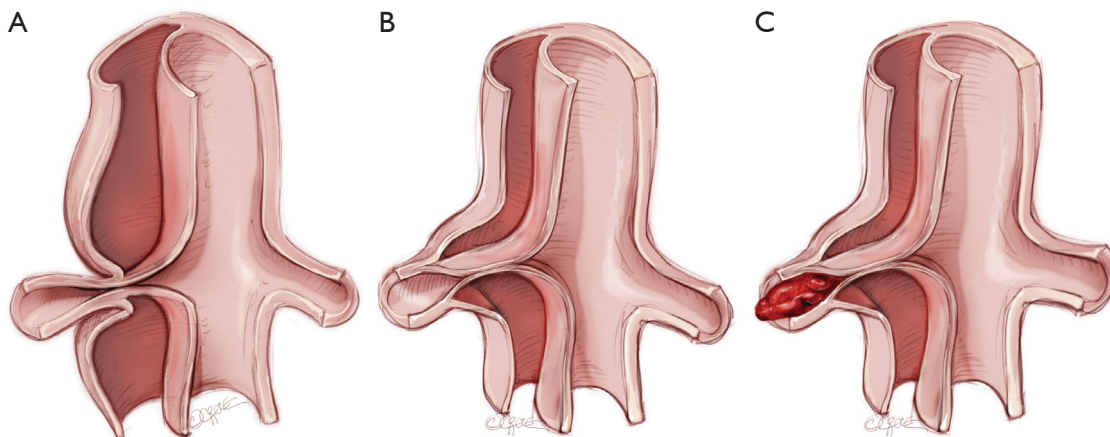


Figure 4 Mechanisms of static obstruction. (A) Compression of the vessel by blind ends of the false lumen; (B) presence of true and false lumen in the vessel causing further compression; (C) thrombosis of the vessel distal to the compromised ostia.

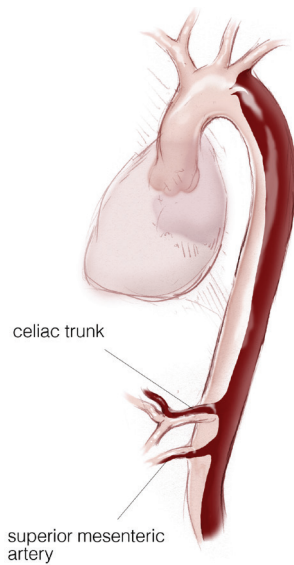


Figure 5 Acute type B aortic dissection (ABAD) involving visceral segment.

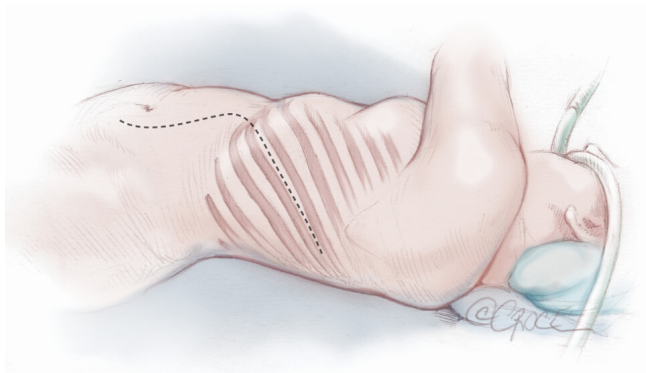


Figure 6 Exposure is achieved through a thoraco-abdominal incision in the 8th or 10th intercostal spaces.

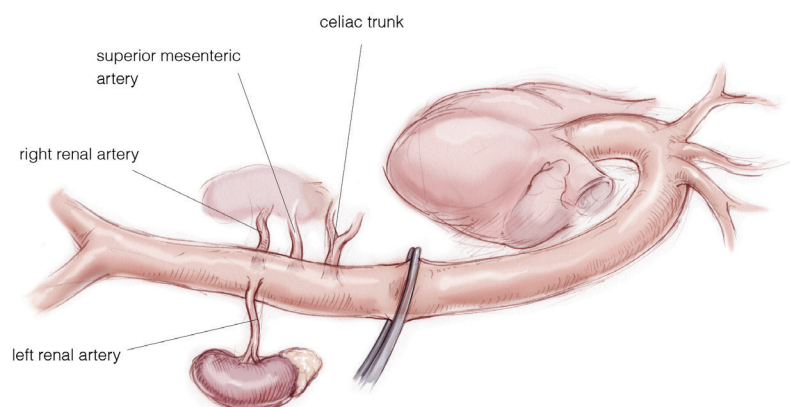


Figure 7 The visceral segment of the aorta is exposed.

the true lumen beyond the compromised ostia may further degrade distal perfusion (*Figure 4C*). All these mechanisms for malperfusion syndrome are defined as *static obstruction*. In these circumstances the restoration of the aortic branch true lumen flow requires management of the vessel itself (stent, fenestration, bypass graft).

Operative technique

In ABAD patients with visceral or renal ischemia who require open surgery (*Figure 5*), the surgical approach is performed through a thoraco-abdominal incision in the 8th or 10th intercostal space (*Figure 6*). This incision allows adequate exposure of the supraceliac and infra-diaphragmatic aorta (*Figure 7*).

After preparation of thoracoabdominal aorta and its branches, a supra-diaphragmatic clamp is placed without the use of any extracorporeal support. Distally, the aorta is clamped at the level of its bifurcation. A longitudinal aortotomy is performed (typically 5-8 cm), and the true and false lumens are identified (*Figure 8*).

The intimal membrane is widely resected, leaving behind the adherent intima. The dissected flap is proximally and distally resected in a triangular shape, to maximize the single aortic lumen. If the dissection extended into the visceral and/or renal arteries, a similar technique is adopted in these arteries (*Figure 9*).

The longitudinal aortotomy is then sutured and reinforced with strips of Teflon, which resulted in a slightly reduced aortic diameter (*Figure 10*).

In ABAD patients with limb ischemia and no visceral/renal malperfusion, the open treatment is conducted through a median laparotomy.

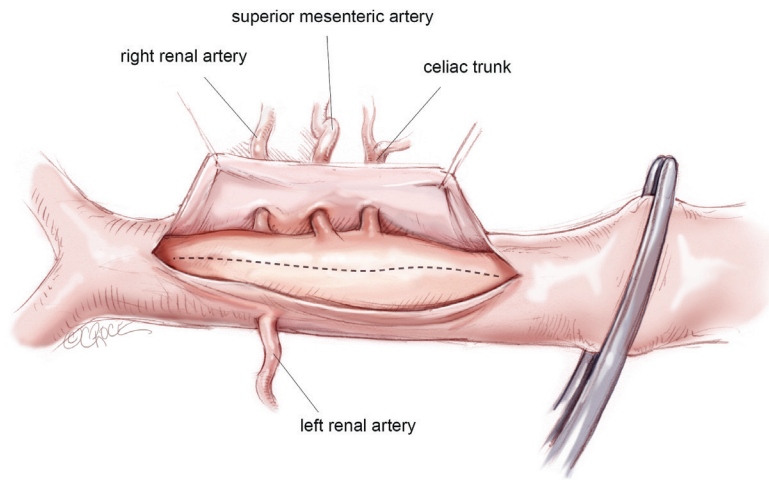


Figure 8 The true and false lumen of the aorta is identified.

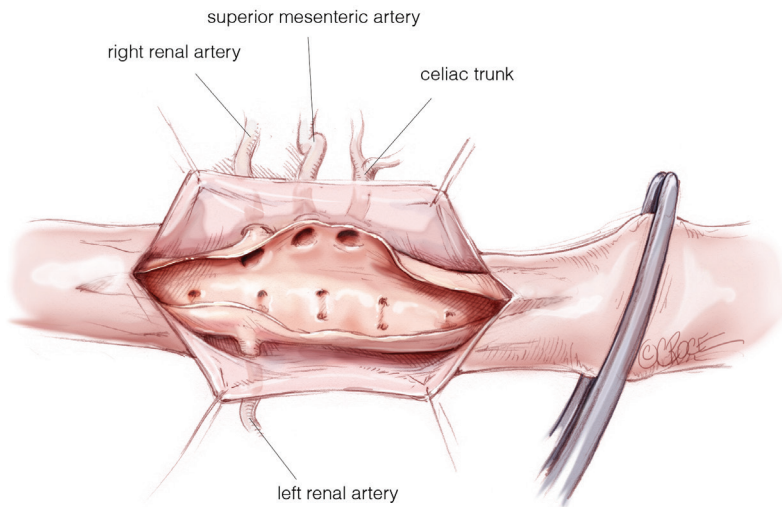


Figure 9 The visceral ostia after the removal of the intimal flap.

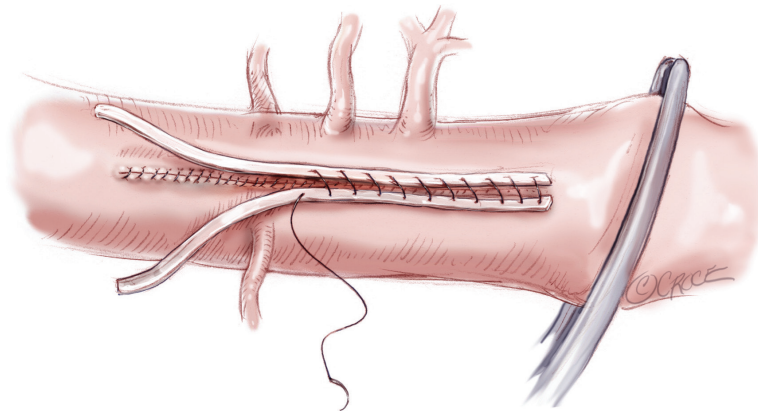


Figure 10 The suture is reinforced with Teflon strips.

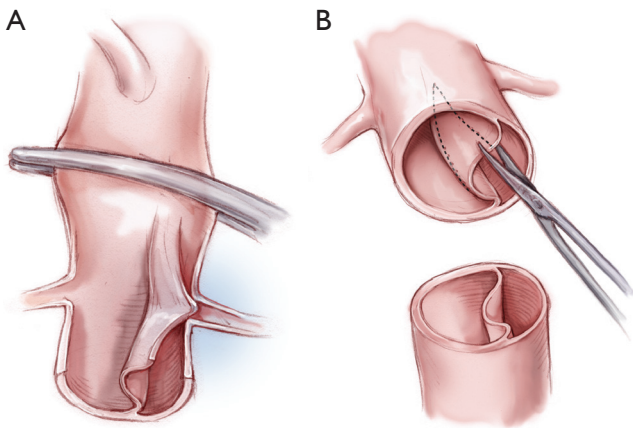


Figure 11 This represents the particular of another fenestration technique: (A) transection of the aorta; (B) septum resection.

The aorta is clamped at the suprarenal or infrarenal level and at the iliac arteries, and then opened in a crossway. After identification of the true and false lumen, the dissected flap is resected longitudinally for 2 to 3 cm, from above to just below the level of the renal arteries. The intimal flap is resected proximally in a triangular shape to maximize the single aortic lumen (*Figure 11*). The distal extent of the intimal flap is fixed to adventitia, and the aortic wall is reinforced both internally and externally with strips of Teflon (*Figure 12A*). Aortic replacement with a Dacron graft is performed in those cases with complete infrarenal aortic or iliac occlusion and/or abdominal aortic

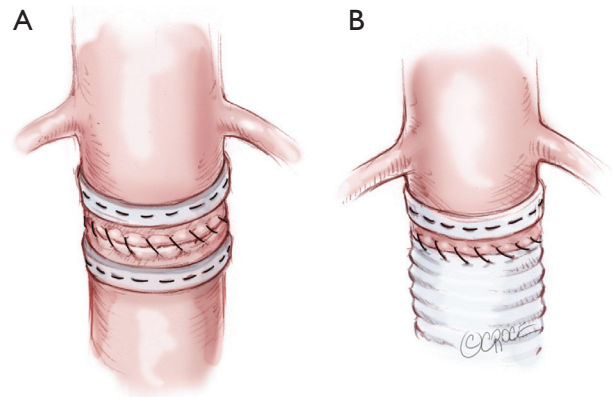


Figure 12 This represents two type of repair: (A) aortic walls sutures with two Teflon felt stripes; (B) the infrarenal tract of the aorta is also replaced with a surgical graft.

aneurysm (*Figure 12B*).

Acknowledgements

Disclosure: The authors declare no conflict of interest.

References

1. Gurin D, Bulmer JW, Derby R. Dissecting aneurysm of the aorta: diagnosis and operative relief of acute arterial obstruction due to this cause. *NY State J Med* 1935;35:1200-2.

Cite this article as: Trimarchi S, Segreti S, Grassi V, Lomazzi C, Cova M, Piffaretti G, Rampoldi V. Open fenestration for complicated acute aortic B dissection. *Ann Cardiothorac Surg* 2014;3(4):418-422. doi: 10.3978/j.issn.2225-319X.2014.07.08

Thoracoabdominal aortic aneurysm repair with a branched graft

Kim I. de la Cruz, Scott A. LeMaire, Scott A. Weldon, Joseph S. Coselli

Division of Cardiothoracic Surgery, Michael E. DeBakey Department of Surgery, Baylor College of Medicine; and Department of Cardiovascular Surgery, The Texas Heart Institute at St. Luke's Episcopal Hospital, Houston, Texas, USA

Introduction

Many aspects of open thoracoabdominal aortic aneurysm (TAAA) repair are individualized according to patient-specific factors related to the type and extent of disease, comorbid conditions, and physiological reserve. One example of how surgeons can individualize the technical approach to this operation is the use of a prefabricated aortic graft with four side branches designed for reattaching the celiac axis, superior mesenteric artery (SMA), and both renal arteries (1-4). Using this branched graft in TAAA repairs is ideal when one of two conditions are met: (I) The patient has a connective tissue disorder (e.g., Marfan syndrome, Loeys-Dietz syndrome), and aortic tissue that remains after the procedure will be prone to aneurysmal dilatation, pseudoaneurysm formation, and rupture, eventually necessitating reintervention (5-7); or (II) the origins of the patient's visceral vessels are far enough apart that an island patch reimplantation is not desirable.

The ultimate goal of these operations is to balance the need to resect and replace as much diseased aortic tissue as possible with the need to protect the spinal cord and other organs and, thereby, prevent postoperative complications. Our strategies for organ protection have been described in detail elsewhere (8-14). To protect the spinal cord, we employ mild passive hypothermia, cerebrospinal fluid (CSF) drainage, left heart bypass (LHB), sequential cross-clamping, and selective reimplantation of intercostal or lumbar arteries (9-11,14). The renal arteries are perfused with cold crystalloid solution to protect the kidneys from ischemic damage (8,12,13). Perfusing the celiac axis and the SMA with isothermic blood from the LHB circuit minimizes the duration of abdominal-organ ischemia.

Operative techniques

Preoperative planning

The patient's history and physical examination findings are thoroughly reviewed, along with pertinent findings from

the preoperative evaluation. The patient's age, history of tobacco use, ejection fraction, pulmonary function, and kidney function, as well as the status of the carotid and coronary arteries, all factor into intraoperative decisions regarding patient management and surgical technique (10,14). The patient's computed tomographic angiography scans are reviewed to plan various technical aspects of the procedure. The scans are checked for relevant anatomic variants, such as a retroaortic left renal vein. The diameter of the aorta in its nonaneurysmal portions—often just distal to the left subclavian for the proximal anastomotic site and at the aortic bifurcation for the distal anastomotic site—provides an idea as to the size of the Dacron graft that will be needed. Potential clamping and cannulation sites are evaluated. For example, the planned aortic cannulation site for LHB should be in a region that is free from extensive mural thrombus. The spatial relationships between the celiac, SMA, and renal arteries are assessed. When the origins of the branch arteries are substantially displaced away from one another, using a branched graft will enable their reattachment without leaving behind a large patch of aortic tissue (5). In patients with aortic dissection, the configuration of the dissecting membrane and the relationships between the true lumen, false lumen, and branch arteries are evaluated. Furthermore, areas of stenosis at the origins of the visceral and renal arteries are identified because they may need endarterectomy, stenting, or both (15). Although the final decision with regard to any of the aforementioned technical considerations is made intraoperatively on the basis of operative anatomy, it is very useful to have considered these details in advance.

To illustrate the use of a branched graft, we will describe in detail the procedure for performing a Crawford extent II TAAA repair. A typical patient undergoing an extent II repair has an aneurysm extending from the left subclavian artery down to the aortic bifurcation (*Figure 1*). In this particular case, there is a neck of proximal descending aorta distal to the left subclavian artery that can be clamped. Note also that the celiac axis, SMA, and right and left

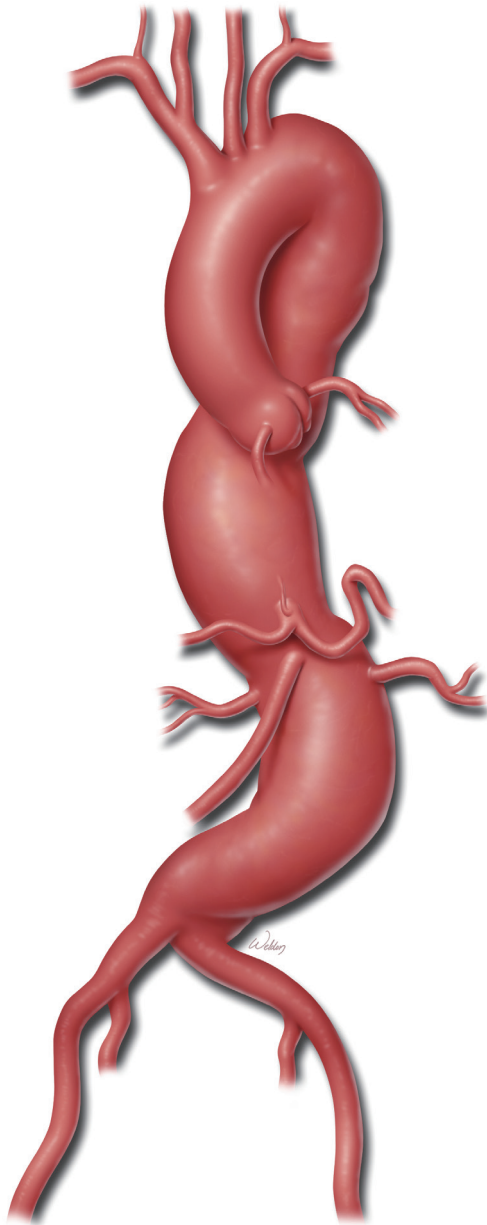


Figure 1 Preoperative anatomy: a typical patient undergoing a Crawford extent II thoracoabdominal aortic aneurysm repair will have an aneurysm extending from the left subclavian artery down to the aortic bifurcation. Note that in this case, the celiac axis, superior mesenteric artery, and right and left renal arteries are displaced away from each other, making their reattachment as a single patch undesirable.

renal arteries are spread relatively far apart along the circumference of the aneurysmal aorta.

Anesthesia considerations and patient positioning

The patient is placed supine on top of a beanbag on the operating table. Both arms are placed on arm boards on either side of the table. A right radial or brachial arterial line is placed by the anesthesiologist. A large-bore peripheral intravenous line is likewise placed at this time. After intravenous sedative and muscle relaxant are administered, the patient is intubated with a double-lumen endobronchial tube for later single right-lung ventilation, and general anesthesia is induced.

The patient is placed in a right lateral decubitus position with both hips and knees flexed for spinal drain placement by the anesthesiologist. An axillary roll is placed between the bed and the patient, just under the right axilla. The spinal drain is placed at the L3-4, L4-5, or L5-S1 level. The CSF pressure is maintained at less than 10 mmHg, but the amount drained is limited to no more than 10 mL/hour. The spinal drain is secured with tape to the right side of the patient's back, and the patient is repositioned such that the upper body is at a 60-degree angle and the hips are at a 30-degree angle to the horizontal. This allows for access to both groins in case there is a need for access to the femoral arteries. The beanbag is suction-deflated and made firm against the patient's body to keep the patient properly positioned. The patient's left arm is placed on top of an elevated arm board and held at an angle above the shoulders in a freestyle swimming stroke position (*Figure 2*). The correct position of the double-lumen endobronchial tube is confirmed with a flexible bronchoscope after final positioning. The patient's left chest and back, abdomen, groins, and upper thighs are prepared and draped in a sterile fashion. An adhesive antimicrobial drape is placed over all exposed skin. Prophylactic broad-spectrum intravenous antibiotics are given within 1 hour of skin incision. The patient's mean arterial pressure (MAP) is maintained in the range of 70 to 90 mmHg throughout the case.

Incision and aortic exposure

A sigmoid-shaped skin incision is made from just posterior

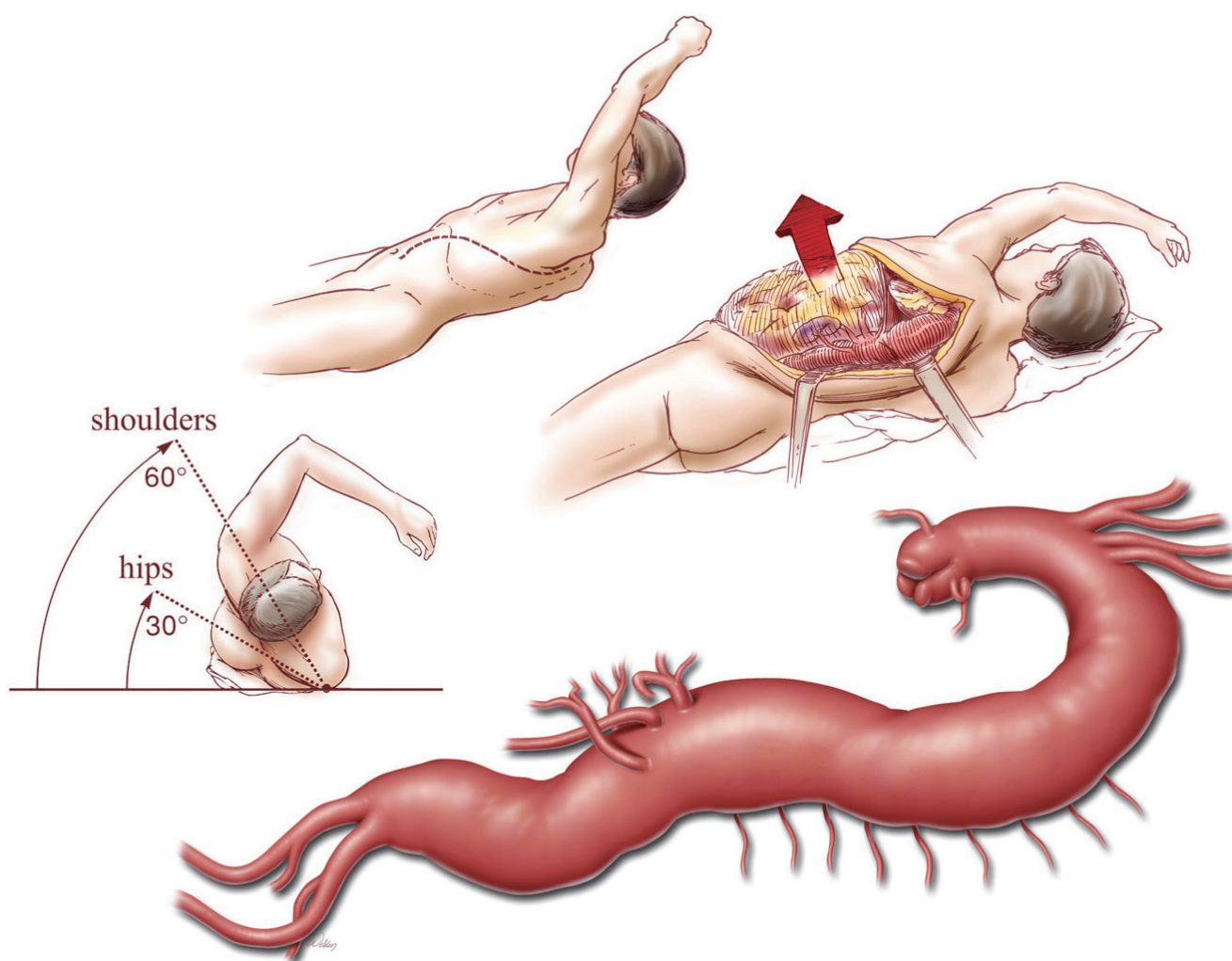


Figure 2 Incision and exposure: the patient is positioned such that the upper body is at 60 degrees from horizontal and the hips are at 30 degrees from horizontal. A sigmoid-shaped skin incision is made from behind the left scapula, along the 7th rib, across the costal margin, and toward the left periumbilical region. The chest is entered through the 6th intercostal space. Left medial visceral rotation and circumferential division of the diaphragm enable exposure of the entire thoracoabdominal aorta. The use of table-mounted self-retaining retractors maintains stable exposure throughout the procedure.

to the inferior aspect of the left scapula, curving along the 7th rib and across the costal margin toward a point about an inch to the left of the umbilicus. To avoid creating areas of skin necrosis, gentle curves are followed instead of sharp angles when the incision is made. When a repair will involve the iliac arteries, the incision may be extended inferiorly around the umbilicus and into the midline to just above the pubic symphysis.

The latissimus dorsi is divided, followed by the serratus anterior, to provide entry into the plane of the rib cage. Ribs

may be counted downward from the apex or upward from the lower ribs to confirm appropriate interspace entry into the left pleural cavity. For most extent II thoracoabdominal repairs, the 6th intercostal space is the best entry point; the 5th intercostal space is occasionally used, such as when there is an especially large aneurysm involving the distal aortic arch and proximal descending thoracic aorta. The anesthesiologist is asked to render the left lung atelectatic at this point and to commence single right-lung ventilation. Then, the intercostal muscle is detached from the rib below

the space chosen, and this incision is carried posteromedially toward the spine and anteriorly to the costal margin. The costal margin is divided, and a portion of it is resected to prevent overlap during reapproximation of the separated ribs at the end of the case. A short posterior segment of the rib may be resected to gain additional exposure.

The diaphragm is divided at the costal margin to expose the peritoneum. A fold of the peritoneum is palpated to make sure that the stomach, transverse colon, and liver are not adherent; the peritoneum is then carefully opened. The abdominal portion of the thoracoabdominal incision is then opened under direct vision to avoid inadvertent injury to intra-abdominal organs. Left medial visceral rotation is then carried out by entering the avascular plane along the line of Toldt. Retroperitoneal fibro-fatty tissues are separated from the inferior portion of the left hemidiaphragm and the anterior aspect of the left psoas muscle. Care is taken to identify and preserve the left ureter and gonadal vein. If a retroaortic left renal vein is present, it is preserved when possible; however, during extent II repairs, it is often necessary to divide the vein and later reconstruct it with an interposition graft. The left hemidiaphragm is divided circumferentially, leaving a 3- to 4-cm rim attached to the rib cage, from the left costal margin to the left crus. Retraction sutures are placed along the edge of the divided diaphragm on the cardiac side. The intra-abdominal aorta is exposed by using electrocautery to divide the retroaortic fibro-fatty tissues between the jaws of a right-angle clamp. The left renal artery and the aortic bifurcation are exposed.

A large Richardson retractor, together with an upper hand retractor, is secured to the table-mounted ether screen to hold the upper rib cage open, and a table-mounted self-retaining retractor with bladder blades pulls the lower ribs posteriorly and to the left. This provides generous exposure for the repair (*Figure 2*). The proximal and distal clamp sites are developed by using low-voltage electrocautery and a pair of long Metzenbaum scissors. Care is taken to identify and preserve the left recurrent laryngeal nerve and the left phrenic nerve. Sometimes, the ligamentum arteriosum must be divided to improve mobilization around the proximal descending thoracic aorta and distal transverse aortic arch. This maneuver is particularly useful when the proximal clamp site needs to be positioned on the aortic arch, between the left common carotid and left subclavian arteries. The distal clamp site is positioned at the level of the left pulmonary hilum. It is important to stay anterior to the hemiazygos vein and intercostal veins, and it may be necessary to ligate some intercostal arteries at the clamp site

with medium-sized clips. Likewise, the adjacent esophagus is identified and dissected away from the aortic clamp site.

Cannulation and perfusion setup

Either the superior or the inferior left pulmonary vein can be used as an atrial cannulation site for LHB (9). The left lung is retracted posterolaterally with a moist laparotomy pad and a deep Deaver retractor. The pericardium is opened near the pulmonary veins, away from the phrenic nerve. A 3-0 pledgeted polypropylene suture is placed in the origin of the vein in a mattress fashion. At the aortic cannulation site, a purse-string suture is placed in the same manner whether the site is in the distal descending thoracic aorta or the proximal abdominal aorta (i.e., proximal to the left renal artery origin).

Heparin is administered intravenously at a dose of 1 mg/kg. A 24-French angled-tip cannula is placed in the left atrium via a pulmonary venotomy, secured with the previously placed purse-string suture and a Rummel tourniquet, and connected to the drainage line of the LHB circuit. This cannula is secured to the patient's skin with a towel clip placed in the left subcostal area. A 20-French angled-tip cannula is placed in the distal aorta and connected to the inflow line of the LHB circuit (*Figure 3*). This cannula is secured to the patient's skin with a towel clip placed near the umbilicus. The inflow line of the LHB circuit has a Y-connector attached that splits pump return between the line going to the distal aortic cannula and another line leading to two 9-French Pruitt balloon-tipped perfusion catheters for later delivery of selective visceral perfusion to the celiac artery and SMA (*Figure 3*). This selective visceral perfusion line remains clamped while distal aortic perfusion is being provided. A separate cold crystalloid renal perfusion circuit is set up with another two 9-French Pruitt balloon-tipped perfusion catheters attached to the end of its line for later administration of 4 °C lactated Ringer's solution with mannitol (12.5 gm/L) and methylprednisolone (125 mg/L) to the renal arteries (*Figure 3*) (8,12,13).

Aortic reconstruction

After LHB is initiated at a flow rate of 500 mL/min, a straight, padded aortic cross-clamp is applied just distal to the left subclavian artery. This clamp is secured with a towel clip to the skin of the upper chest on the superior side of the incision. The proximal descending thoracic

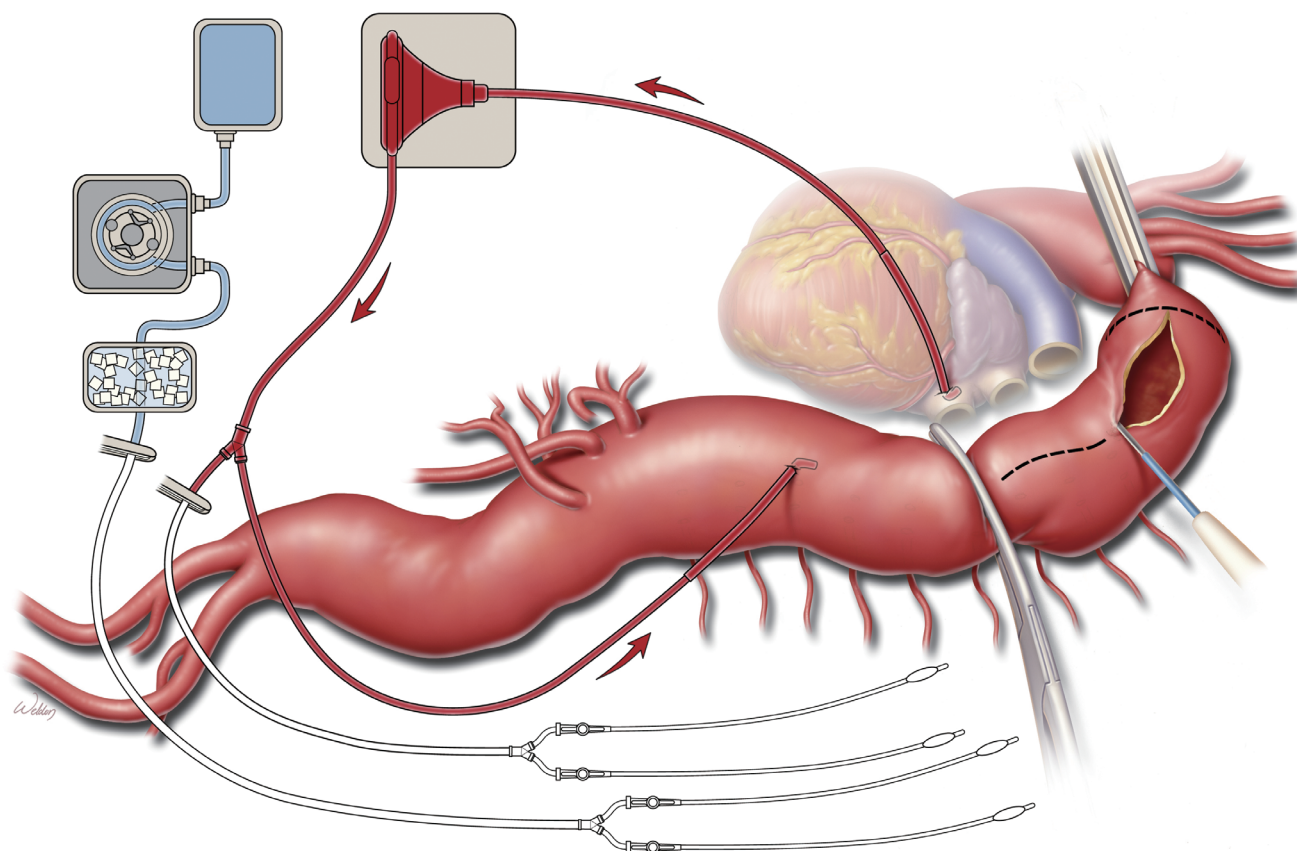


Figure 3 Left heart bypass, placement of aortic clamps, and opening the proximal descending thoracic aorta: a cannula is placed in the left atrium via left inferior pulmonary venotomy and connected to the drainage line of the left heart bypass circuit. Another cannula is placed in the distal descending thoracic aorta and connected to the inflow line of the circuit. A Y-line from the inflow tubing is connected to two balloon perfusion catheters; these are used to provide selective perfusion to the celiac and superior mesenteric arteries later during the repair. A separate cold renal perfusion system is set up to enable intermittent administration of 4 °C lactated Ringer's solution to the renal arteries through two balloon perfusion catheters. After left heart bypass flow is initiated, the proximal aortic clamp is placed just distal to the left subclavian artery, and the distal aortic clamp is applied across the mid-descending thoracic aorta. The aortic segment between the two clamps is opened longitudinally by using electrocautery.

aorta is compressed manually with a laparotomy pad to displace blood distally; then a Crafoord clamp is applied across the aorta at the junction of the upper and middle thirds of the descending thoracic aorta (*Figure 3*). If the aortic segment between the two clamps remains highly pressurized, this may indicate that the proximal clamp has not been applied all the way across; the proximal clamp may have to be reapplied or a second clamp may have to be placed to achieve proximal control.

After the aorta is clamped, LHB flow is increased toward a target between 1.5 and 2.5 L/min to keep the

patient's MAP around 80 mmHg. The aortic segment between the two clamps is then opened longitudinally by using electrocautery, and its edges are retracted laterally with 0 silk stay sutures. Shed blood is collected by a cell-saver system for filter processing, and the washed red cells are collected and auto-transfused back into the patient. In cases involving aortic dissection, the dissecting membrane is excised. Brisk back-bleeding from intercostal arteries is controlled with 2-0 silk suture ligatures placed in a figure-of-eight fashion; this minimizes blood loss, improves visualization, and prevents shunting of blood away from the

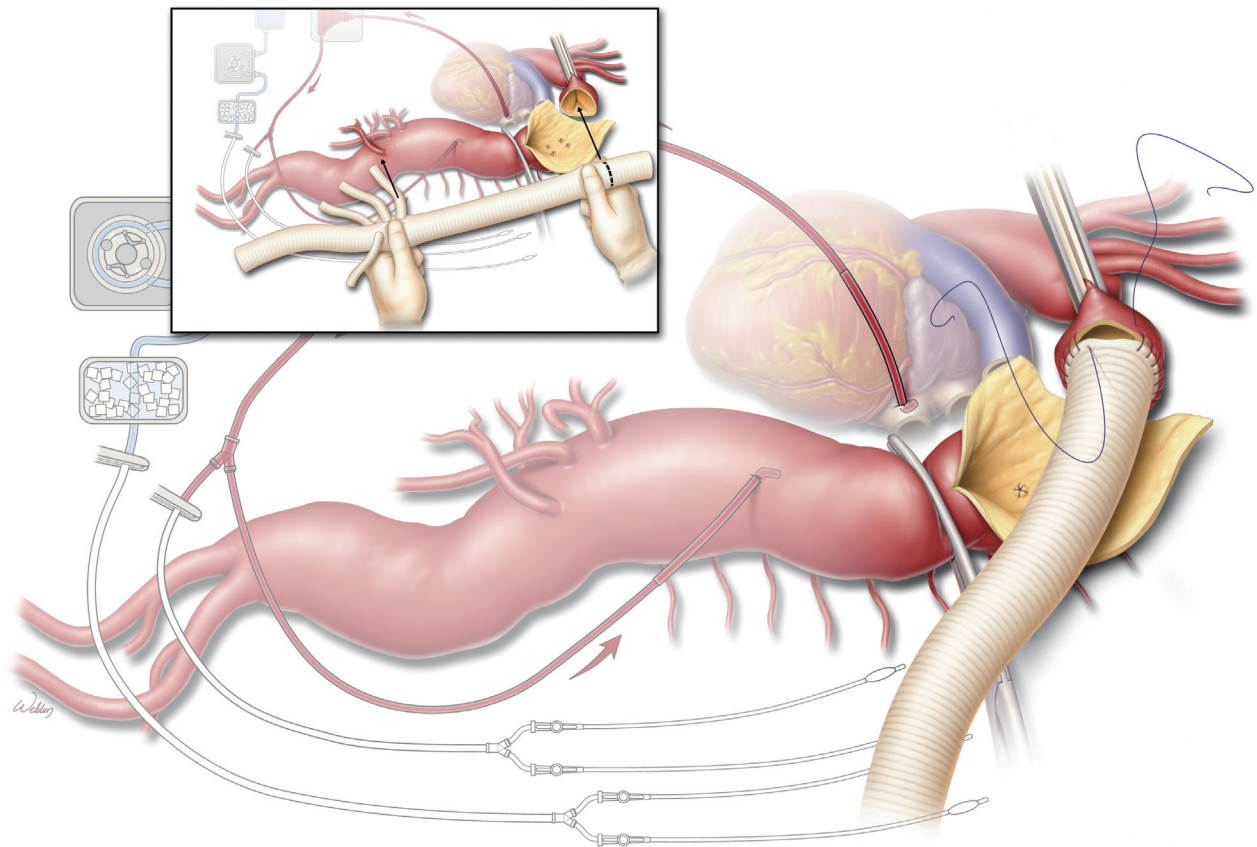


Figure 4 Tailoring the graft and constructing the proximal anastomosis: after back-bleeding intercostal arteries are ligated, the aorta is transected 2 to 3 cm distal to the aortic clamp and separated from the underlying esophagus. A four-branched aortic graft is tailored by stretching the graft so that it is taut, lining up the origin of the celiac graft with the origin of the left renal artery, and cutting the proximal end of the aortic graft at the point where it reaches the proximal anastomosis site (inset). This ensures that the origin of each branch graft is positioned slightly inferior to the origin of its paired artery, and thereby facilitates the formation of gentle curves in the branch grafts that help prevent the grafts from becoming kinked. The anastomosis between the aortic graft and the proximal aortic cuff is sewn.

spinal circulation. A cuff of proximal descending thoracic aorta about 2-3 centimeters distal to the proximal aortic clamp is cut transversely and carefully separated from the underlying esophagus by using electrocautery; this important step prevents the incorporation of the esophagus into the suture line when the proximal anastomosis is sewn.

The size of the four-branched aortic graft is chosen partially on the basis of the aortic diameters measured at the planned proximal and distal anastomosis sites on preoperative imaging, but the choice is largely based on visual inspection of the aorta intraoperatively. Usually, a 24-, 26-, or 28-mm graft is used. The four branch grafts arise from the distal third of the main body of the graft, and they include two anteriorly-placed 10-mm branches

that are about 1 cm apart (corresponding to the celiac axis and the SMA) and two 8-mm side branches placed about 1 cm distal to the second 10-mm branch on either side of the graft (corresponding to the renal arteries). The proximal end of the aortic graft is trimmed to the appropriate length to match the distance from the proximal anastomotic site to the location of the visceral arteries distally (*inset, Figure 4*). Ideally, the origin of each branch graft is positioned slightly inferior to the origin of its paired artery. This facilitates the formation of gentle curves in the branch grafts that help prevent them from becoming kinked. This positioning can be rapidly achieved by stretching the graft so that it is taut, lining up the origin of the celiac graft with the origin of the left renal artery, and cutting the proximal end of the aortic graft at the point where

it reaches the proximal anastomosis site.

The anastomosis between the aortic graft and the proximal aortic cuff is sewn in an end-to-end configuration with a continuous 3-0 or 4-0 polypropylene suture (*Figure 4*). Although 3-0 suture is used in most cases, 4-0 suture is preferred when the aortic tissue is extremely fragile (e.g., in some patients with Marfan syndrome). The suture line is often reinforced with a circumferential layer of pledgeted 3-0 or 4-0 polypropylene sutures in an interrupted mattress fashion. After the proximal anastomosis is completed, the proximal aortic clamp is left in place if it is positioned distal to the left subclavian artery. However, if the clamp had been placed proximal to the left subclavian artery, the patient is placed in Trendelenburg position and the clamp on the left subclavian artery is removed to de-air the proximal portion of the graft; the aortic clamp is then moved onto the graft to restore blood flow to the left subclavian artery.

Left heart bypass is stopped at this point, and the tubing going to the distal aortic cannula is clamped. Simultaneously, the distal aortic clamp is removed and the aorta is opened longitudinally down to the aortic bifurcation; care is taken to cut posterior to the origin of the left renal artery. Once again, 0 silk retraction sutures are applied to both edges of the opened aorta along its length to provide wide exposure of the lumen. Shed blood continues to be collected with the cell-saving system. In cases of aortic dissection, the exposed dissecting membrane is excised. Briskly back-bleeding intercostal and lumbar arteries are suture ligated in a figure-of-eight fashion with 2-0 silk sutures to prevent shunting of blood away from the spinal circulation. A briskly back-bleeding inferior mesenteric artery may likewise be ligated at this point. The origins of the visceral arteries off of the aneurysmal native aorta are identified and inspected for significant stenosis, calcification, or dissection. Such lesions can be managed by performing an endarterectomy, fenestrating a dissecting membrane, or placing uncovered balloon-expandable stents (6- or 7-mm diameter, 14- or 15-mm length) (15). The celiac artery and SMA are cannulated with the 9-French Pruitt visceral perfusion catheters connected to the inflow line of the LHB circuit, and selective perfusion is delivered at a flow rate of approximately 200 mL/min. The renal arteries are likewise cannulated with the 9-French Pruitt catheters, and boluses of the cold crystalloid solution are administered every 6 to 10 min at volumes generally ranging between 200 and 400 mL (*Figure 5*) (8,12,13). Nasopharyngeal temperature is monitored closely; the temperature usually drifts down into the range of 32 to 34 °C. To avoid hypothermia-

induced arrhythmias, additional boluses of cold crystalloid renal perfusion are not administered if the nasopharyngeal temperature is at or below 32 °C.

The remaining patent intercostal and lumbar arteries are carefully inspected, particularly between T7 and L1; those that are large and have little back-bleeding are chosen for reimplantation. An opening in the side of the graft is cut to size, and a side-to-side anastomosis is created with continuous 3-0 or 4-0 polypropylene suture (*Figure 5*). The anastomosis is constructed in a manner that minimizes the amount of aortic tissue within the reattached patch. Fragile areas within the anastomosis are selectively reinforced with 3-0 or 4-0 pledgeted polypropylene sutures in a mattress fashion.

After the patch reimplantation of the intercostal arteries is completed, whenever possible, the proximal aortic cross-clamp is moved down the aortic graft to a position immediately distal to the intercostal patch (*Figure 6*). This allows for reperfusion of the reimplanted intercostal arteries as part of the spinal protection strategy known as sequential cross-clamping. The distal end of the aortic graft is trimmed to the appropriate length, and the distal anastomosis is performed in an end-to-end configuration with a continuous 2-0, 3-0, or 4-0 polypropylene suture (depending on the quality of the tissue) (*Figure 6*). The circumference of the distal anastomosis is selectively reinforced with pledgeted 3-0 polypropylene sutures in an interrupted mattress fashion.

The aortic graft and its four branches are allowed to fill with blood from the distal anastomosis. Hemostat clamps are placed across each branch of the graft; then the patient is placed in Trendelenburg position, and the aortic cross-clamp is slowly removed to reestablish blood flow to the pelvis and both lower extremities (*Figure 7*). The graft is de-aired by briefly releasing the hemostat clamp from the left-sided 8-mm side branch and then punching tiny holes through the graft with a small-gauge needle.

The right renal artery anastomosis is done next because of its medial location and because it is important to reestablish blood flow to one of the kidneys as soon as possible to reduce renal ischemic time. After the right renal artery perfusion catheter is removed, the right-sided 8-mm side branch is trimmed to the appropriate length and anastomosed in an end-to-end configuration with a continuous 5-0 polypropylene suture (*Figure 7*). After the graft is de-aired, the anastomosis is finished and the hemostat clamp released. Reinforcing mattress stitches are placed where needed with pledgeted 4-0 polypropylene suture.

Next, the more inferior of the two anteriorly-placed

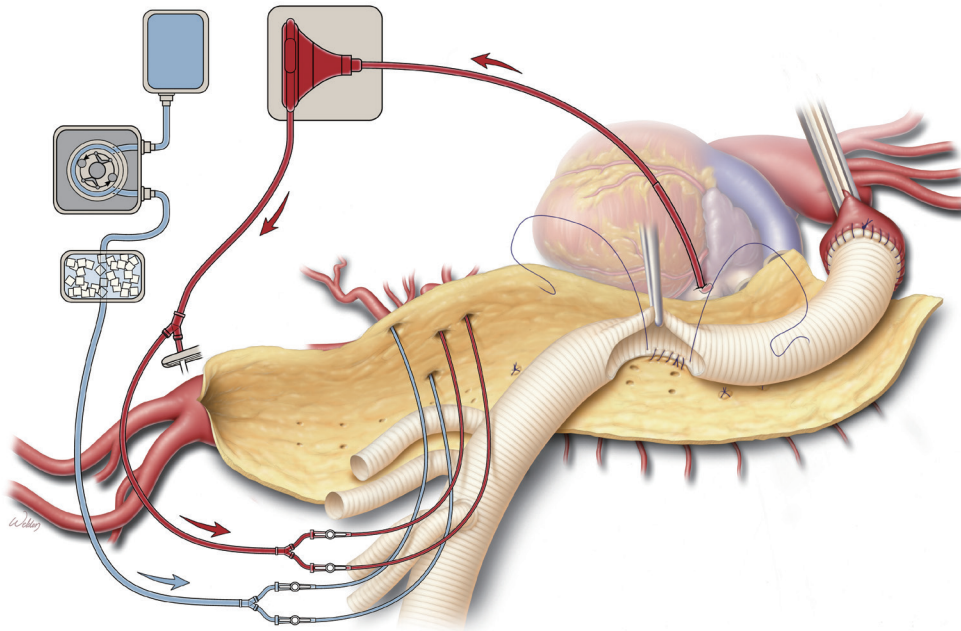


Figure 5 Visceral perfusion and the intercostal patch anastomosis: after the proximal anastomosis is completed, left heart bypass is stopped, the distal aortic clamp and cannula are removed, and the aorta is opened longitudinally down to the aortic bifurcation. Briskly back-bleeding intercostal and lumbar arteries are suture ligated. The celiac and superior mesenteric arteries are cannulated with balloon perfusion catheters, and selective perfusion is initiated. The renal arteries are likewise cannulated with balloon perfusion catheters to enable intermittent perfusion with cold crystalloid solution. Two pairs of intercostal arteries have been selected for reattachment; these are sutured to an opening in the side of the graft.

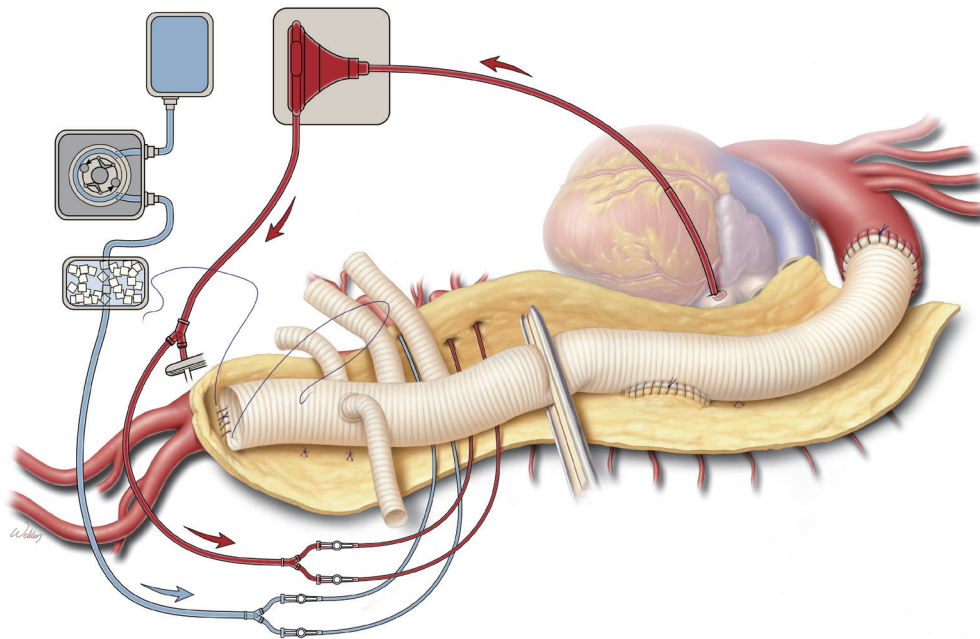


Figure 6 Distal anastomosis: after the patch reimplantation of the intercostal arteries, the aortic cross-clamp is moved down to the aortic graft distal to the intercostal patch, thereby allowing reperfusion of the reimplanted intercostal arteries. The distal end of the aortic graft is trimmed to the appropriate length, and the distal anastomosis is performed.

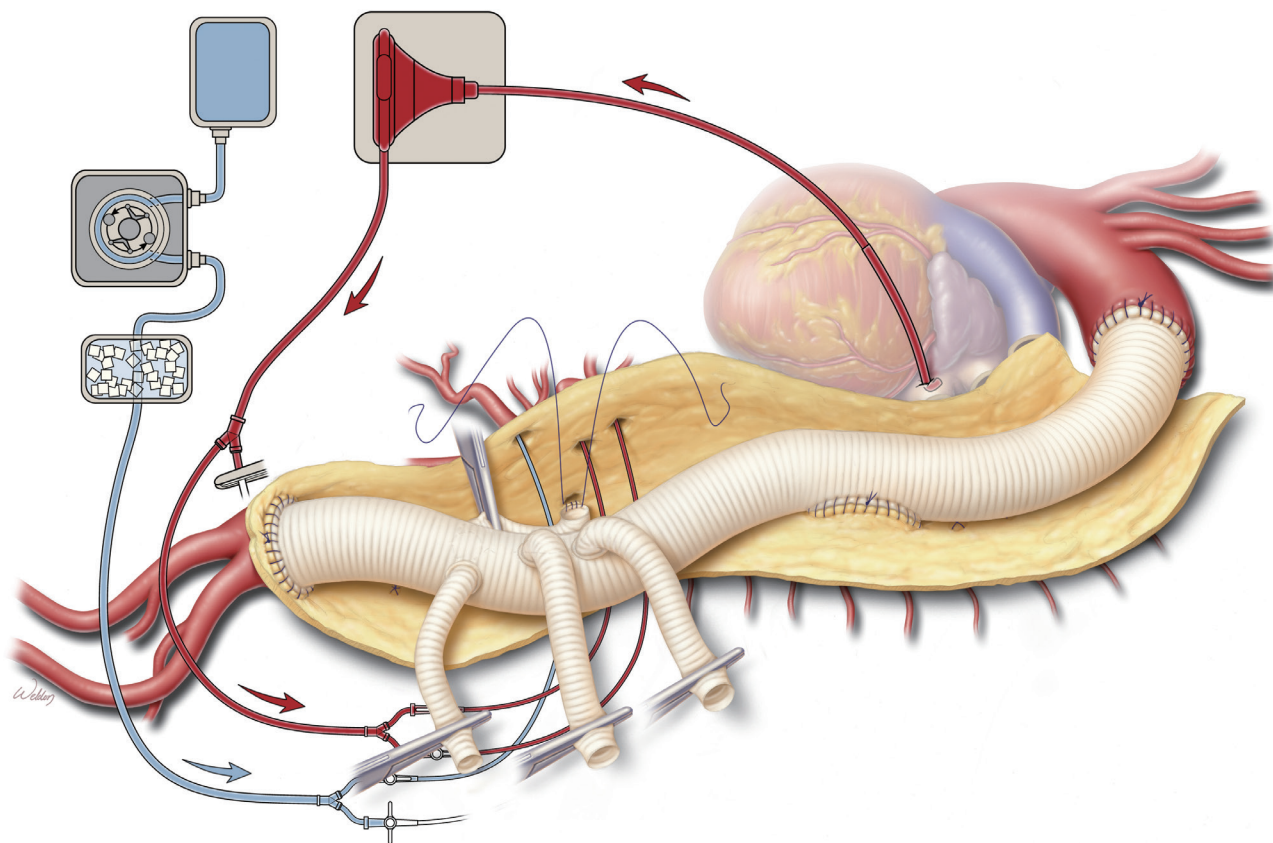


Figure 7 Right renal artery anastomosis: after the four branch grafts are clamped, the aortic clamp is removed so that flow is restored to the iliac arteries. The right-sided 8-mm branch graft is trimmed to the appropriate length and anastomosed to the origin of the right renal artery.

10-mm branches is cut to the appropriate length and anastomosed in an end-to-end configuration to the SMA with a continuous 5-0 polypropylene suture (*Figure 8*). To facilitate this anastomosis, the selective perfusion catheter to the SMA is removed and selective flow to the celiac axis is discontinued; this enhances visualization of the anastomosis by preventing visceral back-bleeding through the SMA. Before the anastomosis is completed, the branch graft is briefly de-aired. Anastomotic bleeding is controlled with pledgeted 4-0 polypropylene mattress sutures.

A hemostat clamp is then reapplied across the branch graft to the SMA to prevent back-bleeding from interfering with the celiac anastomosis. The celiac perfusion catheter is removed, and the uppermost 10-mm branch graft is trimmed to the appropriate length and then sewn to the origin of the celiac axis in an end-to-end configuration with a continuous 5-0 polypropylene suture (*Figure 9*). Before the celiac anastomosis is completed, the hemostat on the

SMA graft is removed to facilitate the de-airing of the celiac graft. After the anastomosis is completed, the clamp on the celiac branch graft is released.

Often, the origin of the left renal artery is separated from the aortic wall as a button, and its proximal portion is mobilized. The remaining 8-mm side-branch graft is trimmed to the appropriate length; care is taken to ensure that the artery and the branch graft will not kink once the abdominal organs are returned to their anatomic positions. The renal perfusion catheter is removed, and like the anastomoses formed in the other bypassed vessels, the anastomosis is fashioned in an end-to-end configuration with a continuous 5-0 polypropylene suture (*Figure 10*). After the graft has been de-aired and the anastomosis completed, the clamp is removed. Protamine sulfate is administered to reverse the heparin. Indigo carmine is also administered intravenously to assess the adequacy of renal perfusion; ideally, blue dye should be visible in the urine

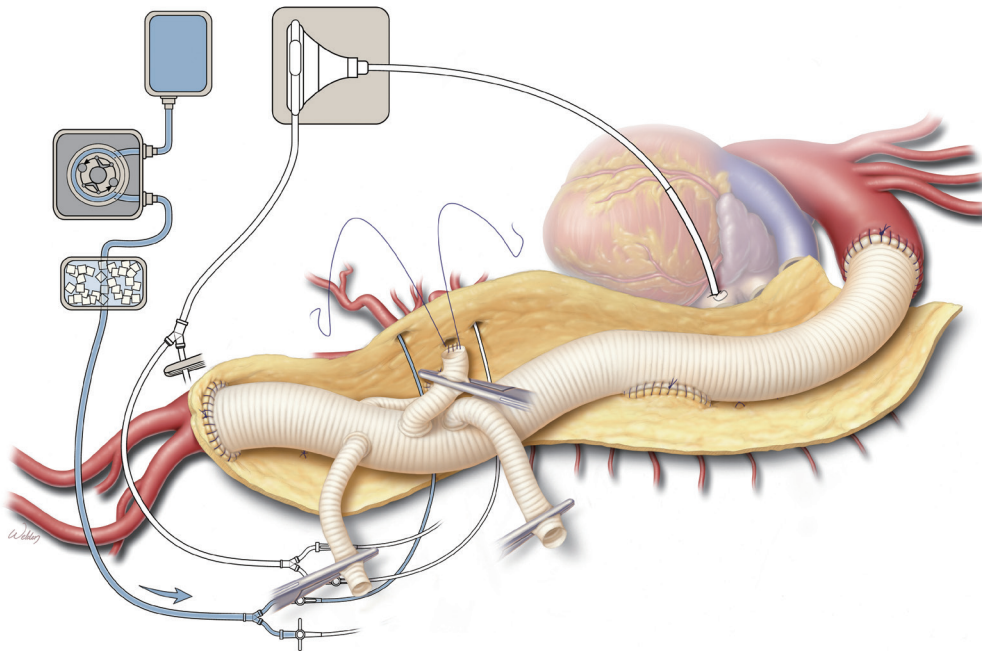


Figure 8 Superior mesenteric artery anastomosis: the inferior 10-mm branch graft is used to reattach the superior mesenteric artery. The perfusion catheter is removed from the superior mesenteric artery, and flow to the celiac axis is stopped; this prevents visceral back-bleeding from impairing visualization of the anastomosis. The branch graft is cut to appropriate length and sutured to the origin of the superior mesenteric artery.

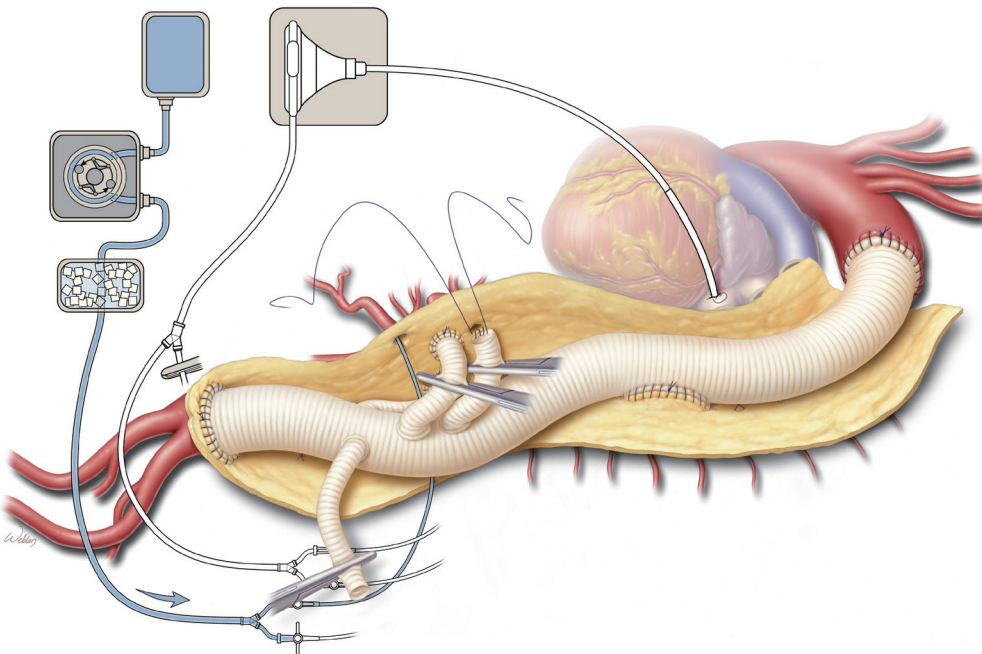


Figure 9 Celiac axis anastomosis: a hemostat clamp remains in place on the superior mesenteric artery graft to ensure a dry field during the celiac anastomosis. After the celiac axis catheter is removed, the superior 10-mm branch graft is trimmed to appropriate length and sutured to the origin of the celiac axis.

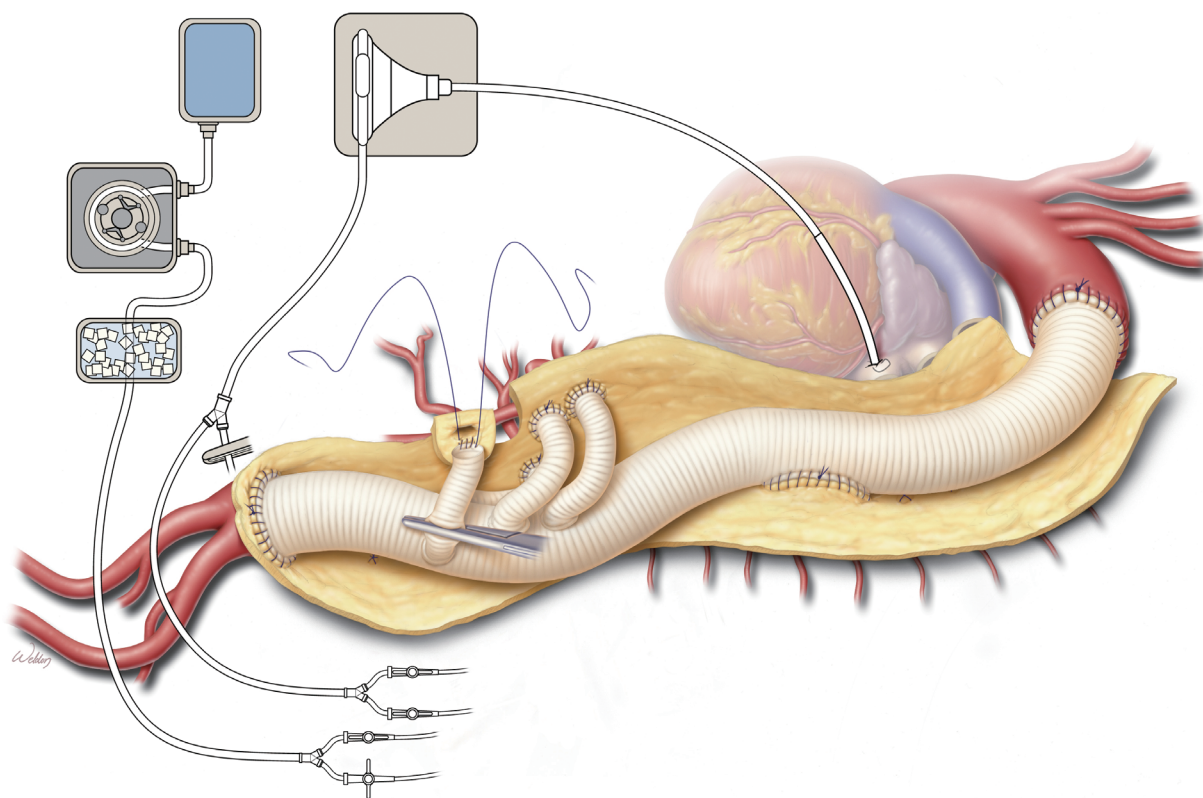


Figure 10 Left renal artery mobilization and anastomosis: the origin of the left renal artery is separated from the aortic wall as a button, and its proximal portion is mobilized. The remaining 8-mm branch graft is cut to appropriate length—with care taken to ensure that the graft will not kink once the abdominal organs are returned to their anatomic positions—and sewn to the left renal artery in an end-to-end configuration.

within 20 minutes.

Hemostasis and closure

All anastomoses and suture ligatures are checked for bleeding and are reinforced as needed. The left lung is retracted posteriorly by using a moist laparotomy pad and a deep Deaver retractor. The atrial cannula is removed, and the purse string suture in the pulmonary vein is tied. This cannulation site closure is reinforced with a pledgeted 3-0 polypropylene suture. After protamine has been given and surgical hemostasis has been secured, blood products are transfused as necessary to reverse any coagulopathy. The cut edges of the opened native aorta are cauterized. The completed repair is inspected to make sure that the main graft and its branches lie properly without kinking (*Figure 11*). The left renal artery, proper hepatic artery, and intestinal arterial branches are palpated to check for

pulses and ensure adequate blood flow. The kidneys are palpated for turgor, the bowel is visualized to confirm that it is well perfused, and the spleen is inspected to ensure that it has not been injured.

The field is irrigated with warm water to halt the cooling trend. A 19-French closed-suction abdominal drain is placed in the upper left retroperitoneal space. The left hemidiaphragm is reapproximated up to the costal margin with a continuous #1 polypropylene suture. The retractors are removed at this point. Two straight 36-French chest tubes are placed in an anteroapical and posterobasal position within the left chest cavity. Five #2 braided absorbable pericostal sutures are placed around the 6th and 7th ribs in a figure-of-eight fashion. Two #7 surgical steel wires are also placed around the ribs in a figure-of-eight fashion, one in the middle portion of the thoracotomy and one near the costal margin. The wires are twisted, cut, and buried, and the pericostal sutures are tied, which reapproximates the 6th

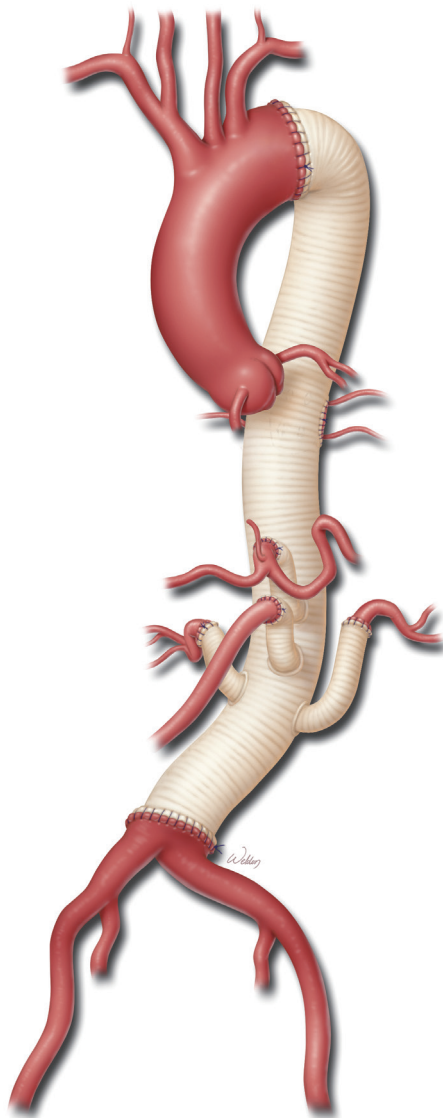


Figure 11 Completed repair: the use of the branched graft essentially eliminates residual aortic tissue in the visceral segment, thereby preventing future visceral patch aneurysm formation.

and 7th ribs. The chest tubes are connected to a standard evacuation container that is connected to -20 cmH₂O continuous suction. The abdominal fascia is closed with another continuous #1 polypropylene suture; this suture is carried to the left costal margin and tied to the suture from the diaphragm, which is tightened to ensure that there are no defects in the diaphragm closure. Both lungs are ventilated at this point. Two pericostal analgesia catheters are placed along the thoracotomy incision. The serratus anterior and

latissimus dorsi muscles are reapproximated with separate #1 polypropylene sutures. The abdominal drain is connected to bulb suction. The wound is irrigated with antibiotic solution. The subdermal layer is reapproximated with continuous 2-0 absorbable monofilament suture, and the skin is closed with staples. Betadine ointment and then a sterile dressing are applied to the wound. Quarter-percent ropivacaine is administered via a timed-release reservoir connected to the pericostal analgesia catheters.

Comments

The use of the four-branched graft in TAAA repairs has been adopted by several groups (1-4). The potential disadvantages of using this approach are primarily related to the greater number of anastomoses involved in the four-branch technique than in the traditional patch reattachment approach; collectively, the four branch anastomoses may take longer to complete than a single patch anastomosis, thus prolonging abdominal organ ischemic times. Additionally, to avoid postoperative organ ischemia due to graft kinking, the branch grafts need to be situated with proper length and orientation. Importantly, branch graft patency is 98% at 5 years, and the incidence of subsequent reoperation on the visceral segment of the aorta or its branches is essentially nil (4).

The abovementioned concerns appear to be offset by several key advantages that the branched graft technique provides (8,12,13). Most notably, it affords a durable repair in patients with connective tissue disease by minimizing the amount of residual native aorta in the visceral segment, thereby preventing the future development of patch aneurysm. The branched graft also provides an alternate repair option in patients whose visceral and renal arteries are far enough apart to make a patch reimplantation undesirable. In addition, the branched graft can be very useful in reoperations on patients who have developed a visceral patch aneurysm after previous TAAA surgery. Furthermore, by facilitating construction of the distal anastomosis before the visceral and renal anastomoses, using the branched graft enables earlier reperfusion of the iliac circulation, which provides important collateral blood flow to the spinal cord. The prefabricated branched graft also provides the advantage of flexibility, because it can be adapted to different anatomic needs. Additionally, the sequence of grafting can be varied according to the size, patency, and location of the visceral arteries. The surgeon can decide the order

in which the anastomoses will be performed, allowing for earlier reperfusion of the kidneys and other organs as needed. Moreover, the technique allows for the creation of tension-free anastomoses, preventing early bleeding problems. Using the prefabricated graft further reduces the potential for bleeding by eliminating the anastomoses that would be necessary if separate grafts for the branch arteries were individually sutured to a standard aortic graft intraoperatively. Finally, in cases of visceral arterial occlusive disease, the stenotic ostial portion of the visceral branches can be addressed by transecting the vessel beyond the stenosis. This avoids the need for vessel endarterectomy or the placement of branch-vessel stents.

Acknowledgements

The authors thank Stephen N. Palmer, PhD, ELS, and Susan Y. Green, MPH, for editorial support. Figures used with the permission of Baylor College of Medicine.

Disclosure: Dr. Coselli serves as a consultant for Vasutek Ltd., a subsidiary of Terumo Corporation, and receives royalties related to Vasutek® Gelweave™ Coselli thoracoabdominal grafts.

References

- De Rango P, Estrera AL, Miller C 3rd, et al. Operative outcomes using a side-branched thoracoabdominal aortic graft (STAG) for thoraco-abdominal aortic repair. *Eur J Vasc Endovasc Surg* 2011;41:41-7.
- Kokotsakis J, Lazopoulos G, Ashrafian H, et al. Thoracoabdominal aneurysm repair using a four-branched thoracoabdominal graft: a case series. *Cases J* 2009;2:7144.
- Kouchoukos NT, Masetti P, Castner CF. Use of presewn multiple branched graft in thoracoabdominal aortic aneurysm repair. *J Am Coll Surg* 2005;201:646-9.
- Kulik A, Castner CF, Kouchoukos NT. Patency and durability of presewn multiple branched graft for thoracoabdominal aortic aneurysm repair. *J Vasc Surg* 2010;51:1367-72.
- Dardik A, Perler BA, Roseborough GS, et al. Aneurysmal expansion of the visceral patch after thoracoabdominal aortic replacement: an argument for limiting patch size? *J Vasc Surg* 2001;34:405-9; discussion 410.
- LeMaire SA, Carter SA, Volguina IV, et al. Spectrum of aortic operations in 300 patients with confirmed or suspected Marfan syndrome. *Ann Thorac Surg* 2006;81:2063-78; discussion 2078.
- Schwill S, LeMaire SA, Green SY, et al. Endovascular repair of thoracic aortic pseudoaneurysms and patch aneurysms. *J Vasc Surg* 2010;52:1034-7.
- Bhamidipati CM, Coselli JS, LeMaire SA. Perfusion techniques for renal protection during thoracoabdominal aortic surgery. *J Extra Corpor Technol* 2012;44:P31-7.
- Coselli JS, LeMaire SA. Left heart bypass reduces paraplegia rates after thoracoabdominal aortic aneurysm repair. *Ann Thorac Surg* 1999;67:1931-4; discussion 1953-8.
- Coselli JS, LeMaire SA. Tips for successful outcomes for descending thoracic and thoracoabdominal aortic aneurysm procedures. *Semin Vasc Surg* 2008;21:13-20.
- Coselli JS, LeMaire SA, Köksoy C, et al. Cerebrospinal fluid drainage reduces paraplegia after thoracoabdominal aortic aneurysm repair: results of a randomized clinical trial. *J Vasc Surg* 2002;35:631-9.
- Köksoy C, LeMaire SA, Curling PE, et al. Renal perfusion during thoracoabdominal aortic operations: cold crystalloid is superior to normothermic blood. *Ann Thorac Surg* 2002;73:730-8.
- LeMaire SA, Jones MM, Conklin LD, et al. Randomized comparison of cold blood and cold crystalloid renal perfusion for renal protection during thoracoabdominal aortic aneurysm repair. *J Vasc Surg* 2009;49:11-9; discussion 19.
- Vaughn SB, LeMaire SA, Collard CD. Case scenario: anesthetic considerations for thoracoabdominal aortic aneurysm repair. *Anesthesiology* 2011;115:1093-102.
- LeMaire SA, Jamison AL, Carter SA, et al. Deployment of balloon expandable stents during open repair of thoracoabdominal aortic aneurysms: a new strategy for managing renal and mesenteric artery lesions. *Eur J Cardiothorac Surg* 2004;26:599-607.

Cite this article as: de la Cruz KI, LeMaire SA, Weldon SA, Coselli JS. Thoracoabdominal aortic aneurysm repair with a branched graft. *Ann Cardiothorac Surg* 2012;1(3):381-393. doi: 10.3978/j.issn.2225-319X.2012.08.05

Open reconstruction of thoracoabdominal aortic aneurysms

Yutaka Okita, Atsushi Omura, Katsuaki Yamanaka, Takeshi Inoue, Hiroya Kano, Rei Tanioka, Hitoshi Minami, Toshihito Sakamoto, Shunsuke Miyahara, Tomonori Shirasaka, Taimi Ohara, Hidekazu Nakai, Kenji Okada

Division of Cardiovascular Surgery, Department of Surgery, Kobe Graduate School of Medicine, Kobe, Japan

Introduction

The technical details of our strategy for operating on thoracoabdominal aortic aneurysms are presented below with our emphasis on the importance of reconstructing intercostal and visceral arteries to prevent postoperative paraplegia, intestinal ischemia, and renal failure.

Patients and methods

Between October 1999 and June 2012, 152 patients underwent surgery for thoracoabdominal aortic aneurysms at the Kobe University Hospital [Crawford classification type I=21 (13.8%), type II=43 (28.3%), type III=73 (48.0%), type IV=15 (9.9%)]. Mean age was 64.6±13.9 years and 115 (75.7%) patients were male. Sixty-three (41.4%) had aortic dissection, including 2 (1.3%) patients with acute type B dissection, and 17 (11.2%) had ruptured aneurysms. Eight (5.3%) patients had mycotic aneurysm, and 3 (2.0%) had aortitis. Emergent or urgent surgery was performed in 25 (16.4%) patients. Preoperative computed tomography (CT) scan or magnetic resonance (MR) angiography detected the Adamkiewicz artery in 103 (67.8%) patients. Cerebrospinal fluid drainage (CSFD) was performed in 115 (75.7%) patients and intraoperative motor evoked potentials (MEPs) were recorded in 97 (63.8%) patients. One hundred and seven (70.4%) patients had reconstruction of the intercostal arteries from T7 to L2, using the aortic patch technique in 35 patients and branched grafts in 72 patients. The mean number of reconstructed intercostal arteries was 3.1±2.5 pairs. Mild hypothermic partial cardiopulmonary bypass with tympanic temperatures between 32–34 °C was used in 105 (69.1%) patients, left heart bypass was used in 4 (2.6%), and deep hypothermic cardiopulmonary bypass with tympanic temperature <20 °C was used in 42 (27.6%).

Surgical procedure

The day prior to the operation, a CSFD catheter is inserted

in the lumbar region. On the day of surgery, both groins are incised and right common femoral vein and left common femoral artery are exposed in the supine position. Then the patient is turned into the left semi-posterolateral position with the shoulders rotated rightward 50 degrees and hips rotated 20 degrees (*Figure 1A*). A catheter for paravertebral nerve block is inserted before skin incision. The skin incision follows a rather straight line. The whole thoracoabdominal aorta is exposed through the left 5th or 6th intercostal space, and a retroperitoneal approach is undertaken. The diaphragm is excised circumferentially, leaving a 2 cm peripheral margin (*Figure 1B*). Transcranial stimulated MEPs are recorded throughout the operation. Partial cardiopulmonary bypass is initiated through a left femoral arterial cannula and a right femoral venous cannula, which is passed to the inferior caval-atrial junction (*Figure 2*). Segmental-staged aortic clamping is liberally used under partial cardiopulmonary bypass. Aortic segments containing fewer than three pairs of intercostal arteries are sequentially clamped and opened. The aorta is initially clamped proximal to the left subclavian artery and across the mid-descending thoracic aorta (*Figure 3*).

Next, the aorta is incised between the clamps and bleeding orifices from the bronchial arteries or high intercostal arteries are oversewn (*Figure 4A*). The proximal aorta is completely transected and dissected away from the surrounding esophagus, left vagus nerve, and away thoracic duct (*Figure 4B*). A 20 or 22 mm Dacron graft with 8-mm side-branches is used. This graft has 4 spatially orientated branches for the abdominal visceral arteries. The proximal anastomosis is performed using a 4-0 monofilament suture (22-mm needle) with Teflon strip reinforcement (*Figure 5A*). The edge of the Teflon strip is tightened with a compacting stitch to prevent suture hole bleeding (*Figure 5B*). The descending aorta is then clamped at the T10 level. Before opening the aorta, the left T8 and T9 intercostal arteries are exposed and clamped from outside the aorta (*Figure 6*).

Five minutes after aortic clamping and observing the

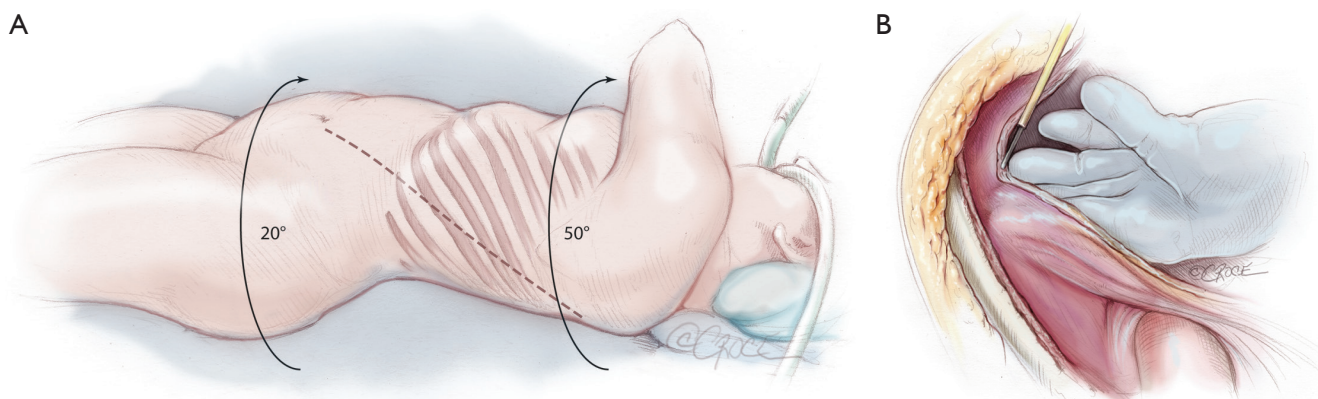


Figure 1 (A) The patient is turned into the left semi-posterolateral position with the shoulders rotated rightward 50 degrees and hips rotated 20 degrees. The skin incision follows a rather straight line. The whole thoracoabdominal aorta is exposed through the left 5th or 6th intercostal space, and a retroperitoneal approach is undertaken; (B) The diaphragm is excised circumferentially, leaving a 2 cm peripheral margin.

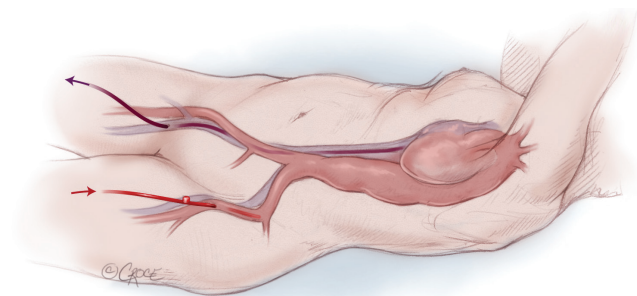


Figure 2 Partial cardiopulmonary bypass is initiated through a left femoral arterial cannula and a right femoral venous cannula, which is passed to the inferior cavo-atrial junction.

MEPs for decreased signaling, the aorta is opened. Back bleeding from the right intercostal arteries is controlled by inserting 2-Fr balloon-tipped catheters into the respective ostia (Figure 7), in order to prevent spinal cord ischemia from a steal phenomenon. Patent orifices of intercostal arteries (no more than two pairs) are then anastomosed to a side hole of the graft as an aortic patch using an inclusion technique with a 4-0 monofilament suture (17-mm needle) (Figure 8A). Another technique to reattach the intercostal arteries is through a graft interposition, where several small grafts connect to the orifices of the intercostal arteries (Figure 8B). This is followed by transposing the graft clamp distally to allow perfusion of the newly anastomosed intercostal arteries (Figure 9). Additional neighboring intercostal arteries are reconstructed and reperfused in the same fashion according to the findings of the preoperative CT angiogram.

After reconstruction of the intercostal arteries, 30 mg of Edaravone is routinely administered to prevent neurologic injury. The infra-renal portion of the abdominal aorta is then clamped and opened. The back-bleeding from lumbar arteries is controlled similarly to intercostal back-bleeding. The 4 visceral arteries are perfused using 8-Fr size balloon-tipped catheters (Fuji phycon[®], Tokyo) via a single roller pump at arterial flows of 150-200 mL/min (Figure 10). Upon completion of visceral artery cannulation, rewarming is initiated. Each visceral artery is individually dissected to make a button (Figure 11). First, the right renal artery is anastomosed to one side branch of the graft using a 4-0 monofilament suture. Then, the distal anastomosis between the graft and the aorta is performed using a 4-0 suture (22-mm needle) and reinforced with Teflon felt. After this is completed, the buttons of the celiac, superior mesenteric artery and left renal artery are anastomosed to side branches with 4-0 sutures on a 17-mm needle. The inferior mesenteric artery is often reattached directly to an opening in the graft using a 5-0 monofilament suture with a 17-mm needle. After completion of all anastomoses, the patient is weaned from cardiopulmonary bypass and hemostasis is achieved after protamine is administered (Figure 12).

Results

Nine (5.9%) patients died within 30 days [Crawford classification I =1 (4.8%), II =1 (2.3%), III =6 (8.2%), IV =1 (6.7%)], while hospital mortality occurred in 20 (13.2%) patients [Crawford extent I =3 (14.3%), II =2 (4.7%), III =13 (17.8%), IV =2 (13.3 %)]. In emergent and urgent cases,

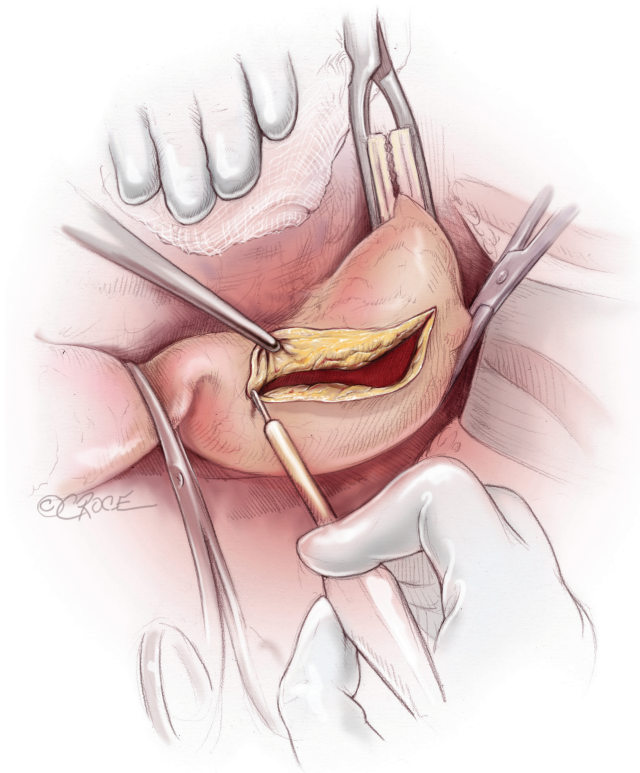


Figure 3 The aorta is initially clamped proximal to the left subclavian artery and across the mid-descending thoracic aorta and then the aorta is incised between the clamps.

30-day and hospital mortality rates were 20% and 32%, respectively. Independent risk factors for hospital mortality were emergency surgery (OR 13.4, $P=0.003$) and aortic cross clamping >2 hours (OR 5.7, $P=0.04$). Postoperative spinal cord ischemic complications in 16 (10.5%) patients; 8 patients developed paraplegia and 8 had paraparesis [2 (9.5%) in Crawford extent I, 3 (7.0%) in II, 11 (15.1%) in III, and zero in IV]. In emergent and urgent cases, spinal cord ischemic complications developed in 12.0%. Risk factors for spinal cord ischemia were prior surgery involving the descending thoracic or abdominal aorta (OR 3.75, $P=0.05$), diabetes mellitus (OR 5.49, $P=0.03$) and post-bypass hypotension <80 mmHg (OR 1.06, $P=0.03$). Postoperative survival at 5 years for all patients was $83.6\pm 4.5\%$. 5-year survival was $47.5\pm 8.6\%$ in patients with spinal cord ischemic complications and was $88.9\pm 10.4\%$ in patients without these complications. Freedom from aortic events, such as redo operation, rupture of residual aneurysm, and false aneurysm formation, was $91.8\pm 4.3\%$ at 5 years.

Comments

Although the usefulness of extracorporeal circulation during reconstruction of the thoracoabdominal aorta is well documented, left heart bypass with a reduced dose of heparinization (1,2) and repair without cardiopulmonary

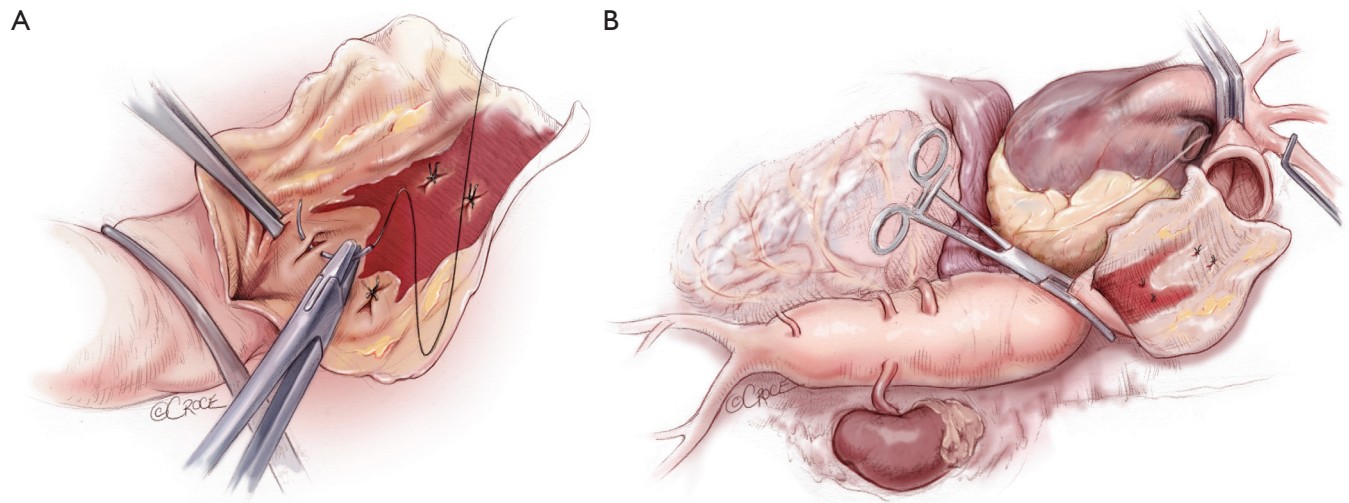


Figure 4 (A) Bleeding orifices from the bronchial arteries or high intercostal arteries are oversewn with monofilament sutures; (B) The proximal aorta is completely transected and dissected away from the surrounding esophagus, left vagus nerve, and thoracic duct.

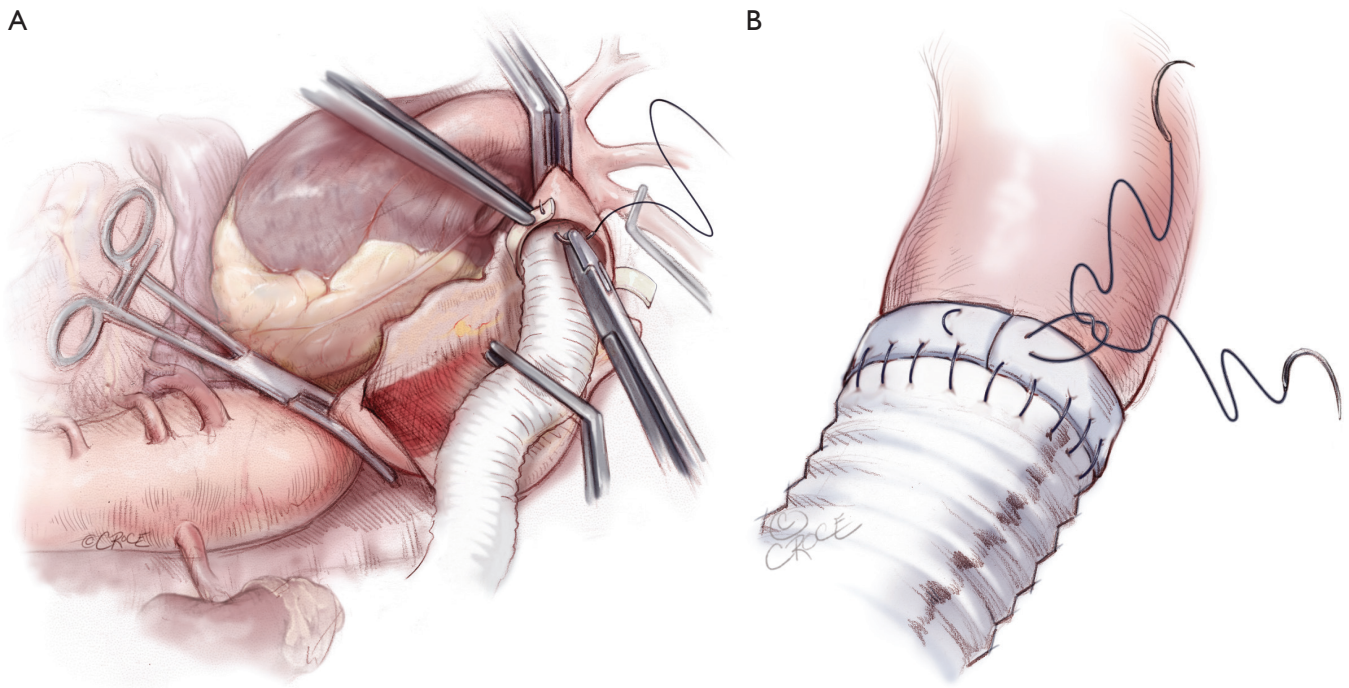


Figure 5 (A) A 20- or 22-mm Dacron graft with 8-mm side-branches is used. This graft has 4 spatially orientated branches for the abdominal visceral arteries. The proximal anastomosis is performed using a 4-0 monofilament suture (22-mm needle) with Teflon strip reinforcement; (B) The edge of the Teflon strip is tightened with a compacting stitch to prevent bleeding from suture holes.

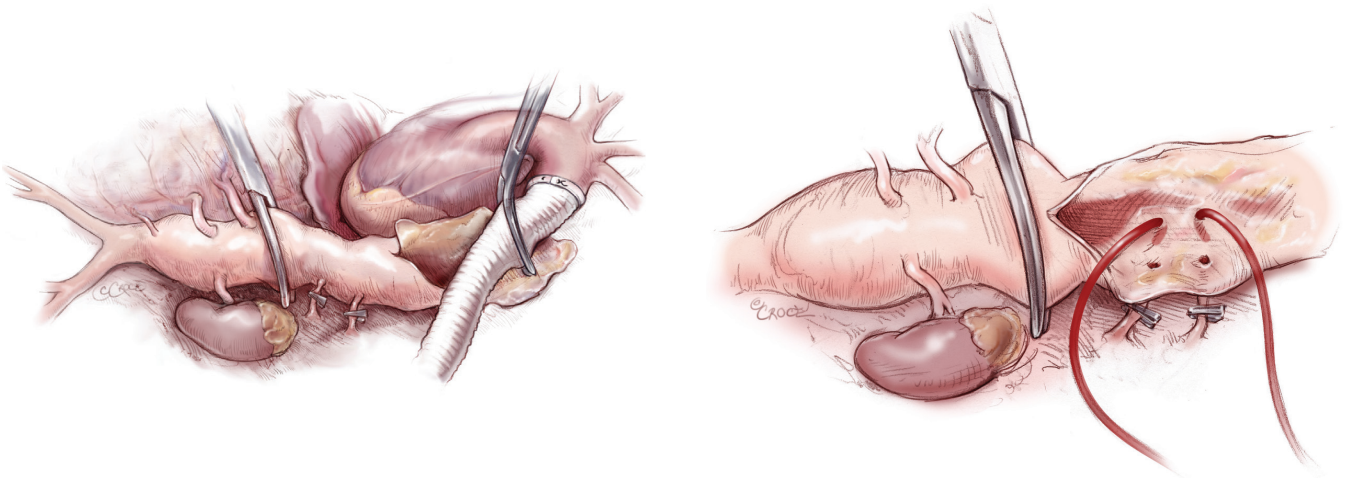


Figure 6 The descending aorta is then clamped at the T10 level. Before opening the aorta, the left T8 and T9 intercostal arteries are exposed and clamped from outside the aorta.

Figure 7 Five minutes after aortic clamping and observing the MEPs for decreased signaling, the aorta is opened. Back-bleeding from the right intercostal arteries is controlled by inserting 2-Fr balloon-tipped catheters into the respective ostia, in order to prevent spinal cord ischemia resulting from a steal phenomenon.

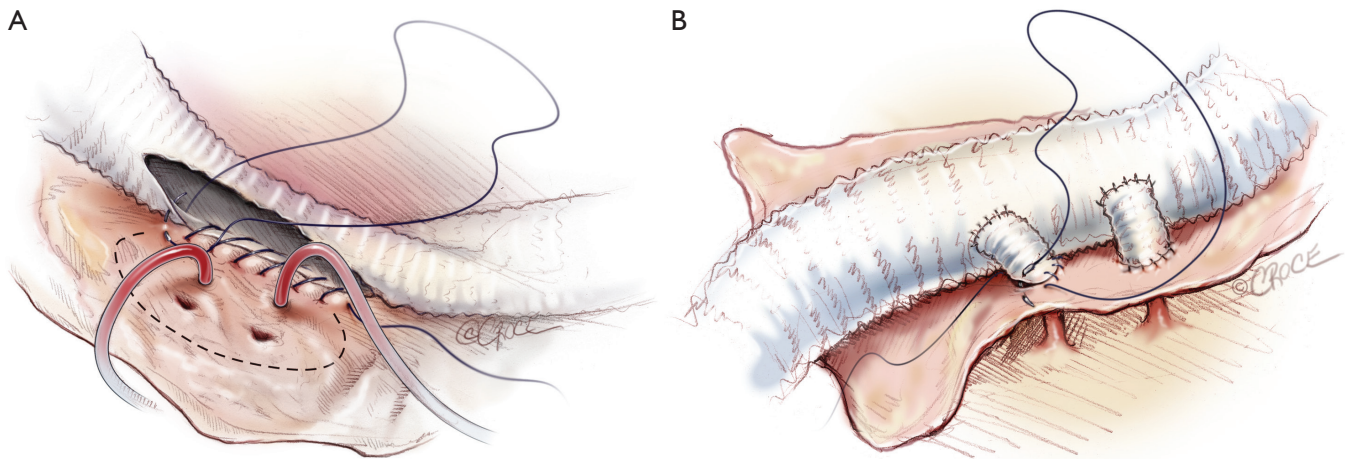


Figure 8 (A) Patent orifices of intercostal arteries (no more than two pairs) are then anastomosed to a side hole of the graft as an aortic patch using an inclusion technique with a 4-0 monofilament suture (17-mm needle); (B) Another technique to reattach the intercostal arteries is through a graft interposition, where several small grafts connect to the orifices of the intercostal arteries.

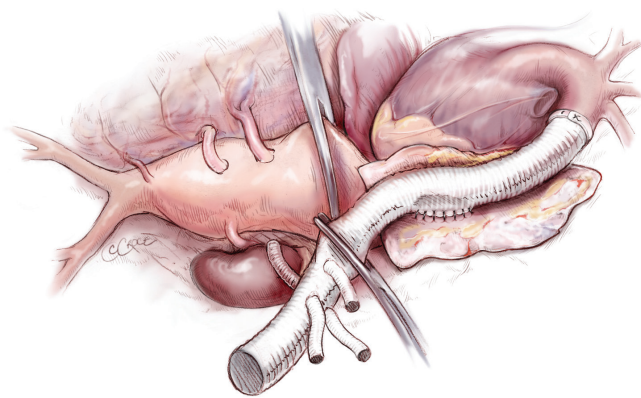


Figure 9 Following the intercostal artery anastomosis, the graft clamp is moved distally to allow perfusion of the newly anastomosed intercostal arteries.

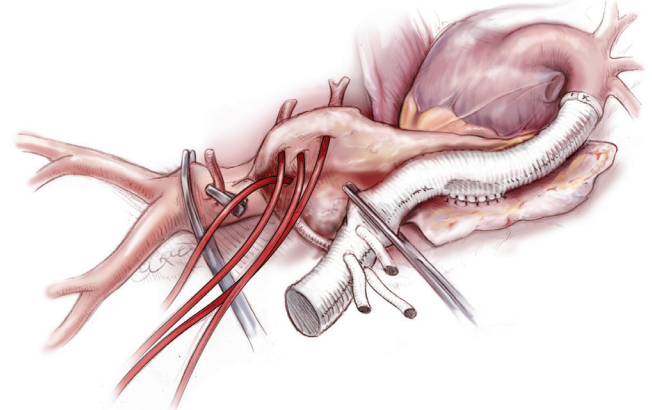


Figure 10 The infra-renal portion of the abdominal aorta is then clamped and opened. The back-bleeding from lumbar arteries is controlled similarly to intercostal back-bleeding. The 4 visceral arteries are perfused using 8-Fr size balloon tipped catheters (Fuji phycon[®], Tokyo) via a single roller pump at arterial flows of 150-200 mL/min.

bypass altogether (3,4) have been shown to produce acceptable surgical outcomes. At our institution, we have primarily instituted cardiopulmonary bypass instead of either of these two alternatives as it provides stable hemodynamic support if pulmonary function deteriorates. An additional advantage of this technique is that a cardiotomy suction can be used in case of unexpected massive bleeding. Lastly, the benefits of hypothermia on end-organ protection can be taken advantage of as the patient's body temperature is easily controlled through

core-cooling during the bypass period (5,6).

Revascularization of the intercostal arteries represents an important technical step during repair of thoracoabdominal aneurysms. Several surgical techniques have been described, the most simple of which is an aortic patch anastomosis to the prosthetic graft. The main advantage of the patch technique is the reduced number of anastomoses (1). However, isolated reimplantation of each intercostal artery

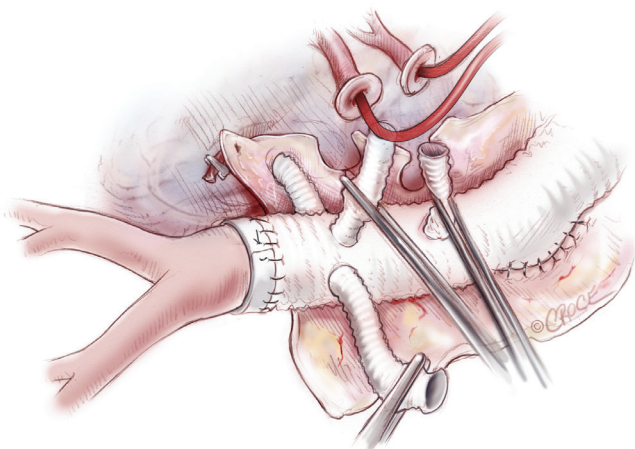


Figure 11 Upon completion of visceral artery cannulation, rewarming is initiated. Each visceral artery is individually dissected to make a button.

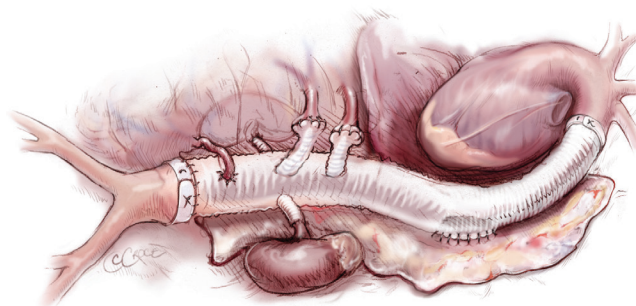


Figure 12 After completion of all anastomoses, the patient is weaned from cardiopulmonary bypass and hemostasis is achieved after protamine is administered.

might be necessary for larger aneurysms, particularly if the ostia of the intercostal arteries are widely displaced from each other. Moreover, it has been reported that when a segment of aortic wall is left in situ to facilitate branch reconstruction, it may become aneurysmal, particularly in patients with Marfan syndrome (7). Dardik *et al.* (8) reported a prevalence of patch aneurysm of 7.5% in 107 patients who underwent thoracoabdominal aneurysm repair. Lombardi *et al.* (9) reported 3 patients with patch aneurysm among 20 patients who required reoperation after previous thoracoabdominal aneurysm repair. Kouchoukos *et al.* (10) reported 2 cases of patch aneurysm in Marfan patients.

The major drawback of the graft interposition technique is suboptimal patency of the reconstructed grafts when compared with the patch technique, where almost all attached intercostal arteries should remain patent. In our series, early patency of the interpositioned grafts was only 70% by angiography or CT scan. Moreover, more than half of the grafts were occluded in patients who had postoperative paraplegia (11).

Other adjuncts for spinal cord protection played important roles in the surgical outcomes of this cohort. The advent of the MR and CT imaging has facilitated identification of the great radicular artery, the artery of Adamkiewicz. Yamada *et al.* (12) firstly demonstrated the Adamkiewicz artery in the majority of the patients with descending or thoracoabdominal aortic aneurysms. Yoshioka *et al.* (13) demonstrated several intercommunicating collateral pathways between the critical

intercostal arteries. These non-invasive imaging techniques have simplified the surgical procedure to reconstruct the critical intercostal arteries and neighboring ones. Additionally, concomitant use of intraoperative transcranial-stimulated MEPs of the spinal cord enables detection of cord ischemia and identifies critical intercostal arteries in real time (14). Furthermore, CSFD alleviates secondary compression of the spinal cord due to ischemic edema (15).

Regarding techniques for reconstructing visceral arteries, Carrel *et al.* (16) reported their technique of separate revascularization of the visceral arteries in thoracoabdominal aneurysm repair. Similarly, Safi *et al.* (17) reported their use of a presewn 4-branched graft for visceral artery reconstruction during thoracoabdominal aortic repair using a deep hypothermic technique. Visceral protection has been achieved by separate visceral perfusion with graft flows between 100-200 mL/min. Some reports (18,19) state that systemic deep hypothermia provides excellent organ protection; however, deep hypothermia also has potential disadvantages including a longer cardiopulmonary bypass time, increased coagulopathy (20), and increased lung dysfunction (21). On the other hand, Coselli *et al.* (22) emphasized the superiority of infusing cold crystalloid solution into the renal arteries. We favor, however, perfusing viscera rather than infusing cold saline or no perfusion when the aortic cross clamp time is prolonged. We believe that each button anastomosis facilitates mobilization of the branches that may improve the postoperative patency rate of visceral arterial anastomoses when compared with the

patency rate following the inclusion technique. Care must be taken to avoid rotation of the viscera to the right during reconstruction because the visceral arteries, especially the left renal artery, may kink after subsequent repositioning of the viscera.

The importance of postoperative pain control cannot be overemphasized when patients start respiratory and ambulatory rehabilitation. In such circumstances, paravertebral nerve blockade enables physiotherapy even in the elderly (23).

Conclusions

Early results of patients who underwent surgery for thoracoabdominal aortic aneurysms, with reconstruction of the intercostal arteries and using a branched replacement graft, was satisfactory.

Acknowledgements

We thank Ms. Beth Croce, Illustration Editor, and Dr. Ashutosh Hardikar, Art of Operative Techniques Section Editor, for making these highly detailed illustrations.

Disclosure: The authors declare no conflict of interest.

References

1. Crawford ES, Crawford JL, Stowe CL, et al. Total aortic replacement for chronic aortic dissection occurring in patients with and without Marfan's syndrome. *Ann Surg* 1984;199:358-62.
2. Hollier LH, Symmonds JB, Pairolero PC, et al. Thoracoabdominal aortic aneurysm repair. Analysis of postoperative morbidity. *Arch Surg* 1988;123:871-5.
3. Cambria RP, Davison JK, Zannetti S, et al. Thoracoabdominal aneurysm repair: perspectives over a decade with the clamp-and-sew technique. *Ann Surg* 1997;226:294-303; discussion 303-5.
4. Tefera G, Acher CW, Wynn MM. Clamp and sew techniques in thoracoabdominal aortic surgery using naloxone and CSF drainage. *Semin Vasc Surg* 2000;13:325-30.
5. Okita Y, Takamoto S, Ando M, et al. Repair for aneurysms of the entire descending thoracic aorta or thoracoabdominal aorta using a deep hypothermia. *Eur J Cardiothorac Surg* 1997;12:120-6.
6. von Segesser LK, Marty B, Mueller X, et al. Active cooling during open repair of thoraco-abdominal aortic aneurysms improves outcome. *Eur J Cardiothorac Surg* 2001;19:411-5; discussion 415-6.
7. Ingu A, Ando M, Okita Y, et al. Redo operation for thoracoaortic aneurysm after entire aortic replacement. *Ann Thorac Surg* 2001;72:1766-7.
8. Dardik A, Perler BA, Roseborough GS, et al. Aneurysmal expansion of the visceral patch after thoracoabdominal aortic replacement: an argument for limiting patch size? *J Vasc Surg* 2001;34:405-9; discussion 410.
9. Lombardi JV, Carpenter JP, Pochettino A, et al. Thoracoabdominal aortic aneurysm repair after prior aortic surgery. *J Vasc Surg* 2003;38:1185-90.
10. Kouchoukos NT, Masetti P, Castner CF. Use of prewoven multiple branched graft in thoracoabdominal aortic aneurysm repair. *J Am Coll Surg* 2005;201:646-9.
11. Omura A, Tanaka A, Miyahara S, et al. Early and late results of graft replacement for dissecting aneurysm of thoracoabdominal aorta in patients with Marfan syndrome. *Ann Thorac Surg* 2012;94:759-65.
12. Yamada N, Okita Y, Minatoya K, et al. Preoperative demonstration of the Adamkiewicz artery by magnetic resonance angiography in patients with descending or thoracoabdominal aortic aneurysms. *Eur J Cardiothorac Surg* 2000;18:104-11.
13. Yoshioka K, Niinuma H, Ohira A, et al. Three-dimensional demonstration of the artery of Adamkiewicz by multidetector-row computed tomography. *Ann Thorac Surg* 2004;78:719.
14. de Haan P, Kalkman CJ. Spinal cord monitoring: somatosensory- and motor-evoked potentials. *Anesthesiol Clin North America* 2001;19:923-45.
15. Coselli JS, LeMaire SA, Köksoy C, et al. Cerebrospinal fluid drainage reduces paraplegia after thoracoabdominal aortic aneurysm repair: results of a randomized clinical trial. *J Vasc Surg* 2002;35:631-9.
16. Carrel TP, Signer C. Separate revascularization of the visceral arteries in thoracoabdominal aneurysm repair. *Ann Thorac Surg* 1999;68:573-5.
17. De Rango P, Estrera AL, Miller C 3rd, et al. Operative outcomes using a side-branched thoracoabdominal aortic graft (STAG) for thoraco-abdominal aortic repair. *Eur J Vasc Endovasc Surg* 2011;41:41-7.
18. Kulik A, Castner CF, Kouchoukos NT. Outcomes after thoracoabdominal aortic aneurysm repair with hypothermic circulatory arrest. *J Thorac Cardiovasc Surg* 2011;141:953-60.
19. Fehrenbacher JW, Siderys H, Terry C, et al. Early and late results of descending thoracic and thoracoabdominal

- aortic aneurysm open repair with deep hypothermia and circulatory arrest. *J Thorac Cardiovasc Surg* 2010;140:S154-60; discussion S185-90.
20. Westaby S. Coagulation disturbance in profound hypothermia: the influence of anti-fibrinolytic therapy. *Semin Thorac Cardiovasc Surg* 1997;9:246-56.
 21. Apostolakis E, Filos KS, Koletsis E, et al. Lung dysfunction following cardiopulmonary bypass. *J Card Surg* 2010;25:47-55.
 22. LeMaire SA, Jones MM, Conklin LD, et al. Randomized comparison of cold blood and cold crystalloid renal perfusion for renal protection during thoracoabdominal aortic aneurysm repair. *J Vasc Surg* 2009;49:11-9; discussion 19.
 23. Català E, Casas JI, Unzueta MC, et al. Continuous infusion is superior to bolus doses with thoracic paravertebral blocks after thoracotomies. *J Cardiothorac Vasc Anesth* 1996;10:586-8.

Cite this article as: Okata Y, Omura A, Yamanaka K, Inoue T, Kano H, Tanioka R, Minami H, Sakamoto T, Miyahara S, Shirasaka T, Ohara T, Nagai H, Okada K. Open reconstruction of thoracoabdominal aortic aneurysms. *Ann Cardiothorac Surg* 2012;1(3):373-380. doi: 10.3978/j.issn.2225-319X.2012.09.05

Video-assisted thoracoscopic lobectomy using a standardized three-port anterior approach – The Copenhagen experience

Henrik J. Hansen, René H. Petersen

Department of Cardiothoracic Surgery 2.15.2, Rigshospitalet, Copenhagen University Hospital, Denmark

Introduction

Video-Assisted Thoracoscopic Surgery (VATS) lobectomy is now well established and performed all around the world. Formerly there was much debate about the feasibility of the technique in cancer surgery and proper lymph node handling. Although there is a lack of proper randomized studies, it is now generally accepted that the outcome of a VATS procedure is at least not inferior to a resection via a traditional thoracotomy. Several papers have concluded that there is no significant difference in survival rates and that there might even be a better outcome by VATS (1-3).

A VATS lobectomy and even more a VATS anatomical segmentectomy is a challenging and technically demanding procedure to perform; and yet there is still no consensus about the basic principles in the technique. Different techniques have been described including the simultaneously stapled lobectomy (4), a VATS assisted operation with some rib spreading (5) and a true VATS lobectomy defined by no rib spreading along with anatomical hilar dissection and only monitor based vision rather than looking through the utility incision. The procedure is performed with up to 5 incisions and is even reported with a uniportal approach (6). Different lobe specific approaches have been reported (7) and a wide variation in instruments and camera positions is seen.

At our institution we have a large experience with about 1,000 cases performed by a standardised three-port anterior approach with sequential division of the hilar structures, proper lymph node handling, no rib spreading and vision relying on the monitor only. This allows us to perform VATS lobectomies in the majority of the cases even if there are significant difficulties (8). We find that our standardized three-port anterior approach facilitates the VATS lobectomy, and it is our experience from visiting surgeons that our technique can easily be adapted by many surgeons, especially those who are used to an open anterior approach.

The major advantages of the standardized anterior approach are:

- ❖ The mini-thoracotomy is placed directly over the

- hilum and the major pulmonary vessels. Easy to clamp the major vessels in case of major bleeding
- ❖ No need of changing the surgeons' position or the place of the incision if a conversion is required
- ❖ The first structures to be transected are the major vessels
- ❖ The same approach to all lobes makes it easy to reproduce and learn
- ❖ The lung tissue only pushed backwards gently with peanuts and never grasped with forceps and therefore not torn apart
- ❖ Easy to teach as the surgeon and the assisting surgeon stand on the same side and use the same monitor. They do not work opposite to each other and therefore maybe against one and another. This facilitates a fluid learning process

Indications for VATS lobectomy

VATS lobectomy is commonly performed for selected peripherally located T1 or T2 tumours and usually reserved for patient where complications are not expected. We think that the advantages of a minimally invasive approach would also benefit cases that are more advanced and therefore the question in our daily clinically practice is: Are there any contraindications to perform the planned lobectomy as a VATS procedure?

At present we find the following contraindications:

- ❖ T3 or T4 tumours.
- ❖ Tumours larger than 6 cm.
- ❖ Tumours visible in the bronchus by bronchoscopy within 2 cm of the origin of the lobe to be resected and where a possible Sleeve resection might be needed.
- ❖ Centrally placed tumours in the hilum and adherent to vessels.

This means that patients with former Tuberculosis, previous cardiothoracic surgery and patients who have received preoperative chemo-radiotherapy are still considered as candidates for a VATS lobectomy. All our patients have a preoperative examination with lung function testing, PET/CT, bronchoscopy and EBUS/mediastinoscopy for preoperative staging (unless it is a peripheral placed T1 tumour on PET). With growing experience, we perform VATS lobectomy in the majority of the cases at our institution, even if they do present with co-morbidity. In the last few years, between 70% and 80% of all cancer lobectomies in our institution were performed by VATS and we now perform well over 200 VATS lobectomies and quite a few anatomical VATS segmentectomies each year (17 in 2011) with a very low conversion rate (2% in 2011).

Operating room set-up and basic surgical principles

A standard set-up is with one monitor placed on each side of the table in front of the surgeons and the scrub nurse (*Figure 1*). Other screens in the room allow other persons in the theatre to follow the surgery. We have two dedicated VATS theatres designed by the author together with Olympus Inc at our clinic and these theatres are only used for thoracic procedures. The basic principle is that the theatre is symmetrical so it is suitable for both right and left sided procedures. The light setting is a dynamic and colored lighting that enhances the surgical ergonomometry.

All VATS lobectomies are performed with a 10 mm, 30 degree angled HD video-thoracoscope. The 30-degree angulation allows a superior view within the chest cavity. In a 10 mm camera, the power of the light source is stronger than the light source in the existing 5 mm cameras, and is not easily flooded by even a minor bleeding.

The surgeon and the assistant are positioned on the anterior (abdominal) side of the patient and with the surgeon cranially. The scrub nurse is opposite to the assistant and follows the operation on a separate screen and still positioned face to face with the surgeon (*Figure 1*). Initially, a 5 cm anterior utility incision is made without any tissue retractor or rib spreading. The wound is protected by a plastic soft tissue retractor kept in place by a ring in the chest cavity and one outside the skin (Alexis Retractor, Applied Medical USA). This incision is later used for specimen retrieval, and is positioned between the breast and the lower angle of the scapula in the fourth intercostal

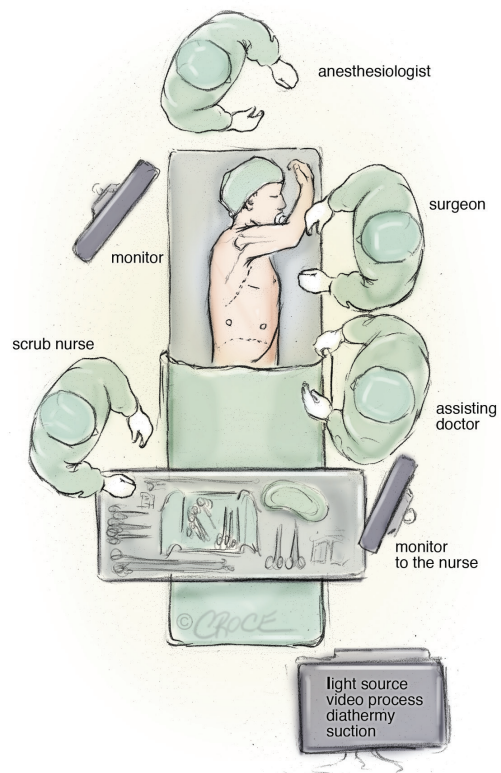


Figure 1 Operating room set-up for the anterior approach of video-assisted thoracoscopic lobectomy.

space just anterior to the latissimus dorsi muscle (*Figure 2*). In case of a conversion to open procedure, this incision can be easily expanded to a 10 to 15 cm muscle sparing thoracotomy within a few minutes.

The cavity is evaluated with the camera through this incision looking for unexpected pathology, adhesions, and the level of the diaphragm. A low anterior 1 cm camera-port is positioned at the level of the top of the diaphragm and anterior to the level of the hilum and the phrenic nerve. The final 1.5 cm incision is positioned at the same level but more posterior in a straight line down from the scapula and anterior to the latissimus dorsi muscle. This results in a triangle with two approximately 10 cm limbs and the camera positioned at the apex, with a working channel on each side, which makes the procedure more easy and natural to the surgeon (*Figure 2*). The camera is in the lower anterior corner of the chest cavity with a good overview and it is usually not necessary to change camera port at any point of the procedure.

To palpate, free and prepare the structures, we use an array of a peanut or a sponge stick, an electrocautery blade

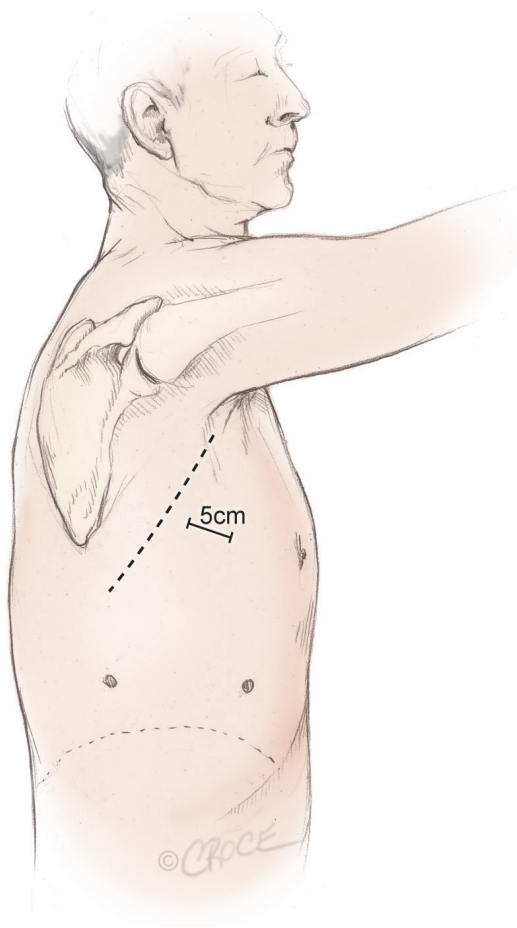


Figure 2 Three incisions made for the anterior approach forming a triangular configuration, with the utility incision at the apex of the triangle, measuring 5 cm in length.

hook controlled with a normal surgical handhold. The tip of the hook can be used to lift and divide the tissue. To present vessels and other structures to be divided we use an elastic vessel loop made of rubber, as slings of other materials present a risk of tearing, especially the fragile arteries to upper lobes. We do not place clamps on the vessels before stapling but two vessel clamps are ready on the table in case of an emergency bleeding and furthermore a set up for open surgery is present in the theatre.

The vessels, the fissures and the bronchus are divided sequentially, with appropriate endostaplers. For the vessels and thin parenchyma we use a tan Tri-stapler (Covidien, USA) and for poorly defined fissures and the bronchus, we transect with a purple Tri-stapler. Any specimen with suspicion of malignancy is removed with an endobag

Energy-based devices can also be used and we have some experience with an electro-thermal bipolar tissue sealing

system (Ligasure, Valleylab Inc., USA) and find it useful to transect minor pulmonary arteries up to the size of 3-4 mm and they are very useful for lymph adenectomy where it facilitates an “en bloc” dissection.

Due to a high percentage of patients with prolonged air-leakage in our early experience, we have changed our strategy to a “fissure non-touch technique”. This means no dissection or use of electrocautery in the fissure. Instead the fissure is stapled with the visceral pleura intact as a seal above the parenchyma, giving a more tight closure within the stapling line, and no scars in the tissue next to the clips. To facilitate this, the fissure stapling is performed quite late in the procedure after the majority of the hilar structures are divided.

At the end, one intercostal drain is placed in through the camera incision. After surgery, the patient is transferred to an intermediate ward and next day to the normal ward. The patients are mobilised on the day of surgery and lung physiotherapy is provided for training. The tube is removed when there is no air-leakage and less than 500 cc of fluid in 24 hours. Patients are usually discharged one day after tube removal and seen ten days later in the outpatient clinic.

Operative techniques

After inspection of the cavity and confirmation of the indication for lobectomy, the structures are divided as you encounter them during the operation from anterior to posterior.

Right upper lobectomy

First the pleura over the anterior hilum and along the azygos vein are divided and next a thoracoscopic DeBakey forceps, introduced through the posterior port, is passed behind the superior pulmonary vein after clear identification of the middle lobe vein. The superior pulmonary vein is then encircled with a vessel loop and enough space to introduce a stapler around the vessel is created (*Figure 3*). The endovascular stapler is introduced through the posterior port and the thin blade is passed behind the superior pulmonary vein, which is then divided after removal of the vessel loop.

When the pulmonary vein is divided, the pulmonary artery and the truncus anterior are visualized and the superior trunk is transected in the same way as the vein. The pulmonary artery can then be visualized down to the branches to the middle lobe and the minor fissure is divided

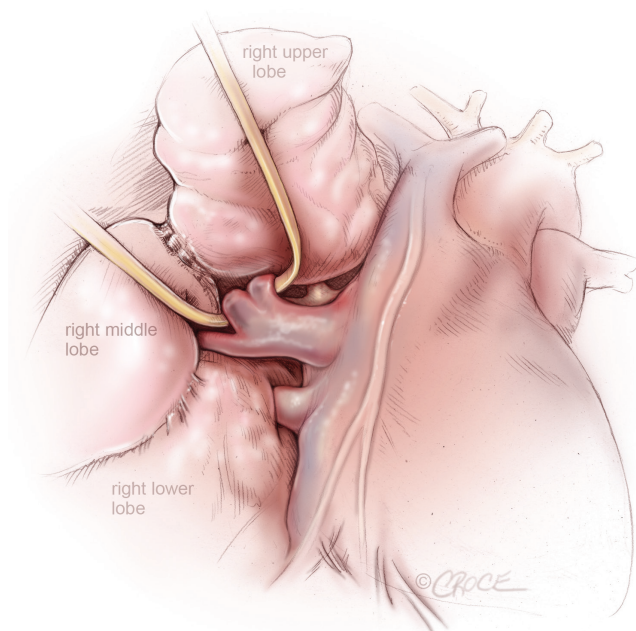


Figure 3 VATS right upper lobectomy: right superior pulmonary vein from right upper lobe is encircled by a vascular loop, while the pulmonary venous drainage from the right middle lobe is clearly seen.

with endostaplers (*Figure 4*). The central landmark is the posterior border of the artery just above the middle lobe and below the divided vein to the upper lobe. After the transection of the fissure past the artery, the middle lobe drops down and exposes the posterior part of the artery and the remaining arterial branches to the upper lobe, which are then transected (*Figure 4*). Next the bronchus and the posterior part of the fissure is divided one by one. The bronchus is transected with a purple endostapler (in large-size patients a black Tristapler might be needed) and the device is closed and opened a few times to crunch the bronchus before firing to make the closure tighter. The lobe is then placed in an endobag and removed via the utility incision.

Right middle lobectomy

The anterior part of the pleura over and between the veins is divided with the hook to expose and allow division of the middle lobe vein. Next, the middle lobe bronchus is exposed by blunt dissection in the hilum but sometimes the anterior part of the major fissure need to be transected. The bronchus is presented with a vessel loop and the stapler is

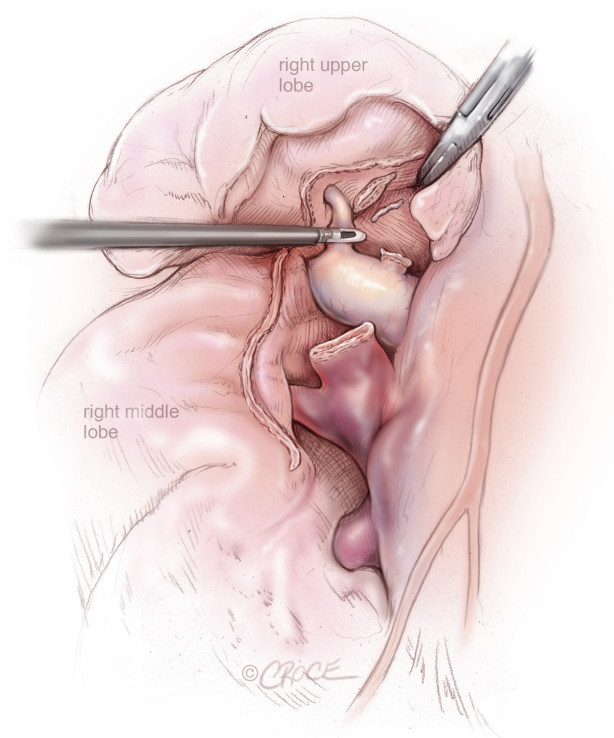


Figure 4 VATS right upper lobectomy: after division of right upper lobe pulmonary vein and truncus anterior, posterior ascending segmental artery to the right upper lobe is being divided by a Ligasure.

introduced from the posterior incision (*Figure 5*). There will now be a good view of the artery and branches to the middle lobe are exposed (*Figure 6*), encircled and transected. The fissures are then completed beginning with stapling of the central part next to the artery via the posterior port.

Left upper lobectomy

The pleura over the hilum is divided and the artery and both veins are identified. The plane between the artery and the upper lobe vein is opened so the vein is exposed by a vessel loop coming from the anterior utility incision and it can then be transected with the stapler introduced from the posterior port. Next the superior branch of the pulmonary artery is divided in the same way and thereafter a plane between the artery and the bronchus can be created. The bifurcation of the left upper and lower lobe bronchi is identified, and the left upper lobe bronchus is transected from the posterior port by a purple Tristapler. The lobe is pushed posterior and the remaining branches on the pulmonary artery including the lingular artery are

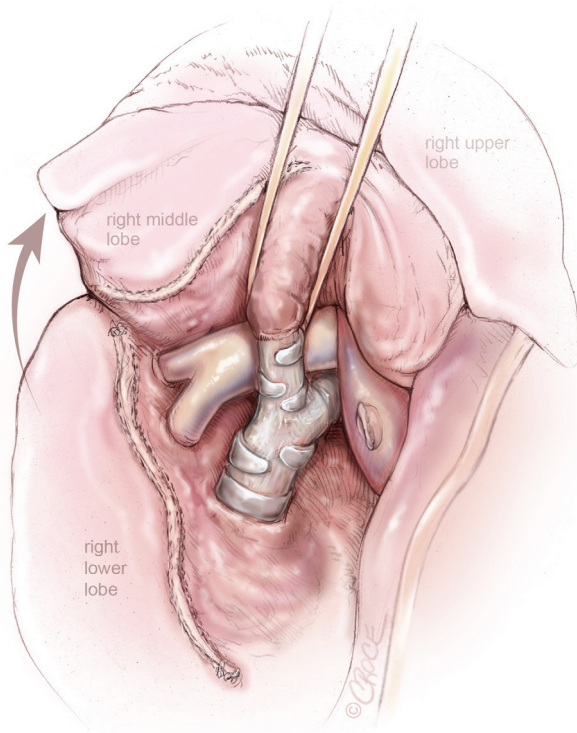


Figure 5 VATS right middle lobectomy: bronchus of the right middle lobe is presented through the oblique fissure after division of the right middle lobe vein.

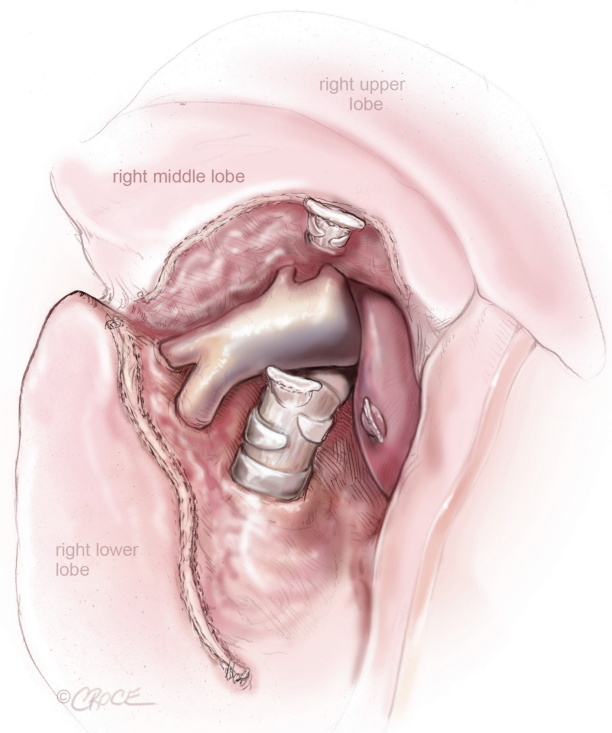


Figure 6 VATS right middle lobectomy: after the division of the right middle lobe vein and bronchus, pulmonary artery branches to the right middle lobe and lower lobe is exposed.

exposed and transected by stapler or a mixture of clips and energy based devices. The fissure is finally transected with endostaplers via the posterior port (*Figure 7*).

Lower lobectomies

The lower lobe is retracted superiorly and the inferior pulmonary ligament is divided. This exposes the inferior pulmonary vein which can be encircled with a rubber loop and transected with the stapler from the utility incision. Next in the sequence is the artery where the pleura above are opened to allow the artery to be dissected in the sheath (*Figure 8*). The artery is lifted away from the parenchyma with a vascular sling and divided. In some cases, the superior segment of the right lower lobe artery needs to be divided separately, when it arises high up. The anterior part of the fissure is divided before or after the artery and the bronchus and the posterior fissure can be transected step by step.

One should be sure of the position of the middle lobe bronchus on the right side and when in doubt, the stapler should be closed at the site of the planned firing

and the lung is then inflated to demonstrate airflow in the middle lobe.

Lymph node dissection

In our opinion it is doubtful whether a complete mediastinal lymph node dissection has a therapeutic benefit, or if the lymph node sampling only relates to stage identification. In all our cases we do a systematic lymph node dissection using the electro-thermal system (Ligasure) or electrocautery with removal of lymph nodes from at least 3 stations of N2 nodes according to the IASLC/Mountain classification.

In right-sided procedures, the nodes removed are from station 2R and 4R en-bloc. First, the pleura is opened above and under the azygos vein. The dissection begins at the tracheobronchial angle and progresses upwards under the azygos vein. After cleaning of the inferior part of the fatty tissue of the superior mediastinum the fatty tissue including the nodes is gripped from above and the dissection continues on so the level 2 nodes are included and the whole tissue packet is removed in one piece (*Figure 9*).

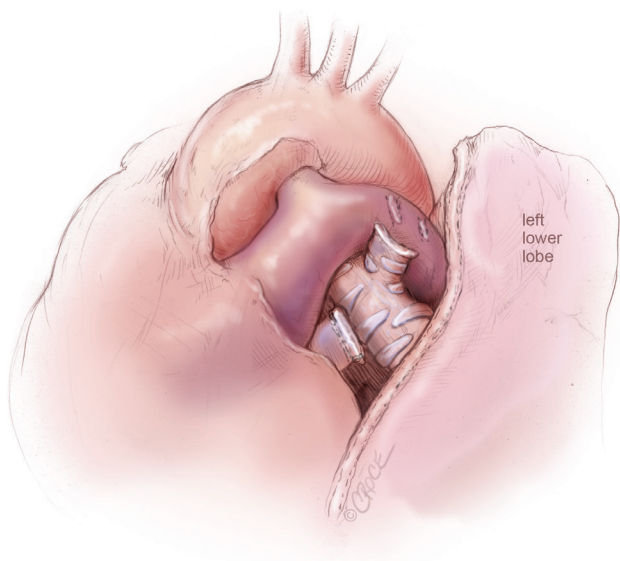


Figure 7 VATS left upper lobectomy: left upper lobe bronchial and vascular stumps are visualized, after left upper lobectomy and en bloc removal of Station 5 and Station 6 lymph nodes.

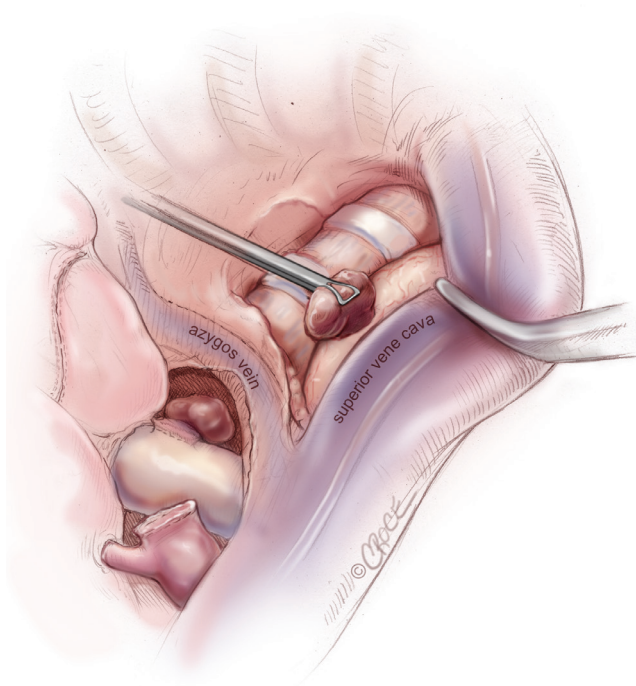


Figure 9 VATS lymph node dissection: superior mediastinal lymph node dissection on the right side.

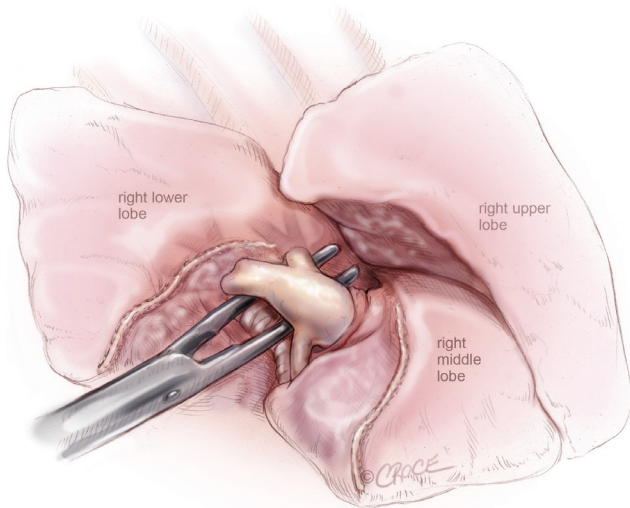


Figure 8 VATS right lower lobectomy: pulmonary artery to right lower lobe, including superior segmental artery is isolated, after dividing the oblique fissure anteriorly.

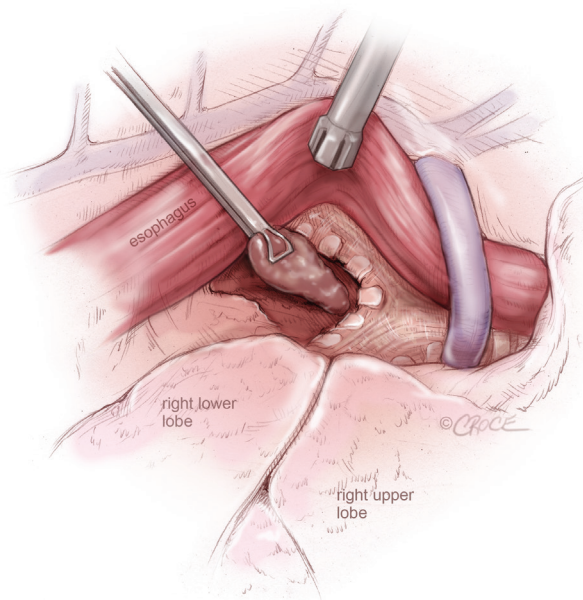


Figure 10 VATS lymph node dissection: subcarinal lymph node dissection from the right side, by retracting the esophagus posteriorly and the lung anteriorly to expose the membranous trachea and the subcarinal region.

To approach the subcarinal nodes the inferior ligament is divided and the pleura on the posterior limit of the lung is opened up to the azygos vein. The remaining lung is pushed anteriorly and the camera is angled so it looks along the oesophagus and the station 7 is exposed and removed so that the carinal bifurcation and the opposite bronchus are clean (*Figure 10*).

On the left side nodes are removed en-bloc from station 5 and 6 (as seen on *Figure 7* between the aorta and the main pulmonary artery), station 7 is removed like on the right side. In lower lobe resections nodes from station 8 and 9 on the affected site are removed as well. Station 10 nodes are in upper lobe resections removed as part of the procedure to expose other structures.

Comments

We have a VATS lobectomy program that deals with the majority of our institution's pulmonary resections. All operations are performed with a standardized three-port anterior approach independent of the procedure and the part of the lung to be addressed. There is a low conversion rate with a very low mortality (in the last few years <1% 30-day mortality) and a low morbidity.

Acknowledgements

Disclosure: The authors declare no conflict of interest.

References

- Downey RJ, Cheng D, Kernstine K, et al. Video-Assisted Thoracic Surgery for Lung Cancer Resection. A Consensus Statement of the International Society of Minimally Invasive Cardiothoracic Surgery (ISMICS) 2007. *Innovations (Phila)* 2007;2:293-302.
- Whitson BA, Groth SS, Duval SJ, et al. Surgery for early-stage non-small cell lung cancer: a systematic review of the video-assisted thoracoscopic surgery versus thoracotomy approaches to lobectomy. *Ann Thorac Surg* 2008;86:2008-16; discussion 2016-8.
- Yan TD, Black D, Bannon PG, et al. Systematic review and meta-analysis of randomized and nonrandomized trials on safety and efficacy of video-assisted thoracic surgery lobectomy for early-stage non-small-cell lung cancer. *J Clin Oncol* 2009 27:2553-62.
- Lewis RJ, Caccavale RJ, Sisler GE, et al. One hundred video-assisted thoracic surgical simultaneously stapled lobectomies without rib spreading. *Ann Thorac Surg* 1997;63:1415-21; discussion 1421-2.
- Okada M, Sakamoto T, Yuki T, et al. Hybrid surgical approach of video-assisted minithoracotomy for lung cancer: significance of direct visualization on quality of surgery. *Chest* 2005;128:2696-701.
- Gonzalez-Rivas D, Paradela M, Fieira E, et al. Single-incision video-assisted thoracoscopic lobectomy: initial results. *J Thorac Cardiovasc Surg* 2012;143:745-7.
- Gossot D. Technical tricks to facilitate totally endoscopic major pulmonary resections. *Ann Thorac Surg* 2008;86:323-6.
- Hansen HJ, Petersen RH, Christensen M. Video-assisted thoracoscopic surgery (VATS) lobectomy using a standardized anterior approach. *Surg Endosc* 2011;25:1263-9.

Cite this article as: Hansen HJ, Petersen RH. Video-assisted thoracoscopic lobectomy using a standardized three-port anterior approach—The Copenhagen experience. *Ann Cardiothorac Surg* 2012;1(1):70-76. doi: 10.3978/j.issn.2225-319X.2012.04.15

Surgical atlas of thoracoscopic lobectomy and segmentectomy

Tristan D. Yan^{1,2}

¹The Collaborative Research (CORE) Group, Macquarie University, Sydney, Australia; ²Department of Cardiothoracic Surgery, Royal Prince Alfred Hospital, University of Sydney, Sydney, Australia

Video-assisted thoracoscopic surgery (VATS) is a well-established technique for major pulmonary resections (1). Since the first procedure was performed more than 20 years ago, the operative approach and instrumentation have matured. In 2007, CALGB 39802 trial established the most authoritative and accepted definition of the VATS lobectomy technique, i.e., 4–8 cm access incision, totally endoscopic approach, without rib spreading and individual anatomical dissection and division of pulmonary vein, artery and bronchus (2). Compared to open surgery, the minimally invasive approach has a number of benefits especially in the immediate post-operative period (3). A recent meta-analysis of propensity score matched patients demonstrated significantly lower incidences of overall complications, prolonged air leak, pneumonia, atrial arrhythmias and renal failure, as well as shorter hospitalization compared to open thoracotomy (4). This study further consolidated the benefits of VATS and offered the highest clinical evidence on this topic.

The posterior approach was first developed by Mr. William Walker from Edinburgh in April 1992. In contrast to the anterior approach, the main differences in techniques of the posterior approach include: (I) the surgeons stand posterior to the patient; (II) the utility incision is made at the 6th or 7th intercostal space anterior to latissimus dorsi muscle, instead of the 4th intercostal space; (III) the camera port is made through the auscultatory triangle, instead of lower anterior incision; and (IV) the order of dissection is from posterior to anterior, by opening up the fissure first to identify and isolate pulmonary arterial branches. The main advantages of the posterior approach include: (I) easy access to posterior hilum; (II) lymph nodes are clearly visualized; and (III) tips of the instruments are coming towards the camera, which allows safer dissection. The fact that the posterior hilum can be clearly seen greatly facilitates dissection of the segmental bronchial branches and pulmonary arteries. Hence, the posterior approach offers great advantages for VATS segmentectomy.

Preoperative considerations

I have adopted VATS resection as the preferred surgical strategy of choice for all cases of peripheral lung carcinoma of 7 cm or less in diameter and for suitable benign disease. Lobectomy and anatomic segmentectomy are standard procedures. It is possible to utilize VATS techniques in patients with more advanced disease such as moderate chest wall or pericardial involvement and, rarely, for pneumonectomy in patients with low bulk hilar involvement. However, with the trend towards lung conservation strategies, we now reserve pneumonectomy for individuals in whom bronchovascular reconstruction is not feasible.

Baseline pulmonary function is assessed by using a combination of spirometry and CO transfer factors. Additionally, selected patients undergo exercise testing. Cardiological assessment is carried out as relevant to the individual patient. Echocardiography assessment of pulmonary (PA) pressure is undertaken in patients at risk of pulmonary hypertension (PAP >45 mmHg). Few patients are declined surgery on the basis of poor pulmonary function data (e.g., both FEV₁ and FVC <35%) (1). In addition to a contrast-enhanced computed tomography scan of the head, chest, abdomen and pelvis, positron emission tomography-CT (PET-CT) with 18F-fluorodeoxyglucose (¹⁸F-FDG) is performed in all patients with bronchogenic carcinoma under consideration for resection. In patients considered suitable for lobectomy or segmentectomy, the VATS approach is attempted in all patients meeting size and stage criteria. The only absolute contraindications are those patients in whom the pleural cavity is obliterated on radiological grounds or who clearly have very proximal disease requiring a pneumonectomy. The requirement for sleeve lobectomy is a significant relative contraindication, but not absolute.

Operative techniques

Anesthesia and positioning

Following induction of anesthesia, the patient is positioned

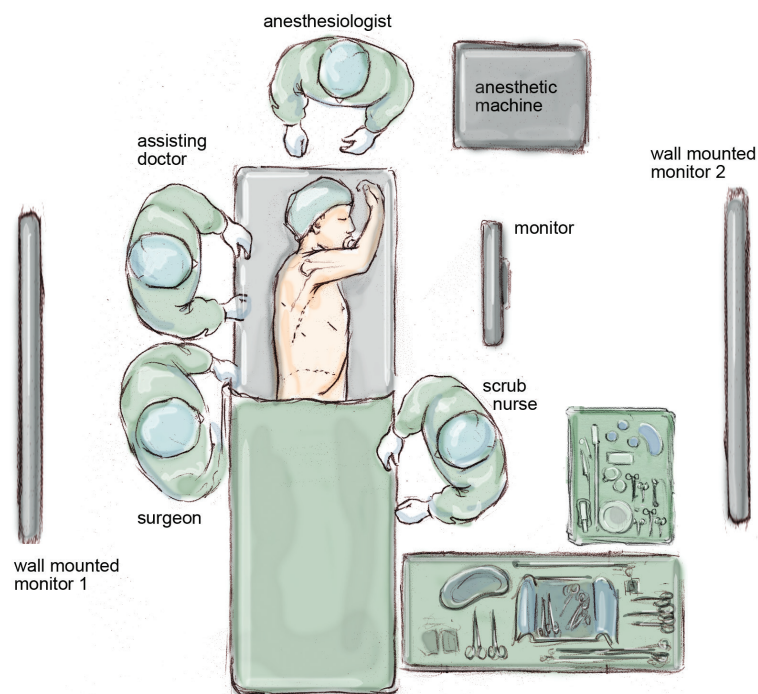


Figure 1 The positioning of the surgical, anaesthetic and nursing teams and the equipment for thoracoscopic surgery.

in the lateral decubitus position. The hands are placed unsupported in the “prayer” position in front of the face and the operating table is manipulated to extend the thorax laterally opening up the intercostal spaces. As soon as the double lumen endotracheal tube is confirmed to be in the correct position, whilst the patient is still in the anaesthetic room, ventilation is switched to the contralateral lung to optimize deflation of the lung that is to be operated upon. Suction is occasionally used if the lung does not deflate readily. The respiratory rate can be increased to 20 breaths/min or more in order to reduce the tidal volume and hence the degree of mediastinal excursion due to ventilation. This provides a more stable operating field. Central lines or urinary catheters are rarely used, but always use an arterial line and large bore venous cannulae.

The paravertebral catheter is inserted as soon as the chest cavity is entered, under thoracoscopic guidance. This is used for perioperative analgesia in preference to epidural anaesthesia and it remains in place for 48 hours. Furthermore, a patient-controlled pump is supplied to the patient for post-operative analgesia. The positioning of the surgical, anaesthetic and nursing teams and the equipment is illustrated in *Figure 1*. The surgeon and their assistants stand at the patient’s back with the screen directly across the

table and the scrub nurse obliquely opposite.

Instrument

I prefer a zero degree 5 mm high definition STORZ video thoracoscope, as it provides a single axis view allowing easy correction of orientation. A combination of endoscopic and standard open surgical instruments is used. Lung retraction and manipulation are performed using ring-type sponge-holding forceps. Long artery dissection forceps (30 cm) with or without mounted pledgets are employed for blunt dissection, which are particularly useful for exposing the PA at the base of the oblique fissure, cleaning structures and clearing node groups. A range of curved forceps and an endodissector are used gently as probes to create a passage between the lung parenchyma and major hilar structures. A right-angled dissector or long curved artery forceps is used to dissect out and pass slings around pulmonary arteries and veins. Endoscopic clips are used to ligate small vessels whilst large vessels and lung parenchyma are divided using endoscopic stapling devices to ensure haemostasis and aerostasis. Both endoscopic shears and specific VATS Metzenbaum type scissors to be helpful. The latter have the advantage of curved blade ends, which reduce the risk of

vascular injury.

Incision

Three access ports are used and port position is standard irrespective of the lobe or segment to be removed (*Figure 2*).

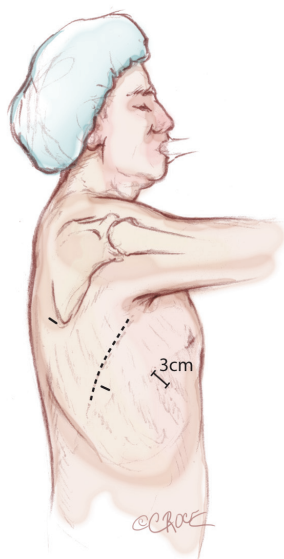


Figure 2 Standardized incisions for the posterior approach.

A 3-4 cm utility port site incision is made in the sixth or seventh intercostal space (whichever is the wider). The camera is temporarily introduced through this port to facilitate safe creation of a 0.5 cm incision posteriorly in the auscultatory triangle at the point nearest to the upper end of the oblique fissure. The anterior hilum dissection is not essential for the posterior approach. However, for completeness of this article, it is important to understand the segmental anatomy of the pulmonary veins viewed from the anterior hilum. The pulmonary veins are the most anterior structures in the hilum (*Figure 3*). Their tributaries are also anterior to the segmental arteries and bronchi. The interlobar vein often traverses between the upper and lower lobes in the oblique and then the upper and middle lobes in the horizontal fissure before joining the superior pulmonary vein in the hilum. In majority of cases, the middle lobe vein drains into the right superior pulmonary vein.

A port is inserted to accommodate the camera, which is positioned in the auscultatory triangle for the remainder of the procedure. A further 1 cm port is created in the mid-axillary line level with the upper third of the anterior utility port. The anterior and posterior ports lie at opposite ends of the oblique fissure. A video-imaged thoracoscopic assessment is performed to confirm the location of the lesion, establish resectability and exclude unanticipated

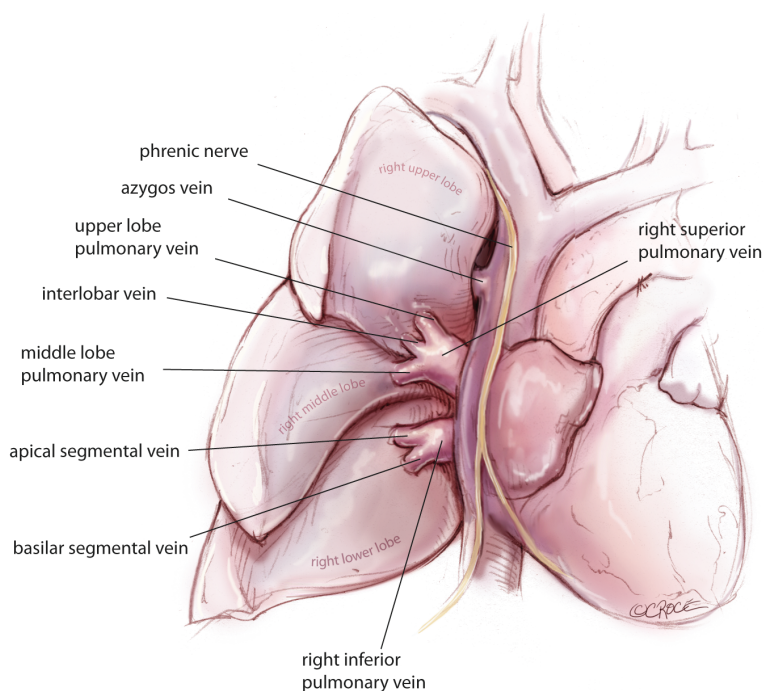


Figure 3 Segmental anatomy of the pulmonary veins viewed from the anterior hilum.

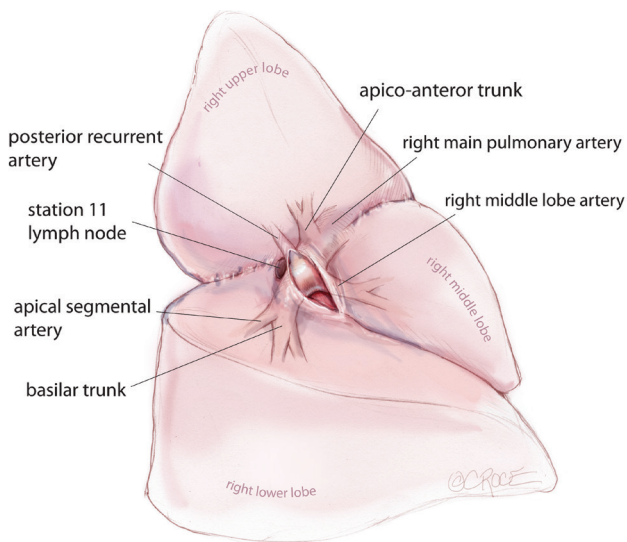


Figure 4 Pulmonary artery is revealed by separating the overlying pleura using blunt dissection.

disease findings that might preclude resection. If the lesion is small or cannot be palpated easily, sound knowledge of segmental anatomy is crucial for determining the location of the lesion within the segment(s) of the respective lobe.

The 'landmark' lymph node

The first step is to identify the PA within the central section of the oblique fissure. In some patients the PA is immediately visible, but in the majority of cases, the PA is revealed by separating the overlying pleura using blunt dissection with mounted pledgets. If the fissure does not open easily or is fused, an alternative approach utilizing a fissure-last dissection should be considered. Once the PA has been identified, the sheath of the artery is grasped with a fine vascular clamp or long artery forceps and an endoscopic dissector is used to enter the sheath defining the anterior and posterior margins of the artery. The apical lower branch of the PA is often exposed during this dissection (*Figure 4*).

For all lobectomy and segmentectomy procedures excepting middle lobectomy, the lung is then reflected anteriorly and the posterior pleural reflection is divided using sharp and blunt dissection. On the right, this process should clear lung tissue away from the angle between the bronchus intermedius and the upper lobe bronchus, exposing the posterior hilar lymph nodes in this position (*Figure 5*). One lymph node packet, the station 11 lymph

node, sitting at the bronchial bifurcation between the right upper lobe and the bronchus intermedius is the 'landmark' lymph node to me, because just superficial to this, it indicates a safe passage from the interlobar fissure to the posterior hilum over the pulmonary artery. From the anterior port site, dissecting forceps are passed gently immediately superficial and posterior to this station 11 'landmark' lymph node, where it has been identified in the oblique fissure (*Figure 6*). When the lung is retracted anteriorly, the tips of the long artery forceps will emerge through the incised posterior pleural reflection, above the 'landmark' lymph node that is now viewed from the posterior hilum. This maneuver is the key step for any VATS lobectomy or segmentectomy via the posterior approach on the right side. Care should be taken during this maneuver not to disrupt this lymph node lying on the bronchial bifurcation. A sling is then passed behind the posterior fissure, which is divided with an endoscopic linear stapling device. The PA is now clearly seen and the distinction between the upper and lower lobes is established. Dissection then proceeds according to the lobe or segment to be resected.

Right upper lobectomy

Having divided the posterior fissure, the posterior ascending segmental branch of the PA is often evident, and should be divided at this stage if appropriate. It is frequently small enough to clip. The upper lobe bronchus is then identified and dissected out. It is common to find a substantial bronchial artery running alongside the bronchus, which should be ligated with clips and divided. Note that clips are only used on the proximal end and the distal end is not clipped since clips in this position may interfere with subsequent stapling of the bronchus. The upper lobe is then retracted inferiorly and blunt dissection with mounted pledgets is used to free the cranial border of the upper lobe bronchus and define the apico-anterior trunk. The azygos vein is often closely related to the bronchus and can be pushed away using a gentle sweeping motion. Long artery forceps are passed around the upper lobe bronchus close to its origin in the plane between the bronchus and the associated node packet (*Figure 7*). It should be appreciated that the apico-anterior trunk lies immediately anterior to the bronchus, but sometimes separated by station 11 right upper lobe lymph nodes. The bronchus is transected at this level using an endoscopic linear stapling device. It is not necessary to inflate the lung to test that the correct

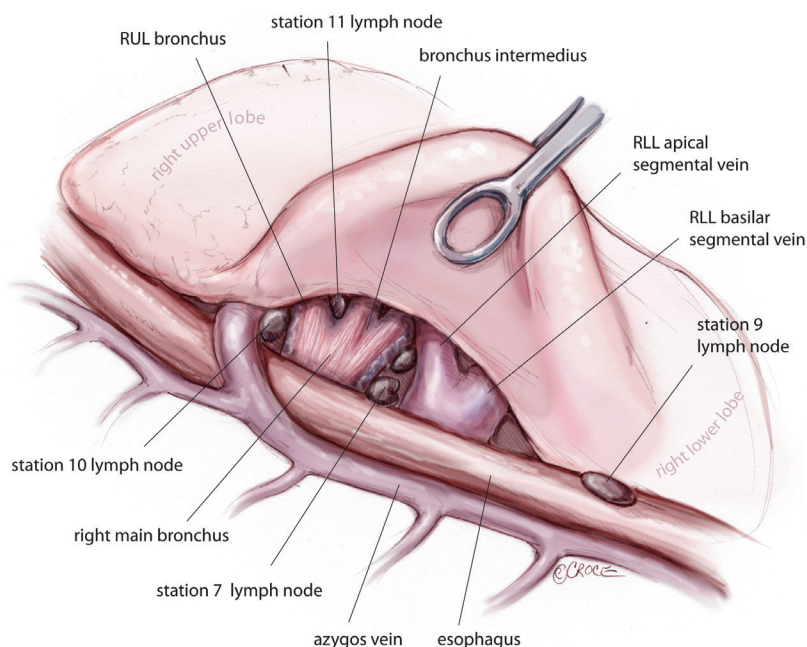


Figure 5 Viewed from the posterior hilum, the ‘landmark’ station 11 lymph node is exposed by clearing the lung tissue away from the bronchus intermedius and the upper lobe bronchus.

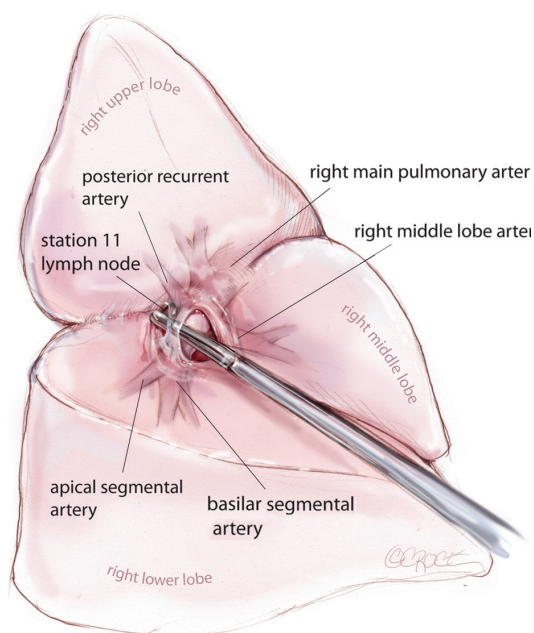


Figure 6 From the anterior port site, dissection forceps are passed gently immediately superficial and posterior to this station 11 ‘landmark’ lymph node, where it has been identified in the oblique fissure. When the lung is retracted anteriorly, the tips of the forceps will emerge through the incised posterior pleural reflection, above the ‘landmark’ lymph node between the right upper lobe bronchus and the bronchus intermedius, as seen in the previous figure.

bronchus is being divided, as the vision is invariably excellent via the posterior approach and the re-inflated lung may subsequently obscure the view for remainder of the resection.

Following division of the bronchus, the feeding vessels to the right upper lobe bronchus node packet are clipped and divided, allowing the nodes to be swept up into the operative specimen. Clasping the distal end of the transected bronchus with an endoscopic toothed grasper, the upper lobe can be reflected upwards. The posterior segmental artery is divided at this stage if not already dealt with and the apical and anterior segmental arteries or common stem artery are carefully cleaned, dissected out (*Figure 8*) and divided with an endoscopic stapler. Finally, the lung is retracted posteriorly facilitating dissection of the superior vein. This can be divided from either the posterior or anterior aspect as convenient, taking care in either case to identify clearly and preserve the middle lobe vein. The transverse fissure is then divided. The middle lobe artery is most easily identified and protected if the stapling device is first passed through the inferior port and fired from posterior to anterior. Division of the transverse fissure is then completed, passing the stapling device through the anterior port. The inferior pulmonary ligament is divided to facilitate expansion of the right lower lobe.

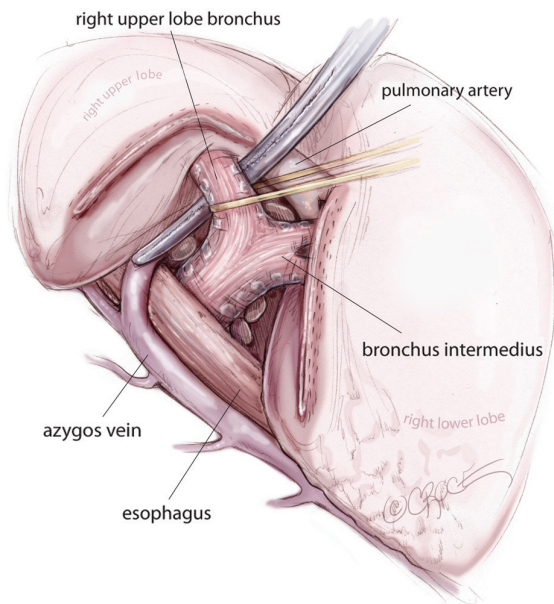


Figure 7 Long artery forceps are passed around the upper lobe bronchus close to its origin in the plane between the bronchus and the associated node packet.

Right lower lobectomy

Having identified the PA in the oblique fissure and divided the posterior oblique fissure, the pulmonary artery is then divided either in one or separately as a basal trunk artery and the apical segmental artery to the lower lobe. The space between the superior and inferior veins is developed and a long clamp is passed into this space emerging anterior to the PA in the oblique fissure. A sling is passed into this plane and the anterior oblique fissure is then divided. The lower lobe is mobilized by dividing the inferior pulmonary ligament. The inferior vein is dissected free from surrounding tissue and divided using an endoscopic linear stapling device. The bronchus is identified and the bronchial vessels are clipped proximally. Lymph nodes are cleared from its medial and lateral margins. The lower lobe bronchus is divided through its apical and basal branches preserving airflow to the middle lobe. The middle lobe bronchus must be visualized prior to stapling.

Right middle lobectomy

The PA is identified and the anterior oblique fissure is divided as for right lower lobectomy. The vein, bronchus

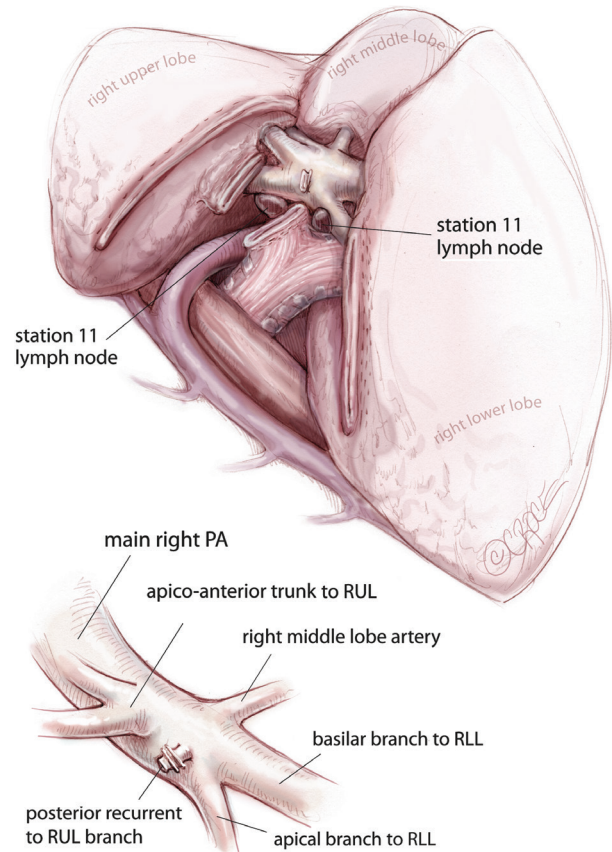


Figure 8 The posterior segmental artery is divided at this stage if not already dealt with and the apical and anterior segmental arteries or common stem artery are carefully cleaned, dissected out.

and arteries are then seen clearly, like three little 'soldiers' when the right upper lobe is retracted superiorly and are divided in sequence. The transverse fissure is divided as described for right upper lobectomy.

Left upper lobectomy

The PA is identified in the oblique fissure and the posterior aspect of the oblique fissure is divided in a similar way to the right side. The arterial branches to the left upper lobe are then divided sequentially. Division of the anterior aspect of the fissure is completed in similar manner to that on the right side. It is important to develop the space between the pulmonary veins and central to the fused anterior oblique fissure thoroughly. When passing a clamp through the utility incision and under the fused fissure, the surgeon will feel the lower lobe bronchus and should allow the clamp to pass superficially in order to preserve the airway to the

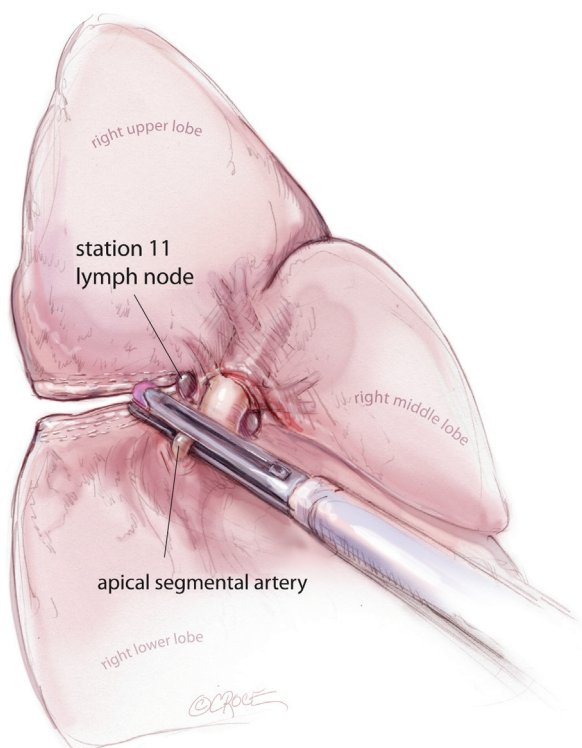


Figure 9 The apical segmental artery is divided using a vascular stapler.

lower lobe. Gentle blunt dissection is used to separate the superior pulmonary vein from the anterior surface of the bronchus. A long clamp is passed around the base of the bronchus, taking particular care not to damage the PA. Retraction of the PA using a mounted pledget may be helpful. A sling is passed around the bronchus and used to elevate it (crane maneuver) in relation to the pulmonary artery and create a space via which an endoscopic stapling device can be inserted to divide the bronchus. The superior vein is cleaned and divided. The inferior pulmonary ligament is divided up to the level of the inferior vein to facilitate expansion of the lower lobe.

Left lower lobectomy

As on the right side, having identified the PA and divided the posterior aspect of the oblique fissure, the arterial branches are identified. The anterior portion of the oblique fissure is divided as for left upper lobectomy and the arterial supply divided with an endostapler. The inferior pulmonary ligament is divided up to the level of the inferior pulmonary vein. The margins of the vein are clearly delineated and it

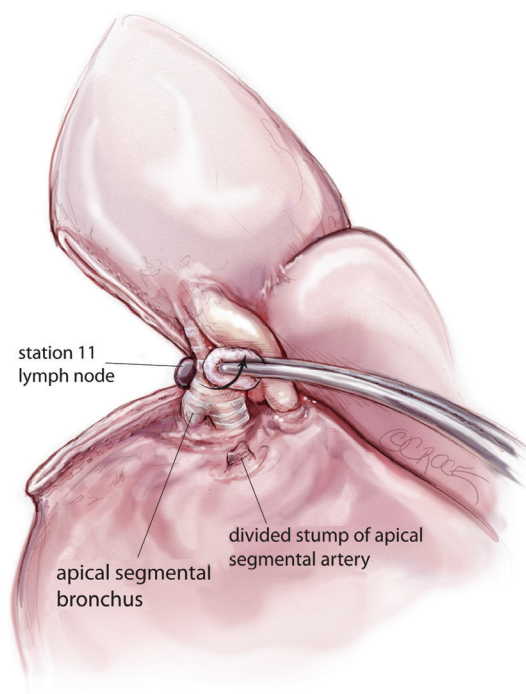


Figure 10 Once the apical artery is divided, the pulmonary artery is pulled forward to reveal the bronchus intermedius posteriorly and its bifurcation to the lower lobe, i.e., apical and basilar segmental bronchi.

is then divided. Bronchial vessels are clipped proximally and divided, and the lymph node chains are cleared off the medial and lateral aspects of the bronchus, which is divided at its base.

Segmentectomy-‘three-directional’ stapling technique

Apical segmentectomy of the lower lobe is a common procedure. In this article, I describe the technique of thoracoscopic apical segmentectomy using a ‘three-directional’ stapling technique. Having identified the PA in the oblique fissure and divided the posterior oblique fissure, the pulmonary artery is then prepared using blunt dissection by ‘dragging’ the lung tissue distally along the pulmonary artery until its bifurcation to apical and basal segmental branches is clearly seen. The apical segmental artery is divided using a vascular stapler (*Figure 9*). Once the apical artery is divided, the PA is pulled forward to reveal the bronchus intermedius posteriorly and its bifurcation to the lower lobe, i.e., apical and basilar segmental bronchi (*Figure 10*). The apical segmental bronchus is divided with a stapler, passed through the anterior access port. Lymph

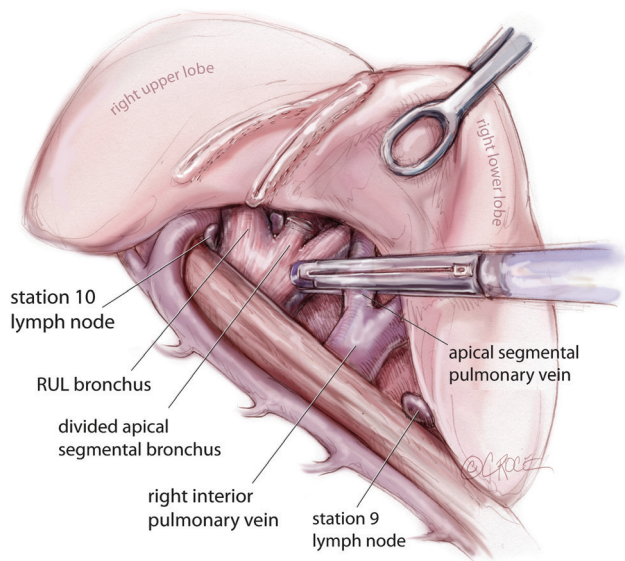


Figure 11 The apical segmental vein is divided using an endoscopic linear stapling device.

nodes are cleared from the medial and lateral margins of the bronchus. The lower lobe is then retracted forward to expose the posterior hilum. The lower lobe is further mobilized by dividing the inferior pulmonary ligament. The inferior vein is dissected free from surrounding tissue and the confluence of the apical and basilar segmental veins is developed by ‘pushing’ the lung tissue distally using a small pledget mounted on the tips of long dissecting forceps. The apical segmental vein is divided using an endoscopic linear stapling device (*Figure 11*).

Finally, the apical segment is separated from the basilar tri-segments using a ‘three-directional’ stapling technique. It is clear that each lobe is a three-dimensional structure or pyramidal in shape. By simply compressing the lung tissue and dividing it using a heavy stapling device in one plane, not only is it not possible to achieve an anatomical segmentectomy, but also the staples may not be able to hold the thick lung tissues together, resulting in prolonged air-leak. It is important to first orientate the segment to its anatomical position. The ‘three-directional’ stapling technique requires the first stapler coming from the anterior access incision towards the distal limit of the apical segmental bronchus, compressing the interlobar surface with the anterior surface of the lobe; the second stapler coming from the posterior direction towards the distal limit of the segmental bronchus, compressing the lateral and posterior surfaces of the lobe; and the third

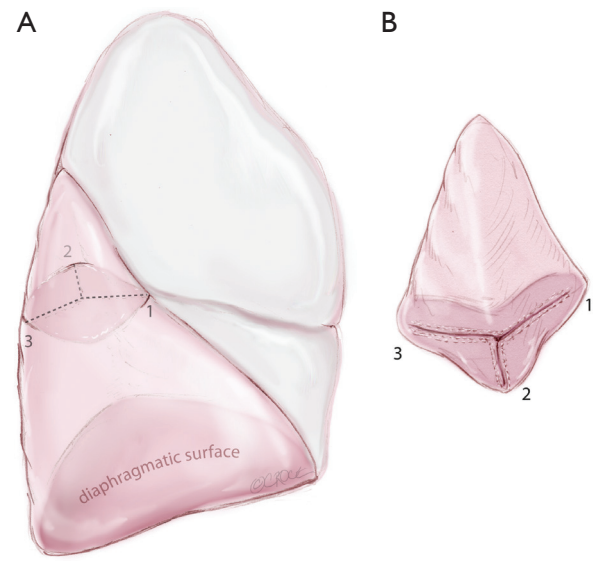


Figure 12 (A) The ‘three-directional’ stapling technique requires the first stapler coming from the anterior access incision towards the distal limit of the apical segmental bronchus, compressing the interlobar surface with the anterior surface of the lobe; the second stapler coming from the posterior direction towards the distal limit of the segmental bronchus, compressing the lateral and posterior surfaces of the lobe; and the third stapler dividing the lung parenchyma medial and parallel to the apical segmental bronchus, hence completing the segmentectomy in three directions; (B) the final apical segmentectomy specimen should be pyramidal in shape.

stapler dividing the lung parenchyma medial and parallel to the apical segmental bronchus, hence completing the segmentectomy in three directions (*Figure 12A*). The final apical segmentectomy specimen should be pyramidal in shape with individually divided segmental artery, bronchus and vein (*Figure 12B*). All hilar and segmental level nodes relevant to the resected segment are excised. At mediastinal level either extensive sampling or lymphadenectomy is preferred.

Postoperative care

A size 32 Fr apical drain is placed through the mid-axillary line port site and is usually removed on the first postoperative day subject to a satisfactory chest radiograph and aerostasis. Patients are typically nursed on the general thoracic ward after immediate extubation. Analgesia is provided using a patient-controlled analgesia pump and a local anaesthetic paravertebral catheter. Early mobilization

is strongly encouraged with the availability of physiotherapy seven days per week, and discharge as early as postoperative day 2 or 3 is often possible.

Comments

The posterior approach is a safe, reliable and reproducible approach to VATS lobectomy and segmentectomy. VATS has been shown to compare favorably with open thoractomy in terms of immediate post-operative recovery and is considered to be oncologically equivalent. Our cross-sectional survey on 838 thoracic surgeons worldwide showed that 95% of surgeons who performed VATS agreed with the CALGB definition of 'true' VATS lobectomy; 92% of surgeons who did not perform VATS were prepared to learn this technique, but were hindered by limited resources, exposure and mentoring (5). Majority of thoracic surgeons believed advanced VATS techniques should be incorporated into thoracic surgical training and for more standardized workshops to be made available. A recent consensus from 50 major minimally invasive thoracic surgeons showed that increased use of VATS techniques for lobectomy and segmentectomy would be highly desirable (1).

Cite this article as: Yan TD. Surgical atlas of thoracoscopic lobectomy and segmentectomy. *Ann Cardiothorac Surg* 2014;3(2):183-191. doi: 10.3978/j.issn.2225-319X.2014.03.11

Acknowledgements

Disclosure: The author declares no conflict of interest.

References

1. Yan TD, Cao C, D'Amico TA, et al. Video-assisted thoracoscopic surgery lobectomy at 20 years: a consensus statement. *Eur J Cardiothorac Surg* 2014;45:633-9.
2. Swanson SJ, Herndon JE 2nd, D'Amico TA, et al. Video-assisted thoracic surgery lobectomy: report of CALGB 39802--a prospective, multi-institution feasibility study. *J Clin Oncol* 2007;25:4993-7.
3. Yan TD, Black D, Bannon PG, et al. Systematic review and meta-analysis of randomized and nonrandomized trials on safety and efficacy of video-assisted thoracic surgery lobectomy for early-stage non-small-cell lung cancer. *J Clin Oncol* 2009;27:2553-62.
4. Cao C, Manganas C, Ang SC, et al. Video-assisted thoracic surgery versus open thoracotomy for non-small cell lung cancer: a meta-analysis of propensity score-matched patients. *Interact Cardiovasc Thorac Surg* 2013;16:244-9.
5. Cao C, Tian DH, Wolak K, et al. Cross-sectional survey on lobectomy approach (X-SOLA). *Chest* 2014. [Epub ahead of print].

Video-assisted thoracoscopic microthymectomy

Joel Dunning

Department of Thoracic Surgery, James Cook University Hospital, Middlesbrough, UK

Introduction

There is a wide range of techniques that may be employed in order to achieve a minimally invasive thymectomy. In our journey through the range of techniques available, we had at the core of our ethos the principles laid out by the International Thymic Malignancy Interest Group (ITMIG) in 2011, which requires an *en bloc* thymectomy for all thymomas, including perithymic fat and cervical poles. Furthermore, patients with myasthenia gravis are required to undergo an extended thymectomy must be performed, including the mediastinal pleura, pericardiophrenic fatty tissue and dissection of the aorto-pulmonary window (1). The Myasthenia Gravis Foundation of America have also graded the completeness of thymectomy and provided a classification system, ranging from a T1. We are mindful of the need to achieve at least a T2b video-assisted thoracoscopic (VATS) extended thymectomy for myasthenic patients (2). In addition, we have been particularly impressed by subxiphoid approaches to thoracic surgery. Early descriptions in thoracic surgery were described by Mineo and colleagues (3,4) for metastasectomy, where two ports were placed in the intercostal spaces. The xiphisternum was then resected and an 8-cm vertical incision was made in the linea alba allow entry of the surgeons hand into the hemithorax in order to palpate the whole lung for metastases, as well as the contralateral hemithorax. More recently this approach has been replicated but with a single subxiphoid approach, avoiding all incisions between the intercostal spaces and using a Covidien single incision laparoscopic surgery (SILS) port and carbon dioxide (CO₂) to perform bilateral metastasectomy (5). Cardiac surgery has also been performed using a subxiphoid-only approach by Mark Levinson, including multi vessel off pump coronary bypass and atrial septal defect repairs, using a 7-cm subxiphoid incision and a sternal elevator (6,7). Subxiphoid surgery has been extended to lobectomy of every lobe by Liu *et al.* from Taiwan using a sternal elevator rather than CO₂ (8). They have also performed segmentectomies in this fashion. Resection of anterior mediastinal masses have been described with a subxiphoid incision (9) and thymectomy

has also been performed using a single subxiphoid approach (10). This has been achieved using the SILS port and CO₂, but also required a Kirschner wire in the upper sternum for sternal elevation.

Therefore, we aimed to reduce the magnitude of our own incisions both in lobectomy and thymectomy by using a subxiphoid utility port. However, subxiphoid-only surgery is technically very demanding as it is a considerable change compared to our usual multiport approach. In addition, we felt that this compromised safety and vision significantly in our hands. Subsequently, we have replicated our traditional VATS approaches but with a subxiphoid utility incision, which has allowed us to restrict ourselves to 5-mm ports rather than our usual 12-mm ports.

Operative techniques

Positioning

The patient is supine and the surgeon and assistant are by the patient's side. If the patient has a thymoma that is more on the left side or near the left phrenic nerve, then we will start the operation on the left side (*Figure 1A*). However, for patients with non-thymomatous myasthenia gravis and in general, we will typically start the procedure in the right hemithorax (*Figure 1B*).

Port insertion for microthymectomy

The intercostal spaces range in size from 7-10 mm, and therefore large ports and instruments may easily cause damage to intercostal nerves, causing post-thoracostomy pain. Most large stapling devices require either a 12-mm or a 15-mm port for access, and thus in a standard VATS lobectomy 12 mm ports routinely used. Once a subxiphoid port is utilized, it may quickly be found that there is no necessity for large ports in the chest. In addition, high quality 5-mm cameras are now available and there is therefore no longer any need for 10-mm cameras in routine practice. Thus, our approach is as follows.

The computed tomography (CT) scan is assessed and

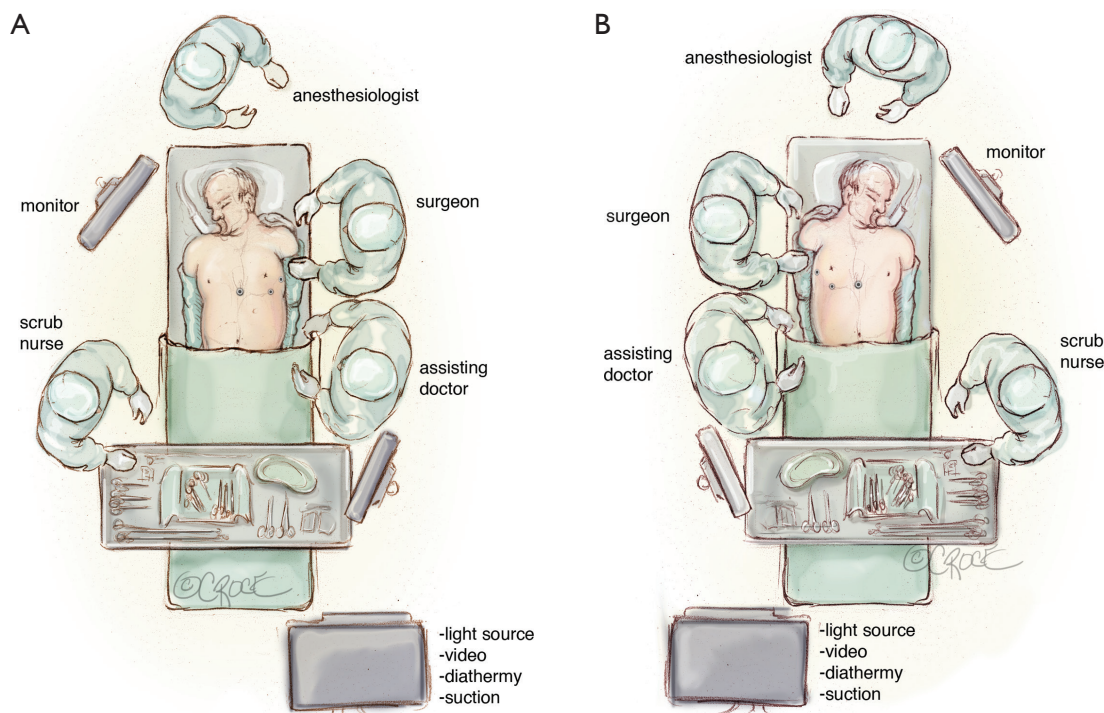


Figure 1 (A) The positioning for a left sided microthymectomy. This approach is used for thymomas that are predominantly on the left side of the mediastinum and those that are likely to be near to the left phrenic nerve; (B) the positioning for a right sided microthymectomy. This approach is the usual approach for non-thymomatous myasthenia gravis resections, and thymomas or anterior mediastinal masses that are predominantly to the right of the midline.

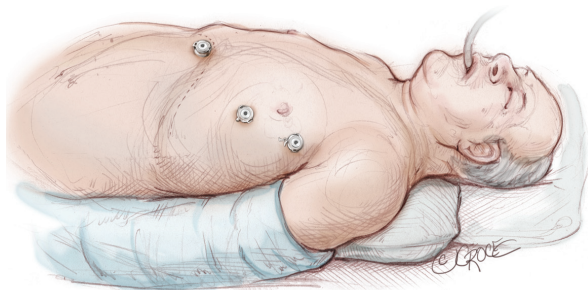


Figure 2 Port placement for a left microthymectomy. Two 5-mm ports are placed in the 5th and 7th intercostal spaces. Once the mediastinal fat is cleared from the subxiphoid space the Subxiphoid port is created.

this guides the placement of the two 5 mm intercostal ports. *Figure 2* demonstrates the position of the left sided ports. However, in non thymomatous myasthenia gravis or in more right-sided thymomas, we prefer to approach from the right hemithorax due to the increased space on this side (*Figure 3*). The patient is positioned supine,

often with a support under the left scapula in a left sided approach. A single lumen tube is used, as we use CO₂ to create space in the anterior mediastinum bilaterally, so that single lung isolation is not required. The CO₂ is set at 8 mmHg at a maximum flow rate of 8 litres per minute and reduced if there is hypotension, high airway pressures or hypercarbia. As a finger cannot be first inserted into the chest for a 5-mm port, we use a disposable plastic 5-mm port, which has a clear central trocar to enter the chest. (*Figure 4*). The CO₂ is attached to the side arm and a 5-mm straight camera is inserted into the trocar. An incision is made over the skin of the 5th space in the anterior axillary line, and under screen vision and CO₂ insufflation, the trocar is pushed into the chest once ventilation has been paused. The pleura and then the lung are seen on the screen and further advancement is paused as the lung is pushed away by the CO₂. The port is then inserted safely into the chest. We have a camera cover that facilitates easy exchange with the straight and 30 degree cameras, and thus we now change to the 30 degree camera for the remainder of the procedure. After CO₂ insufflation

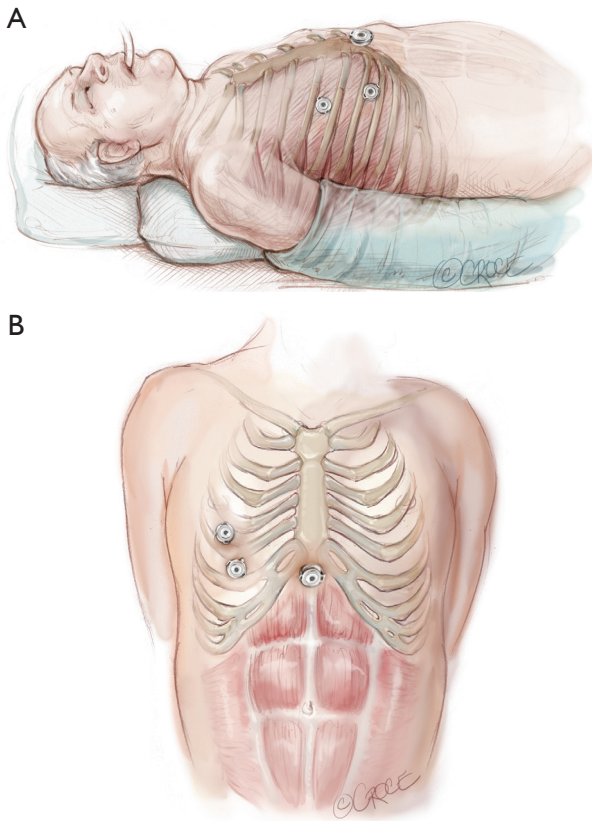


Figure 3 (A) Demonstration of port placement for a right sided microthymectomy. Exact port placement is sometimes dependent on the size and shape of the patient. Here a subxiphoid port is shown with ports in the 4th and 6th intercostal spaces; (B) anteroposterior view of the port placement for a right sided microthymectomy.

has pushed the diaphragm inferiorly, a second port is then placed in the mid clavicular line, usually in the 7th intercostal space. A 5-mm dissecting peanut is then used to push the mediastinal tissue away from the back of the inferior sternum in preparation for the subxiphoid incision. A 2-cm vertical incision is then made below the xiphisternum and down to the linea alba. The linea alba is divided by electrocautery for 2 cm and then a finger is inserted and pushed up vertically under the xiphisternum and body of the sternum. The finger is then moved towards the camera in the chest and is easily seen. Once the finger has entered the chest cavity, it is replaced by a 10-mm CO₂ port. The subxiphisternal port is then used for a hook diathermy, 5-mm SILS endo dissector or 5-mm peanut to clear the thymus from the retrosternal space, with a three-

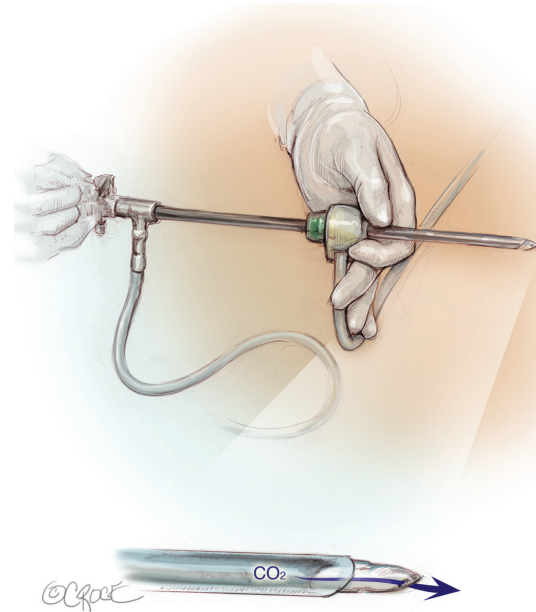


Figure 4 The 5 mm camera is placed into the clear trocar in the middle of the 5 mm port. We advocate the use of a port such as the Allied medical Kii-Fios first entry port with a clear central trocar so one is able to watch chest entry. Also, this trocar has a fenestration 2 mm from the tip for CO₂, so insufflation to push the lung away occurs almost immediately.

port approach.

Conduct of the thymectomy

With the 30 degree camera in the lower 5-mm port, the other two ports are used to dissect the thymus away from the sternum by following a line just medial to the internal mammary artery (IMA), up to the IMA vein. The thymus and thymic fat are removed from the diaphragmatic surface and the phrenic nerve closest to the camera is released using bipolar cautery. Further specifiers could be provided or 5 mm endoscopic scissors. The thymus is lifted anteriorly and released from the pericardium. A very low threshold exists for obtaining a disc of pericardium with the sample, especially in older patients or larger thymomas where the tumor may be more invasive in nature. If approaching from the left hemithorax, the left IMA (LIMA) vein is followed superiorly and then posteriorly until it inserts into the innominate vein (*Figure 5*). The thymus is then stripped off the innominate vein as far as is convenient. The left superior horn can also be followed above the LIMA vein. If approaching from the right hemithorax, the thymus is first

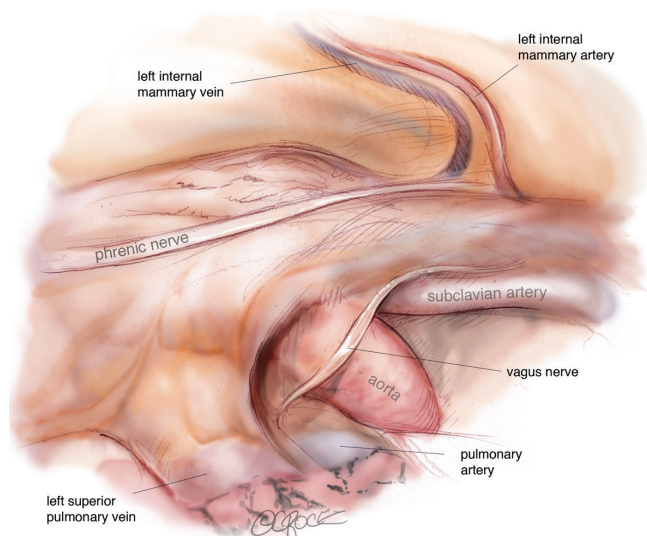


Figure 5 View from the left hemithorax. The left phrenic nerve is anterior to the hilum and it is followed up in the dissection until the left internal mammary vein is found and then medially along the innominate vein.

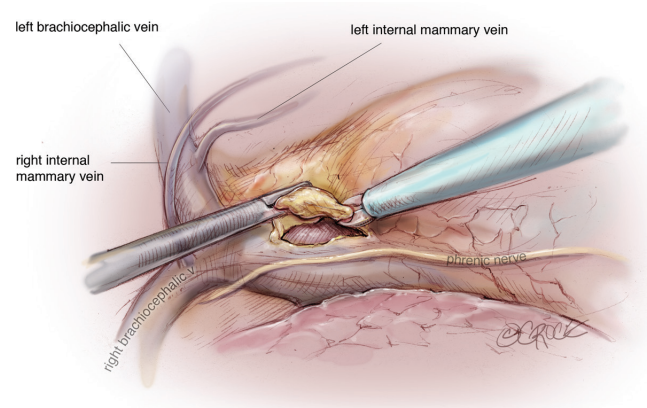


Figure 6 View from the right hemithorax. The first step is to remove the thymus off the right phrenic nerve from inferior to superior, following the superior vena cava until the right internal mammary vein is identified, then the innominate vein is followed across the midline.

stripped off the right phrenic nerve (*Figure 6*). The superior vena cava (SVC) is followed up to the right IMA (RIMA) vein and then across the innominate vein, with clipping of the thymic vein.

The camera is then changed to the subxiphoid port, which facilitates an excellent view of the opposite phrenic

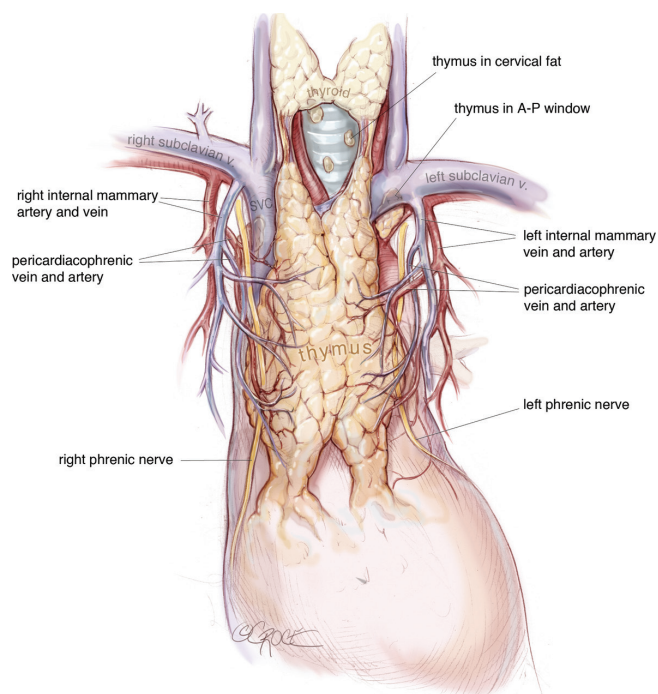


Figure 7 Anterior view of the thymus, demonstrating the vascular supply and the position of the thymic lobes and superior and inferior horns.

nerve. In the case of an initial left chest approach, instruments are still used from the two left-sided 5 mm ports. One is used to elevate the thymus, and a hook diathermy or energy device is used to remove the thymus from the right phrenic nerve. This plane of dissection is followed up the SVC to the RIMA vein and across to the innominate vein. A 5-mm clip may be applied to the thymic vein, which invariably arises from the mid-point of the innominate vein. Vessels arising from the IMA, internal mammary vein, thyrothymic ligament and inferiorly from pericardiophrenic vessels are usually small enough to be divided by diathermy or an energy device. Finally, the right superior horn is released. Additional tissue under the innominate vein is also removed and the view of this process and of the cervical superior horns from the subxiphoid port is excellent. The key vascular anatomy of the thymus is demonstrated in *Figure 7*.

Removal of the thymus

After release of the thymus, it is placed in the left hemithorax, and the area is checked for bleeding. Intercostal nerve

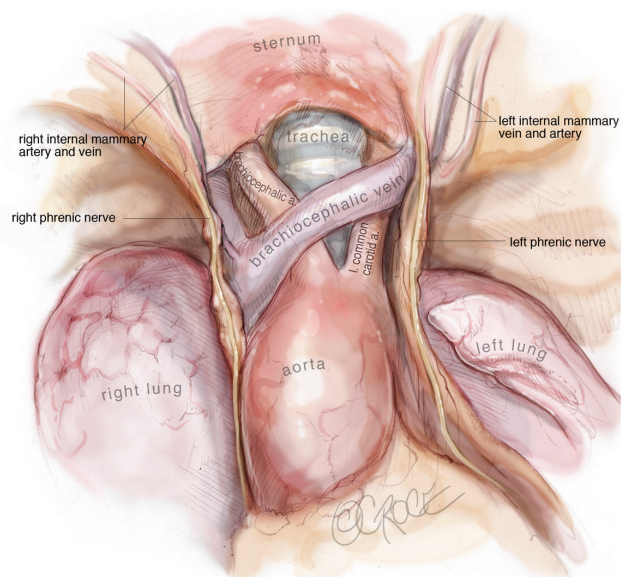


Figure 8 The final subxiphoid view after thymus removal. For complete thymectomy the space above the innominate should be clear of thymus and thymic fat. You will then be able to see the right brachiocephalic, the innominate artery, the trachea and occasionally the left carotid artery. The phrenic nerves will demarcate the lateral borders of the resection.

blocks are placed using a long needle under vision from the subxiphoid port. The sample is only removed as the final intraoperative step, as CO₂ insufflation will be lost once the subxiphoid port is extended to remove the thymus in a retrieval bag. Once removed in a bag, a single size 24 French drain is inserted into the mediastinum. We find that two drains are unnecessary. In addition, the drain establishes the absence of a pneumothorax, as bleeding is invariably minimal with this technique. Once the thymus has been removed in full, one should be able to visualize the remaining anatomy very clearly from the subxiphoid port and fully evaluate the extent of resection (*Figure 8*).

Safety considerations

Throughout the operation, there is a 5-mm suction irrigator available for use. We also have 5-mm dissecting peanuts and 5- and 10-mm endclip applicators available. If a larger vessel bleeds, then pressure can be applied and the suction irrigator can be used to identify the source of bleeding, which can then be grasped prior to application of a clip. If the innominate vein is damaged, then it must be

remembered that this is a low pressure vessel and the patient can be placed in a reverse Trendelenberg position to further reduce the venous pressure. Additional CO₂ insufflation can also collapse small low pressure veins to provide more time to identify the location of bleeding.

Comments

The most important consideration in VATS thymectomy is that the same quality of resection must be achieved as by an open operation. Challenges include adequate visualization of both phrenic nerves and of the superior horns above the innominate vein. If an equivalent resection is achieved as that possible by sternotomy, then the VATS technique will significantly reduce pain compared to sternotomy and speed up recovery. Microthymectomy achieves many of these aims. The subxiphoid port allows an excellent view of both phrenic nerves and the superior horns of the thymus. It also allows painless removal of the sample at the end of the operation. The 5-mm ports allow the surgeon to use a multiport approach that may be more familiar than a uniportal subxiphoid approach. We encourage surgeons to try this approach as one method of performing VATS thymectomy.

Acknowledgements

We are very grateful for the outstanding illustrations provided by Beth Croce.

Footnote

Conflicts of Interest: The author has no conflicts of interest to declare.

References

1. Toker A, Sonett J, Zielinski M, et al. Standard terms, definitions and policies for minimally invasive resection of thymoma. *J Thorac Oncol* 2011;6:S1739-42.
2. Jaretzki A 3rd, Barohn RJ, Ernstoff RM, et al. Myasthenia gravis: recommendations for clinical research standards. Task Force of the Medical Scientific Advisory Board of the Myasthenia Gravis Foundation of America. *Ann Thorac Surg* 2000;70:327-34.
3. Mineo TC, Pompeo E, Ambrogi V, et al. Video-assisted approach for transxiphoid bilateral lung metastasectomy. *Ann Thorac Surg* 1999;67:1808-10.

4. Mineo TC, Ambrogi V, Paci M, et al. Transxiphoid bilateral palpation in video-assisted thoracoscopic lung metastasectomy. *Arch Surg* 2001;136:783-8.
5. Suda T, Ashikari S, Tochii S, et al. Single-incision subxiphoid approach for bilateral metastasectomy. *Ann Thorac Surg* 2014;97:718-9.
6. Levinson MM. Subxiphoid multi-arterial OPCAB: surgical technique and initial case report. *Heart Surg Forum* 2005;8:E303-10.
7. Levinson ML, Fonger J. Minimally invasive atrial septal defect closure using the subxiphoid approach. *Heart Surg Forum* 1998;1:49-53.
8. Liu CC, Wang BY, Shih CS, et al. Subxiphoid single-incision thoracoscopic left upper lobectomy. *J Thorac Cardiovasc Surg* 2014;148:3250-1.
9. Kido T, Hazama K, Inoue Y, et al. Resection of anterior mediastinal masses through an infrasternal approach. *Ann Thorac Surg* 1999;67:263-5.
10. Suda T, Sugimura H, Tochii D, et al. Single-port thymectomy through an infrasternal approach. *Ann Thorac Surg* 2012;93:334-6.

Cite this article as: Dunning J. Video-assisted thoracoscopic microthymectomy. *Ann Cardiothorac Surg* 2015;4(6):550-555. doi: 10.3978/j.issn.2225-319X.2015.11.04

Video-assisted thoracoscopic thymectomy using 5-mm ports and carbon dioxide insufflation

René Horsleben Petersen

Department of Cardiothoracic Surgery, Copenhagen University Hospital, Rigshospitalet, Copenhagen, Denmark

Introduction

The preferred approach for thymectomy has traditionally been a sternotomy. Since the introduction of video assisted thoracoscopic surgery (VATS) thymectomy in the beginning of the 1990s (1), a minimally invasive approach to thymectomy for myasthenia gravis and early stage thymomas has gained widespread popularity. Several minimally invasive approaches to thymectomy have been described; VATS thymectomy from the right side, VATS thymectomy from the left side, bilateral VATS thymectomy (2), cervical thymectomy, subxiphoidal thymectomy (3), uniportal thymectomy (4) and robotic thymectomy (5). The potential benefits of a minimally invasive approach includes better cosmetic results, less postoperative pain, shorter length of stay, earlier return to daily activities, less bleeding and fewer complications overall with similar outcomes for survival, recurrence rate of thymoma and complete remission (CR) for myasthenia gravis (6-8).

Indication

This approach is applicable for patients with myasthenia gravis and/or thymomas up to 5 cm in diameter in clinical Masoaka Koga stage I (9). Either the left or right side can be used with this approach. The right side is preferred since there is a wider intrapleural space than on the left side, where the heart occupies space. Localizing the innominate vein is also easier on the right side, where it fuses with the superior vena cava. The phrenic nerve is localized more posteriorly on the left side, however, and it can be challenging to localize it from the right side. If the thymoma is located on the left-side close to the left phrenic nerve or the aorta-pulmonary window, a left sided approach is therefore preferred. Evidence of unilateral adhesions due to previous thoracic surgery may also influence the choice of side. If a bilateral approach is needed, an additional 5 mm port on the contralateral side can be added. If the thymoma

is located high in the neck, the addition of a cervical incision may be necessary.

Positioning

The procedure is performed under general anesthesia with the patient monitored through an arterial line, and using double-lumen endotracheal intubation and contralateral one-lung ventilation. The patient is placed in the supine position with a 30-degree retroversion (*Figure 1*). The ipsilateral arm is placed over the head of the patient in a holder. Care should be taken to not overextend the shoulder, and thus avoid injury to the brachial plexus (*Figure 2*). The surgeon and the assistant stand on the ipsilateral side of the patient while the scrub nurse stands on the opposite site, using a separate monitor (*Figure 3*). A sternotomy tray is always ready in the operating theatre for a potential conversion.

Port placement

Three 5-mm ports (Versaport, Covidien) along the lateral border of the breast gland are used. The first port is created with a 5-mm skin incision. A dissector is introduced using blunt dissection along the upper edge of the sixth intercostal space in the mid-axillary line in order to create a pneumothorax. A 5-mm port with a trocar is then introduced into the same incision and a 5-mm, 30-degree thoracoscope (Endoeye, Olympus) is used for inspecting the thoracic cavity for potential adhesions and pathology. Carbon dioxide (CO₂) insufflation is installed using a pressure limit of 6–8 mmHg. Under thoracoscopic guidance, a second 5-mm port is bluntly introduced using a trocar into the anterior axillary line in the third intercostal space and a third 5-mm port placed in the midclavicular line into the sixth or seventh intercostal space. This latter incision is expanded at the end of procedure to 1–3 cm according to the size of the specimen to be resected.

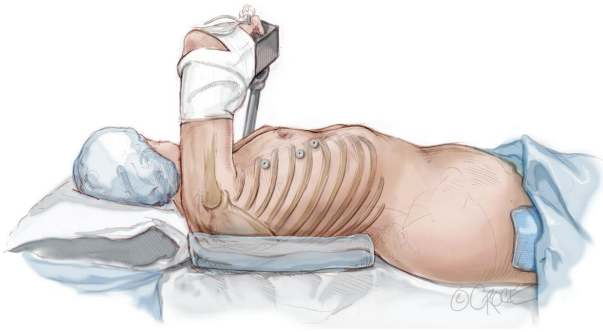


Figure 1 Positioning for a right-sided video assisted thoracoscopic thymectomy.

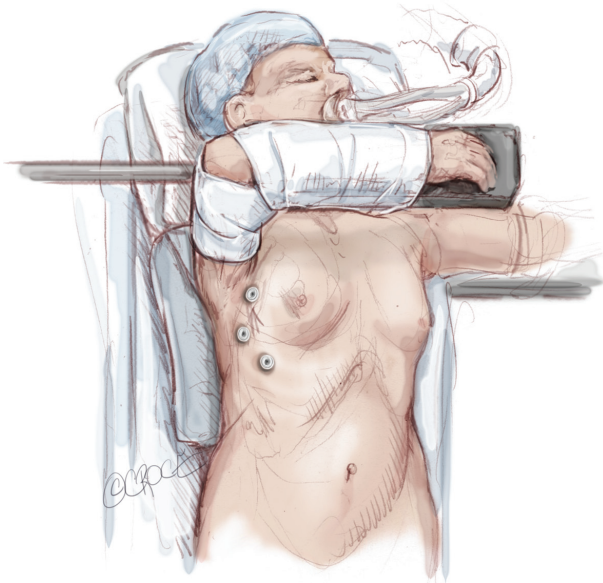


Figure 2 Positioning of the ipsilateral arm in a hanger.

Surgical steps

The entire thymic gland, including the two upper and two lower horns and all the fatty tissue in the anterior mediastinum, is excised in an “*en bloc*” fashion without touching the thymoma according to the recommendations from the International Thymic Malignancy Interest Group (ITMIG) (10). Dissection is performed using a bipolar energy device (LigaSure 5 mm, 35 cm, Covidien) in a clockwise direction on the right side and an anticlockwise direction on the left side. A rotulating crasper (Endo Crasp, Covidien) and 5 mm endopecanuts (Endopecanut, Covidien) are used for retraction. On the right side, the right lower horn is dissected along the right phrenic nerve,

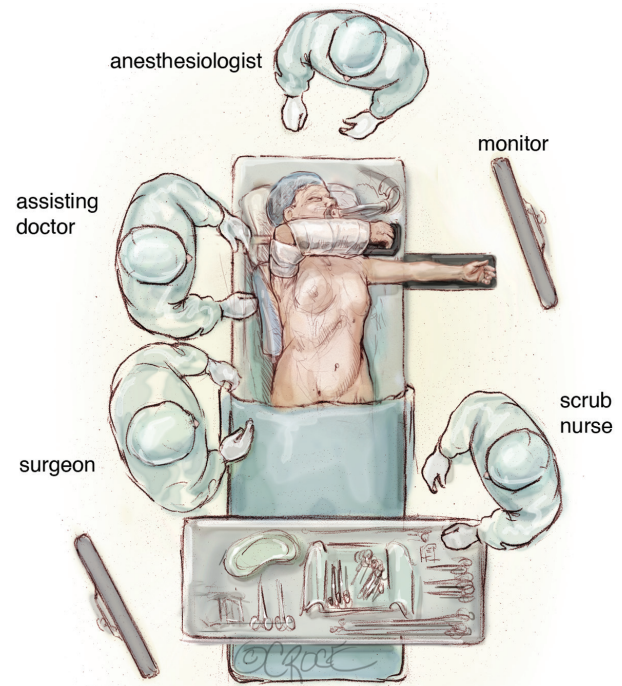


Figure 3 Theatre setup for a right-sided video assisted thoracoscopic thymectomy.

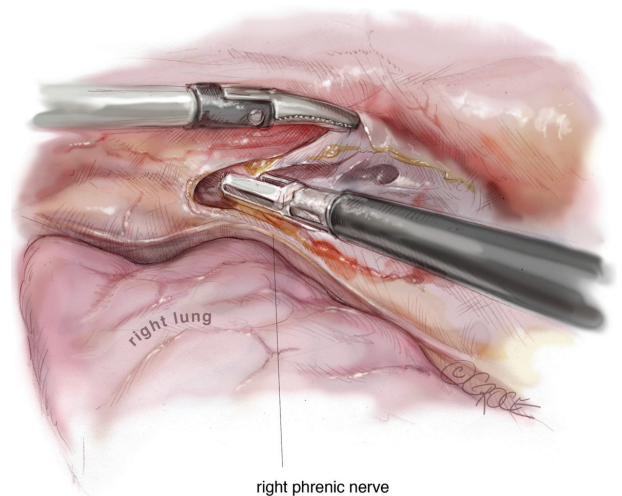


Figure 4 On the right side, the right lower horn is dissected along the right phrenic nerve, the pericardium and sternum.

the pericardium and sternum (*Figure 4*). The dissection is then continued along the right phrenic nerve until the right mammary vein is reached. Continuing the dissection along the superior vena cava until its point of fusion with the innominate vein makes the localization of the latter

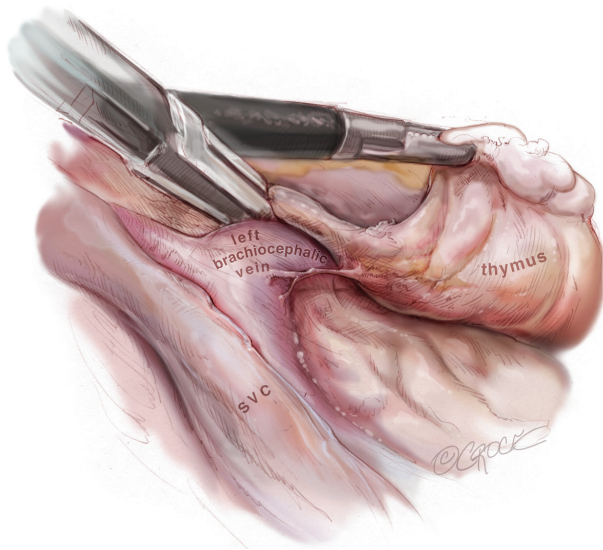


Figure 5 Dissection along the superior vena cava until its fusion with the innominate vein makes localization of the innominate vein on the right side easier than on the left side.

structure easier on the right side easier than on the left (*Figure 5*). The right upper cervical horn is isolated, and while retracting the thymic gland inferiorly, the thyrothymic ligament is divided with LigaSure. The dissection is then continued along and above the innominate vein including all thymic and fatty tissue. Side branches to the innominate vein are divided with LigaSure, using a “double sealing technique”. In this sealing technique, the proximal end near the innominate vein is sealed with LigaSure, but not cut. Sealing and cutting is then performed distal to this point. A hemoclip can be applied, but is rarely needed. The left upper horn is dissected in the same way as the right upper horn and the thymic vein is divided with LigaSure (*Figure 6*). The pleura on the left side is localized and by continuing the dissection posteriorly, the left phrenic nerve can be visualized (*Figure 7*). The dissection is continued inferiorly along the left phrenic nerve while the gland is retracted to the right, and extended along the pleura and pericardium in order to remove the remaining part of the gland and fatty tissue, including the left inferior horn. The pleura on the left side are kept intact for as long as possible to prevent the left lung from occupying operating space. After completing the dissection, the orientation of the specimen is noted. CO₂ insufflation is stopped and the lower 5 mm port is expanded to 1–3 cm according to the size of the specimen. An endobag (LaproSurge) is then introduced into the right thoracic cavity, where there is space and the specimen

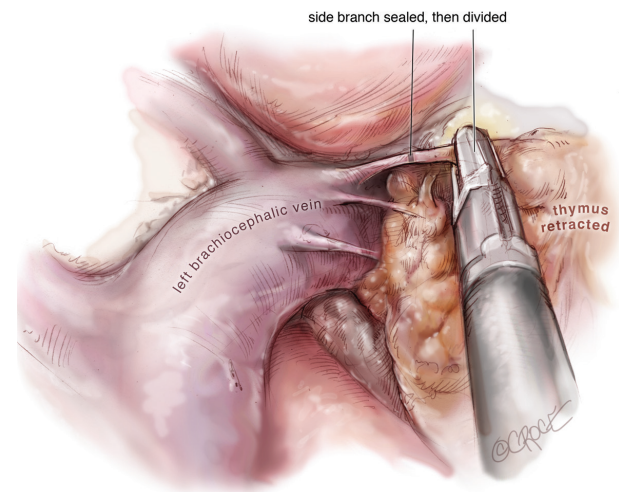


Figure 6 The left upper horn is dissected in the same way as the right upper horn and the thymic vein is divided with LigaSure.

is grasped and placed into the bag. While extracting a thymoma of the thoracic cavity in an endobag, care should be taken not to squeeze the capsule. The specimen is marked with sutures and a drawing is made according to the recommendations from ITMIG (11) (*Figure 8*). Then the specimen is sent for pathology. The two 5 mm incisions are closed using only one suture in the skin. A CH18 chest drain is introduced in lower port and this incision is sutured in three layers using Vicryl 2-0.

Pain management and postoperative care

For pain management, an opioid-sparing multimodal analgesic regimen is used as previously described for VATS lobectomies (12), and consists of paracetamol (1 g + 1 g + 1 g + 1 g), slow-release ibuprofen (800 mg + 800 mg) and gabapentin (300 mg + 600 mg). At the beginning of the procedure, an intercostal block is applied for every port, using a total of 20 mL of bupivacaine (0.5%). An intercostal catheter is introduced sub-pleural into the posterior intercostal space of the lower port, using the Seldinger technique. The catheter is connected to an epidural pump with continuous infusion of 6 mL of bupivacaine/hour (0.25%). Removal of the catheter is usually performed together with chest drain removal. After extubation, the patient is transferred to a recovery room and observed for two hours, and then moved to the ward and mobilized according to enhanced recovery criteria. Usually, the chest drain can be removed the following morning, and if X-ray

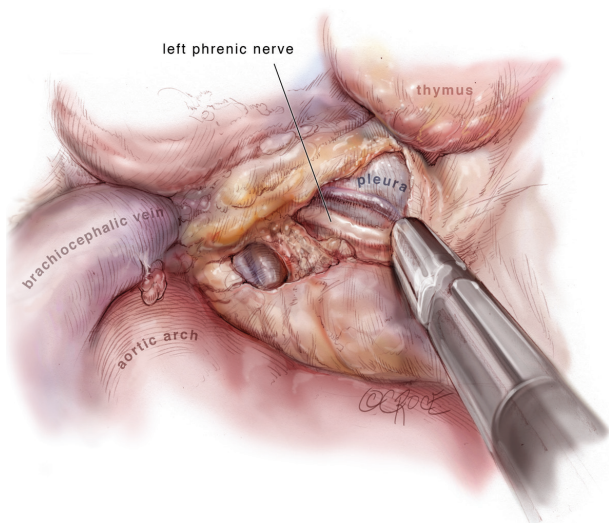


Figure 7 The pleura on the left side is localized, and by continuing the dissection posteriorly the left phrenic nerve can be localized.

is acceptable and pain management is sufficient, the patient is sent home. Patients are seen in the outpatient clinic two weeks after surgery.

Discussion

The potential advantages of this approach compared to sternotomy include better cosmesis, less postoperative pain, shorter length of stay, earlier return to daily activities, less bleeding and fewer complications (6-8). Whether there is any difference in outcome between the many different minimal invasive approaches to thymectomy is unclear and remains to be investigated. The use of 5 mm ports and a 5-mm camera may potentially include less pressure on the intercostal nerve and thus less postoperative pain and possibly less chronic pain. A CH18 chest drain is used for the same reason, accepting that this size may not adequately drain a potential hemothorax, and in this case, another chest drain may be needed. CO₂ insufflation is used to compress the ipsilateral lung and mediastinum, providing great space over the innominate vein and making the dissection of the innominate vein and cervical horns safer. Patients with a comprised cardiac output may not tolerate CO₂ insufflation. In such cases, the pressure can be reduced or CO₂ can be used intermittently for the crucial dissection in the neck. Bipolar electrocoagulation with LigaSure has less lateral thermal spread than monopolar electrocoagulation, allowing for safer dissection along the phrenic nerve and

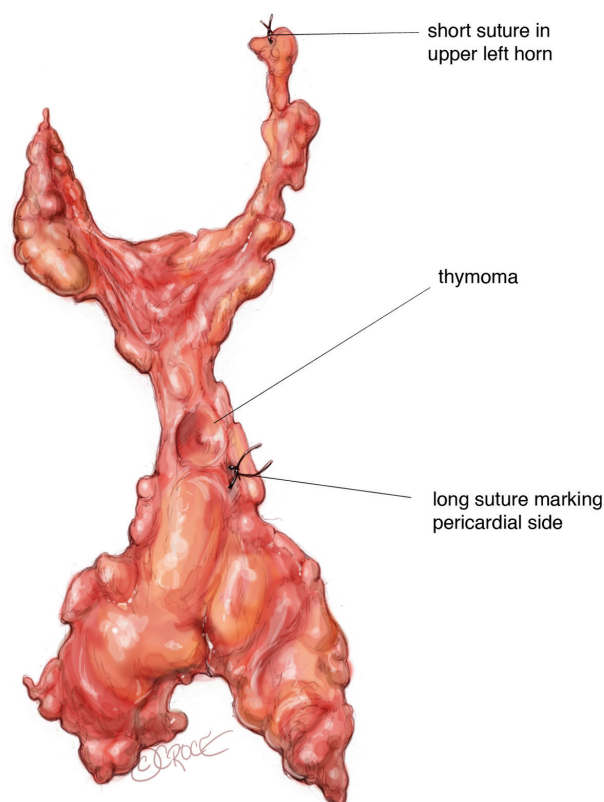


Figure 8 Thymus marked for the pathologist.

greater vessels. Ultrasonic devices can also be used for dissection, but one should be aware about the heat spread from the active plate.

A potential aspect for further development of the technique could involve introducing a subxiphoidal incision for thymomas that are over 5 cm in diameter, thus avoiding compression of the intercostal nerve when extracting these larger tumors from the thoracic cavity.

Acknowledgements

None.

Footnote

Conflicts of Interest: The author is a Speaker for Medtronic, Ethicon, Medela and Takeda.

References

1. Landreneau RJ, Dowling RD, Castillo WM, et al.

- Thoracoscopic resection of an anterior mediastinal tumor. *Ann Thorac Surg* 1992;54:142-4.
2. Liu Z, Yang J, Lin L, et al. Unilateral video-assisted thoracoscopic extended thymectomy offers long-term outcomes equivalent to that of the bilateral approach in the treatment of non-thymomatous myasthenia gravis. *Interact Cardiovasc Thorac Surg* 2015;21:610-5.
 3. Zielinski M, Czajkowski W, Gwozdz P, et al. Resection of thymomas with use of the new minimally-invasive technique of extended thymectomy performed through the subxiphoid-right video-thoracoscopic approach with double elevation of the sternum. *Eur J Cardiothorac Surg* 2013;44:e113-9; discussion e119.
 4. Wu CF, Gonzalez-Rivas D, Wen CT, et al. Single-port video-assisted thoracoscopic mediastinal tumour resection. *Interact Cardiovasc Thorac Surg* 2015;21:644-9.
 5. Rueckert J, Swierzy M, Badakhshi H, et al. Robotic-assisted thymectomy: surgical procedure and results. *Thorac Cardiovasc Surg* 2015;63:194-200.
 6. Yuan ZY, Cheng GY, Sun KL, et al. Comparative study of video-assisted thoracic surgery versus open thymectomy for thymoma in one single center. *J Thorac Dis* 2014;6:726-33.
 7. Ye B, Tantai JC, Ge XX, et al. Surgical techniques for early-stage thymoma: video-assisted thoracoscopic thymectomy versus transsternal thymectomy. *J Thorac Cardiovasc Surg* 2014;147:1599-603.
 8. Jurado J, Javidfar J, Newmark A, et al. Minimally invasive thymectomy and open thymectomy: outcome analysis of 263 patients. *Ann Thorac Surg* 2012;94:974-81; discussion 981-2.
 9. Koga K, Matsuno Y, Noguchi M, et al. A review of 79 thymomas: modification of staging system and reappraisal of conventional division into invasive and non-invasive thymoma. *Pathol Int* 1994;44:359-67.
 10. Toker A, Sonett J, Zielinski M, et al. Standard terms, definitions, and policies for minimally invasive resection of thymoma. *J Thorac Oncol* 2011;6:S1739-42.
 11. Dettnerbeck FC, Moran C, Huang J, et al. Which way is up? Policies and procedures for surgeons and pathologists regarding resection specimens of thymic malignancy. *J Thorac Oncol* 2011;6:S1730-8.
 12. Wildgaard K, Petersen RH, Hansen HJ, et al. Multimodal analgesic treatment in video-assisted thoracic surgery lobectomy using an intraoperative intercostal catheter. *Eur J Cardiothorac Surg* 2012;41:1072-7.

Cite this article as: Petersen RH. Video-assisted thoracoscopic thymectomy using 5-mm ports and carbon dioxide insufflation. *Ann Cardiothorac Surg* 2016;5(1):51-55. doi: 10.3978/j.issn.2225-319X.2016.01.02

Extrapleural pneumonectomy and extended pleurectomy/decortication for malignant pleural mesothelioma: the Memorial Sloan-Kettering Cancer Center approach

Valerie W. Rusch

Memorial Sloan-Kettering Cancer Center, Cornell University Medical College, New York, NY 10065, USA

Introduction

Surgical management for malignant pleural mesothelioma (MPM) remains controversial, but because of the limitations of radiation and chemotherapy in this disease, surgery is still an important part of treatment for these patients (1-13). Operations for MPM can be categorized as those performed with either palliative or curative intent. Palliative procedures such as video-assisted thoracoscopy surgery (VATS) and talc pleurodesis control pleural effusions in patients whose overall medical condition precludes definitive resection (14). In such cases, thoracotomy and partial pleurectomy is indicated only when the pleural effusion is loculated and cannot be evacuated by VATS.

Curative intent operations include extrapleural pneumonectomy (EPP) and extended pleurectomy/decortication (P/D). This article provides a brief review of preoperative evaluation and the surgical technique for EPP and P/D (15-17).

Preoperative evaluation

Preoperative evaluation aims to determine whether the patient has potentially resectable tumor and sufficient cardiopulmonary reserve to undergo the planned operation (18-21).

Computed tomography (CT) of the chest and upper abdomen is the primary imaging study to assess the extent of the primary tumor and identify metastatic disease in the peritoneum or the contralateral lung and pleura. Magnetic resonance imaging (MRI) can help determine whether the primary tumor invades the chest wall or diaphragm but our experience suggests that MRI does not add significantly to CT in preoperative staging, especially in an era of routine coronal and sagittal CT imaging (22-27).

Positron emission tomography (PET) adds to CT in staging MPM. It identifies metastatic disease not detected by CT in approximately 10 percent of patients. The standardized

uptake value (SUV) on PET is also an independent prognostic factor for overall survival and is useful in selecting patients for treatment (28-31). We use PET-CT routinely in the initial evaluation of patients with MPM.

Mediastinoscopy is frequently used by some institutions as a staging procedure before EPP because mediastinal nodal metastases (N2 disease) are an adverse prognostic factor in MPM, and because CT and PET are known to be inaccurate in detecting nodal disease (1,21,32-34). However, mediastinoscopy fails to identify N2 disease in some patients because the pattern of nodal metastases from MPM differs from that of lung cancer. Thus, patients may have metastases in the internal mammary or peridiaphragmatic nodes without having involvement of the superior mediastinal nodes. In addition, N2 disease is only one of several important prognostic factors in MPM and does not uniformly identify all patients who have a poor prognosis. At the current time, we do not routinely perform mediastinoscopy as part of the initial staging evaluation for MPM. Mediastinoscopy is perhaps most helpful in identifying N2 disease in patients thought to have T1 tumors on CT who might not otherwise be considered for induction chemotherapy before surgical resection.

Laparoscopy has also been advocated as a staging maneuver before resection because it identifies transdiaphragmatic tumor extension or intra-abdominal metastases (35,36). However, routine laparoscopy is not required in patients whose imaging studies show earlier stage tumors and no intra-abdominal abnormalities.

The assessment of cardiopulmonary reserve is a pivotal part of the preoperative evaluation for EPP. Pulmonary function testing (PFTs) should be performed, including a diffusion capacity (DLCO), because MPM patients who have had asbestos exposure often have underlying interstitial lung disease. When EPP is being considered, a quantitative ventilation/perfusion (V/Q) lung scan should also be done to help calculate the patient's postoperative pulmonary

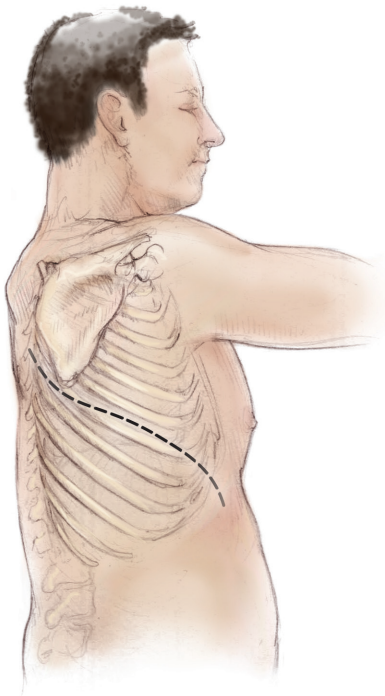

Figure 1 Line of incision (extended posterolateral thoracotomy incision).

function.

Most MPM patients are older and have medical co-morbidities, especially underlying cardiovascular disease (20,36-38). An EPP places patients at high risk for myocardial ischemia because of intra-operative blood loss and postoperative fluid shifts. Therefore, some form of stress testing should be considered preoperatively.

In summary, our routine preoperative evaluation of patients being considered for EPP includes a CT scan of the chest and upper abdomen, a PET-CT scan, complete PFTs, a quantitative V/Q scan, and usually, some form of stress testing. Additional evaluation including MRI, laparoscopy, mediastinoscopy or endobronchial ultrasound (EBUS) is performed selectively.

Surgical technique for EPP

A video in another section of this issue illustrates the technique for left EPP. This chapter describes the step-by-step technique for right and left EPP and for extended P/D.

Preparation, positioning and incision

Preoperatively, an epidural catheter is placed for

postoperative analgesia. After induction of general anesthesia, a double lumen endotracheal tube is inserted. In addition to standard intra-operative monitoring (arterial line, pulse oximetry), a central venous catheter (CVC) is inserted to help manage peri-operative fluid shifts in patients undergoing EPP. A CVC is not generally used for extended P/D.

The patient is placed in the lateral decubitus position. Initial exploration is performed via a standard posterolateral thoracotomy incision. Once it is determined that the patient has resectable tumor without diffuse invasion of the chest wall, the incision is extended as an S-shaped thoracotomy with a long anterior component down towards the costal margin providing exposure for diaphragmatic resection and reconstruction (*Figure 1*). Some surgeons add a second small posterior thoracotomy incision at the level of the eleventh rib to provide exposure to the costophrenic sulcus (39) but this causes more pain and chest wall edema and does not significantly improve exposure. If postoperative hemithoracic radiation is planned there is no need to excise previous chest wall incisions, because the radiation treats potential tumor implants. Both the latissimus dorsi and the serratus anterior muscles are divided. Some authors recommend using a median sternotomy rather than a thoracotomy, especially for right sided resection (40). However, this approach does not provide as much exposure for resection and reconstruction of the posterior aspect of the diaphragm and is not used at Memorial Sloan-Kettering Cancer Center (MSKCC).

Technique of resection

The sixth rib is excised to expose to the extrapleural plane. The intercostal muscles are carefully preserved for reclosure at the end of the operation. This approach is slightly lower than for a standard pulmonary resection to facilitate exposure of the diaphragm. Blunt dissection is performed in the extrapleural plane freeing the parietal pleura from the endothoracic fascia using a sweeping motion of the hand (*Figure 2*) up to apex of the chest, then down to the diaphragm, anteriorly to the pericardium, and posteriorly to the spine (*Figure 3*). Hemostasis is obtained as the dissection is performed to prevent substantial blood loss from the chest wall. The most effective hemostatic tool for this is the Tissue Link (Tissue Link Medical, Inc., Dover, NH). Once the parietal pleura is mobilized away from the chest wall, a chest retractor is inserted, and dissection continues under direct vision mobilizing the pleura circumferentially

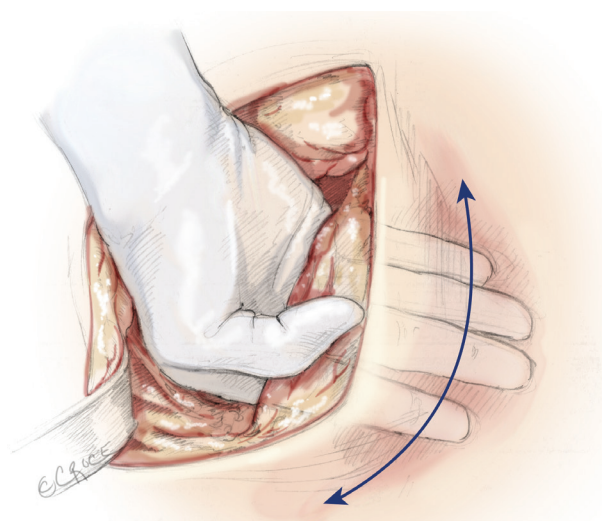


Figure 2 Extra-pleural plane developed using blunt dissection with the palm facing upwards against the ribs in a side-to-side sweeping motion.

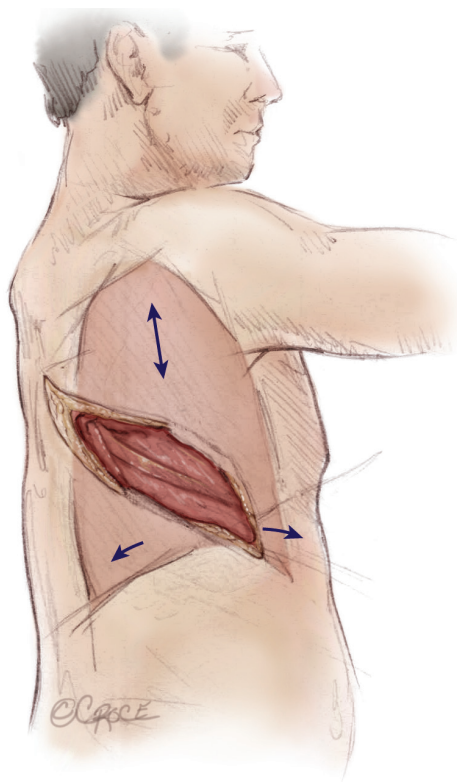


Figure 3 Before the chest retractor is inserted, the pleura is mobilized away from the chest wall to the apex of the chest superiorly, to the sternum anteriorly, to the spine posteriorly and to the diaphragm inferiorly.

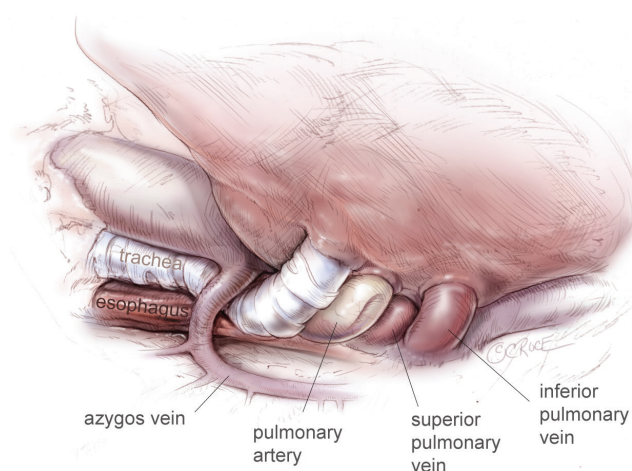


Figure 4 The mediastinal pleural tumor is mobilized away from the underlying mediastinal structures exposing the main bronchus and hilar vessels.

away from the mediastinum. On the left side, care is taken to identify the plane between the tumor and the adventitia of the aorta and the esophagus. On the right side, dissection along the superior vena cava must be performed very gently. In some patients, there is a clean plane of dissection between the mediastinal pleura and the pericardium. In others, this plane is obliterated and the anterior mediastinal pleura has to be resected en-bloc with the pericardium later in the operation. After the pleura and lung are completely mobilized in the upper half of the chest, exposing the superior and posterior aspects of the hilum, an en-bloc dissection of the subcarinal lymph nodes is performed for staging purposes and to expose the main-stem bronchus (*Figure 4*).

The diaphragmatic tumor is then resected. There is always a palpable “edge” laterally between the tumor and normal diaphragmatic muscle or peritoneum at the level of the costophrenic sulcus. This plane is developed and the tumor mobilized along its diaphragmatic surface by blunt dissection similar to a Kocher maneuver. Once mobilized from the posterior and lateral costophrenic angles, the tumor is rotated up into the thoracotomy incision, rolling it back upon itself, and placing strong traction on the diaphragm (*Figure 5*). If the involvement of the diaphragm is extensive, it is removed entirely, peeling it away from the peritoneum. If the involvement of the diaphragm is superficial, dissection can be carried through the diaphragmatic muscle using the electrocautery (*Figure 5*). Every effort is made not to enter the peritoneum because

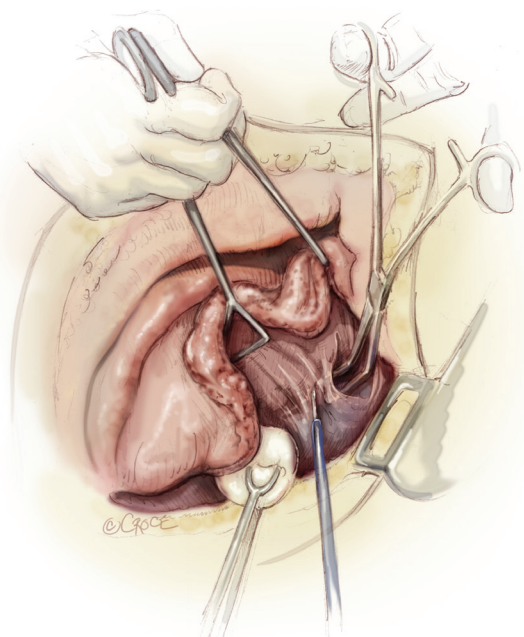


Figure 5 Resection of diaphragmatic pleura with diaphragm muscle fibers.

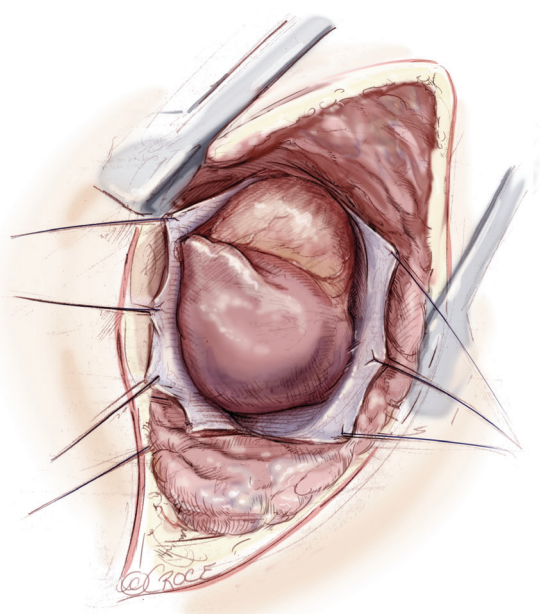


Figure 7 If pericardial resection is required, this is done after the pleural tumor has otherwise been completed in order to minimize intraoperative hemodynamic changes. Traction sutures are placed on the pericardium, as the resection is performed to prevent it from retracting towards the contralateral hemithorax.

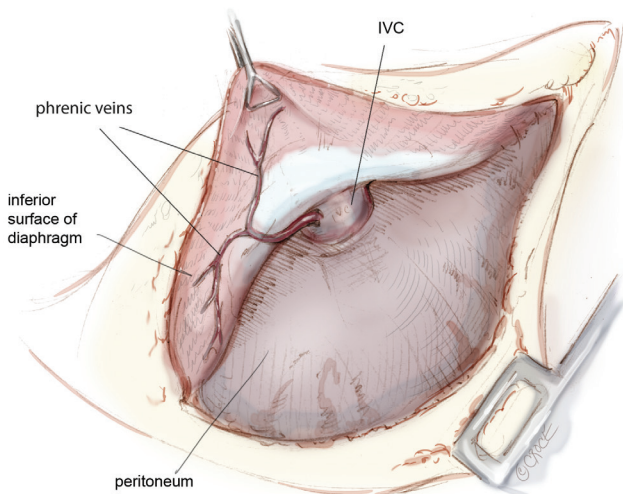


Figure 6 For right-sided resections, it is important to identify the phrenic veins draining from the diaphragm directly into the inferior vena cava.

of the propensity of MPM to produce tumor implants. However, entry into the abdomen at the level at the central tendon is unavoidable because of the fusion of tissue planes in that area. The peritoneum is immediately reclosed as the central tendon is removed. The diaphragm is mobilized back to the pericardium medially.

For right-sided resections, it is very important to identify the phrenic veins draining from the diaphragm directly into the inferior vena cava (IVC) (Figure 6). There are a variable number of such veins, which must be carefully mobilized, ligated and divided to avoid bleeding the IVC. These veins are not present on the left side of the diaphragm. If resection of the pericardium is required, it is entered only when the tumor has been mobilized as fully as possible from all other directions because traction on the pericardium causes arrhythmias and hemodynamic instability (Figure 7).

The hilar structures are divided in whatever sequence is technically easiest and requires the least manipulation of the large tumor mass, usually the main-stem bronchus first (Figure 8), then the inferior pulmonary vein (Figure 9), the superior pulmonary vein, and lastly the main pulmonary artery (Figure 10) If the pericardium is resected, it is gradually opened as this portion of the dissection is carried out. Traction sutures are placed on the pericardium to prevent it from retracting toward the opposite hemithorax thereby minimizing changes in the position of the heart and avoiding hemodynamic instability. The specimen consisting of pleura, lung, and diaphragm, with or without

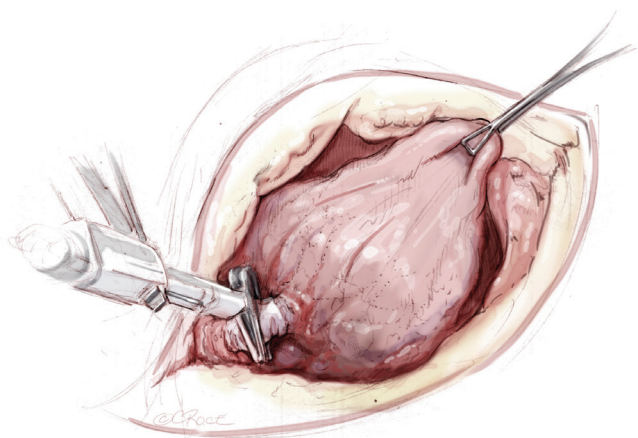


Figure 8 Lung and tumor block retracted anteriorly and right main bronchus divided with a stapler.

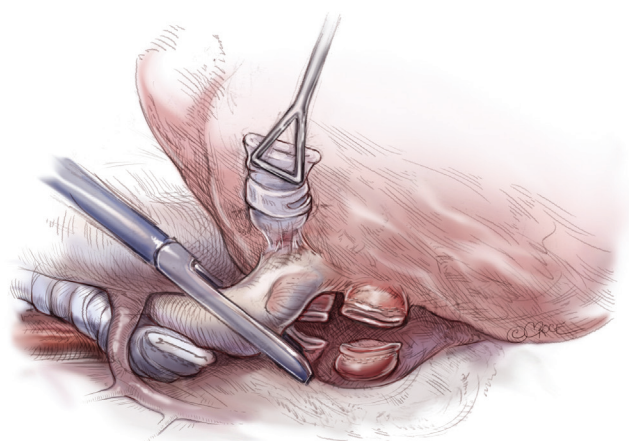


Figure 10 Main pulmonary artery divided with a stapler.

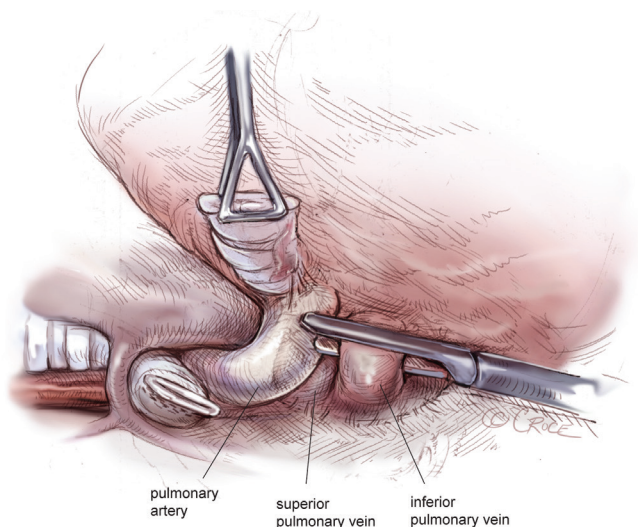


Figure 9 Inferior and superior pulmonary veins are sequentially divided with a stapler.

pericardium, is removed en-bloc. Dissection of the paratracheal lymph nodes if the operation is on the right, or of the aorto-pulmonary window nodes if the operation is on the left, is performed for staging purposes.

Reconstruction of the diaphragm and pericardium

Reconstruction of the diaphragm is performed using a 2 mm thickness Gore Tex patch (W.L. Gore & Associates, Flagstaff, AZ). Laterally, the prosthetic patch is secured with #2 Vicryl sutures around the ribs. Posteriorly, it

is sutured to the crus or gently tacked with fine sutures to the wall of the esophagus. Medially it is sewn to the edge of the pericardium with 0-Prolene interrupted sutures (*Figure 11*). It is extremely important to place the diaphragmatic reconstruction at the same level as the native diaphragm, namely at the tenth intercostal space posteriorly and at the eighth and ninth intercostal spaces anteriorly and laterally. Placing the reconstruction any higher than this makes it difficult to deliver adjuvant radiation safely, especially to the posterior costophrenic sulcus, and increases the risk of radiation hepatitis after right-sided and radiation gastritis after left-sided resections. Although some surgeons recommend reconstructing the diaphragm with a latissimus dorsi reverse flap (41), this technique is more complex and does not provide the stable reconstruction needed to facilitate postoperative radiation.

If the pericardium is resected, it is reconstructed with absorbable mesh to prevent cardiac herniation into the empty hemithorax, and facilitate postoperative radiation to the hemithorax by maintaining the heart in a central position (*Figure 12*). Some surgeons prefer a 1 mm thickness Gore Tex fenestrated patch for pericardial reconstruction. However, this is more difficult to size than absorbable mesh for the pericardial defect and is associated with a risk of epi- and pericarditis (42). A chest tube, usually a 32 French right angle tube, is inserted and placed on the diaphragmatic reconstruction to drain the blood that inevitably oozes from the chest wall dissection. The thoracotomy incision is closed, carefully reapproximating the intercostal muscles to prevent leakage of fluid from the pleural space.

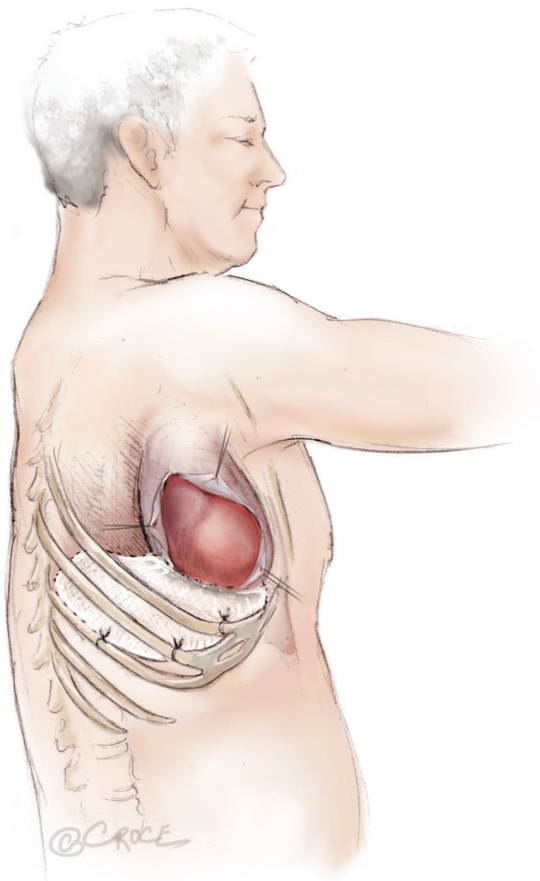


Figure 11 Illustration showing Gore-tex graft for diaphragm reconstruction in position.

Important aspects of postoperative care

Fluid management is critical after EPP. Ongoing fluid shifts during surgery make hemoglobin an unreliable guide to transfusion. Transfusing the patient according to measured intra-operative blood loss is more appropriate and, in our experience, will avoid peri-operative hypotension. Gradual intravascular equilibration during the first few days postoperatively usually requires additional transfusions. Monitoring of the central venous pressure during the first 24 hours postoperatively is helpful in assessing fluid management. As for any pneumonectomy, administration of intravenous crystalloid solution should be minimized.

The chest tube is placed to gravity drainage using a balanced drainage system to equilibrate the mediastinum. Leaving the chest tube in for 48 hours until the drainage becomes serosanguinous avoids the accumulation of a large hemothorax. A purse string suture should be placed around the chest tube and tied upon removal of the tube to prevent

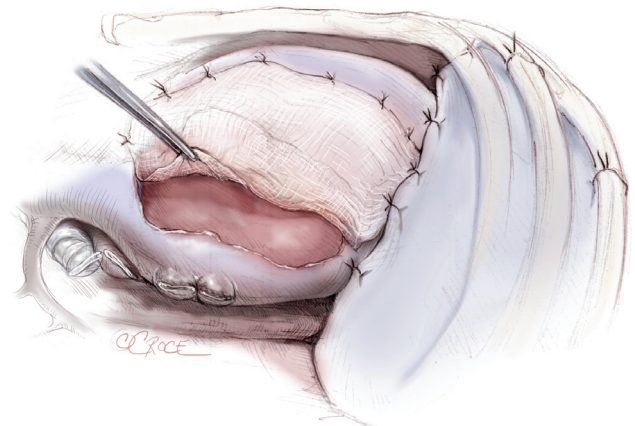


Figure 12 Pericardium resection reconstructed with absorbable mesh.

leakage of pleural fluid from the chest tube site.

Atrial fibrillation occurs in approximately one-third of patients after EPP. We routinely start diltiazem prophylactically on the first postoperative day and continue that for up to six weeks. Careful attention should be paid to the position of the mediastinum after the chest tube has been removed. Because the pleural space usually fills with fluid faster than air is resorbed from it, the mediastinum often shifts away from the operated side during the first five days postoperatively. Mediastinal shift can cause refractory atrial arrhythmias, which respond immediately to aspiration of air from the pleural space, but are not controlled by medication. Prophylactic aspiration of the pleural space performed as soon as the tracheal silhouette is seen to shift even slightly on chest X-ray will prevent these arrhythmias and also relieve the sense of dyspnea experienced by patients when the mediastinum is compressed. Aspiration of the pleural space is performed by inserting a catheter or spinal needle into the first or second intercostal space at the mid-clavicular line under sterile conditions with local anesthesia while the patient is sitting upright. The catheter is attached to a three-way stopcock and a 50 mL syringe. No more than 500 mL of air and/or fluid is aspirated at one time to avoid rapid shift of the mediastinum.

Respiratory insufficiency (atelectasis, retained secretions, pneumonia and acute lung injury) is the most common complication and great attention is given to early ambulation and to the maintenance of pulmonary toilet.

Surgical technique for extended P/D

All of the initial steps for extended P/D are identical to

those performed for EPP, including the thoracotomy incision, resection of the 6th rib, extrapleural dissection along the chest wall and mediastinum and mobilization of the diaphragm. Systematic mediastinal lymph node dissection is also performed. Once the parietal pleura has been fully mobilized, it is incised entering the pleural space. The parietal pleura is mobilized away from the underlying lung, also removing all areas of visceral pleural tumor. In patients who have extensive visceral pleural disease including involvement of the fissures, this part of the dissection is extremely tedious and leaves extensively or completely denuded lung upon completion of the operation. Reconstruction of the diaphragm and pericardium is performed as outlined above for an EPP. It is especially important for the diaphragmatic prosthesis to sit at the same level as the native diaphragm and to be taut because any rise in the patch reconstruction not only compromises postoperative radiation but also produces symptomatic lower lobe atelectasis postoperatively.

Unlike EPP, closure of the thoracotomy incision after extended P/D does not require reapproximation of the intercostal muscles since there is no fluid accumulating in the pleural space. At least two chest tubes (or even three) are used to evacuate the pleural space and aid in re-expanding the lung.

Postoperatively, chest tube output can be considerable for the first 72 hours because of the extrapleural dissection. Patients may require additional intravenous fluids to compensate for this. The other peri-operative care issues that arise after EPP (e.g., rebalancing the mediastinum) do not occur after extended P/D. However, both EPP and extended P/D patients require meticulous respiratory care during the first 5 to 7 days postoperatively.

Acknowledgements

Disclosure: The author declares no conflict of interest.

References

- Flores RM, Zakowski M, Venkatraman E, et al. Prognostic factors in the treatment of malignant pleural mesothelioma at a large tertiary referral center. *J Thorac Oncol* 2007;2:957-65.
- Martin-Ucar AE, Nakas A, Edwards JG, et al. Case-control study between extrapleural pneumonectomy and radical pleurectomy/decortication for pathological N2 malignant pleural mesothelioma. *Eur J Cardiothorac Surg* 2007;31:765-70; discussion 770-1.
- de Perrot M, Uy K, Anraku M, et al. Impact of lymph node metastasis on outcome after extrapleural pneumonectomy for malignant pleural mesothelioma. *J Thorac Cardiovasc Surg* 2007;133:111-6.
- Rice DC, Stevens CW, Correa AM, et al. Outcomes after extrapleural pneumonectomy and intensity-modulated radiation therapy for malignant pleural mesothelioma. *Ann Thorac Surg* 2007;84:1685-92;discussion 1692-3.
- Aigner C, Hoda MA, Lang G, et al. Outcome after extrapleural pneumonectomy for malignant pleural mesothelioma. *Eur J Cardiothorac Surg* 2008;34:204-7.
- Flores RM, Pass HI, Seshan VE, et al. Extrapleural pneumonectomy versus pleurectomy/decortication in the surgical management of malignant pleural mesothelioma: results in 663 patients. *J Thorac Cardiovasc Surg* 2008;135:620-6,626.
- Schipper PH, Nichols FC, Thomse KM, et al. Malignant pleural mesothelioma: surgical management in 285 patients. *Ann Thorac Surg* 2008;85:257-64; discussion 264.
- Yan TD, Boyer M, Tin MM, et al. Extrapleural pneumonectomy for malignant pleural mesothelioma: outcomes of treatment and prognostic factors. *J Thorac Cardiovasc Surg* 2009;138:619-24.
- Cao CQ, Yan TD, Bannon PG, et al. A systematic review of extrapleural pneumonectomy for malignant pleural mesothelioma. *J Thorac Oncol* 2010;5:1692-703.
- Luckraz H, Rahman M, Patel N, et al. Three decades of experience in the surgical multi-modality management of pleural mesothelioma. *Eur J Cardiothorac Surg* 2010;37:552-6.
- Sugarbaker DJ, Wolf AS, Chiriac LR, et al. Clinical and pathological features of three-year survivors of malignant pleural mesothelioma following extrapleural pneumonectomy. *Eur J Cardiothorac Surg* 2011;40:298-303.
- Yan TD, Cao CQ, Boyer M, et al. Improving survival results after surgical management of malignant pleural mesothelioma: an Australian institution experience. *Ann Thorac Cardiovasc Surg* 2011;17:243-9.
- Rusch VW, Giroux D, Kennedy C, et al. Initial analysis of the International Association for the Study of Lung Cancer mesothelioma database. *J Thorac Oncol* 2012;7:1631-9.
- Rice D, Rusch V, Pass H, et al. Recommendations for uniform definitions of surgical techniques for malignant pleural mesothelioma: a consensus report of the International Association for the Study of Lung Cancer committee and the International Mesothelioma Interest Group. *J Thorac Oncol* 2011;6:1304-12.

15. Chang MY, Sugarbaker DJ. Extrapleural pneumonectomy for diffuse malignant pleural mesothelioma: techniques and complications. *Thorac Surg Clin* 2004;14:523-30.
16. Rusch VW. Technique of extrapleural pneumonectomy for malignant pleural mesothelioma. In: Pearson FG, Patterson GA, Cooper J, et al. eds. *Thoracic Surgery*, Third ed. New York: Churchill Livingstone, 2008:1186-93.
17. Rusch VW. Diffuse Malignant Mesothelioma. In: Shields TW, LoCicero J, Reed CE, et al. eds. *General Thoracic Surgery*, 7th ed. Philadelphia: Lippincott, Williams & Wilkins, 2009:847-59.
18. Sugarbaker DJ, Heher EC, Lee TH, et al. Extrapleural pneumonectomy, chemotherapy, and radiotherapy in the treatment of diffuse malignant pleural mesothelioma. *J Thorac Cardiovasc Surg* 1991;102:10-4; discussion 14-5.
19. Rusch VW, Venkatraman E. The importance of surgical staging in the treatment of malignant pleural mesothelioma. *J Thorac Cardiovasc Surg* 1996;111:815-25; discussion 825-6.
20. Rusch VW, Venkatraman ES. Important prognostic factors in patients with malignant pleural mesothelioma, managed surgically. *Ann Thorac Surg* 1999;68:1799-804.
21. Sugarbaker DJ, Flores RM, Jaklitsch MT, et al. Resection margins, extrapleural nodal status, and cell type determine postoperative long-term survival in trimodality therapy of malignant pleural mesothelioma: results in 183 patients. *J Thorac Cardiovasc Surg* 1999;117:54-63; discussion 63-5.
22. Rusch VW, Godwin JD, Shuman WP. The role of computed tomography scanning in the initial assessment and the follow-up of malignant pleural mesothelioma. *J Thorac Cardiovasc Surg* 1988;96:171-7.
23. Patz EF Jr, Shaffer K, Piwnica-Worms DR, et al. Malignant pleural mesothelioma: value of CT and MR imaging in predicting resectability. *AJR Am J Roentgenol* 1992;159:961-6.
24. Patz EF Jr, Rusch VW, Heelan R. The proposed new international TNM staging system for malignant pleural mesothelioma: application to imaging. *AJR Am J Roentgenol* 1996;166:323-7.
25. Heelan RT, Rusch VW, Begg CB, et al. Staging of malignant pleural mesothelioma: comparison of CT and MR imaging. *AJR Am J Roentgenol* 1999;172:1039-47.
26. Scherpereel A, Astoul P, Baas P, et al. Guidelines of the European Respiratory Society and the European Society of Thoracic Surgeons for the management of malignant pleural mesothelioma. *Eur Respir J* 2010;35:479-95.
27. Cao C, Krog Andvik SK, Yan TD, et al. Staging of patients after extrapleural pneumonectomy for malignant pleural mesothelioma--institutional review and current update. *Interact Cardiovasc Thorac Surg* 2011;12:754-7.
28. Flores RM, Akhurst T, Gonen M, et al. Positron emission tomography defines metastatic disease but not locoregional disease in patients with malignant pleural mesothelioma. *J Thorac Cardiovasc Surg* 2003;126:11-6.
29. Erasmus JJ, Truong MT, Smythe WR, et al. Integrated computed tomography-positron emission tomography in patients with potentially resectable malignant pleural mesothelioma: Staging implications. *J Thorac Cardiovasc Surg* 2005;129:1364-70.
30. Flores RM, Akhurst T, Gonen M, et al. Positron emission tomography predicts survival in malignant pleural mesothelioma. *J Thorac Cardiovasc Surg* 2006;132:763-8.
31. Nowak AK, Francis RJ, Phillips MJ, et al. A novel prognostic model for malignant mesothelioma incorporating quantitative FDG-PET imaging with clinical parameters. *Clin Cancer Res* 2010;16:2409-17.
32. Pilling JE, Stewart DJ, Martin-Ucar AE, et al. The case for routine cervical mediastinoscopy prior to radical surgery for malignant pleural mesothelioma. *Eur J Cardiothorac Surg* 2004;25:497-501.
33. Edwards JG, Stewart DJ, Martin-Ucar A, et al. The pattern of lymph node involvement influences outcome after extrapleural pneumonectomy for malignant mesothelioma. *J Thorac Cardiovasc Surg* 2006;131:981-7.
34. Flores RM, Routledge T, Seshan VE, et al. The impact of lymph node station on survival in 348 patients with surgically resected malignant pleural mesothelioma: implications for revision of the American Joint Committee on Cancer staging system. *J Thorac Cardiovasc Surg* 2008;136:605-10.
35. Conlon KC, Rusch VW, Gillern S. Laparoscopy: an important tool in the staging of malignant pleural mesothelioma. *Ann Surg Oncol* 1996;3:489-94.
36. Rice DC, Erasmus JJ, Stevens CW, et al. Extended surgical staging for potentially resectable malignant pleural mesothelioma. *Ann Thorac Surg* 2005;80:1988-92; discussion 1992-3.
37. Rusch VW, Rosenzweig K, Venkatraman E, et al. A phase II trial of surgical resection and adjuvant high-dose hemithoracic radiation for malignant pleural mesothelioma. *J Thorac Cardiovasc Surg* 2001;122:788-95.
38. de Perrot M, McRae K, Anraku M, et al. Risk factors for major complications after extrapleural pneumonectomy for malignant pleural mesothelioma. *Ann Thorac Surg* 2008;85:1206-10.
39. Politi L, Scanagatta P, Salani A, et al. Double unilateral

- thoracotomy for malignant pleural mesothelioma. *J Cardiovasc Surg (Torino)* 2004;45:591-2.
40. Edwards JG, Martin-Ucar AE, Stewart DJ, et al. Right extrapleural pneumonectomy for malignant mesothelioma via median sternotomy or thoracotomy? Short- and long-term results. *Eur J Cardiothorac Surg* 2007;31:759-64.
41. Bedini AV, Andreani SM, Muscolino G. Latissimus dorsi reverse flap to substitute the diaphragm after extrapleural pneumonectomy. *Ann Thorac Surg* 2000;69:986-8.
42. Byrne JG, Karavas AN, Colson YL, et al. Cardiac decortication (epicardiectomy) for occult constrictive cardiac physiology after left extrapleural pneumonectomy. *Chest* 2002;122:2256-9.

Cite this article as: Rusch VW. Extrapleural pneumonectomy and extended pleurectomy/decortication for malignant pleural mesothelioma: the Memorial Sloan-Kettering Cancer Center approach. *Ann Cardiothorac Surg* 2012;1(4):523-531. doi: 10.3978/j.issn.2225-319X.2012.11.13

AME JOURNALS



AME BOOKS



AME CONFERENCES

<p>The 93rd annual meeting of American Association for Thoracic Surgery</p>	<p>Panhellenic Congress News innovation in the academic world</p>	<p>The 14th Central European Lung Cancer Conference (CELCC)</p>	<p>The 15th World Conference on Lung Cancer</p>	<p>The 22nd European Conference on General Thoracic Surgery</p>
---	---	---	---	---

AME DATABASE



www.amegroups.com



AME Wechat

INTRODUCTION TO ANNALS OF CARDIOTHORACIC SURGERY

EDITOR-IN-CHIEF: TRISTAN D. YAN



