

ROBOTIC THORACIC SURGERY: RUIJIN HOSPITAL EXPERIENCE

Honorary Editors: Giulia Veronesi, Jules Lin,
Inderpal S. Sarkaria, Daniela Molena

Editor: Hecheng Li

Associate Editors: Abbas E. Abbas, Jie Xiang

Secretary of Editor: Su Yang



www.amegroups.com

ROBOTIC THORACIC SURGERY: RUIJIN HOSPITAL EXPERIENCE



ROBOTIC THORACIC SURGERY: RUIJIN HOSPITAL EXPERIENCE

Honorary Editors: Giulia Veronesi, Jules Lin,
Inderpal S. Sarkaria, Daniela Molena

Editor: Hecheng Li

Associate Editors: Abbas E. Abbas, Jie Xiang

Secretary of Editor: Su Yang

AME Publishing Company

Room C 16F, Kings Wing Plaza 1, NO. 3 on Kwan Street, Shatin, NT, Hong Kong

Information on this title: www.amegroups.com

For more information, contact books@amegroups.com

Copyright © AME Publishing Company. All rights reserved.

This publication is in copyright. Subject to statutory exception and to the provisions of relevant collective licensing agreements, no reproduction of any part may take place without the written permission of AME Publishing Company.

First published in 2018

Printed in China by AME Publishing Company

Editor: Hecheng Li

Robotic Thoracic Surgery: Ruijin Hospital Experience (Hardcover)

ISBN 978-988-78919-4-9

AME Publishing Company, Hong Kong

AME Publishing Company has no responsibility for the persistence or accuracy of URLs for external or third-party internet websites referred to in this publication, and does not guarantee that any content on such websites is, or will remain, accurate or appropriate.

The advice and opinions expressed in this book are solely those of the authors and do not necessarily represent the views or practices of the publisher. No representation is made by the publisher about the suitability of the information contained in this book, and there is no consent, endorsement or recommendation provided by the publisher, express or implied, with regard to its contents.

Robotic Thoracic Surgery: Ruijin Hospital Experience (FIRST EDITION)

III

HONORARY EDITORS

Giulia Veronesi

Division of Thoracic and General Surgery, Humanitas Clinical and Research Center, Rozzano (Milan), Italy

Jules Lin

Section of Thoracic Surgery, Department of Surgery, University of Michigan Medical Center, Ann Arbor, Michigan, USA

Inderpal S. Sarkaria

Department of Cardiothoracic Surgery, The University of Pittsburgh School of Medicine and the University of Pittsburgh Medical Center, Pittsburgh, PA, USA

Daniela Molena

Thoracic Surgery Service, Memorial Sloan Kettering Cancer Center, New York, NY, USA

EDITOR

Hecheng Li

Department of Thoracic Surgery, Ruijin Hospital, Shanghai Jiao Tong University, School of Medicine, Shanghai 200025, China

ASSOCIATE EDITORS

Abbas E. Abbas

Division of Thoracic Surgery, Department of Thoracic Medicine and Surgery, Lewis Katz School of Medicine at Temple University, Philadelphia, USA

Jie Xiang

Department of Thoracic Surgery, Ruijin Hospital, Shanghai Jiao Tong University, School of Medicine, Shanghai 200025, China

SECRETARY OF EDITOR

Su Yang

Department of Thoracic Surgery, Ruijin Hospital, Shanghai Jiao Tong University, School of Medicine, Shanghai 200025, China

AUTHORS

Abbas E. Abbas

Division of Thoracic Surgery, Department of Thoracic Medicine and Surgery, Lewis Katz School of Medicine at Temple University, Philadelphia, USA

Marco Alloisio

Division of Thoracic and General Surgery, Humanitas Clinical and Research Center, Rozzano (Milan), Italy; Biomedical Science Department, Humanitas University, Rozzano (Milan), Italy

Florian Augustin

Department of Visceral, Transplant and Thoracic Surgery, Center of Operative Medicine, Medical University of Innsbruck, Anichstrasse 35, 6020, Innsbruck, Austria

Johannes Bodner

Department of Visceral, Transplant and Thoracic Surgery, Center of Operative Medicine, Medical University of Innsbruck, Anichstrasse 35, 6020, Innsbruck, Austria; Department of Thoracic Surgery, Klinikum Bogenhausen, StKM, Munich, Germany

Umberto Cariboni

Division of Thoracic and General Surgery, Humanitas Clinical and Research Center, Rozzano (Milan), Italy

Xingshi Chen

Department of Thoracic Surgery, Ruijin Hospital, Shanghai Jiao Tong University, School of Medicine, Shanghai 200025, China

Kai Chen

Department of Thoracic Surgery, Ruijin Hospital, Shanghai
Jiao Tong University, School of Medicine, Shanghai
200025, China

Xueyu Chen

Department of Thoracic Surgery, Ruijin Hospital, Shanghai
Jiao Tong University, School of Medicine, Shanghai
200025, China

Hailei Du

Department of Thoracic Surgery, Ruijin Hospital, Shanghai
Jiao Tong University, School of Medicine, Shanghai
200025, China

Suat Erus

Department of Thoracic Surgery, Ko University School of
Medicine, Istanbul, Turkey

Wei Guo

Department of Thoracic Surgery, Ruijin Hospital, Shanghai
Jiao Tong University, School of Medicine, Shanghai
200025, China

Dingpei Han

Department of Thoracic Surgery, Ruijin Hospital, Shanghai
Jiao Tong University, School of Medicine, Shanghai
200025, China

Wael C. Hanna

Division of Thoracic Surgery, McMaster University,
Hamilton, ON, Canada

Matthew G. Hartwig

Division of Cardiothoracic Surgery, Duke University
Medical Center, Durham, North Carolina, USA

Yanxia Hu

Department of Thoracic Surgery, Ruijin Hospital, Shanghai
Jiao Tong University, School of Medicine, Shanghai
200025, China

Runsen Jin

Department of Thoracic Surgery, Ruijin Hospital, Shanghai
Jiao Tong University, School of Medicine, Shanghai
200025, China

Jacob A. Klapper

Division of Cardiothoracic Surgery, Duke University
Medical Center, Durham, North Carolina, USA

Gregor J. Kocher

Division of General Thoracic Surgery, Bern University
Hospital, University of Bern, Bern, Switzerland

Hecheng Li

Department of Thoracic Surgery, Ruijin Hospital, Shanghai
Jiao Tong University, School of Medicine, Shanghai
200025, China

Chengqiang Li

Department of Thoracic Surgery, Ruijin Hospital, Shanghai
Jiao Tong University, School of Medicine, Shanghai
200025, China

Jie Li

Department of Operation Theatre, Ruijin Hospital,
Shanghai Jiao Tong University, School of Medicine,
Shanghai 200025, China

Jules Lin

Section of Thoracic Surgery, Department of Surgery,
University of Michigan Medical Center, Ann Arbor,
Michigan, USA

Jon A. Lutz

Division of General Thoracic Surgery, Bern University
Hospital, University of Bern, Bern, Switzerland

Franca Melfi

Department of Surgical, Medical, Molecular Pathology and
of Critical Area, University of Pisa, Pisa, Italy

Marcello Migliore

Thoracic Surgery, Department of Surgery and Medical
Specialities, Policlinico University Hospital, University of
Catania, Catania, Italy

Daniela Molena

Thoracic Surgery Service, Memorial Sloan Kettering
Cancer Center, New York, NY, USA

Pierluigi Novellis

Division of Thoracic and General Surgery, Humanitas
Clinical and Research Center, Rozzano (Milan), Italy

David Pennywell

Department of Cardiothoracic Surgery, The University of Pittsburgh School of Medicine and the University of Pittsburgh Medical Center, Pittsburgh, PA, USA

Jiajie Pu

Department of Thoracic Surgery, Ruijin Hospital, Shanghai Jiao Tong University, School of Medicine, Shanghai 200025, China

Qianjian Qian

Department of Operating Theatre, Ruijin Hospital, Shanghai Jiao Tong University School of Medicine, Shanghai, 200025, China

Inderpal S. Sarkaria

Department of Cardiothoracic Surgery, The University of Pittsburgh School of Medicine and the University of Pittsburgh Medical Center, Pittsburgh, PA, USA

Michela Solinas

Division of Thoracic and General Surgery, Humanitas Clinical and Research Center, via Manzoni 56, 20089 Rozzano, MI, Italy

Serhan Tanju

Department of Thoracic Surgery, Ko University School of Medicine, Istanbul, Turkey

Simon R. Turner

Division of Thoracic Surgery, University of Alberta, Edmonton, Canada

Giulia Veronesi

Division of Thoracic and General Surgery, Humanitas Clinical and Research Center, Rozzano (Milan), Italy

Wei Wang

Department of Operating Theatre, Ruijin Hospital, Shanghai Jiao Tong University School of Medicine, Shanghai, 200025, China

Han Wu

Department of Thoracic Surgery, Ruijin Hospital, Shanghai Jiao Tong University, School of Medicine, Shanghai 200025, China

Beiwen Wu

Department of Clinical Nutrition, Ruijin Hospital, Shanghai Jiao Tong University School of Medicine, Shanghai, 200025, China

Jie Xiang

Department of Thoracic Surgery, Ruijin Hospital, Shanghai Jiao Tong University, School of Medicine, Shanghai 200025, China

Su Yang

Department of Thoracic Surgery, Ruijin Hospital, Shanghai Jiao Tong University, School of Medicine, Shanghai 200025, China

Michael D. Zervos

Department of Cardiothoracic Surgery, NYU Langone Medical Center, New York, NY, USA

Yajie Zhang

Department of Thoracic Surgery, Ruijin Hospital, Shanghai Jiao Tong University, School of Medicine, Shanghai 200025, China

Carmelina Cristina Zirafa

Department of Surgical, Medical, Molecular Pathology and of Critical Area, University of Pisa, Pisa, Italy

Executive Typesetting Editor

Li Wang, AME Publishing Company

The Annals of Cardiothoracic Surgery, one of AME's peer-reviewed journals, is lucky to have an author from Rochester, USA. He is left-handed. When he began his training in surgery, he encountered huge obstacles. For example, when using scissors or knotting during a surgery, his actions were the opposite of what was described in textbooks. Therefore, he often “took a beating” from his mentors when performing a surgery.

Later, he summarized his experience and published it in a journal in an attempt to find other surgeons that “suffer from the same fate”. Surprisingly, after his article was published, many surgeons e-mailed him, asking him how left-handed doctors should undergo surgical training, and so on. Then he met Professor Tristan D. Yan, the editor-in-chief of Annals of Cardiothoracic Surgery, who happens to be a left-handed doctor. Tristan encouraged him to become a heart surgeon because there are steps in cardiac surgery that require the use of the left hand to complete the suture threading technique. Tristan's view was that it was better if surgeons were trained to use both their left and right hands.

A few days ago, on my daughter's first day of kindergarten, I chatted with her teacher for a while; finally, she asked me if there was anything about my daughter that she should take note of. “Please do not correct my daughter's left-handedness,” I said, “Just let it be.” “Why?” the teacher asked in wonder.

On December 7, 2013, we held the second AME Academic Salon in the Hospital Affiliated to Nantong University. After dinner, Dr. Shen Yaxing from the Department of Thoracic Surgery of Shanghai Zhongshan Hospital invited several attendees to have tea in his room. The elevator was in the middle of the hotel. After we walked out of the elevator, he led us to the left, then to the left, then to the left, then to the left, and finally to the door of his room. Although we were somehow confused and disoriented, some of us did find out that the door was just diagonally across the elevator. We all burst into laughter. Yaxing shared that he took this route the first time he entered his room, and so he decided to bring us on the same route on the second time. Yaxing then said that this was the behavior of a ‘typical’ surgeon!

During the training to be a surgeon, each step and each action are done under the strict direction and supervision of a senior surgeon. Thus, many surgeons like to affectionately address their mentors as their “masters”.

How, then, can you become a master of surgery? In addition to your own intelligence and diligence, the expertise and mentorship offered by a “master” is also very important. Just like in the world of martial arts, there are many different schools that are independent from each other and have their own strength and weakness, and the surgical world is very much the same.

Therefore, it is important for a young surgeon to gain knowledge and skills from different masters by taking in only the essence and discarding the dregs. Therefore, we have planned to publish the AME Surgery series, in an attempt to share with our readers the surgical skills of some prominent surgical teams in China and abroad, as well as their philosophical thinking and some interesting stories. We sincerely hope that our colleagues in the surgical departments find these books insightful and helpful.

Stephen D. Wang
Founder and CEO,
AME Publishing Company

Thanks to the tireless explorations of our pioneers and the advances in medical theories and techniques, the past decades have witnessed an unprecedented development in thoracic surgical skills. The innovation and improvement in technology has also brought thoracic surgery forward by leaps and bounds. Meanwhile, technical innovations have also contributed to the leapfrog developments in thoracic surgery. The da Vinci Surgical System is an attempt at introducing scientific and technological advances into the field of surgery.

It was introduced in China in 2006, and since then, it has been widely used in many major hospitals, especially in general surgery and thoracic surgery. It has a high-definition 3D stereoscopic imaging system with an overall magnification of 10 and is equipped with a 720-degree rotating Endo Wrist® simulated wrist. Therefore, it can perform basic surgical operations such as tissue cutting, hemostasis, and suturing and can complete a surgery within a limited space. The da Vinci Surgical System helps to reduce intraoperative trauma, relieves postoperative pain, and accelerates postoperative recovery.

The Department of Thoracic Surgery of Ruijin Hospital Affiliated to Shanghai Jiaotong University School of Medicine is one of the centers in China that have performed a large number of surgeries with the da Vinci Surgical System and has accumulated rich experience. Based on the anatomy of the lungs, esophagus, and mediastinum, this practical and explanatory book focuses on the key points and skills of the application of the da Vinci Surgical System in thoracic surgery. As an illustrated education material, this book uses a large number of pictures to introduce and display the anatomical points and explains the steps and difficulties of each surgical procedure. The texts are simple and concise, so that readers can understand them quickly and easily. This book can help the reader to speed up the learning curve and hence grasp the operating techniques of the system at a faster pace.

Thus, I would like to recommend this book *Robotic Thoracic Surgery: Ruijin Hospital Experience*, edited by Prof. Hecheng Li and his colleagues from Ruijin Hospital Affiliated to Shanghai Jiaotong University School of Medicine, to all thoracic surgeons around the world. I truly believe that all readers will benefit from this informative and useful book.

Jie He

Academician of Chinese Academy of Sciences (CAS)
Cancer Hospital & Institute, Chinese Academy of Medical Science

Since the arrival of a robotic system in 2006 in our hospital, we realised that this was the opportunity for us to introduce minimally invasive approach in our Division of Thoracic Surgery. In fact as commonly happened at that time, many cancer centers were skeptic about the introduction of videothoroscopic major lung resections mainly due to doubts to obtain satisfactory radical lymph node dissection. Besides, lateral muscle sparing thoracotomy that we commonly used at that time, represented already a soft approach to the chest compared to the traditional posterolateral one. Robotic approach, already adopted by few centers in Italy for prostatectomy at that time, was considered the ideal tool to guarantee extended and radical dissections in early stage lung cancer patients. Meanwhile, Bernard Park of the MSKCC (Memorial Sloan Kettering Cancer Centers) had just published its series of 34 lung cancer patients treated with robotic approach, paving the way for the other cancer centers.

The main motivation to start a minimally invasive program in our division came from the experience with lung cancer screening program that has revolutioned the history of cancer patients thanks to the detection of very initial tumors in a large number of asymptomatic high risk individuals.

Since that period robotic surgery has developed and diffused rapidly worldwide at the point that a recent analysis reports that 15% of lobectomies in US are nowadays performed with robotic approach.

I'm happily surprised to see that in Chinese big hospitals, like the Ruijin one, embraced systemically this technique and reached outstanding results and experience.

One of the main critic point today is to find the right and efficient way to teach this procedure to residents and young thoracic surgeons and create the adequate route to avoid the risks related to learning curve in particular in a phase in which the number of robotic procedures is expected to increase further as new devices are going to enter the market and costs hopefully decreased. The scientific societies will propose soon standardised curriculum with the most up to date educational content and simulation systems to facilitate and standardise the educational process. A process that will be conducted in strict collaboration with the manufacturers companies.

This textbook contains the description of the most common robotic thoracic techniques with different point of views by recognized experts at the end of each chapter, representing an innovative and useful way to present and illustrate technical aspects of thoracic surgery to novices in the field and offering in the mean time a critical approach.

With great honor I contribute to the edition of this text that as well as being a witness to the advanced technique developed by Ruijin's colleagues, is an extremely useful manual for young and/or senior open surgeons who want to approach robotic surgery of the chest.

Giulia Veronesi, MD

Humanitas Research Hospital, Rozzano, Milan, Italy.

(Email: giulia.veronesi@humanitas.it; giulia.veronesi@cancercenter.humanitas.it)

Since the introduction of thoracoscopy, thoracic surgery has continued to evolve to more minimally invasive approaches. Outcomes are equivalent to open thoracotomy with less pain, decreased length of stay, and shorter recovery times. However, thoroscopic procedures have a steep learning curve due to reduced tactile sensation and loss of degrees of freedom.

Robotic thoracic surgery may address some of these shortcomings by providing 3-dimensional visualization and wristed instruments especially when there is limited space such as in the chest or mediastinum. Several studies have shown at least equivalent outcomes to thoracoscopy across multiple centers. While there are advantages for the surgeon in terms of dexterity and visualization, the question remains how these advantages affect patient outcomes and whether the robotic approach is a true revolution or an evolution from other minimally invasive approaches. The benefits of robotic thoracic surgery will need to be clearly defined especially in light of higher hospital costs although this will likely improve with the introduction of new robotic platforms and more widespread adoption of robotic surgery. There is a significant learning curve, but with appropriate mentorship and team training, robotic surgery can be performed safely by experienced thoracic surgeons.

The first edition of *Robotic Thoracic Surgery: Ruijin Hospital Experience* brings together the extensive experience of the thoracic surgeons at Ruijin Hospital with expert commentary from thoracic surgeons around the world. The authors provide practical tips and good illustrative photos that demonstrate the key steps and challenging points that all readers, from the novice to the expert, can benefit from. The book covers the spectrum of thoracic robotic surgery including pulmonary resection, esophagectomy, and thymectomy and is highly recommended for all surgeons performing robotic thoracic surgery.

Jules Lin, MD, FACS

Section of Thoracic Surgery, University of Michigan Medical Center, Ann Arbor, MI 48109, USA

(Email: juleslin@med.umich.edu)

The advent of minimally invasive approaches to complex operations, not only in thoracic surgery, but in many surgical fields, has significantly changed the conduct of these operations compared to the standard, traditional open procedures. While these approaches can be performed with great expertise and have brought significant benefit to patients in terms of decreased complications, less pain, and decreased costs in many cases, they have also come with some significant challenges and compromises to surgeons. These compromises and challenges revolve mainly around the loss of direct haptic feedback and touch, the relatively long learning curve of these operations that can be more difficult to teach than open operations, a shift to working with stick-like “stiff” instruments with limited range of motion compared to the operator’s hands and wrists, the need to often work with these instruments through single small access incisions, and a switch to an assistant driving a camera and determining the field of view as opposed to the operator’s own eyes under the volition of the operator’s own brain.

In this surgeon’s humble opinion, modern robotic surgery has largely returned the vast majority of control over the conduct of the operation back to the surgeon, and therein lies the single most important advancement of these approaches. Through superior advanced imaging under the direct control of the operator and situated naturally between the surgeon’s hands, superior instrumentation that mimic the wristed motion of the surgeon with great precision and stability, the use of additional robotic arms that allow surgeons to “self-assist” and decrease dependence on the bedside assistant, these platforms have, to a great extent, allowed surgeons to conduct the operation in a fashion far more akin to traditional open operations, if not better.

Additional technologies incorporated into current robotic platforms, such as robotic stapling under the control of the surgeon, advanced imaging modalities such as near infrared fluorescence imaging that allow tissues of interest to “glow” and be better seen by the surgeon, the ability to tile different simultaneous views into the surgeon console, and dual consoles allowing improvements in assist and training, have further improved the ability of surgeons to control greater aspects of the operation, arguably even better than in the open operative setting in many instances. These technologies, which have proliferated in a relatively rapid manner over a short time span, are only the first of many that can be expected. Additional decreases in instrumentation size, improvements in energy and dissection devices, expansion in optical technologies, to name a few, will no doubt find their way into future iterations of robotic assisted operations. The modern surgeon can have no doubt that these technologies will continue to persist, expand, and improve.

Practical experiences and publications from centers of robotic expertise will be increasingly important in navigating this burgeoning field. I believe this first edition of the *Robotic Thoracic Surgery: Ruijin Hospital Experience*, expertly edited by Dr. Hecheng Li and Dr. Jie Xiang, and composed of well-illustrated, practical, and straightforward descriptions of the operations performed, along with thoughtful commentaries from a wide array of authorities in the field, will serve as one such important guide for young thoracic trainees and practicing surgeons alike.

Inderpal S. Sarkaria, MD, FACS

Vice Chairman, Clinical Affairs,
Director, Thoracic Robotic Surgery,
Co-Director, Esophageal & Lung Surgery Institute,
Department of Cardiothoracic Surgery,
University of Pittsburgh School of Medicine and University of Pittsburgh Medical Center,
Pittsburgh, Pennsylvania, USA
(Email: sarkariais@upmc.edu)

The minimally invasive “revolution” of the early 1990s did not include thoracic surgery. Whereas the shift from open to laparoscopic cholecystectomy happened almost overnight, without strong scientific evidence to support the change, in the early 2000s only 15% of thoracic procedures were done using a video-assisted technique—and most of these were minor diagnostic and therapeutic surgeries (drainage of pleural effusion, treatment of pneumothorax, wedge resections) (1). One study that evaluated the prevalence of video-assisted thoracic surgery (VATS) lobectomy in the United States, using the Nationwide Inpatient Sample database, found that, among 13,619 patients undergoing lobectomy at nonfederal facilities between 2004 and 2006, only 6% (n=759) underwent a VATS approach (2). Even among specialized thoracic surgeons, the new technology took a long time to be embraced, especially for anatomic resections. In the Society of Thoracic Surgeons General Thoracic Surgery Database, the rate of VATS lobectomy increased from 10% in 2002 to only 29% in 2007 (3). There has been no lack of evidence—although most of it is retrospective—that minimally invasive thoracic surgery is associated with faster recovery, lower complication rates, and equivalent oncologic outcomes, compared with open surgery (4). One randomized trial recently conducted in Denmark found decreased postoperative pain and enhanced quality of life after VATS lobectomy (5). Hopefully, these data will help convince the skeptics that still remain.

What has been holding us back? An interesting survey of the European Society of Thoracic Surgeons in 2007 suggested that the main reasons for the low utilization of VATS were the technical difficulty of the operation, the lack of specific training, and a steep learning curve to become competent (6). To overcome some of the limitations of video-assisted surgery, many thoracic surgeons have turned to the robot. Robotic surgery offers some clear advantages: tridimensional view, motion control, and wristed instrumentation, which approximates the movement of the human hand. The learning curve for robotic surgery has also been shown to be more rapid than that for VATS (7), and this might have pushed some traditional-minded surgeons to embrace a minimally invasive approach. It seems that robotic surgery is closing the gap for thoracic surgeons who want to embrace a minimally invasive approach, and its utilization is increasing fast.

The book *Robotic Thoracic Surgery: Ruijin Hospital Experience*, therefore, comes at a prime time for the discipline, and it will likely become a useful guide for thoracic surgeons in China and internationally. Unfortunately, not all that glitters is gold, and the Achilles’ heel of robotic surgery is cost. Hopefully, multidisciplinary use of the system, postoperative fast-tracking of patients, and development of competitive alternate robotic platforms will drive costs down and increase availability.

As an optimist, I believe that patients’ outcomes and satisfaction are what motivate us. There is no doubt that minimally invasive surgery is a better option than open thoracotomy for our patients, and it is time for surgeons to fully embrace it.

References

1. Paul S, Sedrakyan A, Chiu YL, et al. Outcomes after lobectomy using thoracoscopy vs thoracotomy: a comparative effectiveness analysis utilizing the Nationwide Inpatient Sample database. *Eur J Cardiothorac Surg* 2013;43:813-7.
2. Gopaldas RR, Bakaeen FG, Dao TK, et al. Video-assisted thoracoscopic versus open thoracotomy lobectomy in a cohort of 13,619 patients. *Ann Thorac Surg* 2010;89:1563-70.
3. Boffa DJ, Allen MS, Grab JD, et al. Data from The Society of Thoracic Surgeons General Thoracic Surgery database: the surgical management of primary lung tumors. *J Thorac Cardiovasc Surg* 2008;135:247-54.
4. Cao C, Manganas C, Ang SC, et al. Video-assisted thoracic surgery versus open thoracotomy for non-small cell lung cancer: a meta-analysis of propensity score-matched patients. *Interact Cardiovasc Thorac Surg* 2013;16:244-9.
5. Bendixen M, Jorgensen OD, Kronborg C, et al. Postoperative pain and quality of life after lobectomy via video-assisted thoracoscopic surgery or anterolateral thoracotomy for early stage lung cancer: a randomised controlled trial. *Lancet Oncol* 2016;17:836-44.

6. Rocco G, Internullo E, Cassivi SD, et al. The variability of practice in minimally invasive thoracic surgery for pulmonary resections. *Thorac Surg Clin* 2008;18:235-47.
7. Veronesi G. Robotic surgery for the treatment of early-stage lung cancer. *Curr Opin Oncol* 2013;25:107-14.

Daniela Molena, MD

Director of Esophageal Surgery,

Division of Thoracic Surgery,

Department of Surgery,

Memorial Sloan Kettering Cancer Center, New York, NY 10065, USA

(Email: molenad@mskcc.org)

Minimally invasive, as the name suggests, refers to a surgical wound that is smaller than that produced by a conventional surgery, an ideal that has been the goal of surgeons. Surgery has always advanced in the direction of a mission to maintain and restore the physiological functions of the human body. All surgeons are well aware that when a surgery is performed to treat a disease, the surgical wound itself should be smaller than that from the disease, so as to meet the principle of beneficence, and on this basis, further reducing the surgical wound will benefit patients more. In the late twentieth century, along with the introduction of endoscopy, the concept of minimally invasive surgery was rapidly established and widely disseminated, and soon it became feasible and practicable. After nearly 30 years of development, thoracic surgery has already entered an era of "video-assisted thoracoscopic surgery (VATS)", and minimally invasive thoracic surgical techniques have increasingly become mature.

Meanwhile, modern technology and industrial development have also led to innovations in surgical methods, contributing to the R&D of some new minimally invasive techniques. In the early twenty-first century, Intuitive Surgical, Inc. successfully released the da Vinci robotic surgical system. As "one of the top ten greatest inventions in the past 50 years", this system has thoroughly liberated the surgeons from the operating table. It provides clearer, enlarged field of vision and more accurate and flexible operations, which greatly improves the effectiveness and safety of surgical treatment for chest diseases. If minimally invasive surgery is a successful model of the integration of photoelectric technology, biological engineering, material science, and many other modern high-tech achievements with the traditional surgical operations, it is safe to say that robotic surgery is a gifted invention that combines modern remote information technology and intelligent engineering technology with minimally invasive surgical techniques. The former reduces the wound caused by surgical interventions, while the latter represents a revolution in surgical mode and idea!

This *Robotic Thoracic Surgery: Ruijin Hospital Experience*, covering almost all current mainstream operations for thoracic diseases, summarizes the successful robotic operations in hundreds of patients in the Department of Thoracic Surgery of Ruijin Hospital. As an illustrated guide, it is highly informative and practical. Limited by the amount of surgical equipment, robotic thoracic surgery has not yet been fully popularized in China, however, we can foresee its accelerated development in the coming decade. Teaching and learning as a bi-directional activity. I believe this book will serve as a reference and guidance for colleagues in the field of minimally invasive thoracic surgery, especially those who are interested in robotic thoracic surgery. I sincerely hope that thoracic surgery in China will reach a new high under the joint efforts of all Chinese and international peers.

Hecheng Li

Department of Thoracic Surgery,
Ruijin Hospital Affiliated to Shanghai Jiaotong University School of Medicine, Shanghai, China

Our current era has witnessed more than just technological advances in how we perform surgery. It has also seen an incredible dissemination of knowledge among the entire world. With the internet came easy access to data on all the different options for treatment of disease, information once held only by medical practitioners. Patients can now compare different modalities before deciding on their treatment and have appropriately become the driving force in where our priorities in health care should lie. Indeed our patients have spoken and one of their main priorities is minimally invasive surgery, that catchall phrase which simply means doing the operation with the least harm while trying to achieve the same results. To accomplish this priority the last 30 years have undeniably been revolutionary with video assisted intracavitary surgery becoming accessible to almost every part of the human body. More recently, another disruptive technology, computer assisted surgical machinery or “robotics” came along. The ability to use miniaturized articulating instruments inside a cavity with state of the art optics provides an experience for the surgeon that had never been previously appreciated. The surgeon can now perform maneuvers that were hitherto only possible by open surgery, such as bimanual dissection and suturing, the basic principles of sound surgical technique. Of course, this technology does not come cheap. Despite its uncontested technical superiority, the cost of robotic surgery will have to be offset by significant advantages not just to the surgeon but also to the patient and society at large.

The title of this book, *Robotic Thoracic Surgery: Ruijin Hospital Experience* is deceptively simple. One may assume that it is just another manual for surgical procedures that pertains only to Ruijin hospital. However, the old adage of not judging a book by its cover, or in this case its title, certainly applies. On careful review of the topics, the reader finds that they actually cover the entire gamut of robotic thoracic surgery. To this end, editors Li and Xiang have certainly amassed some of the most renowned Chinese and international experts in the field of RATS to author this book. The excellent chapters provide well-crafted and beautifully illustrated details of lung, esophageal and mediastinal procedures. More importantly, they also delve on other issues such as cost, perioperative management and surgical team collaboration; essential components toward building a successful robotic assisted thoracic surgery (RATS) program. One readily realizes that this book can in fact become a useful compendium for thoracic surgeons worldwide.

Although the Ruijin Hospital robotic surgical experience is relatively young, it has quickly become one of the highest volume centers in the world for RATS. I have personally witnessed how this program has grown to become one where the most advanced thoracic procedures are routinely done by robotic minimally invasive techniques. Indeed, the “Ruijin experience” can become a model for how to become a world class center in this field. As a contributor to the book, I have the distinct honor of being part of this valuable fund of knowledge.

Abbas E. Abbas, MD, MS, FACS

Professor and Thoracic Surgeon in Chief,
Department of Thoracic Medicine and Surgery,
Temple University Hospital and Fox Chase Cancer Center,
Lewis Katz School of Medicine at Temple University,
Philadelphia, Pennsylvania, USA.
(Email: abbas.abbas@temple.edu)

Table of Contents

Pandect

- 1 **Application of the da Vinci in thoracic surgery**
Han Wu, Hecheng Li

Robotic-assisted Thoracic Surgery: Lung

- 7 **Robotic-assisted thoracoscopic surgery: right lower lobectomy**
Su Yang, Wei Guo, Runsen Jin, Yajie Zhang, Xingshi Chen, Han Wu, Hailei Du, Dingpei Han, Kai Chen, Jie Xiang, Hecheng Li
- 12 **Robotic lobectomy: revolution or evolution?**
Jules Lin
- 17 **Robotic-assisted thoracoscopic surgery: a promising surgical method**
Su Yang, Hecheng Li
- 19 **Robotic-assisted right middle lobectomy**
Xingshi Chen, Su Yang, Wei Guo, Runsen Jin, Yajie Zhang, Han Wu, Hailei Du, Dingpei Han, Kai Chen, Jie Xiang, Hecheng Li
- 25 **Robotic assisted right middle lobectomy**
Wael C. Hanna
- 26 **Robotic portal lobectomy, surgery through a virtual thoracotomy**
Abbas E. Abbas
- 31 **Reply to comments on “Robotic Assisted Right Middle Lobectomy”: incision positions, approaches and other problems**
Xingshi Chen, Hecheng Li
- 33 **Robotic-assisted right upper lobectomy**
Hailei Du, Su Yang, Wei Guo, Runsen Jin, Yajie Zhang, Xingshi Chen, Han Wu, Dingpei Han, Kai Chen, Jie Xiang, Hecheng Li
- 37 **Is robotic surgery for NSCLC innovative enough?**
Marcello Migliore
- 39 **Robotic-assisted right upper lobectomy: with the further research, robot-assisted thoracic surgery (RATS) will be better in future**
Hailei Du, Hecheng Li

- 41 Robotic thoracic surgery: left lower lobectomy**
Runsen Jin, Su Yang, Wei Guo, Yajie Zhang, Xingshi Chen, Han Wu, Hailei Du, Dingpei Han, Kai Chen, Jie Xiang, Hecheng Li
- 46 Editorial for robotic left lower lobectomy**
Michael D. Zervos
- 47 Robotic left lower lobectomy: our experience**
Runsen Jin, Hecheng Li
- 48 Different techniques in robotic lung resection**
Pierluigi Novellis, Marco Alloisio, Umberto Cariboni, Giulia Veronesi
- 52 Robotic-assisted thoracoscopic surgery: left upper lobectomy**
Jie Xiang, Su Yang, Wei Guo, Runsen Jin, Yajie Zhang, Xingshi Chen, Han Wu, Hailei Du, Dingpei Han, Kai Chen, Hecheng Li
- 57 Robotic-assisted left upper lobectomy: facing the challenge head-on**
Simon R. Turner, Daniela Molena
- 59 Robotic-assisted thoracoscopic surgery: cost and lymph node dissection**
Jie Xiang, Hecheng Li
- 60 Ruijin robotic thoracic surgery: right S⁶ segmentectomy**
Chengqiang Li, Su Yang, Wei Guo, Runsen Jin, Yajie Zhang, Xingshi Chen, Han Wu, Hailei Du, Dingpei Han, Kai Chen, Jie Xiang, Hecheng Li
- 64 Technical aspects of video-assisted and robotic-assisted thoracoscopic segmentectomy**
Jon A. Lutz, Gregor J. Kocher
- 67 Robotic-assisted thoracoscopic segmentectomy: there is a long way to go**
Chengqiang Li, Hecheng Li
- 70 Ruijin robotic thoracic surgery: S¹⁺²⁺³ segmentectomy of the left upper lobe**
Han Wu, Su Yang, Wei Guo, Runsen Jin, Yajie Zhang, Xingshi Chen, Hailei Du, Dingpei Han, Kai Chen, Jie Xiang, Hecheng Li
- 75 Robotic-assisted thoracic surgery: a helpful tool or just another expensive gadget?**
Florian Augustin, Johannes Bodner
- 78 Robotic-assisted thoracic surgery: a promising tool should not be denied**
Han Wu, Hecheng Li
- 80 Robotic thoracic surgery: S¹⁺² segmentectomy of left upper lobe**
Hailei Du, Su Yang, Wei Guo, Runsen Jin, Yajie Zhang, Xingshi Chen, Han Wu, Dingpei Han, Kai Chen, Jie Xiang, Hecheng Li

- 85 **Robotic-assisted thoracoscopic surgery: state of the art and future perspectives**
Gregor J. Kocher
- 88 **Robotic thoracic surgery: S¹⁺² segmentectomy of the left upper lobe: advantages of robotic assisted thoracic surgery**
Hailei Du, Hecheng Li
- 89 **Robotic segmentectomy: far beyond choice**
Suat Erus, Serhan Tanju

Robotic-assisted Thoracic Surgery: Esophagus

- 91 **Ruijin robotic thoracic surgery: robot-assisted Ivor Lewis esophagectomy**
Yajie Zhang, Su Yang, Wei Guo, Runsen Jin, Xingshi Chen, Han Wu, Hailei Du, Dingpei Han, Kai Chen, Jie Xiang, Hecheng Li
- 97 **Robotic assisted minimally invasive esophagectomy for esophageal cancer: a comment on the Ruijin hospital experience**
David Pennywell, Inderpal S. Sarkaria
- 100 **Robotic-assisted McKeown esophagectomy**
Dingpei Han, Su Yang, Wei Guo, Runsen Jin, Yajie Zhang, Xingshi Chen, Han Wu, Hailei Du, Kai Chen, Jie Xiang, Hecheng Li
- 108 **Robotic esophagectomy: a better way or just another way?**
Jacob A. Klapper, Matthew G. Hartwig
- 112 **Robotic-assisted McKeown esophagectomy: a safe and reliable method**
Dingpei Han, Hecheng Li
- 114 **Ruijin robotic thoracic surgery: robot-assisted enucleation of esophageal leiomyoma**
Yajie Zhang, Su Yang, Wei Guo, Runsen Jin, Xingshi Chen, Han Wu, Hailei Du, Dingpei Han, Kai Chen, Jie Xiang, Hecheng Li

Robotic-assisted Thoracic Surgery: Mediastinal Tumor

- 118 **Robotic-assisted thoracoscopic thymectomy**
Kai Chen, Su Yang, Wei Guo, Runsen Jin, Yajie Zhang, Xingshi Chen, Han Wu, Hailei Du, Dingpei Han, Jie Xiang, Hecheng Li
- 122 **Robot-assisted surgery for posterior superior mediastinal mass**
Wei Guo, Su Yang, Runsen Jin, Yajie Zhang, Xingshi Chen, Han Wu, Hailei Du, Dingpei Han, Kai Chen, Jie Xiang, Hecheng Li

- 125 **From manual to robotic video-assisted resection of posterior mediastinal masses**

Giulia Veronesi, Michela Solinas

- 129 **Robot-assisted surgery for posterior mediastinal mass**

Carmelina Cristina Zirafa, Franca Melfi

Robotic-assisted Thoracic Surgery: Perioperative Management

- 132 **Pre-operative preparation for Da Vinci robotic surgery**

Xueyu Chen, Su Yang, Wei Guo, Runsen Jin, Yajie Zhang, Xingshi Chen, Han Wu, Hailei Du, Dingpei Han, Kai Chen, Jie Xiang, Hecheng Li

- 137 **Collaboration between the surgeon, assistants and nurses in robotic-assisted thoracic surgery**

Jie Li, Wei Wang, Qianjian Qian, Xingshi Chen, Hecheng Li

- 142 **Postoperative management of robotic-assisted thoracic surgery**

Yanxia Hu, Jiajie Pu, Beiwen Wu, Xingshi Chen, Hecheng Li

Application of the da Vinci in thoracic surgery

Han Wu, Hecheng Li

Department of Thoracic Surgery, Ruijin Hospital, Shanghai Jiao Tong University, School of Medicine, Shanghai 200025, China

Contributions: (I) Conception and design: All authors; (II) Administrative support: H Li; (III) Provision of study materials or patients: H Li; (IV) Collection and assembly of data: H Wu; (V) Data analysis and interpretation: All authors; (VI) Manuscript writing: All authors; (VII) Final approval of manuscript: All authors.

Correspondence to: Hecheng Li. Department of Thoracic Surgery, Ruijin Hospital, Shanghai Jiao Tong University, School of Medicine, Shanghai 200025, China. Email: lihecheng2000@hotmail.com.

Abstract: The da Vinci Surgical System is an advanced minimally invasive surgical technique that has been widely applied in many fields of surgery. It was adopted relatively late in China, and its use in thoracic surgery is still growing. In this paper, we summarized its present applications in thoracic surgery. We also objectively evaluated its advantages and disadvantages in comparison with traditional open chest surgery and video-assisted thoracoscopic surgery (VATS). We believe that this technology has the potential to markedly change general thoracic surgery.

Keywords: Robot-assisted surgical system; minimally invasive surgery (MIS); lung; esophagus; mediastinum

Received: 02 December 2016; Accepted: 27 December 2016; Published: 07 February 2017.

doi: 10.21037/amj.2017.01.02

View this article at: <http://dx.doi.org/10.21037/amj.2017.01.02>

Surgical techniques have changed considerably over time, from large-incision open surgery to small-incision open surgery, and now to minimally invasive surgery (MIS), which is widely used. MIS reduces tissue trauma and pain, shortens the recovery time, minimizes complications and improves cosmetic results (1).

Minimally invasive thoracic surgery has been the focus of research in recent years. Video-assisted thoracoscopic surgery (VATS) has been used for more than 20 years in China and has gained broad acceptance for various thoracic diseases. Although VATS is recommended as the standard operation for radical lung resection by the National Comprehensive Cancer Network (2), its limitations include the restriction of sensory information to a two-dimensional image and difficulty in maneuvering tips of instrument. The da Vinci robotic Surgical System was introduced to overcome these limitations.

As early as 500 years ago, Leonardo da Vinci, the greatest European artist and inventor of the 15th century, designed a humanoid robot on the drawings. In 1990s, Intuitive Inc. invented the da Vinci Surgical System, by applying the most advanced robotic arm used in the space program for clinical use. In 2000, the da Vinci Surgical System became the first

automatic control system for endoscopic surgery approved by the U.S. Food and Drug Administration (3).

The da Vinci Surgical System consists of three major components (*Figure 1*): a console for the operating surgeon, the robotic arm cart and a vision cart including optical devices for the robotic camera. This system makes it possible for the surgeon sit at the console and trigger highly sensitive motion sensors that transfer the surgeon's movements to the tips of the instruments, rather than directly operating on the patient with surgical instruments. The da Vinci Surgical System is clearly the next step for MIS after VATS. Ruijin Hospital adopted the da Vinci Surgical System for thoracic tumors early and has accumulated practical experience.

Advantages of the da Vinci Surgical System

Compared with traditional MIS, the robotic arms of the da Vinci Surgical System effectively eliminate any hand tremor to improve the stability. The system also provides a clear and magnified three-dimensional operative field (4). The image and the instruments are kept in the same direction to optimize eye-hand coordination, which enables precise tissue dissection, hemostasis, and suturing. The flexible



Figure 1 The components of da Vinci Surgical System.

multi-joint arms and so-called “Endo Wrist technology” offer seven degrees of freedom, exceeding the capacity of the surgeon’s hand in open surgery. The surgeon can adjust the camera and manipulate the field of view simultaneously (5). The da Vinci Surgical System can reduce tissue trauma and shorten the recovery time, which is the advantage of precise MIS. In the future, telesurgery may become possible with this robotic system.

Application of the da Vinci Surgical System in thoracic surgery

The da Vinci Surgical System was approved for thoracic surgery in 2001 and was introduced in China in 2006 (3,5,6). This new technology has been used by many medical institutions for thoracic procedures, such as pulmonary lobectomy, esophagectomy, resection of mediastinal cystic and solid tumors, thymectomy, diaphragmatic hiatus repair, cardiomyotomy, and lymph node dissection, etc.

Conditions for use

- (I) Strict indications: patients should undergo a full evaluation to determine the indication. Injuries caused by prolonged surgeries and anesthesia must be avoided.
- (II) Experienced teams: a successful team includes skilled

surgeons, anesthetists, and nurses to ensure efficiency, safety, and thoroughness.

- (III) Flexibility: the surgical team should have the insight and decisiveness to rapidly respond to unexpected situations.

Lung surgery

Lobectomy with lymph node dissection is a major challenge in thoracic robotic surgery, and surgeons must also be familiar with open surgery and VATS (7). Surgeons usually choose small tumor to learn robotic surgery techniques and accumulate experience. When the tumor is large and adheres to blood vessels, open surgery is safe. Early in 2000, Okada *et al.* (8) used the Televox AESOP system and automatic traction control to perform right middle lobectomy and mediastinal lymph node dissections. Then AESOP was replaced by the da Vinci Surgical System. In 2002, Melfi *et al.* (9) used the da Vinci system for 12 lung surgeries: 5 lobectomies, 3 mass resections, and 4 pulmonary bullae resections. As the technology has developed, and surgeons have accumulated experience, especially with the second-generation da Vinci Surgical System, robotic lung surgery has become widely accepted by surgeons and patients (10,11). The system has a clear and magnified three-dimensional operative field, and its robotic arms effectively eliminate the hand tremor to improve

stability, which enables precise segmental resection and sleeve resection (12,13). Robotic lung surgery was adopted late in China. In 2011, Yi *et al.* (14) completed 22 robotic surgeries on lung nodules. In 2013, Wang *et al.* (7) reported successful robotic lung surgeries and completed the first robotic surgery of the right lower lobe for central lung cancer, upper lobe dorsal segment resection, and lymph node dissection. The retrospective studies of Brooks (15) and Park (16) *et al.* showed that robotic-assisted lobectomies were feasible, safe and oncologically sound procedures for patients with stage IA or IB lung cancer, but noted that there is a steep learning curve. Mahieu *et al.* (17) reported that perioperative results for lung surgeries were comparable to results of robotic surgery and VATS. Numerous researchers consider robotic lung surgery to be comparable to VATS, or even superior to VATS regarding accuracy. However, multi-center and large randomized controlled studies are needed to compare the long-term outcomes of robotic-assisted lung surgery with those of conventional open surgery and VATS (18,19).

Esophagus surgery

Esophagus cancer operations are complex and multisite, which is a challenge in robotic surgery and they were attempted relatively late. The most important factors associated with long-term survival are local recurrence and lymph nodes recurrence. Therefore, lymph node dissection is important in esophagus cancer and the dissection range is from the apical chest to above the diaphragm. The da Vinci Surgical System offers convenience for lymph node dissection. In 2003, Horgan (20) reported the first robotic transhiatal esophageal resection and treated 15 patients with this procedure in the following 2 years. In 2004, Kernstine (21) reported the first robotic transthoracic esophageal resection. Other reports described primary experiences to demonstrate the feasibility of robotic esophageal resection. In 2011, Yi *et al.* (14) reported robotic esophageal resection in China. In recent years, some researchers tried using a semi-prone position rather than the traditional left lateral position to provide a clear operative field and convenient space for the surgeons (22). In 2013, Ishikawa *et al.* (23) reported the safety and feasibility of using semi-prone position for robotic surgery, and Dunn (24) reported similar results for a single-center clinical trial of 40 patients. Mori *et al.* (25,26) compared the robotic transthoracic esophageal resection with the traditional transthoracic approach and found that

the robotic surgery was superior for lymph node dissection and resulted in a lower rate of postoperative infection. A study by Park (27) reported good safety and perioperative results of robotic esophageal resection with mediastinal lymph node dissection in 114 patients. However, prospective studies are still needed to compare the survival rates of traditional and robotic esophageal resection. As this new technology continues to develop, and surgeons accumulate experience, robotic esophageal resection will be more widely applied.

Mediastinal surgery

Midsternal incisions used for thymomas and other anterior mediastinal tumors fully expose tissues but can lead to serious complications. For that reason many medical institutions use VATS instead of open surgery. However, VATS is limited for superior mediastinal suprathoracic lesions. The magnified three-dimensional view and EndoWrist of the da Vinci system overcome the limitations of VATS. Thus, many European hospitals use the da Vinci Surgical System for thymectomies (28).

The da Vinci Surgical System has been used in mediastinal surgery for more than 10 years, especially for myasthenia gravis (29). In 2002, Yoshino *et al.* (30) reported the first robotic thymectomy. In 2009, Huang *et al.* (31) completed the first robotic thymectomy in China. After Bodner *et al.* (32,33) concluded that robotic thymectomy has obvious advantages, it became a routine surgery in many medical institutions. A study by Seong *et al.* (34) describing the treatment of anterior mediastinal tumors in 145 patients showed that robotic surgery is superior to open surgery and comparable to VATS. A retrospective study by Ding *et al.* (35) including 203 patients with mediastinal lesion showed that surgery time was comparable between robotic surgery and VATS. In addition, robotic surgery was superior to VATS regarding safety and recovery but costs more. Kajiwara *et al.* (36) also reported that the robotic surgery is comparable to traditional surgery but is safer and easier to perform than traditional surgery. Many medical institutions emphasize the importance of using a trocar, and the choice is dependent on the position of the tumor (31,34,35).

The flexible robotic arms can completely dissect the adipose tissue near the phrenic nerve completely. The superior vena cava and both innominate veins can be exposed safely and clearly, make it convenient and accurate to access the top of thymus, which has obvious advantages

in the removal of superior mediastinal tumors and is comparable to open surgery (37). Thymic veins, which are the primary vessels that must be dealt with in thymectomies, can be easily clamped, ligatured, and sutured in robotic surgery. The structure of the anterior mediastinum can be demonstrated clearly (38-40). A case series involving more than 50 patients at Shenyang Military Hospital (37) showed that the robotic surgery considerably reduced postoperative pain and discomfort caused by the pleural drainage tube, minimizing trauma and accelerating recovery. Robotic thymectomy is also used in certain patient populations, such as children, obese patients, and the elderly.

Other surgery

There are limited reports about other surgeries, such as Hellers' myotomy, hiatal hernia repair, diaphragmatic hernia repair, and esophagobronchial fistula repair. Tolboom *et al.* (41) reported that robotic surgery has no obvious advantage for hiatal hernia repair and gastroesophageal reflux surgery but has an advantage over a second surgery or huge hiatal hernia repair. Most of the reports were published in the early stage of robotic surgery use, and the primary aim was to accumulate experience.

Limitations

The maker of da Vinci Surgical System has a monopoly in the minimally invasive robotic surgery market. There are still some technical defects to overcome. For example, the mechanical fingers lack the force feedback (42) which make it difficult to judge tissue texture, elasticity, and vessel pulsatility and limits the determination of the tissue intersection and dissociation of vessels. This system is complex and carries a high possibility of operating problem that requires a specialized technician (43). Because the learning curve of the robotic system is relatively steep and prolonged, few surgeons have experience using this system. Wang *et al.* (7) concluded the surgeons should be skilled in VATS before learning robotic surgery, but Lee *et al.* (43) reported that there was no advantage for surgeons with VATS experience in learning robotic surgery. It is still controversial whether robotic surgery should be used in children. Cundy *et al.* (44,45) reported that in the future, robotic surgery systems matched to specific populations (e.g., children) will be developed. In addition, the high cost is another limitation of the da Vinci Surgical System.

Prospects

The da Vinci Surgical System, which represents precise MIS, reflects that trend in MIS development. In our analysis, the da Vinci Surgical System produces less tissue trauma, reduces postoperative complications, and shortens the recovery time compared with traditional VATS. This system has a broad application in MIS and is worth promotion. In the future, the da Vinci Surgical System will likely be miniaturized and have force-feedback technology. In addition, the Intuitive Surgical Inc. is developing a small highly integrated uniportal surgical robot, which could be a technological breakthrough. Along with the increase in yield and the realization of localization, the problem of high cost will be solved when robotic surgery is popularized in China in the near future.

Acknowledgements

None.

Footnote

Conflicts of Interest: The authors have no conflicts of interest to declare.

References

1. McKenna RJ Jr, Houck W, Fuller CB. Video-assisted thoracic surgery lobectomy: experience with 1,100 cases. *Ann Thorac Surg* 2006;81:421-425; discussion 425-426.
2. Detterbeck FC, Postmus PE, Tanoue LT. The stage classification of lung cancer: Diagnosis and management of lung cancer, 3rd ed: American College of Chest Physicians evidence-based clinical practice guidelines. *Chest* 2013;143:e191S-210S.
3. Palep JH. Robotic assisted minimally invasive surgery. *Journal of Minimal Access Surgery* 2009;5:1-7.
4. Byrn JC, Schluender S, Divino CM, et al. Three-dimensional imaging improves surgical performance for both novice and experienced operators using the da Vinci Robot System. *Am J Surg* 2007;193:519-522.
5. Xiu C. Da Vinci surgical robot in thoracic surgery. *Chin J Laparoscopic Surgery (Electronic Edition)* 2010;(4):3-6.
6. Bodner J, Wykypiel H, Greiner A, et al. Early experience with robot-assisted surgery for mediastinal masses. *Ann Thorac Surg* 2004;78:259-265; discussion 265-266.
7. Wang S, Xu S, Tong X, et al. Robotic lobectomy for non-

- small cell lung cancer(NSCLC). *Chin J Clin Thorac Cardiovasc Surg* 2013;(3):308-11.
8. Okada S, Tanaba Y, Sugawara H, et al. Thoracoscopic major lung resection for primary lung cancer by a single surgeon with a voice-controlled robot and an instrument retraction system. *J Thorac Cardiovasc Surg* 2000;120:414-415.
 9. Melfi FM, Menconi GF, Mariani AM, et al. Early experience with robotic technology for thoracoscopic surgery. *Eur J Cardiothorac Surg* 2002;21:864-868.
 10. Park BJ. Robotic lobectomy for non-small cell lung cancer: long-term oncologic results. *Thorac Surg Clin* 2014;24:157-162. vi.
 11. Hartwig MG, D'Amico TA. Thoracoscopic lobectomy: the gold standard for early-stage lung cancer? *Ann Thorac Surg* 2010;89:S2098-S2101.
 12. Pardolesi A, Park B, Petrella F, et al. Robotic anatomic segmentectomy of the lung: technical aspects and initial results. *Ann Thorac Surg* 2012;94:929-934.
 13. Schmid T, Augustin F, Kainz G, et al. Hybrid video-assisted thoracic surgery-robotic minimally invasive right upper lobe sleeve lobectomy. *Ann Thorac Surg* 2011;91:1961-1965.
 14. Yi J, Dong G, Xu B, et al. Application of da Vinci-S Surgical System to general thoracic surgery. *J Med Postgra* 2011;24:696-699.
 15. Brooks P. Robotic-Assisted Thoracic Surgery for Early-Stage Lung Cancer: A Review. *AORN J* 2015;102:40-49.
 16. Park BJ. Robotic lobectomy for non-small cell lung cancer (NSCLC): Multi-center registry study of long-term oncologic results. *Ann Cardiothorac Surg* 2012;1:24-26.
 17. Mahieu J, Rinieri P, Bubenheim M, et al. Robot-Assisted Thoracoscopic Surgery versus Video-Assisted Thoracoscopic Surgery for Lung Lobectomy: Can a Robotic Approach Improve Short-Term Outcomes and Operative Safety? *Thorac Cardiovasc Surg* 2016;64:354-362.
 18. Adams RD, Bolton WD, Stephenson JE, et al. Initial multicenter community robotic lobectomy experience: comparisons to a national database. *Ann Thorac Surg* 2014;97:1893-1898; discussion 1899-1900.
 19. Swanson SJ, Miller DL, McKenna RJ Jr, et al. Comparing robot-assisted thoracic surgical lobectomy with conventional video-assisted thoracic surgical lobectomy and wedge resection: Results from a multihospital database (Premier). *J Thorac Cardiovasc Surg* 2014;147:929-937.
 20. Horgan S, Berger RA, Elli EF, et al. Robotic-assisted minimally invasive transhiatal esophagectomy. *Am Surg* 2003;69:624-626.
 21. Kernstine KH, DeArmond DT, Karimi M, et al. The robotic, 2-stage, 3-field esophagolymphadenectomy. *J Thorac Cardiovasc Surg* 2004;127:1847-1849.
 22. Petri R, Zuccolo M, Brizzolari M, et al. Minimally invasive esophagectomy: thoracoscopic esophageal mobilization for esophageal cancer with the patient in prone position. *Surg Endosc* 2012;26:1102-1107.
 23. Ishikawa N, Kawaguchi M, Inaki N, et al. Robot-assisted thoracoscopic hybrid esophagectomy in the semi-prone position under pneumothorax. *Artif Organs* 2013;37:576-580.
 24. Dunn DH, Johnson EM, Morpew JA, et al. Robot-assisted transhiatal esophagectomy: a 3-year single-center experience. *Dis Esophagus* 2013;26:159-166.
 25. Mori K, Yamagata Y, Aikou S, et al. Short-term outcomes of robotic radical esophagectomy for esophageal cancer by a nontransthoracic approach compared with conventional transthoracic surgery. *Dis Esophagus* 2016;29:429-434.
 26. Mori K, Yamagata Y, Wada I, et al. Robotic-assisted totally transhiatal lymphadenectomy in the middle mediastinum for esophageal cancer. *J Robot Surg* 2013;7:385-387.
 27. Park SY, Kim DJ, Yu WS, et al. Robot-assisted thoracoscopic esophagectomy with extensive mediastinal lymphadenectomy: experience with 114 consecutive patients with intrathoracic esophageal cancer. *Dis Esophagus* 2016;29:326-332.
 28. Chen X, Han B, Guo W, et al. Robotic thymectomy and thymoma resection surgery. *Chin J Laparoscopic Surgery (Electronic Edition)* 2011;(4):37-9.
 29. Wang S, Li B, Xu S, et al. Robot-assisted Extended Thymectomy for Type I Myasthenia Gravis Using Da Vinci S System. *Chin J Clin Thorac Cardiovasc Surg* 2013;(6):679-82.
 30. Yoshino I, Hashizume M, Shimada M, et al. Video-assisted thoracoscopic extirpation of a posterior mediastinal mass using the da Vinci computer enhanced surgical system. *Ann Thorac Surg* 2002;74:1235-1237.
 31. Huang J, Luo Q, Zhao X, et al. Application of Robotic-assisted thoracoscopy in thymectomy. *Tumor* 2009;29:796-798.
 32. Bodner J, Wykypiel H, Wetscher G, et al. First experiences with the da Vinci operating robot in thoracic surgery. *Eur J Cardiothorac Surg* 2004;25:844-851.
 33. Bodner JC, Zitt M, Ott H, et al. Robotic-assisted thoracoscopic surgery (RATS) for benign and malignant esophageal tumors. *Ann Thorac Surg* 2005;80:1202-1206.
 34. Seong YW, Kang CH, Choi JW, et al. Early clinical outcomes of robot-assisted surgery for anterior mediastinal mass: its superiority over a conventional sternotomy

- approach evaluated by propensity score matching. *Eur J Cardiothorac Surg* 2014;45:e68-e73; discussion e73.
35. Ding R, Tong X, Xu S, et al. A comparative study of Da Vinci robot system with video-assisted thoracoscopy in the surgical treatment of mediastinal lesions. *Zhongguo Fei Ai Za Zhi* 2014;17:557-562.
 36. Kajiwaru N, Kakihana M, Kawate N, et al. Appropriate set-up of the da Vinci Surgical System in relation to the location of anterior and middle mediastinal tumors. *Interact Cardiovasc Thorac Surg* 2011;12:112-116.
 37. Xu SG, Wang SM. Experience of da Vinci robot-assisted thoracic surgery of 500 patients. *Chin J Clin Thorac Cardiovasc Surg* 2015;22:895-900.
 38. Augustin F, Schmid T, Sieb M, et al. Video-assisted thoracoscopic surgery versus robotic-assisted thoracoscopic surgery thymectomy. *Ann Thorac Surg* 2008;85:S768-S771.
 39. Rea F, Marulli G, Bortolotti L, et al. Experience with the "da Vinci" robotic system for thymectomy in patients with myasthenia gravis: report of 33 cases. *Ann Thorac Surg* 2006;81:455-459.
 40. Cakar F, Werner P, Augustin F, et al. A comparison of outcomes after robotic open extended thymectomy for myasthenia gravis. *Eur J Cardiothorac Surg* 2007;31:501-504; discussion 504-505.
 41. Tolboom RC, Broeders IA, Draaisma WA. Robot-assisted laparoscopic hiatal hernia and antireflux surgery. *J Surg Oncol* 2015;112:266-270.
 42. Reiley CE, Akinbiyi T, Burschka D, et al. Effects of visual force feedback on robot-assisted surgical task performance. *J Thorac Cardiovasc Surg* 2008;135:196-202.
 43. Lee BE, Korst RJ, Kletsman E, et al. Transitioning from video-assisted thoracic surgical lobectomy to robotics for lung cancer: are there outcomes advantages? *J Thorac Cardiovasc Surg* 2014;147:724-729.
 44. Cundy TP, Marcus HJ, Hughes-Hallett A, et al. Robotic surgery in children: adopt now, await, or dismiss? *Pediatr Surg Int* 2015;31:1119-1125.
 45. Cundy TP, Shetty K, Clark J, et al. The first decade of robotic surgery in children. *J Pediatr Surg* 2013;48:858-865.

doi: 10.21037/amj.2017.01.02

Cite this article as: Wu H, Li H. Application of the da Vinci in thoracic surgery. *AME Med J* 2017;2:9.

Robotic-assisted thoracoscopic surgery: right lower lobectomy

Su Yang, Wei Guo, Runsen Jin, Yajie Zhang, Xingshi Chen, Han Wu, Hailei Du, Dingpei Han, Kai Chen, Jie Xiang, Hecheng Li

Department of Thoracic Surgery, Ruijin Hospital, Shanghai Jiao Tong University, School of Medicine, Shanghai 200025, China

Correspondence to: Hecheng Li, MD, PhD. Department of Thoracic Surgery, Ruijin Hospital, Shanghai Jiao Tong University, School of Medicine, 197 Ruijin Er Road, Shanghai 200025, China. Email: lihecheng2000@hotmail.com.

Abstract: Robotic-assisted surgery is now well established and has been introduced into the field of thoracic surgery. We are going to share the experience of robotic surgery for right lower lobectomy. A 61-year-old patient underwent robotic-assisted thoracic surgery for a primary lung adenocarcinoma. The patient was discharged on postoperative day 6 without any perioperative complications. The pathological stage was T1aN0M0 (stage IA). Our result showed the robotic-assisted thoracoscopic surgery was a safe and feasible surgical approach for non-small cell lung cancer (NSCLC).

Keywords: Robotic-assisted thoracoscopic surgery; right lower lobectomy

Received: 02 December 2016; Accepted: 27 December 2016; Published: 08 February 2017.

doi: 10.21037/amj.2017.01.05

View this article at: <http://dx.doi.org/10.21037/amj.2017.01.05>

Clinical data

A 61-year old woman with chronic obstructive pulmonary disease but no history of smoking was found to have a right lower lobe mass by computed tomography (CT) scan during health checkup. Adenocarcinoma was diagnosed by lung puncture. The right main and upper lobe bronchus were not involved. Positron emission tomography (PET)-CT and cerebral magnetic resonance imaging showed no distant metastasis. Preoperative blood analysis and tests of lung, cardiac, liver and renal function were normal. No superficial lymph node enlargement was detected on physical examination. The clinical stage was cT1N0M0. Informed consent for robotic-assisted thoracic lobectomy was obtained from patient before operation (*Figure 1*).

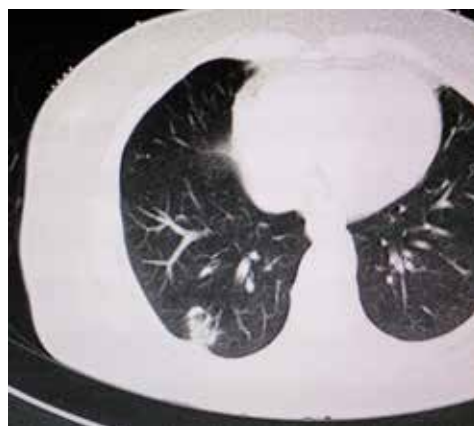

Figure 1 Chest CT: the mass was located in the right inferior lobe.

Procedure

Anesthesia and body position

The patient received general anesthesia by double-lumen endotracheal intubation and was placed in the lateral decubitus position and in a jackknife position (*Figure 2*).

The port positions

After the patient was prepped and draped in the usual

manner, we placed five ports as follows: a 12-mm camera port was placed in the 8th intercostal space (ICS) at the mid axillary line, and three 10-mm working ports were placed separately in the 5th ICS at anterior axillary line (#1 arm), 8th ICS at the right posterior axillary line (#2 arm), and the right 8th ICS which was 2 cm from the spine (#3 arm). Finally, an auxiliary port was created in the 7th ICS between the camera port and the right working port, about 8-cm far from the right working port (*Figure 3*).

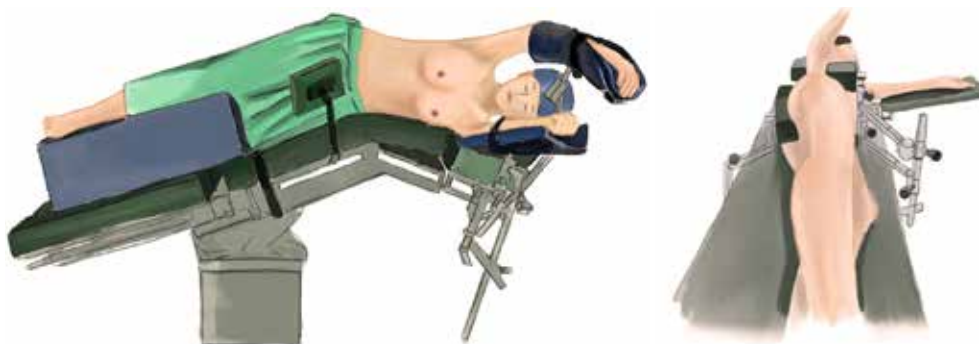

Figure 2 Jackknife position.

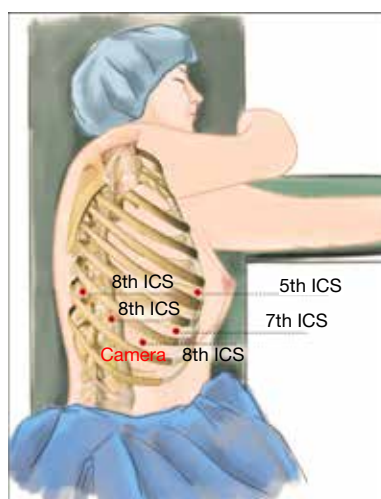


Figure 3 Ports in the 5th, 7th, and 8th ICS. ICS, intercostal space.

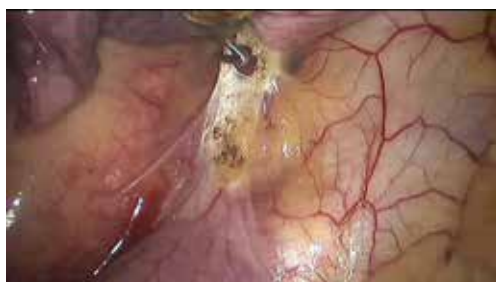

Figure 4 The inferior pulmonary ligament was dissociated using the cautery hook to the inferior pulmonary vein level.

Connection of robot patient cart

The robot patient cart was positioned directly above the operating table. Two bipolar forceps and one unipolar cautery hook were attached to the arms.

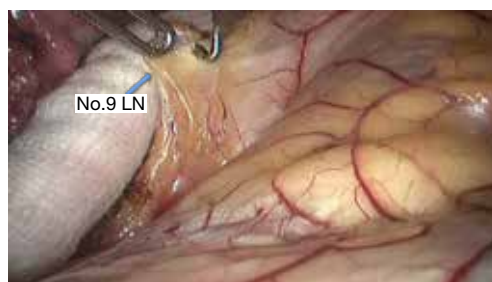


Figure 5 The lymph nodes in the inferior pulmonary ligament (No. 9) were removed.

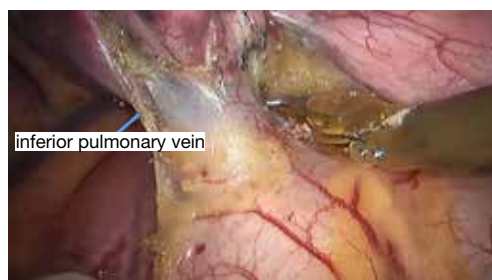

Figure 6 The inferior pulmonary vein was dissociated.

Surgical procedure

See Figures 4-22.

Postoperative outcome

The patient was routinely given anti-inflammatory and phlegm resolving treatment postoperatively. The chest tube was withdrawn after 2 days, and the patient was discharged 6 days later after surgery. No complications were occurred during hospitalization. The pathological stage was

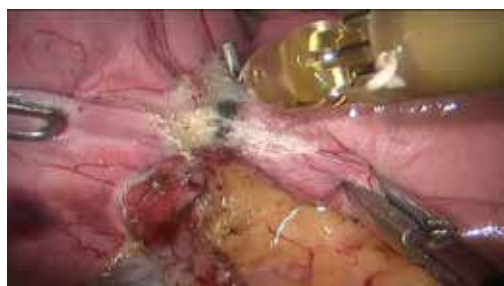

Figure 7 The interlobar adhesion was dissected using the cautery hook.

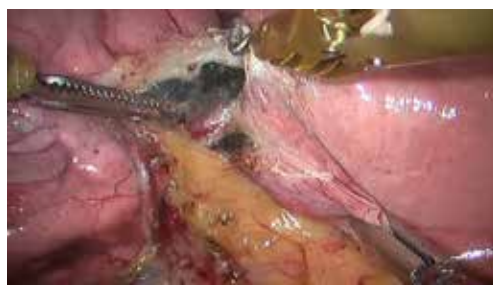

Figure 11 The interlobar lymph nodes were removed.

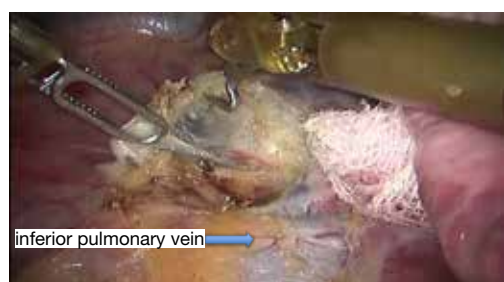

Figure 8 The lung was pushed anteriorly and cut open the posterior pleura.

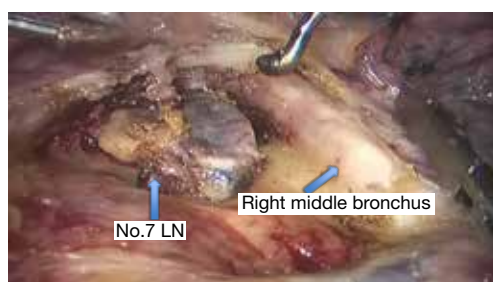


Figure 12 The subcarinal lymph nodes (No.7) were exposed and removed.

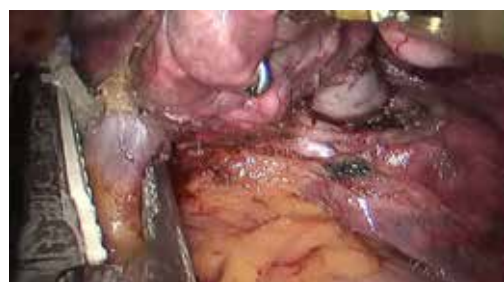

Figure 9 The right inferior pulmonary vein was transected using the Echelon flex.

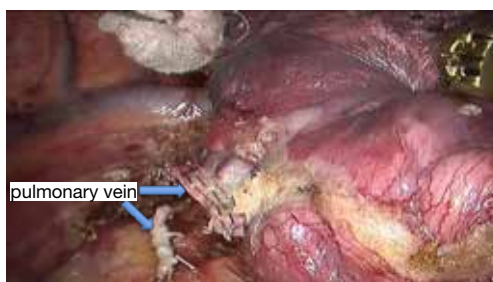


Figure 13 The right inferior pulmonary vein was transected.

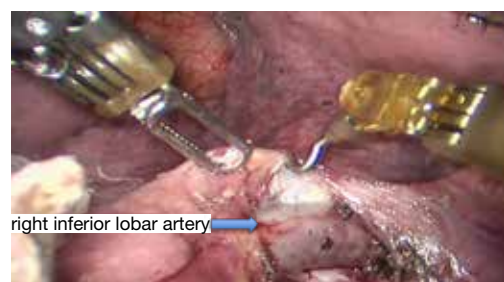


Figure 10 The pulmonary artery to the lower lobe was isolated.

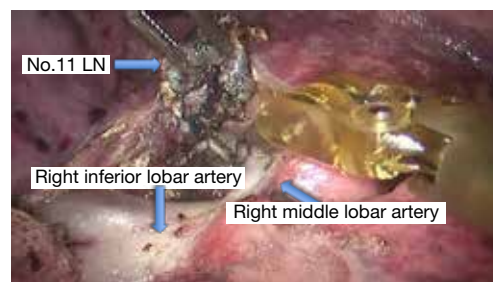


Figure 14 The interlobar lymph nodes were removed.

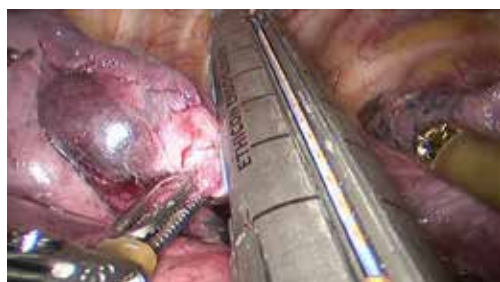

Figure 15 The oblique fissure was dissected using the Echelon flex.

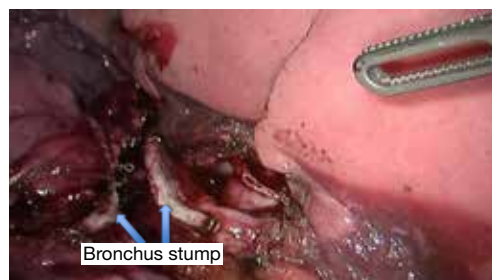


Figure 19 The inferior pulmonary bronchus was transected.



Figure 16 The pulmonary artery of the lower lobe was transected using the Echelon flex.

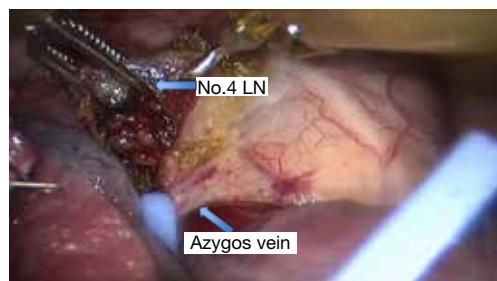


Figure 20 The azygos vein was pulled with elastic line, and the lymph nodes near the trachea were removed.

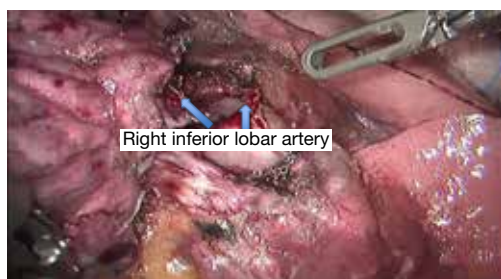


Figure 17 The pulmonary artery of the lower lobe was transected.

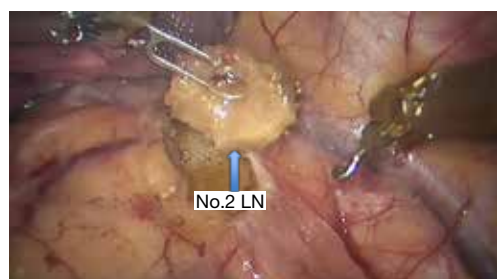

Figure 21 The lymph nodes in front of the trachea (No.2) were removed.

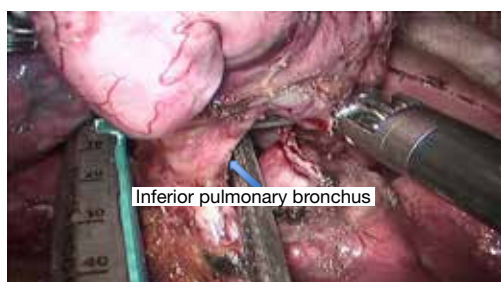


Figure 18 The inferior pulmonary bronchus was transected using the Echelon flex.

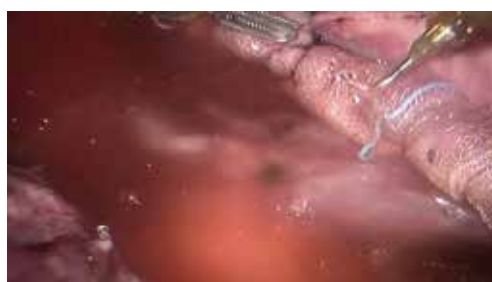

Figure 22 The bronchial stump leak test was negative.

T1aN0M0 (stage IA).

Comment

Currently in our institution, the 3- or 4-arm method is mainly used. When the patient has a small physique, the 3-arm method may reduce interference between arms. However, the 4-arm method become more popular, because the visual field can be set at any angle in the thoracic cavity. Therefore, the position of each port is important. Nakamura *et al.* suggested a 9-cm distance should be set between ports to reduce interference between surgical arms (1). In our experience, a distance of 8–10 cm effectively reduces the interference between arms. Cerfolio *et al.* described a complete robotic lobectomy setting all the ports concentrating in the 7th ICS (2,3), and this method was considered applicable for all lobectomies (1).

Acknowledgements

None.

doi: 10.21037/amj.2017.01.05

Cite this article as: Yang S, Guo W, Jin R, Zhang Y, Chen X, Wu H, Du H, Han D, Chen K, Xiang J, Li H. Robotic-assisted thoracoscopic surgery: right lower lobectomy. AME Med J 2017;2:14.

Footnote

Conflicts of Interest: The authors have no conflicts of interest to declare.

Informed Consent: Written informed consent was obtained from the patient for publication of this manuscript and any accompanying images.

References

1. Nakamura H, Taniguchi Y. Robot-assisted thoracoscopic surgery: current status and prospects. *Gen Thorac Cardiovasc Surg* 2013;61:127-132.
2. Cerfolio RJ, Bryant AS, Skylizard L, et al. Initial consecutive experience of completely portal robotic pulmonary resection with 4 arms. *J Thorac Cardiovasc Surg* 2011;142:740-746.
3. Cerfolio RJ, Bryant AS, Minnich DJ. Starting a robotic program in general thoracic surgery: why, how, and lessons learned. *Ann Thorac Surg* 2011;91:1729-1736; discussion 1736-1737.

Robotic lobectomy: revolution or evolution?

Jules Lin

Section of Thoracic Surgery, Department of Surgery, University of Michigan Medical Center, Ann Arbor, Michigan, USA

Correspondence to: Jules Lin, MD. Associate Professor and Mark B. Orringer Professor, Section of Thoracic Surgery, Department of Surgery, University of Michigan Medical Center, 1500 E. Medical Center Drive, 2120TC/5344, Ann Arbor, MI 48109-5344, USA. Email: juleslin@umich.edu.

Provenance: This is an invited Editorial commissioned by Section Editor Jianfei Shen, MD (Department of Cardiothoracic Surgery, Taizhou Hospital of Zhejiang Province, Wenzhou Medical University, Taizhou, China).

Comment on: Yang S, Guo W, Jin R, *et al.* Robotic-assisted thoracoscopic surgery: right lower lobectomy. AME Med J 2017;2:14.

Submitted Aug 05, 2017. Accepted for publication Aug 10, 2017.

doi: 10.21037/jtd.2017.08.69

View this article at: <http://dx.doi.org/10.21037/jtd.2017.08.69>

In their case report “Robotic-assisted thoracoscopic surgery: right lower lobectomy”, Yang *et al.* described their technique for performing a robotic lobectomy (1). They highlight several advantages of a robotic approach and provide good illustrative photos. While robotic surgery provides advantages for the surgeon in terms of dexterity and visualization, the question remains how these advantages affect patient outcomes and whether the robotic approach is a true revolution or an evolution from other minimally invasive approaches.

Thoracoscopic lobectomy

Jacobeus first used thoracoscopy in 1910. Video assisted thoracoscopic surgery (VATS) is a minimally invasive approach and is associated with less pain, shorter recovery time, less tissue trauma, and improved cosmetic results compared to thoracotomy. While there were initial concerns about oncologic outcomes, several studies have shown that outcomes are equivalent to open lobectomy with less pain, decreased postoperative complications, shorter chest tube duration, and decreased length of stay (2-4).

Some studies have even suggested that patients undergoing minimally invasive approaches have improved long-term survival (5). This difference is thought to be due to decreased immunologic and stress responses after minimally invasive surgery. Quicker recovery after thoracoscopic lobectomy may also result in earlier adjuvant chemotherapy. Peterson, *et al.* found fewer delayed or reduced doses of chemotherapy with 61% of VATS patients receiving more than 75% of their chemotherapy doses compared to only 40% after open

lobectomy (6). Clinical trials evaluating adjuvant treatment for resected non-small cell lung cancer have shown that approximately half of all patients actually received the planned dose of chemotherapy. For early stage, non-small cell lung cancer, surgery has become the mainstay of treatment, and VATS lobectomy has become the treatment of choice.

Robotic lobectomy

However, there is a learning curve associated with complex thoracoscopic procedures such as lobectomy due to reduced tactile sensation, counterintuitive hand-eye coordination, and loss of degrees of freedom. Robotic surgery was developed to overcome some of these challenges by combining three-dimensional imaging, improved hand-eye coordination, and greater degrees of freedom improving dexterity. Although robotic-assisted thoracic surgery (RATS) may provide advantages over VATS in terms of dexterity and degrees of freedom, a significant increase in cost has been shown in some studies (7,8). In addition, a reduction in tactile sensation, one of the disadvantages of VATS, is increased with RATS due to a lack of haptic feedback, which could lead to tissue damage especially for inexperienced surgeons. Some groups have been working on haptic feedback, and early results are promising. However, the benefits of RATS lobectomy need to be clearly defined especially in light of higher hospital costs and longer operating times (7,8).

Learning curve

Similar to VATS lobectomy, where there is a learning curve

of up to 50 cases (9), there is a learning curve associated with transitioning to robotic lobectomy. Fahim *et al.* evaluated 167 RATS lobectomies and found that the total duration of surgery and console time decreased significantly with a steady decline until the 20th case (10). Toker *et al.* reported a learning curve of 14 cases (11) while Meyer *et al.* described a learning curve of 18 ± 3 cases based on operative times, mortality, and surgeon comfort with a trend towards lower morbidity and decreased length of stay with greater experience (12). They concluded that the learning curve may be less for surgeons experienced with VATS. During this learning curve, it is essential to have appropriate mentorship available with a low threshold to convert to either a VATS approach or an open thoracotomy when needed. Case reports and series such as the one by Yang *et al.* as well as videos outlining expert techniques may help to shorten this learning curve (1).

Port placement and positioning

Yang *et al.* describe their port placement with 3 ports in the 8th intercostal space (1). Keeping the ports in the same interspace may help to decrease postoperative pain. The port in the 5th intercostal space may be slightly high. With the introduction of the robotic stapler, keeping the anterior-most port as anterior and inferior as possible gives the robotic stapler more length to fully roticulate. Placing the assistant port more inferiorly may also help prevent interference between the robotic arms and the bedside assistant. Careful patient positioning is important to drop the hip away from the camera. Another important point, which was not specifically stated by Yang *et al.* is the use of carbon dioxide insufflation at 5–8 mmHg to push down the diaphragm and improve exposure. Gauze rolls can also be used to help maintain a bloodless field and also serves as a sponge to tamponade any significant bleeding, which is important when a utility incision is not used and the surgeon is at the robotic console and not at the bedside.

Outcomes

Initial VATS lobectomy studies were difficult to compare due to differences in how VATS was defined in each study. Currently, VATS lobectomy is most often described as defined in the CALGB 39802 trial with a 4–8 cm access incision, a totally thoracoscopic approach without rib spreading, and individual dissection and division of the

pulmonary vein, arterial branches, and the bronchus. In order to compare outcomes between robotic studies, it will be important to use standard definitions to define robotic surgery, including the number of robotic arms, the number of ports, and whether a utility incision was used. It will also be important to propensity match VATS, open, and robotic cohorts to ensure that similar comparisons are being made. For example, most minimally-invasive surgeons, may only perform open lobectomies for more advanced, central tumors or after neoadjuvant chemoradiation. There may also be differences in patient selection between robotic and VATS approaches, especially early in a surgeon's experience.

Several studies have shown at least equivalent long-term survival after VATS compared to open lobectomy (3,4). Several studies have shown that RATS lobectomy can be performed safely by experienced thoracic surgeons with no significant differences in morbidity or mortality (8,13,14). Evaluating 8,253 RATS lobectomies in the Healthcare Cost and Utilization Project National Inpatient Sample, Tchouta *et al.* found that high-volume centers had a shorter LOS and decreased mortality (15). Yang *et al.* evaluated 30,040 lobectomies for stage I lung carcinoma (7,824 VATS and 2,025 RATS) in the National Cancer Database and found that MIS approaches were associated with increased 30-day readmission but shorter LOS and improved 2-year survival (16).

Some have reported significant differences in outcomes compared to VATS. Liang *et al.* performed a meta-analysis of 14 studies including 7,438 patients undergoing lobectomy or segmentectomy (17). The 30-day mortality was lower for RATS versus VATS (0.7% *vs.* 1.1%) while conversion to thoracotomy was lower at 10.3% versus 11.9%. There were no significant differences in postoperative complications, OR time, LOS, or chest tube removal. Louie *et al.* evaluated 1,220 robotic and 12,378 VATS lobectomies in the STS General Thoracic Surgery Database and found that operative times were longer for RATS, but complications, hospital stay, 30-day mortality, and nodal upstaging were equivalent (18). Paul *et al.* evaluated 2,498 robotic-assisted and 37,595 thoracoscopic lobectomies in the Nationwide Inpatient Sample and found a higher risk of iatrogenic bleeding complications of 5.0% versus 2.0% with an odds ratio of 2.64 on multivariable analysis (19). Kent *et al.* evaluated multiple State Inpatient Databases including 33,095 patients (20,238 open, 12,427 VATS, and 430 RATS) and found a reduction in mortality (0.2% versus 1.1%), LOS, and complication rates although this was not significant (20).

Lymph node dissection

There were initial concerns that VATS lobectomy could compromise nodal evaluation. However, several studies have found VATS mediastinal lymph node dissection (MLND) to be equivalent to thoracotomy. Some have reported that RATS MLND may have potential benefits in nodal staging (2,7). Wilson *et al.* evaluated 302 patients in the STS Database and found nodal upstaging in 7.4%, 8.8%, and 11.5% after RATS and 5.2%, 7.1%, and 5.7% after VATS for T1a, T1b, and T2a tumors respectively (21). The authors concluded that the rate of nodal upstaging for robotic resection appears to be superior to VATS and is similar to thoracotomy. Disease-free and overall survival were similar to recent VATS series.

On the other hand, Louie *et al.* evaluated 1,220 robotic and 12,378 VATS lobectomies in the STS General Thoracic Surgery Database and found no difference in nodal upstaging (18). Liang *et al.* found no difference in the number of retrieved lymph nodes or lymph node stations (17), and Yang *et al.* evaluated the National Cancer Database for patients undergoing lobectomy for stage I lung carcinomas and found no significant difference in nodal upstaging (16). Rajaram *et al.* evaluated 62,206 patients in the National Cancer Database and found that fewer lymph nodes were obtained, and more than 12 lymph nodes were examined less frequently with RATS (22).

Pain

While RATS offers certain technical advantages for the surgeon, the benefits to the patient in terms of acute and chronic pain outcomes is less clear. Several studies have shown a decrease in postoperative pain after VATS lobectomy including improved perioperative and long-term pain control. Although Nasir *et al.* did not directly compare robotic and VATS lobectomy, they found minimal morbidity, mortality, and pain after RATS with a median pain score of 2/10 at the 3-week postoperative visit, but no acute pain data was provided from the perioperative course, and the only comparison group was 41 patients converted to thoracotomy (23). In terms of chronic pain, Nomori *et al.* found no significant difference in chronic pain between VATS lobectomy, limited thoracotomy for segmentectomy, or open thoracotomy for segmentectomy (24). Thoracotomy was associated with significantly higher acute pain scores.

In a recent study by Kwon *et al.*, there was no significant difference in terms of acute or chronic pain outcomes

or morphine equivalents used between VATS and RATS lobectomy (25). Even though there was no difference in pain scores, more RATS patients (69.2%) felt that the robotic approach affected their pain positively, suggesting a difference between reality and perception. This likely reflects patients who feel that they are receiving the latest technology and successful marketing that the latest technology is better. There was a significant increase in acute pain scores and chronic numbness in patients undergoing thoracotomy compared to MIS.

Cost

Paul *et al.* evaluated 2,498 robotic-assisted and 37,595 thoracoscopic lobectomies in the Nationwide Inpatient Sample and found that RATS lobectomy costs significantly more than VATS lobectomy (\$22,582 *vs.* \$17,874) (19). Swanson *et al.* evaluated 15,503 patients including 14,837 undergoing VATS lobectomy in the Premier database (8). RATS had higher average hospital costs and longer operating times without any differences in adverse events.

Conclusions

Robotic surgery addresses some of the shortcomings of VATS by providing improved dexterity and visualization. Although no randomized comparisons are available and benefits in terms of quality of life and pain need to be further evaluated, a robotic approach appears to have at least equivalent outcomes to VATS in several studies across multiple centers. There is a significant learning curve, but with appropriate mentorship and team training, robotic lobectomy can be performed safely by experienced thoracic surgeons. Cost effectiveness will need to be considered as well but will likely improve with the introduction of new robotic platforms and more widespread adoption of robotic surgery. The technology will continue to improve with new techniques to visualize tumors, the use of energy devices to divide vessels, and haptic feedback as well as the increased use of RATS for more advanced pulmonary resections including segmentectomy, bilobectomy, and sleeve resection in selected cases. With increasing experience, more surgeons performing robotic thoracic surgery, and increasing patient demand, there is a need for further research on outcomes after RATS lobectomy. Lobectomy can be performed thoracoscopically with similar outcomes. Robotic lobectomy may not be truly revolutionary, but RATS provides the next step in the evolution of minimally-invasive thoracic surgery

and may provide access to minimally invasive approaches to more patients and surgeons, including those without previous VATS experience.

Acknowledgements

None.

Footnote

Conflicts of Interest: The author has no conflicts of interest to declare.

References

1. Yang S, Guo W, Jin R, et al. Robotic-assisted thoracoscopic surgery: right inferior lobectomy. *AME Med J* 2017;2:14.
2. Swanson SJ, Herndon JE 2nd, D'Amico TA, et al. Video-assisted thoracic surgery lobectomy: report of CALGB 39802--a prospective, multi-institution feasibility study. *J Clin Oncol* 2007;25:4993-4997.
3. McKenna RJ Jr, Houck W, Fuller CB. Video-assisted thoracic surgery lobectomy: experience with 1,100 cases. *Ann Thorac Surg* 2006;81:421-425; discussion 425-426.
4. Onaitis MW, Petersen RP, Balderson SS, et al. Thoracoscopic lobectomy is a safe and versatile procedure: experience with 500 consecutive patients. *Ann Surg* 2006;244:420-425.
5. Kaseda S, Aoki T, Hangai N, et al. Better pulmonary function and prognosis with video-assisted thoracic surgery than with thoracotomy. *Ann Thorac Surg* 2000;70:1644-1646.
6. Petersen RP, Pham D, Burfeind WR, et al. Thoracoscopic lobectomy facilitates the delivery of chemotherapy after resection for lung cancer. *Ann Thorac Surg* 2007;83:1245-1249; discussion 1250.
7. Augustin F, Bodner J, Maier H, et al. Robotic-assisted minimally invasive vs. thoracoscopic lung lobectomy: comparison of perioperative results in a learning curve setting. *Langenbecks Arch Surg* 2013;398:895-901.
8. Swanson SJ, Miller DL, McKenna RJ Jr, et al. Comparing robot-assisted thoracic surgical lobectomy with conventional video-assisted thoracic surgical lobectomy and wedge resection: results from a multihospital database (Premier). *J Thorac Cardiovasc Surg* 2014;147:929-937.
9. McKenna RJ Jr. Complications and learning curves for video-assisted thoracic surgery lobectomy. *Thorac Surg Clin* 2008;18:275-280.
10. Fahim C, Hanna W, Waddell T, et al. Robotic-assisted thoracoscopic surgery for lung resection: the first Canadian series. *Can J Surg* 2017;60:260-265.
11. Toker A, Ozyurtkan MO, Kaba E, et al. Robotic anatomic lung resections: the initial experience and description of learning in 102 cases. *Surg Endosc* 2016;30:676-683.
12. Meyer M, Gharagozloo F, Tempesta B, et al. The learning curve of robotic lobectomy. *Int J Med Robot* 2012;8:448-452.
13. Cao C, Manganas C, Ang SC, et al. A systematic review and meta-analysis on pulmonary resections by robotic video-assisted thoracic surgery. *Ann Cardiothorac Surg* 2012;1:3-10.
14. Park BJ, Melfi F, Mussi A, et al. Robotic lobectomy for non-small cell lung cancer (NSCLC): long-term oncologic results. *J Thorac Cardiovasc Surg* 2012;143:383-389.
15. Tchouta LN, Park HS, Boffa DJ, et al. Hospital Volume and Outcomes of Robot-Assisted Lobectomies. *Chest* 2017;151:329-339.
16. Yang CF, Sun Z, Speicher PJ, et al. Use and Outcomes of Minimally Invasive Lobectomy for Stage I Non-Small Cell Lung Cancer in the National Cancer Data Base. *Ann Thorac Surg* 2016;101:1037-1042.
17. Liang H, Liang W, Zhao L, et al. Robotic Versus Video-assisted Lobectomy/Segmentectomy for Lung Cancer: A Meta-analysis. *Ann Surg* 2017. [Epub ahead of print].
18. Louie BE, Wilson JL, Kim S, et al. Comparison of Video-Assisted Thoracoscopic Surgery and Robotic Approaches for Clinical Stage I and Stage II Non-Small Cell Lung Cancer Using The Society of Thoracic Surgeons Database. *Ann Thorac Surg* 2016;102:917-924.
19. Paul S, Jalbert J, Isaacs AJ, et al. Comparative effectiveness of robotic-assisted vs thoracoscopic lobectomy. *Chest* 2014;146:1505-1512.
20. Kent M, Wang T, Whyte R, et al. Open, video-assisted thoracic surgery, and robotic lobectomy: review of a national database. *Ann Thorac Surg* 2014;97:236-242; discussion 242-244.
21. Wilson JL, Louie BE, Cerfolio RJ, et al. The prevalence of nodal upstaging during robotic lung resection in early stage non-small cell lung cancer. *Ann Thorac Surg* 2014;97:1901-6; discussion 6-7.
22. Rajaram R, Mohanty S, Bentrem DJ, et al. Nationwide Assessment of Robotic Lobectomy for Non-Small Cell Lung Cancer. *Ann Thorac Surg* 2017;103:1092-1100.
23. Nasir BS, Bryant AS, Minnich DJ, et al. Performing robotic lobectomy and segmentectomy: cost, profitability, and outcomes. *Ann Thorac Surg* 2014;98:203-208;

discussion 208-209.

24. Nomori H, Cong Y, Sugimura H. Limited thoracotomy for segmentectomy: a comparison of postoperative pain with thoracoscopic lobectomy. *Surg Today* 2016;46:1243-1248.

25. Kwon ST, Zhao L, Reddy RM, et al. Evaluation of acute and chronic pain outcomes after robotic, video-assisted thoracoscopic surgery, or open anatomic pulmonary resection. *J Thorac Cardiovasc Surg* 2017;154:652-9.e1.

Cite this article as: Lin J. Robotic lobectomy: revolution or evolution? *J Thorac Dis* 2017;9(9):2876-2880. doi: 10.21037/jtd.2017.08.69

Robotic-assisted thoracoscopic surgery: a promising surgical method

Su Yang, Hecheng Li

Department of Thoracic Surgery, Ruijin Hospital, Shanghai Jiao Tong University School of Medicine, Shanghai 200025, China

Correspondence to: Professor Hecheng Li. Department of Thoracic Surgery, Ruijin Hospital, Shanghai Jiao Tong University School of Medicine, 197 Ruijin 2nd Road, Shanghai 200025, China. Email: lihecheng2000@hotmail.com.

Provenance: This is an invited article commissioned by the Section Editor Jianfei Shen, MD (Department of Cardiothoracic Surgery, Taizhou Hospital of Zhejiang Province, Wenzhou Medical University, Taizhou, China).

Response to: Lin J. Robotic lobectomy: Revolution or evolution? J Thorac Dis 2017;9:2876-80.

Submitted Sep 25, 2017. Accepted for publication Oct 13, 2017.

doi: 10.21037/jtd.2017.10.57

View this article at: <http://dx.doi.org/10.21037/jtd.2017.10.57>

We appreciate the thoughtful and constructive comments by Dr. Jules Lin on our article “*Robotic-assisted thoracoscopic surgery: right lower lobectomy*” (1). Your comments were valuable and helpful in improving our paper. We have studied your comments carefully and have made the suggested corrections, which we hope will meet with your approval. Our responses to your comments are below.

- (I) I regret that we did not mention the use of carbon dioxide insufflation in our manuscript because it is an essential step in robot-assisted thoracic surgery (RATS). In our center, we usually placed the working ports in the 5th or 6th intercostal space—we considered the 6th intercostal space to be more suitable, but in patients with smaller intercostal spaces, the 5th intercostal space may be more appropriate.
- (II) Currently in China, RATS is significantly more costly than video-assisted thoracic surgery (VATS), but as robot technology becomes more popular, the costs is likely to gradually decrease.
- (III) Young *et al.* recently performed a review analyzing postoperative pain following uniportal VATS (UVATS) and conventional VATS. This study was unable to demonstrate that UVATS conferred less postoperative pain than conventional VATS (2). Nevertheless, we believe that a prospective study is required to compare postoperative pain from RATS and VATS.
- (IV) Louie *et al.* described the dissection of many N1-

level lymph nodes (LNs) using RATS, and this report gave surgeons greater confidence to dissect N1-LNs adjacent to the pulmonary artery (3). Cerfolio *et al.* and Veronesi *et al.* showed that dissections of LNs using RATS were comparable to thoracotomies (4,5). We found that RATS has the advantage of allowing an LN dissection to be performed at any angle of visual field because the arms of the robotic system are flexible.

Acknowledgements

We would like to acknowledge David Tian, Senior Editor of AME Publishing Company, for editing support.

Footnote

Conflicts of Interest: The authors have no conflicts of interest to declare.

References

1. Lin J. Robotic lobectomy: Revolution or evolution? J Thorac Dis 2017;9:2876-2880.
2. Young R, McElnay P, Leslie R, et al. Is uniportal thoracoscopic surgery less painful than multiple port approaches? Interact Cardiovasc Thorac Surg 2015;20:409-414.
3. Louie BE, Farivar AS, Aye RW, et al. Early experience

with robotic lung resection results in similar operative outcomes and morbidity when compared with matched video-assisted thoracoscopic surgery cases. *Ann Thorac Surg* 2012;93:1598-1604; discussion 1604-1605.

4. Cerfolio RJ, Bryant AS, Skylizard L, et al. Initial consecutive experience of completely portal robotic

pulmonary resection with 4 arms. *J Thorac Cardiovasc Surg* 2011;142:740-746.

5. Veronesi G, Galetta D, Maisonneuve P, et al. Four-arm robotic lobectomy for the treatment of early-stage lung cancer. *J Thorac Cardiovasc Surg* 2010;140:19-25.

Cite this article as: Yang S, Li H. Robotic-assisted thoracoscopic surgery: a promising surgical method. *J Thorac Dis* 2017;9(10):E960-E961. doi: 10.21037/jtd.2017.10.57

Robotic-assisted right middle lobectomy

Xingshi Chen, Su Yang, Wei Guo, Runsen Jin, Yajie Zhang, Han Wu, Hailei Du, Dingpei Han, Kai Chen, Jie Xiang, Hecheng Li

Department of Thoracic Surgery, Ruijin Hospital, Shanghai Jiao Tong University, School of Medicine, Shanghai 200025, China

Correspondence to: Hecheng Li, MD, PhD. Department of Thoracic Surgery, Ruijin Hospital, Shanghai Jiao Tong University, School of Medicine, 197 Ruijin Er Road, Shanghai 200025, China. Email: lihecheng2000@hotmail.com.

Abstract: *Da Vinci* surgical system has been widely used in thoracic surgery as a new technique. We are going to share the experience of robotic surgery for right middle lobectomy. A 48-year-old patient with a ground-glass opacity (GGO) underwent robotic-assisted right middle lobectomy in our center. The patient was discharged on postoperative day 4 without any perioperative complications. The pathological stage was T1aN0M0 (stage IA).

Keywords: Robot-assisted surgery; lung cancer; minimally invasive; lobectomy

Received: 02 December 2016; Accepted: 27 December 2016; Published: 21 January 2017.

doi: 10.21037/amj.2017.01.07

View this article at: <http://dx.doi.org/10.21037/amj.2017.01.07>

Clinical data

Medical history

A ground-glass opacity (GGO) was detected in the medial segment of the right middle lung lobe of a 48-year-old man about one year ago during a regular medical examination. He did not have any symptoms (e.g., chest tightness, shortness of breath, cough, or expectoration) at that time; therefore, we suggested he undergo regular re-examinations. Result of a computed-tomography (CT) scan one month ago still indicated a 0.9-cm GGO in the same position. The patient still had no symptoms. Positron emission tomography-CT showed hypermetabolism in this nodule. The patient's physical performance was good, and his appetite, sleep, urination, and defecation were normal. His body weight did not change significantly. He denied smoking or alcohol abuse, and family history.

Physical examination

A complete physical examination was performed when the patient was admitted. No abnormality was found. No lymph nodes were palpable in the neck, axilla, or below the clavicle.

Auxiliary examination

Chest CT showed a 1.1-cm elliptic GGO in the right

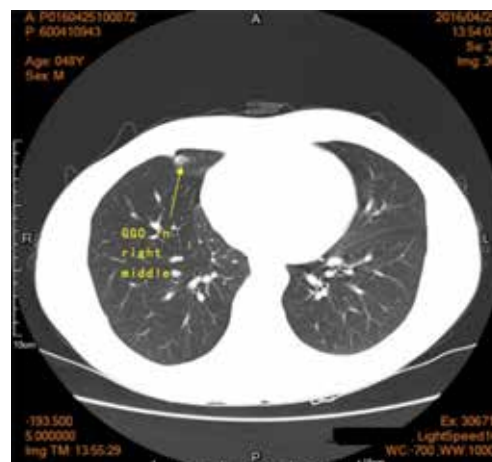


Figure 1 The GGO was located in the right middle lung lobe. GGO, ground-glass opacity.

middle lung lobe, with clear margins, without lobulation sign, spiculation or vacuole sign (*Figure 1*). No abnormality was found in the lung hila. No abnormal lymph nodes were found in the mediastinum.

PET/CT showed hypermetabolism in the nodule of the right middle lung lobe.

Abdominal ultrasound scan, bone scan, cranial magnetic resonance imaging, echocardiogram, and pulmonary

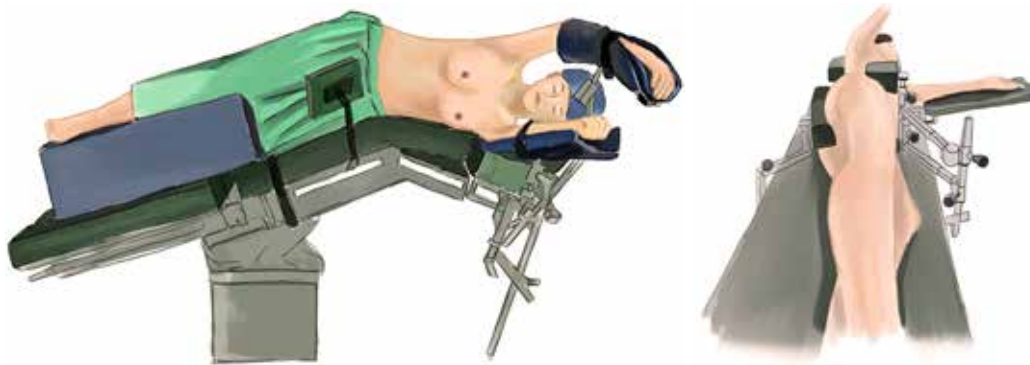

Figure 2 Jackknife position.

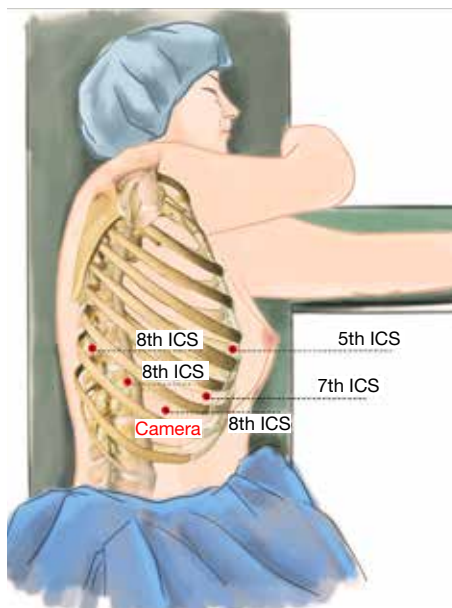


Figure 3 Ports in the 5th, 7th, and 8th ICS. ICS, intercostal space.

function were normal. In addition, blood routine test, hepatorenal function, and blood gases were normal.

Pre-operative preparation

The results of imaging, including PET/CT, suggested that the GGO was considered to be malignant. The lesion was in medial segment of the right middle lung lobe, near the hilum; therefore, segmentectomy and wedge resection were not suitable. After the preoperative discussion and agreement of the patient, we decided to perform robotic-assisted right middle lobectomy.

The patient was a middle-aged man in generally good

condition, without chronic disease, smoking or alcohol abuse, so the preoperative preparation was quite simple. During preoperative education, we described his condition and the surgical method, as well as situations that may occur after surgery. We told him to practice elimination while in bed. We taught him pulmonary function training and how to cough and expectorate after surgery. Eating and drinking are routinely forbidden after 9 pm the day before the operation.

Surgical procedures

Anesthesia and body position

The patient was first placed in the supine position. After combined intravenous and inhalation anesthesia, the patient was placed in a right lateral decubitus position under double-lumen endotracheal intubation, with his hands in front of his head. Then he was placed in the jackknife position and provided with single-lung (left) ventilation. After the patient was fixed tightly, the operation table was turned about 20° towards the patient's back (*Figure 2*).

Incisions

A 12-mm camera trocar was placed in the 8th intercostal space (ICS) at the right mid axillary line, three 8-mm working trocars were placed separately in the 5th ICS at the right anterior axillary line (#1 arm), 8th ICS at the right posterior axillary line (#2 arm), and the right 8th ICS (#3 arm), 2 cm from the spine. A 12-mm auxiliary incision was made in the 7th ICS at the right posterior axillary line (*Figure 3*). Then we created 8–10 mmHg artificial pneumothorax using CO₂. The patient-side cart was connected over the patient's

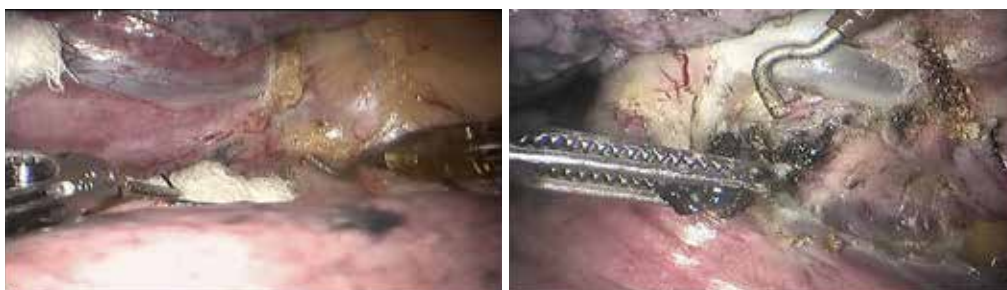

Figure 4 The mediastinal pleura was opened behind the phrenic nerve, exposing the hilum of the right lung. The hilar lymph nodes (No. 10) were removed.

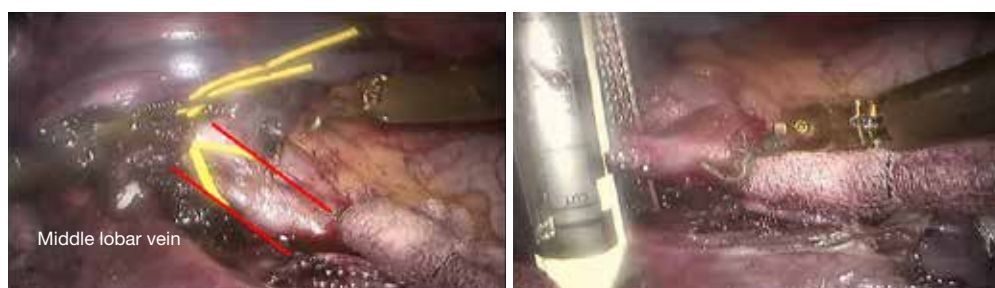

Figure 5 The superior pulmonary vein and middle lobe vein were dissected. The assistant pulled the middle lobe through an auxiliary incision to expose the middle lobe vein. It is important to find all its branches. Then the elastic cord was used to pull the middle lobe vein. The Endo GIA™ 60 mm was used to transect the vein with a white reload.

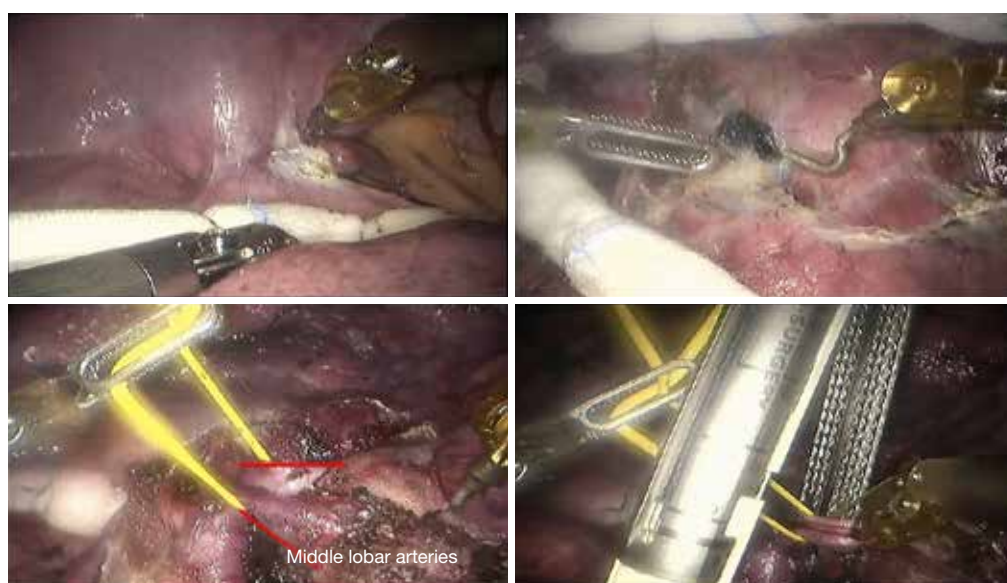


Figure 6 The initial part of the horizontal fissure was opened, and the interlobular lymph nodes (No. 11) were removed. The lateral segmental artery and medial segmental artery were dissociated and transected with a white reload.

head. The #1 arm (right hand) was connected to permanent cautery hook, and the #2 arm (left hand) was connected to fenestrated bipolar forceps.

Procedures

See *Figures 4-12*.

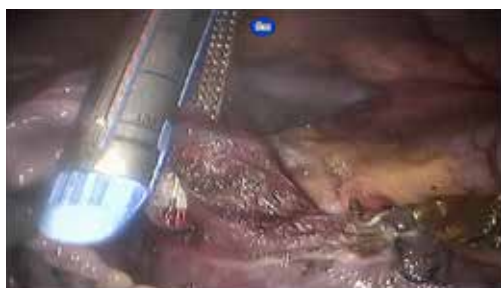

Figure 7 The middle lobe bronchus was dissociated transected it with a blue reload.

Finally, the thoracic cavity was washed with warm water, and the right lung was ventilated. No air leakage or bleeding was observed. We placed an indwelling 28# thoracic drainage tube and a thoracic micro-tube at 8th ICS and 9th ICS, respectively. Then all incisions were closed.

Postoperative treatment

Postoperative treatment is similar to that given after video-assisted lobectomy. No complication was observed. The

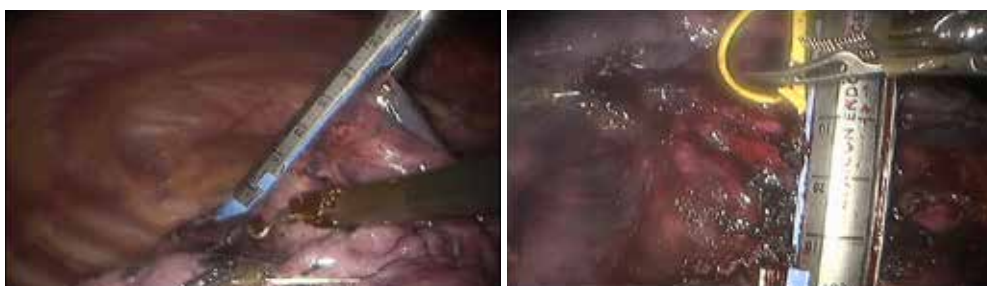

Figure 8 The remaining horizontal fissure and oblique fissure were cut with two blue reloads.

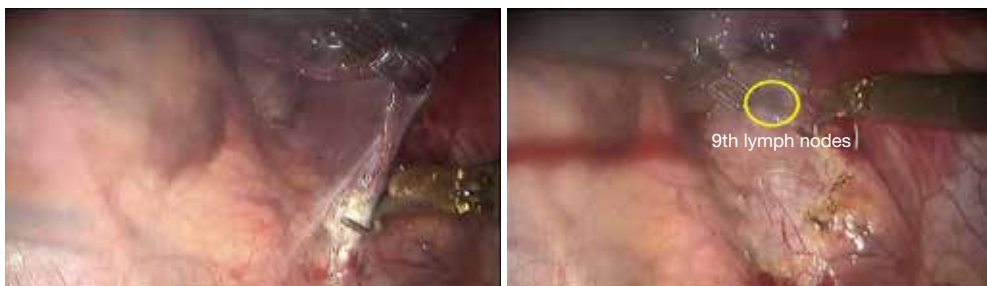

Figure 9 The inferior pulmonary ligament was divided to the inferior lung vein level, and the nearby lymph nodes (No. 9) were removed.

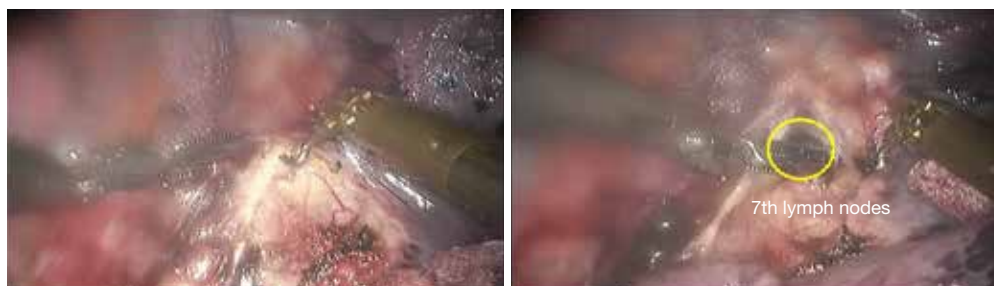

Figure 10 The posterior mediastinal pleura was opened to remove the subcarinal lymph nodes (No. 7).

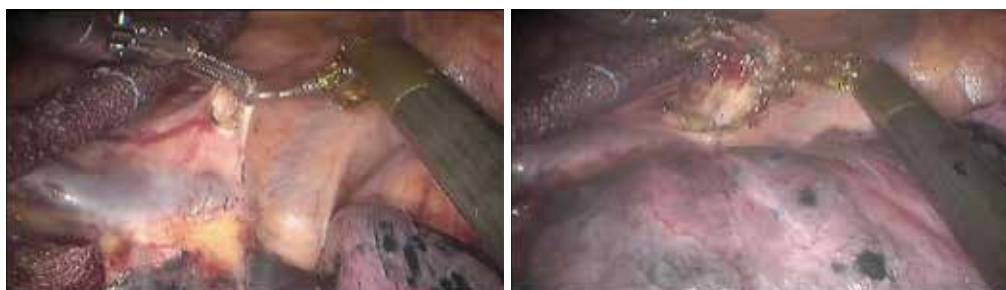

Figure 11 The upper mediastinal pleura was opened to remove lymph nodes near the trachea (No. 2 and 4), azygos vein arch and the superior vena cava.

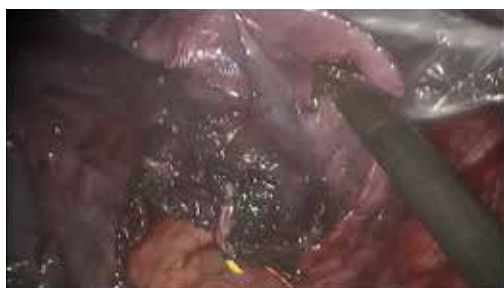

Figure 12 After extending the auxiliary incision to about 4 cm, we removed the resected middle lobe using a specimen bag. A lung cancer, diagnosis was proved by frozen section diagnosis. Bleeding was limited during surgery.

patient ate and took part in out-of-bed activities on the first day after surgery, and was discharged on the fourth day after surgery, with the thoracic drainage tube withdrawn. The thoracic micro-tube was withdrawn on 14th day after surgery.

Pathologic diagnosis was lung adenocarcinoma *in situ* (1 cm × 0.5 cm × 0.5 cm) with focal micro-invasion. No cancer cells were detected at the bronchial stump or lymph nodes.

Discussion

Because of the aplasia of fissures and the adhesion of lymph nodes around the vessels and bronchus, right middle lobectomy can be difficult (1). The stability and dexterity of the *da Vinci* Surgical System make it suitable for this procedure (2). Especially in systematic lymphadenectomy (3), the high-resolution three dimensional view makes it easier to completely remove lymph nodes thoroughly with less injury to nearby tissues.

Appropriate body position and incisions are key points of this surgery. We choose the lateral decubitus position and elevated the chest to make the surgical field clearer (4). After several attempts, we choose these incision locations that make it possible for the camera and robotic arms to cover the entire thoracic cavity. The auxiliary incision should be chosen to be convenient for placing instruments, such as the Endo GIATM and the specimen bag, and to minimize mutual interference between the robotic arms.

Regarding the choice of instruments, we use three arms (5), including a camera lens, a permanent cautery hook and a fenestrated bipolar forceps to meet the need for cutting, dissociation, coagulation, and pickup.

The case was typical, dealing with veins, arteries, bronchus, and fissures successively. However, we should pay attention to potential anatomic variations of these structures. In addition, the assistant should cooperate well with the surgeon and be experienced in thoracoscopic surgery and thoracotomy. In emergency circumstances, such as rupture of the main vessels, the assistant should be able to handle the situation independently under thoracoscopy or even open the chest immediately.

Acknowledgements

None.

Footnote

Conflicts of Interest: The authors have no conflicts of interest to declare.

Informed Consent: Written informed consent was obtained

from the patient for publication of this manuscript and any accompanying images.

References

1. Gaudet MA, D'Amico TA. Thoracoscopic Lobectomy for Non-small Cell Lung Cancer. *Surg Oncol Clin N Am* 2016;25:503-513.
2. Wei B, Eldaif SM, Cerfolio RJ. Robotic Lung Resection for Non-Small Cell Lung Cancer. *Surg Oncol Clin N Am* 2016;25:515-531.
3. Nasir BS, Bryant AS, Minnich DJ, et al. Performing robotic lobectomy and segmentectomy: cost, profitability, and outcomes. *Ann Thorac Surg* 2014;98:203-208.
4. Yan TD. Surgical atlas of thoracoscopic lobectomy and segmentectomy. *Ann Cardiothorac Surg* 2014;3:183-191.
5. Park BJ, Yang HX, Woo KM, et al. Minimally invasive (robotic assisted thoracic surgery and video-assisted thoracic surgery) lobectomy for the treatment of locally advanced non-small cell lung cancer. *J Thorac Dis* 2016;8:S406-S413.

doi: 10.21037/amj.2017.01.07

Cite this article as: Chen X, Yang S, Guo W, Jin R, Zhang Y, Wu H, Du H, Han D, Chen K, Xiang J, Li H. Robotic-assisted right middle lobectomy. *AME Med J* 2017;2:8.

Robotic assisted right middle lobectomy

Wael C. Hanna

Division of Thoracic Surgery, McMaster University, Hamilton, ON, Canada

Correspondence to: Wael C. Hanna, MDCM, MBA, FRCSC. St. Joseph's Healthcare Hamilton, 50 Charlton Ave. E, Juravinski Tower, Suite T2105 F, Hamilton, ON L8N4A6, Canada. Email: hannaw@mcmaster.ca.

Provenance: This is an invited Editorial commissioned by Section Editor of JTD, Jianfei Shen, MD (Department of Cardiothoracic Surgery, Taizhou Hospital of Zhejiang Province, Wenzhou Medical University, Taizhou, China).

Comment on: Chen X, Yang S, Guo W, *et al.* Robotic-assisted right middle lobectomy. AME Med J 2017;2:8.

Submitted Jul 25, 2017. Accepted for publication Jul 31, 2017.

doi: 10.21037/jtd.2017.08.38

View this article at: <http://dx.doi.org/10.21037/jtd.2017.08.38>

Dr. Chen and colleagues share their experience in performing a right middle lobectomy (RML) for a small peripheral ground-glass tumor (1). They use a 5-port approach: 3 robotic arms, 1 assistant and one camera. The incisions are placed between the 5th and 8th intercostal space, and the procedure is done through an anterior hilar approach, with vein divided first, followed by pulmonary artery, followed by bronchus. Lastly, the posterior mediastinal pleura was dissected and lymph node station 7 was harvested.

RML lobectomies are interesting operations. When the lesion is small and peripheral, the operation is usually straightforward and low-risk. However, when the tumor is bulky, or central on the fissure, these operations can be complicated, requiring meticulous vascular dissection around the pulmonary artery. At our institution, we use a different approach, which may facilitate RML lobectomy when it is a complicated operation. We use a 5-port technique according to the CPRL-4 positioning described by Cerfolio (2). We find that the ports all lining up in the same interspace minimizes postoperative pain and allows for better visualization of the fissure then the camera is looking down on pulmonary artery. We also start every robotic case with a posterior mediastinal incision and dissection of lymph node stations 9, 7, 4R, 2R and 11RS. This delivers the lung from the rigidity of the posterior mediastinum and renders the hilar dissection around the vessels much easier. We then divide the RML vein, followed by pulmonary artery, followed by bronchus and finally the fissure.

Regardless of which approach is taken, it is important

for robotic teams to be consistent in the way they perform robotic setup, docking, and operating. Repetition allows for streamlining of manoeuvres, improves operating room efficiency and minimizes complications. With the advent of low dose computed tomography, we expect a surge in minimally invasive targeted surgery for small lung tumors, and robotic surgeons will be on the forefront of this emerging field.

Acknowledgements

None.

Footnote

Conflicts of Interest: The author has no conflicts of interest to declare.

References

1. Chen X, Yang S, Guo W, et al. Robotic-assisted right middle lobectomy. AME Med J 2017;2:8.
2. Cerfolio RJ, Bryant AS. How to teach robotic pulmonary resection. Semin Thorac Cardiovasc Surg 2013;25:76-82.

Cite this article as: Hanna WC. Robotic assisted right middle lobectomy. J Thorac Dis 2017;9(8):2325. doi: 10.21037/jtd.2017.08.38

Robotic portal lobectomy, surgery through a virtual thoracotomy

Abbas E. Abbas

Division of Thoracic Surgery, Department of Thoracic Medicine and Surgery, Lewis Katz School of Medicine at Temple University, Philadelphia, USA
Correspondence to: Abbas E. Abbas, MD, MS, FACS. Professor and Thoracic Surgeon in Chief, Department of Thoracic Medicine and Surgery, Temple University Health System, Lewis Katz School of Medicine, 3401 N. Broad St., Suite C-100, Philadelphia, PA 19035, USA.
Email: abbas.abbas@temple.edu.

Provenance: This is an invited Editorial commissioned by Section Editor Jianfei Shen, MD (Department of Cardiothoracic Surgery, Taizhou Hospital of Zhejiang Province, Wenzhou Medical University, Taizhou, China).

Comment on: Chen X, Yang S, Guo W, *et al.* Robotic-assisted right middle lobectomy. AME Med J 2017;2:8.

Submitted Aug 03, 2017. Accepted for publication Aug 07, 2017.

doi: 10.21037/jtd.2017.08.84

View this article at: <http://dx.doi.org/10.21037/jtd.2017.08.84>

Resection for lung cancer remains the most effective mechanism to offer a chance at cure from a potentially devastating disease. We have known this fact for almost an entire century ever since the first resection by pneumonectomy for lung cancer was performed by Dr. Evarts Graham (1). Despite recent advances in nonsurgical technologies such as stereotactic radiation and percutaneous ablation, resection of the cancer with an adequate margin along with the anatomical unit of lung in which it resides including lymphatics, vessels and parenchyma remains the gold standard of care, against which competing modalities must be judged. Whether this “anatomical unit” is 1 lobe, 2 lobes, one or more segments, or even the whole lung depends on many factors including pulmonary functional status, comorbidities, location of tumor, size and histology. Increasing evidence of possible equivalence of sublobar resection to lobectomy is emerging especially for small or subsolid tumors associated with less aggressive lepidic adenocarcinomas (2,3).

Regardless of the extent of lung resection, the surgical approach to the lung can be classified as either by thoracotomy (with rib spreading) or by endoscopy (without). Rib-spreading thoracotomy has been the standard procedure and provides excellent exposure of the hilum in addition to allowing natural two-handed surgical techniques in dissection. However, in many studies it has also been associated with higher incidence of morbidity and even less favorable outcomes than minimally invasive approaches. Postoperative morbidities often occur when patients have intercostal neuralgic pain causing poor respiratory effort

leading to atelectasis and pneumonia. In addition, up to 20% of patients will have chronic post-thoracotomy pain that is resistant to most forms of treatment. Here lies the crux of the matter and why there is an enormous interest in developing a better way of doing this operation.

Non-rib spreading video-assisted thoracoscopic surgery (VATS) has been used to describe minimally invasive thoracic procedures. Such procedures were found not only to be feasible but also associated with better outcomes (4-8). However, as any surgeon who has done VATS lobectomy knows, it is a fundamentally different operation than that done through thoracotomy. This is primarily due to the different viewing angle which is necessarily anterior to the hilum. The approach is therefore, usually anterior to posterior, with division of the fissure last. As surgeons have gained more experience with this approach some find that they are able to adapt it to increasingly more difficult situations. However, it is ideally indicated for peripheral small tumors not associated with significant hilar adenopathy (8). Otherwise, the straight instruments do not allow easy manipulation of the lung and the 2-dimensional camera prevents good depth perception, preventing the surgeon from instinctively judging the necessary maneuvers needed for difficult dissection.

More recently, robotic technology has entered the arena of minimally invasive surgery. The benefits of dexterous dissection and manipulation in a confined space make it ideal for dissection in the chest. In the thoracic cavity, the ability of the surgeon to handle and manipulate the pulmonary hilar vessels and structures with excellent

3-dimensional visualization allows the safe conduct of the operation. Robotic surgery has allowed fine dissection of lymph nodes with better precision than traditional endoscopic techniques. However, in this author's opinion one of the main advantages of robotic thoracoscopy is that it almost perfectly replicates the open approach. The viewing angle is top down, not from the side. The surgeon has an instrument on each side of the camera, i.e., it is a natural surrogate for the natural human anatomy with a hand on each side of the eyes. The wristed nature of the instruments perfectly allows unlimited manipulation of the tissues and the ability to perform fine sharp dissection as we were taught to do so with open lobectomy. This is perhaps nowhere more important than when operating on the pulmonary vessels or when attempting to extirpate mediastinal lymph nodes. In fact, robotic portal lobectomy is simply an open procedure done through small holes, i.e., it is a "virtual thoracotomy". As such, it gives the surgeon the visual illusion of looking at the lung through an open chest and of being able to address the anatomy in a natural bimanual wristed technique. This has resulted in surgeons who were critical of VATS for various reasons finding they are able to easily adopt this new technology even for advanced cases. Unpublished reports suggest that up to 20% of lobectomies in the US are currently done robotically. An interesting fact, since the first published reports were only about 10 years ago.

As robotic-assisted thoracic surgery (RATS) appeared on the scene, so too has the name been used to describe any operation where the robot was used. Some surgeons perform the operation completely through ports. Others make a utility incision through which the assistant has both visual and manual access to the field. Yet others may use the robot for some of the procedure and VATS or thoracotomy for the rest, the so called "hybrid" procedures. For this reason, a new nomenclature recently proposed classifying robotic thoracic procedures as either "robotic assisted" where the assistant uses a utility incision at the bedside or "robotic portal" where the only assistance is through a surgical port. The name RATS may therefore disappear giving way to terms such as RPL4 or RAL3 when describing a robotic lobectomy (9,10).

Dr. Chen and colleagues from Department of Thoracic Surgery, Ruijin Hospital in Shanghai provide a clear elegant example of a robotic portal 4 arm (RPL4) right middle lobectomy for a suspicious ground glass nodule that turned out to be a minimally invasive adenocarcinoma (11). Because of the tumor's central location, it was not amenable

to a preoperative biopsy or to sublobar resection. The patient had an uneventful postoperative course and was discharge on the 4th postoperative day. Although this is not a newly described procedure, the paper is beautifully illustrated and provides a comprehensive overview of their surgical program. Their patient care starts long before the day of surgery. The patient is instructed on respiratory training including breathing, coughing and expectoration after surgery, even on using a bedside commode. In the operating room, they have established a system that works for them including bed location, patient position, port placement, instruments used and team members available. Postoperatively, they have an ambulation and physical therapy protocol with early discharge when possible. These are the hallmarks of how to have a successful surgical program with excellent outcomes. Each of these items may often be taken for granted and are seldom reproduced as well as this paper illustrates.

The operative details are clearly outlined with superb illustrations and photos. Although, their port placement is not the only approach to this operation it is certainly conducive to excellent visualization and handling. They prefer to place the ports in multiple intercostal spaces, whereas the author of this article prefers to place all of the robotic ports in the 8th intercostal space whenever possible. This minimizes the possibility of causing more than one intercostal neuralgia. In addition, we prefer to place the assistant port subcostally, through the insertion of the diaphragm on the costal margin. This avoids having to remove a large specimen through an intercostal space causing intercostal nerve compression. Even pneumonectomies and large tumors can be removed in this fashion without the need for any rib spreading. Of course, the diaphragm must be reinserted when closing this incision using permanent suture attaching it back to the costal margin.

An important aspect when trying to understand a robotic procedure is to know which robot model was actually used for the procedure. Advances in the robotic system continue to develop and not all models are universally available. The newer Xi robot (currently only available in the US) provides certain advantages including 360-degree rotation of the arms, robotic vascular stapling and higher definition. This has allowed two major changes in how the robotic thoracic procedures can be performed. The first is the ability to dock the robot from the side of the patient instead of the head. Head docking makes it difficult for the anesthesiologist to access the patient's head, e.g., to manipulate the endotracheal tube if necessary. With side

docking, the patient's head is clear and there is no need to rotate the bed away from the anesthesia cart. The second major benefit is robotic stapling where the surgeon is able to truly control what may be the most critical part of the procedure, dividing the hilar structures. This takes away one of the criticisms of robotic surgery. However, as anyone who has observed a robotic lobectomy with bedside stapling knows, the console surgeon is indeed in control, as much as in any open procedure, the surgeon performs the exposure of the vessel and helps guide the stapler around it. The assistant must carefully communicate with the surgeon, not make sudden moves and finally fire the stapler, much as they would do when assisting in a thoracotomy or VATS procedure. I believe that the described approach by the authors and their port placement works well for bed-side stapling whereas if the robotic stapler was used, the ports would need to be lower, i.e., in the 8th or 9th intercostal space.

The authors make two important comments in this article which are truly take-home messages. The first is that appropriate body position and incisions are key elements of this procedure. This is perhaps more important in robotic surgery than in any other. Once the robot is docked and the surgeon is at the console it is very difficult to change port placement or patient position. It is essential therefore, as these surgeons have done, to develop a clear understanding of the angles required by the robotic arms and the clearance provided by the spatial relationship of the ports to the anatomy of the patient and to one another. This comes with experience but once a system has been developed surgeons find that it is remarkable consistent and can be standardized to most patients.

The second important point they make is that the assistant should cooperate well with the surgeon and be experienced in both thoracoscopic and open surgery. Again, this is especially true for robotic surgery since the primary surgeon is actually not at the patient's side. Perfect communication between the console surgeon and the bedside assistant is essential. Indeed the "assistant" is really the bedside surgeon. She or he must lead the surgical team and let the console surgeon know if any potential problems such as arm collision or difficulty with any aspect of their end of the procedure. Occasionally the angle between one of the arms and the assistant port is insufficient for safe stapling and this must be conveyed to the console surgeon. In an emergency, this same assistant must be able to handle the situation almost independently and this requires knowledge of thoracic surgery not just robotic techniques. It is important therefore, to constantly review different

emergency scenarios with the entire team so that when it is necessary each individual in the room knows exactly what his or her role is. This author routinely announces a preprocedural "timeout" reviewing the role of the anesthesiologist to call for assistance, the circulating nurse to call for blood, the scrub nurse to start the undocking procedure and the assistant to perform whatever is necessary at the time e.g. holding pressure on a bleeder or making a thoracotomy (*Table 1*). Thoracoscopic and open instruments should be immediately available either open or in the room. Although the need for conversion will diminish with experience, it should remain as an expectation not a surprise for any busy thoracic program.

As robotic technology continues to evolve and as more medical device companies enter this arena, we are bound to see rapid advances in the not too distant future. The field of ideas is vast but certain needs come to mind. The ability to provide better haptic feedback for the console surgeon would eliminate one of the most often voiced concerns of non-robotic surgeons. Another example of possible upcoming advances is image overlay, essentially being able to overlay a reconstructed 3-dimensional study (e.g., CT scan or MRI) over the real-time video image and use this to identify important anatomical structures below the pleural surface such as the pulmonary arterial branches or a deep small nodule.

Another useful addition would be to add navigational technology to the robotic platforms. One recent publication by this author's group describes incorporating electromagnetic navigational bronchoscopic localization of nodules by injecting them with indocyanine green (ICG) (12). This method benefits from the ability of the robot to use near infrared laser emission by specially equipped robotic cameras to identify the autofluorescent ICG-injected nodules. This allows the detection of small, deep or subsolid nodules that may be difficult to find otherwise (12) (*Figure 1*). Perhaps in the future we can incorporate navigational technology into the robotic platform and allow the robot itself to be directed to the target nodule.

Perhaps the most revolutionary change we can have in robotic surgical technology would be to make it more accessible. It continues to carry a hefty price tag and is not available to the vast majority of surgeons and their patients in the world. Making the robot more affordable will need more competition by manufacturers and academic institutions. As we have shown, robotic surgery may actually be profitable when it leads to better outcomes, shorter hospital stays and faster returns to work. It should therefore

Table 1 Preprocedural checklist timeout for emergency conversion

Job title	What to do
Anesthesiologist	Call for anesthesia support Avoid reventilating the lung
Circulating nurse	If thoracotomy instruments not already open do that first Obtain blood in the room Notify blood bank to stay 4 units ahead of whatever is released
Bedside assistant (depends on the situation)	If holding pressure on a bleeding vessel then continue to do that and do not assist in anything else If control is lost then proceed with emergent thoracotomy (at 5 th intercostal space)
Scrub nurse or technician	Leave gown and glove on side of cart for surgeon to self-gown Do not remove or switch off camera Undock only the arms that the console surgeon specifies. Have thoracotomy instruments open Have bedside instrument-release wrench available
Console surgeon	Gown and glove oneself Call a colleague to assist Keep calm and carry on

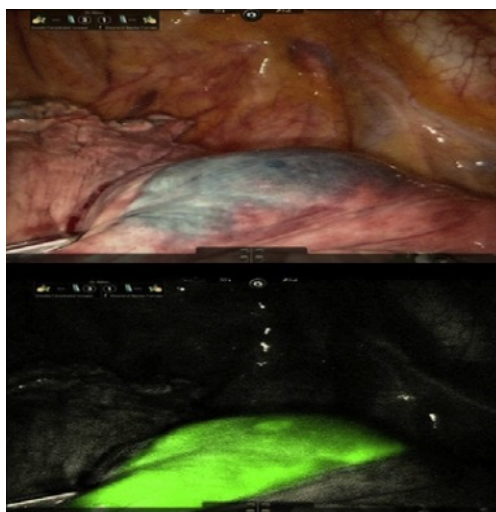

Figure 1 Electromagnetic navigational bronchoscopic localization of a small nodule, injected with mixture of methylene blue and indocyanine green (ICG). Upper image shows blue pleural surface from the effect of the methylene blue whereas the lower image shows the stark fluorescent effect when subjected to NIR light by the epically equipped robotic camera.

be preferentially selected for cases with high acuity such as thoracic procedures where these benefits will make a real difference. Using it for simple outpatient procedures such as sympathectomy or cholecystectomy may not be cost-effective at this time (13).

Robotic technology may allow more lung cancer patients to have minimally invasive thoracoscopic surgery instead of rib-spreading thoracotomy. With experience, it can be consistently used for more advanced cases such as bilobectomy, pneumonectomy, sleeve resections, chest wall involvement, and extensive adhesions whereas many surgeons would otherwise opt (wisely) for thoracotomy in these situations. In addition, surgeons who are unhappy about using 2-dimensional imaging with lack of depth perception and straight non-articulating instruments for the oncologic and vascular needs of lung cancer surgery may become convinced that a robotic portal lobectomy is indeed just a minimally invasive way of doing this routine operation through a thoracotomy. It is simply surgery through a virtual thoracotomy.

Acknowledgements

None.

Footnote

Conflicts of Interest: The author has no conflicts of interest to declare.

References

1. Horn L, Johnson DH., Evarts A. Graham and the first pneumonectomy for lung cancer. *J Clin Oncol* 2008;26:3268-3275.
2. Cao C, Chandrakumar D, Gupta S, et al. Could less be more?-A systematic review and meta-analysis of sublobar resections versus lobectomy for non-small cell lung cancer according to patient selection. *Lung Cancer* 2015;89:121-132.
3. Sakurai H, Asamura H. Sublobar resection for early-stage lung cancer. *Transl Lung Cancer Res* 2014;3:164-172.
4. Landreneau RJ, Hazelrigg SR, Mack MJ, et al. Postoperative pain-related morbidity: video-assisted thoracic surgery versus thoracotomy. *Ann Thorac Surg* 1993;56:1285-1289.
5. Jaklitsch MT, DeCamp MM Jr, Liptay MJ, et al. Video-assisted thoracic surgery in the elderly. A review of 307 cases. *Chest* 1996;110:751-758.
6. Demmy TL, Curtis JJ. Minimally invasive lobectomy directed toward frail and high-risk patients: a case-control study. *Ann Thorac Surg* 1999;68:194-200.
7. Kaseda S, Aoki T, Hangai N, et al. Better pulmonary function and prognosis with video-assisted thoracic surgery than with thoracotomy. *Ann Thorac Surg* 2000;70:1644-1646.
8. McKenna RJ Jr, Houck W, Fuller CB. Video-assisted thoracic surgery lobectomy: experience with 1,100 cases. *Ann Thorac Surg* 2006;81:421-425; discussion 425-426.
9. Abbas AE. New nomenclature for robotic-assisted thoracic surgery also gets rid of RATS. *J Thorac Cardiovasc Surg* 2017. [Epub ahead of print].
10. Cerfolio R, Louie BE, Farivar AS, et al. Consensus statement on definitions and nomenclature for robotic thoracic surgery. *J Thorac Cardiovasc Surg* 2017. [Epub ahead of print].
11. Chen X, Yang S, Guo W, et al. Robotic-assisted right middle lobectomy. *AME Med J* 2017;2:8.
12. Abbas A, Kadakia S, Ambur V, et al. Intraoperative electromagnetic navigational bronchoscopic localization of small, deep, or subsolid pulmonary nodules. *J Thorac Cardiovasc Surg* 2017;153:1581-1590.
13. Shen J. Prof. Abbas E. Abbas: a robotic thoracic practice can provide both clinical and financial benefits for an academic institution. *J Thorac Dis* 2017;9:E573-E575.

Cite this article as: Abbas AE. Robotic portal lobectomy, surgery through a virtual thoracotomy. *J Thorac Dis* 2017;9(9):2871-2875. doi: 10.21037/jtd.2017.08.84

Reply to comments on “*Robotic Assisted Right Middle Lobectomy*”: incision positions, approaches and other problems

Xingshi Chen, Hecheng Li

Department of Thoracic Surgery, Ruijin Hospital, Shanghai Jiao Tong University School of Medicine, Shanghai 200025, China

Correspondence to: Professor Hecheng Li. Department of Thoracic Surgery, Ruijin Hospital, Shanghai Jiao Tong University School of Medicine, 197 Ruijin 2nd Road, Shanghai 200025, China. Email: lihecheng2000@hotmail.com.

Provenance: This is an invited article commissioned by the Section Editor Jianfei Shen, MD (Department of Cardiothoracic Surgery, Taizhou Hospital of Zhejiang Province, Wenzhou Medical University, Taizhou, Zhejiang, China).

Response to: Hanna WC. Robotic assisted right middle lobectomy. J Thorac Dis 2017;9:2325;

Abbas AE. Robotic portal lobectomy, surgery through a virtual thoracotomy. J Thorac Dis 2017;9:2871-5.

Submitted Sep 25, 2017. Accepted for publication Oct 13, 2017.

doi: 10.21037/jtd.2017.10.45

View this article at: <http://dx.doi.org/10.21037/jtd.2017.10.45>

We appreciate the thoughtful and constructive comments by Dr. Wael C. Hanna from Canada (1) and Dr. Abbas E. Abbas from America (2) on our article “*Robotic Assisted Right Middle Lobectomy*”. In this article, we described our experience with robotic assisted right middle lobectomy through a specific case (3). As both Dr. Hanna and Dr. Abbas mentioned in their insightful comments, they preferred to line up all of the robotic ports in the same intercostal space (8th intercostal space) to minimize postoperative pain. In robot-assisted thoracic surgery, the incision positions are flexible and their placement primarily depends on the practice and preference of the surgeon. Many surgeons place the ports in multiple locations in the intercostal space (4–6). Another important factor that we could not ignore is racial difference. Caucasians have wider chests than Chinese; the Chinese chest surface is 93% of the chest surface of Caucasians (7). Thus, if we place four ports in the same intercostal space in a Chinese patient, especially in a female Chinese patient, there may not be adequate distances between the ports, which may lead to interference between the robotic arms. We have attempted various port placements and finally selected the incision locations described in our manuscript as part of our routine procedure. Dr. Hanna stated that they started every robotic case with a posterior mediastinal incision, and this information was useful and we agree with this approach. In fact, we perform many of our robotic assisted

lung surgeries via the posterior approach (8) or via a combined anterior and posterior approach (9).

Dr. Abbas reviewed the development of lung surgery in detail from thoracotomy to video-assisted thoracic surgery and to the recently developed robotic surgery, and he described the advantages of the newest Xi robot, which is not yet available in China. For the detection of small, deep, or sub-solid nodules, Dr. Abbas described a useful navigational technology, and we agree that these kinds of technology are necessary. Because of the frequent use of low-dose computed tomography (CT) and other methods of examination (10), an increasing number of patients with lung cancer have been observed to have small nodules or ground-glass opacities, which are not palpable during surgery and are difficult for pathologists to find. In our center, we always perform pre-operative percutaneous CT-guided Hook Wire localization (11) in these cases. Dr. Abbas also provided us with a set of processes to deal with an emergency. Here, we include a list of instruments that we prepare for open surgery in our center (*Table 1*) (12).

We thank Dr. Wael C. Hanna and Dr. Abbas Abbas for their comments on our article.

Acknowledgements

We would like to acknowledge David Tian, Senior Editor of AME Publishing Company, for editing support.

Table 1 Instruments prepared for open surgery

Routine instruments
Routine thoracic instruments for open pulmonary surgeries
Retractors (auto-retractors for small incisions or crossed retractors)
Handles for shadowless lamp
Measuring cylinder
Special instruments for esophageal surgery
Disposable instruments
Yankauer suction tip
Extension for electric scalpels
Trocars
2/0 Sutures, 0 sutures, 3/0 prolene sutures, 4/0 prolene sutures, 5/0 prolene sutures
Ultrasonic knives
Gauzes, 20 or 25 cm wound dressings
Spherical irrigator

Footnote

Conflicts of Interest: The authors have no conflicts of interest to declare.

References

- Hanna WC. Robotic assisted right middle lobectomy. *J Thorac Dis* 2017;9:2325.
- Abbas AE. Robotic portal lobectomy, surgery through a virtual thoracotomy. *J Thorac Dis* 2017;9:2871-2875.
- Chen X, Yang S, Guo W, et al. Robotic-assisted right middle lobectomy. *AME Med J* 2017;2:8.
- Melfi FM, Fanucchi O, Davini F, et al. Robotic lobectomy for lung cancer: evolution in technique and technology. *Eur J Cardiothorac Surg* 2014;46:626-630; discussion 630-631.
- Veronesi G. Robotic lobectomy and segmentectomy for lung cancer: results and operating technique. *J Thorac Dis* 2015;7:S122-S130.
- Kocher GJ, Schmid RA, Melfi FM. Robotic lobectomy: tips, pitfalls and troubleshooting. *Eur J Cardiothorac Surg* 2014;46:e136-e138.
- Donnelly PM, Yang TS, Peat JK, et al. What factors explain racial differences in lung volumes? *Eur Respir J* 1991;4:829-838.
- Yang S, Guo W, Jin R, et al. Robotic-assisted thoracoscopic surgery: right inferior lobectomy. *AME Med J* 2017;2:14.
- Xiang J, Yang S, Guo W, et al. Robotic-assisted thoracoscopic surgery: left upper lobectomy. *AME Med J* 2017;2:22.
- Jacobs CD, Jafari ME. Early Results of Lung Cancer Screening and Radiation Dose Assessment by Low-dose CT at a Community Hospital. *Clin Lung Cancer* 2017;18:e327-e331.
- Xu X, Yao Y, Shen Y, et al. Clinical Analysis of Percutaneous Computed Tomography-Guided Hook Wire Localization of 168 Small Pulmonary Nodules. *Ann Thorac Surg* 2015;100:1861-1867.
- Li J, Wang W, Qian Q, et al. Collaboration between the surgeon, assistants and nurses in robotic-assisted thoracic surgery. *AME Med J* 2017;2:21.

Cite this article as: Chen X, Li H. Reply to comments on “*Robotic Assisted Right Middle Lobectomy*”: incision positions, approaches and other problems. *J Thorac Dis* 2017;9(10):E962-E963. doi: 10.21037/jtd.2017.10.45

Robotic-assisted right upper lobectomy

Hailei Du, Su Yang, Wei Guo, Runsen Jin, Yajie Zhang, Xingshi Chen, Han Wu, Dingpei Han, Kai Chen, Jie Xiang, Hecheng Li

Department of Thoracic Surgery, Ruijin Hospital, Shanghai Jiao Tong University, School of Medicine, Shanghai 200025, China

Correspondence to: Hecheng Li, MD, PhD. Department of Thoracic Surgery, Ruijin Hospital, Shanghai Jiao Tong University, School of Medicine, 197 Ruijin Er Road, Shanghai 200025, China. Email: lihecheng2000@hotmail.com.

Abstract: We are going to share the experience of robotic surgery for right upper lobectomy. A 71-year-old patient underwent robotic-assisted thoracoscopic surgery for a primary lung adenocarcinoma. The patient was discharged on postoperative day 3 without any perioperative complications. The pathological stage was T1aN0M0 (stage IA). Our result showed the robotic-assisted thoracoscopic surgery was a feasible and reliable surgical approach for non-small cell lung cancer (NSCLC).

Keywords: Robotic-assisted thoracoscopic surgery; right upper lobectomy

Received: 02 December 2016; Accepted: 27 December 2016; Published: 21 January 2017.

doi: 10.21037/amj.2017.01.08

View this article at: <http://dx.doi.org/10.21037/amj.2017.01.08>

Clinical data

The patient was a 71-year-old man admitted because of cough and expectoration lasting a week. Chest computed tomography (CT) (*Figure 1*) showed a nodular shadow on the right upper lobe of the lung. The local hospital considered the possibility of inflammation, and cough improved after anti-inflammatory treatment. A second CT scan showed that the lesions did not shrink. The patient even visited our hospital again. Positron emission tomography (PET)-CT findings were highly suggestive of lung cancer. The patient's cardiopulmonary function, blood gas analysis, and laboratory tests were normal. There was no positive sign or supraclavicular lymph node enlargement on physical examination. He had a history of diabetes (5 years). Twenty years previously, he underwent surgery for the gallbladder stones.

Operation steps

Anesthesia and body position

The patient received general anesthesia by double-lumen endotracheal intubation and was placed in the lateral decubitus position and in a jackknife position with single-lung (left) ventilation (1) (*Figure 2*).

Ports

A 1.5-cm camera port (for a 12-mm trocar) was placed in the 8th intercostal space (ICS) at the right middle axillary line, and three separate 1.0-cm working ports (for 8-mm trocars) were made in the 5th ICS (#1 arm) at the right anterior axillary line, the 8th ICS (#2 arm) at the right posterior axillary line, and the right 8th ICS (#3 arm), 2 cm from the spine. An auxiliary port (for a 12-mm trocar) was made in the 7th ICS near the costal arch (2) (*Figure 3*).

Installation of the surgical arms

The robot patient cart was positioned directly above the operating table and then connected. The #2 arm was connected to a bipolar cautery forceps, and the #1 arm was connected to a unipolar cautery hook (3).

Surgical procedure (see *Figures 4-14*)

Postoperative condition

Postoperative treatments included anti-inflammation and phlegm-resolving treatment. The thoracic drainage tube was withdrawn 2 days after surgery, and the patient was discharged 3 days after surgery. No complications were observed during hospitalization.

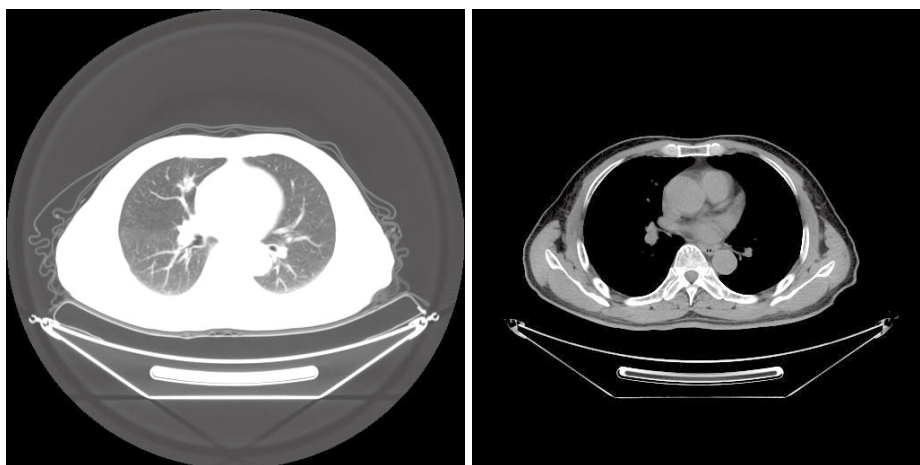


Figure 1 Preoperative CT scan a nodular in the right upper lobe. CT, computed tomography.



Figure 2 Jackknife position.

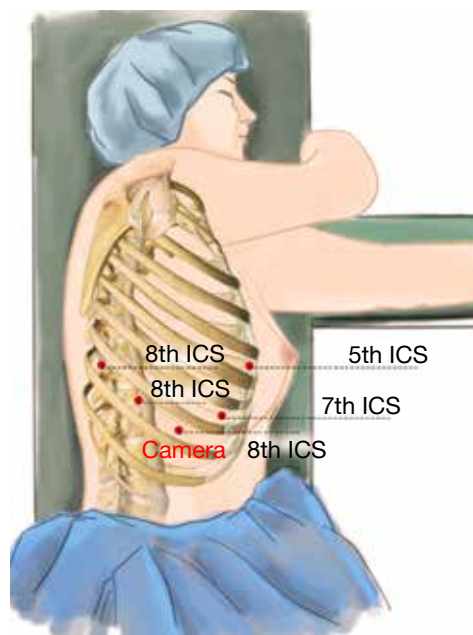


Figure 3 Ports in the 5th, 7th, and 8th ICS. ICS, intercostal space.

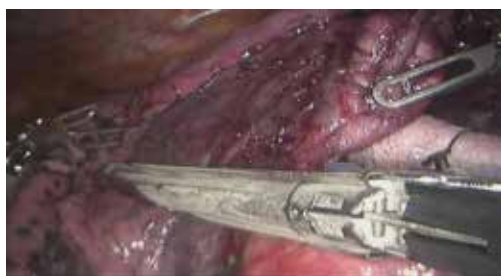

Figure 4 After wedge resection of the lesion, a diagnosis of a lung cancer was made by quick-frozen section during the surgery, and then the lobectomy was performed.

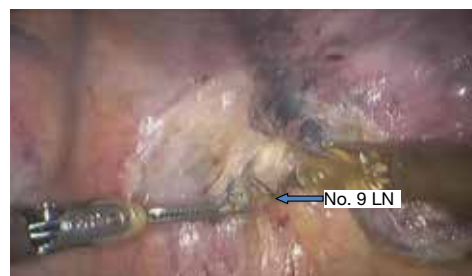

Figure 5 The lymph nodes (No. 9) in the inferior pulmonary ligament were removed.

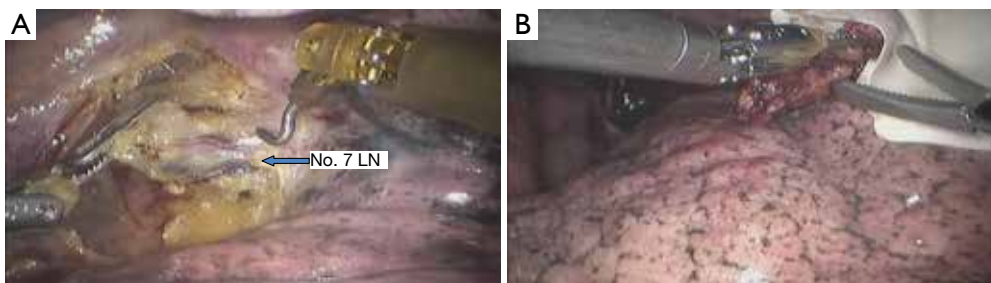


Figure 6 (A,B) The pleura of the hilum was opened, and the subcarinal lymph node (No. 7) were removed.

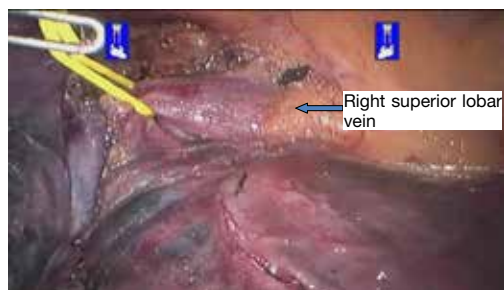


Figure 7 The upper pulmonary vein was pulled using an elastic cuff and cut using the Endo GIA.

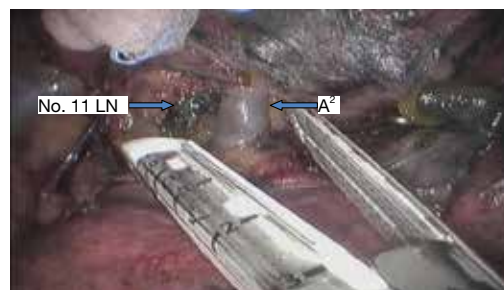


Figure 9 The lymph node (No. 11) was removed. The posterior segmental artery in the right upper lobe (A^2) was clamped and divided using the Endo GIA.

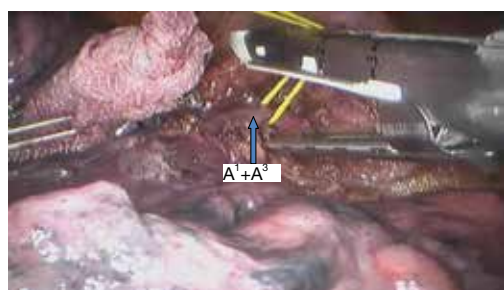


Figure 8 The apical and anterior branches of arteries (A^1+A^3) were pulled using elastic cuffs and cut by Endo GIA.

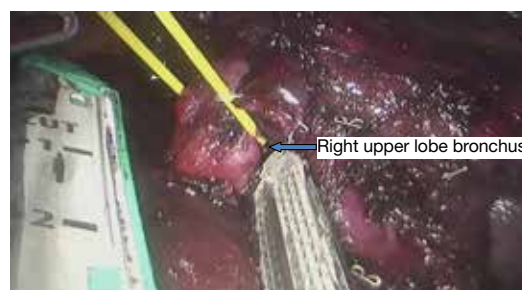


Figure 10 The right upper lobe bronchus was clamped and divided using the Endo GIA.

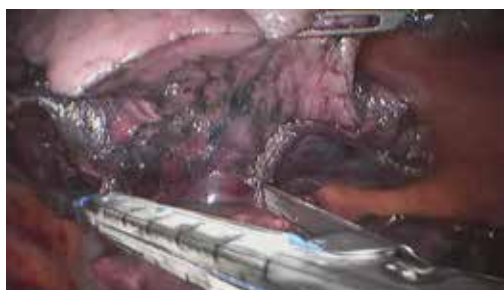


Figure 11 The horizontal fissure was clamped and divided using Endo GIA.

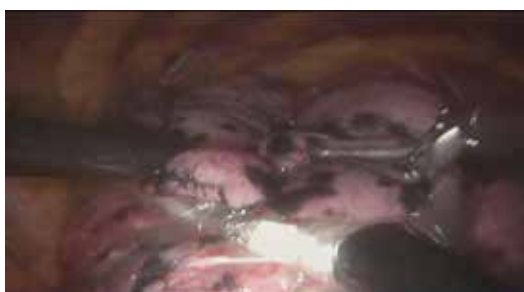

Figure 12 An extraction bag was inserted to harvest the completely resected right upper lobe through the incision.

Pathological diagnosis was invasive adenocarcinoma (2.0 cm × 1.5 cm × 1.0 cm) in the right upper pulmonary lobe. No metastasis was seen at the bronchial stump or the sampled lymph nodes. The pathological stage: pT1aN0M0, IA stage.

Acknowledgements

None.

Footnote

Conflicts of Interest: The authors have no conflicts of interest to declare.

doi: 10.21037/amj.2017.01.08

Cite this article as: Du H, Yang S, Guo W, Jin R, Zhang Y, Chen X, Wu H, Han D, Chen K, Xiang J, Li H. Robotic-assisted right upper lobectomy. AME Med J 2017;2:6.

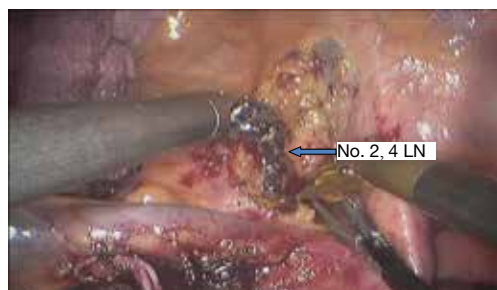


Figure 13 Lymph node (No. 2 and No. 4) were removed.

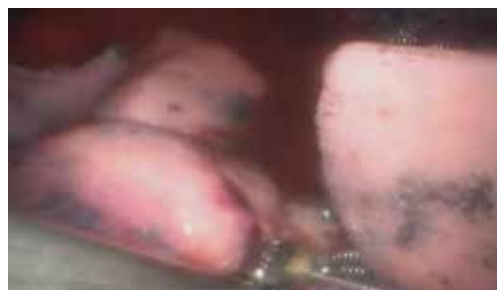

Figure 14 The bronchial stump leak test was negative result. A closed chest drainage tube was placed in the camera port. Then the chest was closed.

Informed Consent: Written informed consent was obtained from the patient for publication of this manuscript and any accompanying images.

References

1. Xu S, Wang T, Xu W, et al. Robotic-assisted right upper lobectomy. *Ann Transl Med* 2015;3:170.
2. Park BJ, Flores RM, Rusch VW. Robotic assistance for video-assisted thoracic surgical lobectomy: technique and initial results. *J Thorac Cardiovasc Surg* 2006;131:54-59.
3. Cerfolio RJ, Bryant AS. Robotic-assisted pulmonary resection - Right upper lobectomy. *Ann Cardiothorac Surg* 2012;1:77-85.

Is robotic surgery for NSCLC innovative enough?

Marcello Migliore

Thoracic Surgery, Department of Surgery and Medical Specialities, Policlinico University Hospital, University of Catania, Catania, Italy

Correspondence to: Marcello Migliore. Thoracic Surgery, Department of Surgery and Medical Specialities, Policlinico University Hospital, Via Passo Gravina 78, Catania 95124, Italy. Email: mmiglior@unict.it.

Provenance: This is an invited Editorial commissioned by Section Editor of *JTD*, Jianfei Shen, MD (Department of Cardiothoracic Surgery, Taizhou Hospital of Zhejiang Province, Wenzhou Medical University, Taizhou, China).

Comment on: Du H, Yang S, Guo W, *et al.* Robotic-assisted right upper lobectomy. *AME Med J* 2017;2:6.

Submitted Jul 30, 2017. Accepted for publication Jul 31, 2017.

doi: 10.21037/jtd.2017.08.37

View this article at: <http://dx.doi.org/10.21037/jtd.2017.08.37>

I read with interest the article of Dr. Du *et al.* describing their personal technique of robotic assisted (RATS) right upper lobectomy to treat early lung cancer (1). The authors after an explanation of their technique conclude that RATS is a feasible and reliable surgical approach for non-small cell lung cancer. Hence, this is another paper which confirms that RATS is as good as the other available minimally invasive techniques to perform lung resection and lymphadenectomy to treat lung cancer. While seeing the images in the paper and other videos, I note with interest that one of the most attractive advantage of RATS is the flexibility of the robotic arms which allow the surgeon to move instruments freely inside the chest according to the intraoperative necessity, and without the imposed schemes of geometry (2,3). Robotic assisted thoracic surgery is a beautiful medical example to confirm the Hippocrates aphorisms that *surgery is of all the arts the most noble*.

Although in the medical market since 20 years, it is reductive to still consider RATS an innovative approach. Robotic Assisted Thoracic Surgery is a technique, an excellent technique, but it is not “the sole and best technique” to treat lung cancer. At this moment, RATS should be considered a more sophisticated and costly VATS technique (4). Unfortunately, only in rich economies, hospital management could spend the bulk of their income on services such as RATS, and this behavior contributes to cause a tremendous delay in the widespread use of RATS.

Nevertheless, because literature is full of trustworthy editorials and comments on RATS lobectomy, it could be

more interesting to look RATS from a different view.

Do we need randomized controlled studies to compare VATS and RATS?

I read often that it is necessary to perform a randomized controlled study to show what is the best minimally invasive technique to treat lung cancer. From my point of view, there is no urgent rationale to support a randomized controlled study between all available minimally invasive techniques for at least one main reason: irrespective to the VATS or RATS technique, surgeons perform the same operation, and therefore long-term survival is expected to be similar (3,4). Instead, there is the strong necessity to definitively confirm that patients with NSCLC operated using minimally invasive techniques have similar, if not better, long term survival than those operated by open surgery to consign to history “large thoracotomies” to treat lung cancer.

RATS for surgical university schools

Optimistically, RATS lobectomy should be taught to all residents in (cardio) thoracic surgery, not because RATS is a better technique but because all residents should learn all the available minimally invasive techniques to understand what is the technique that suits her/him best. Therefore, it could be wise that all worldwide schools of surgery include RATS in their core curriculum, and the manufacturers should help university medical schools in less fortunate regions to buy it.

Teaching RATS (and VATS)

I would like to bring to your attention, from what it is achievable to understand in the medical literature, that many authored surgeons who are performing RATS (and VATS) are not junior but senior experienced surgeons (5-7). Most of them initiated their career performing open surgery, but now they are excellent RATS or VATS surgeons, and all of them have the capabilities to quickly control bleeding. In the nineties, at the beginning of my surgical career as thoracic surgeon in Bristol and Leuven, in case of difficult fissure or an extended tumor I recall that finger dissection of the main PA was the first step that have been taught to me to control the lung when vascular troubles could be expected. Nowadays open thoracic surgery is becoming very rare, and it is therefore very rare that we can teach junior surgeons to perform finger dissection of the main pulmonary artery and veins. Moreover, some studies have shown an higher incidence of vascular problems during RATS (8,9), and it is known that it could be a disaster if the surgeon has no experience in open surgery to control very quickly the main PA.

Animal lab “for open surgery” to train excellent RATS and VATS surgeons

One question inexorably arises: what can be done to teach residents to react correctly when something goes wrong, and profuse bleeding from the pulmonary artery appears during RATS (or VATS)? My personal view is that residents should operate in the animal lab and in transplant surgery to gain self-confidence to work with large vessels under emergency. Moreover, I could foresee an animal lab “for open surgery” to train VATS surgeons.

The future

The uniportal or multiportal RATS should not be still considered innovative but it is undoubtedly a reality of the contemporary operating room. Truthfully thoracic and oncologic surgery community instead to invest time to show

if RATS is better of uniportal, biportal or multiportal VATS (or vice versa), should look ahead to find other operative multimodality treatment options to achieve longer survival to patients with lung cancer.

Acknowledgements

None.

Footnote

Conflicts of Interest: The author has no conflicts of interest to declare.

References

1. Du H, Yang S, Guo W, et al. Robotic-assisted right upper lobectomy. *AME Med J* 2017;2:6.
2. Migliore M, Calvo D, Criscione A, et al. Uniportal video assisted thoracic surgery: summary of experience, mini-review and perspectives. *J Thorac Dis* 2015;7:E378-E380.
3. Migliore M. VATS surgery for anatomical lung resection: a different approach for every surgeon. *Video-assist Thorac Surg* 2016;1:31.
4. Migliore M. Video-assisted thoracic surgery techniques for lung cancer: which is better? *Future Oncol* 2016;12:1-4.
5. Melfi FM, Menconi GF, Mariani AM, et al. Early experience with robotic technology for thoracoscopic surgery. *Eur J Cardiothorac Surg* 2002;21:864-868.
6. Veronesi G, Galetta D, Maisonneuve P, et al. Four-arm robotic lobectomy for the treatment of early-stage lung cancer. *J Thorac Cardiovasc Surg* 2010;140:19-25.
7. Cerfolio RJ, Bryant AS, Skylizard L, et al. Initial consecutive experience of completely portal robotic pulmonary resection with 4 arms. *J Thorac Cardiovasc Surg* 2011;142:740-746.
8. Migliore M. Robotic assisted lung resection needs further evidence. *J Thorac Dis* 2016;8:E1274-E1278.
9. Park SY, Suh JW, Narm KS, et al. Feasibility of four-arm robotic lobectomy as solo surgery in patients with clinical stage I lung cancer. *J Thorac Dis* 2017;9:1607-1614.

Cite this article as: Migliore M. Is robotic surgery for NSCLC innovative enough? *J Thorac Dis* 2017;9(8):2326-2327. doi: 10.21037/jtd.2017.08.37

Robotic-assisted right upper lobectomy: with the further research, robot-assisted thoracic surgery (RATS) will be better in future

Hailei Du, Hecheng Li

Department of Thoracic Surgery, Ruijin Hospital, Shanghai Jiao Tong University School of Medicine, Shanghai 200025, China

Correspondence to: Professor Hecheng Li. Department of Thoracic Surgery, Ruijin Hospital, Shanghai Jiao Tong University School of Medicine, 197 Ruijin 2nd Road, Shanghai 200025, China. Email: lihecheng2000@hotmail.com.

Provenance: This is an invited article commissioned by the Section Editor Jianfei Shen, MD (Department of Cardiothoracic Surgery, Taizhou Hospital of Zhejiang Province, Wenzhou Medical University, Taizhou, China).

Response to: Migliore M. Is robotic surgery for NSCLC innovative enough? J Thorac Dis 2017;9:2326-7.

Submitted Sep 25, 2017. Accepted for publication Oct 13, 2017.

doi: 10.21037/jtd.2017.10.56

View this article at: <http://dx.doi.org/10.21037/jtd.2017.10.56>

We are grateful for the reviewers' comments on our manuscript entitled "*Robotic-assisted right upper lobectomy*" (1). Robot-assisted thoracic surgery (RATS) has been performed for several years with the first robotic lung resections described in 2002 by Melfi *et al.* (2). An analysis of the U.S. National Cancer Data Base found that the percentage of robotic lobectomies increased from 3% in 2010 up to 9% in 2012 (3). Although the number of robotic lung resections performed are increasing, the primary factor that continues to impede widespread use of the robotic technique is the higher overall cost of RATS relative to the cost of video-assisted thoracic surgery (VATS) approaches (4-7). We believe that the cost of robotic surgery will decrease as the instrumentation develops and when the pertinent patent becomes overdue.

Currently, we need randomized controlled studies that compare VATS and robotic assisted thoracoscopic surgery to determine which procedure should be used to remove various stage tumors. We believe that RATS lobectomy should be taught to all thoracic surgery residents. Access to an animal lab to train surgeons in RATS and VATS is critical for training. After training, we recommend that appropriate measures be taken to prevent and/or properly manage intraoperative complications with the robot.

We believe that new developments, such as improved instruments, tactile feedback, and "enhanced" reality, in RATS will reduce the cost of robotic surgery and will allow for more and improved widespread use of this advanced technology.

Acknowledgements

We would like to acknowledge David Tian, Senior Editor of AME Publishing Company, for editing support.

Footnote

Conflicts of Interest: The authors have no conflicts of interest to declare.

References

1. Migliore M. Is robotic surgery for NSCLC innovative enough? J Thorac Dis 2017;9:2326-2327.
2. Melfi FM, Menconi GF, Mariani AM, et al. Early experience with robotic technology for thoracoscopic surgery. Eur J Cardiothorac Surg 2002;21:864-868.
3. Rajaram R, Mohanty S, Bentrem DJ, et al. Nationwide Assessment of Robotic Lobectomy for Non-Small Cell Lung Cancer. Ann Thorac Surg 2017;103:1092-1100.
4. Park BJ, Flores RM. Cost comparison of robotic, video-assisted thoracic surgery and thoracotomy approaches to pulmonary lobectomy. Thorac Surg Clin 2008;18:297-300. vii.
5. Swanson SJ, Miller DL, McKenna RJ Jr, et al. Comparing robot-assisted thoracic surgical lobectomy with conventional video-assisted thoracic surgical lobectomy and wedge resection: results from a multihospital database (Premier). J Thorac Cardiovasc Surg 2014;147:929-937.
6. Paul S, Jalbert J, Isaacs AJ, et al. Comparative effectiveness

of robotic-assisted vs thoracoscopic lobectomy. Chest 2014;146:1505-1512.

7. Deen SA, Wilson JL, Wilshire CL, et al. Defining the cost

of care for lobectomy and segmentectomy: a comparison of open, video-assisted thoracoscopic, and robotic approaches. Ann Thorac Surg 2014;97:1000-1007.

Cite this article as: Du H, Li H. Robotic-assisted right upper lobectomy: with the further research, robot-assisted thoracic surgery (RATS) will be better in future. J Thorac Dis 2017;9(10):E964-E965 doi: 10.21037/jtd.2017.10.56

Robotic thoracic surgery: left lower lobectomy

Runsen Jin, Su Yang, Wei Guo, Yajie Zhang, Xingshi Chen, Han Wu, Hailei Du, Dingpei Han, Kai Chen, Jie Xiang, Hecheng Li

Department of Thoracic Surgery, Ruijin Hospital, Shanghai Jiao Tong University, School of Medicine, Shanghai 200025, China

Correspondence to: Hecheng Li, MD, PhD. Department of Thoracic Surgery, Ruijin Hospital, Shanghai Jiao Tong University, School of Medicine, 197 Ruijin Er Road, Shanghai 200025, China. Email: lihecheng2000@hotmail.com.

Abstract: Robotic-assisted surgery is now well established and has been introduced into the field of thoracic surgery. We are going to share the experience of robotic surgery for left lower lobectomy. A 44-year-old patient was underwent robotic-assisted thoracic surgery for a pulmonary nodule. The patient was discharged on postoperative day 3 without any perioperative complications. The pathological stage was T1aN0M0 (stage IA). Our result showed the robotic-assisted thoracoscopic surgery was a safe and feasible surgical approach for lobectomy.

Keywords: Robotic-assisted thoracoscopic surgery; left lower lobectomy

Received: 02 December 2016; Accepted: 27 December 2016; Published: 08 February 2017.

doi: 10.21037/amj.2017.01.09

View this article at: <http://dx.doi.org/10.21037/amj.2017.01.09>

Clinical data

The patient was a 44-year-old woman admitted because of a pulmonary nodule detected by computed tomography (CT). She had seen a doctor because of chest pain 2 weeks previously. Chest CT scan revealed a nodule located in the left lower lobe. The patient had no other symptoms, such as cough, fever, or dyspnea. Three-dimensional (3D) reconstruction of the pulmonary nodules with high-resolution CT showed a mixed density nodules in the left lower lobe of the lung with irregular shape and borders, and spicules, which suggested a malignant lesion. There was no positive sign or supraclavicular lymph node enlargement on physical examination. The patient's cardiopulmonary function, blood gas analysis, and laboratory tests were normal. She had no medical history. Preoperative stage was cT1N0M0 (IA). The preoperative data suggested a malignant tumor in the left lower lobe of the lung; therefore, the left lower lobectomy was performed.

Three-dimensional reconstruction CT shows a mixed density nodules on the left lower lobe of the lung (*Figure 1*). The lesion was irregular in shape, with spiculation, pleural traction, and multiple visible vessels, but no sign of vascular bundles or vacuoles. The plain scan CT value was about -216 Hu. The anteroposterior diameter of the nodule was

18.2 mm, left-right diameter was 14.8 mm, vertical diameter was 14 mm, and volume was about 507 mm³. The solid part was in the center of the lesion, accounting for nearly half of the nodule.

Operation steps

Anesthesia and body position (1)

After the induction of general anesthesia, the patient was placed in a right lateral decubitus position under double-lumen endotracheal intubation with single-lung (right) ventilation. With his hands placed in front of head, the patient was fixed in the jackknife position (*Figure 2*).

Ports

A 1.5-cm camera port (for a 12-mm trocar) was created in the 8th intercostal space (ICS) at the left mid axillary line, and three separate 1.0-cm working ports (for 8-mm trocars) were made in the 6th ICS (#1 arm) at the left anterior axillary line, the 8th ICS (#2 arm) at the left posterior axillary line, and the left 7th ICS (#3 arm), 2 cm from the spine. An auxiliary port (for a 12-mm trocar) was made in the 8th ICS near the costal arch (*Figure 3*).

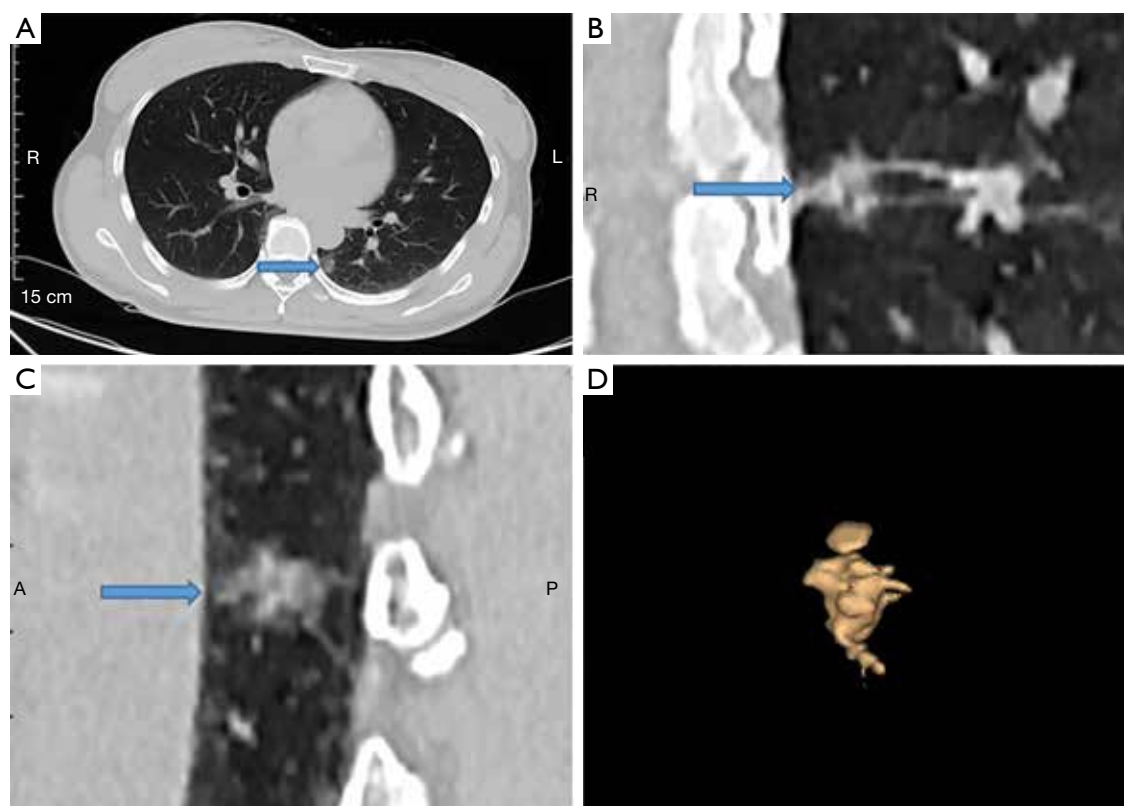


Figure 1 A nodule located in the left lower lobe. (A) Horizontal section; (B) coronal section; (C) sagittal section; (D) 3D-reconstruction.

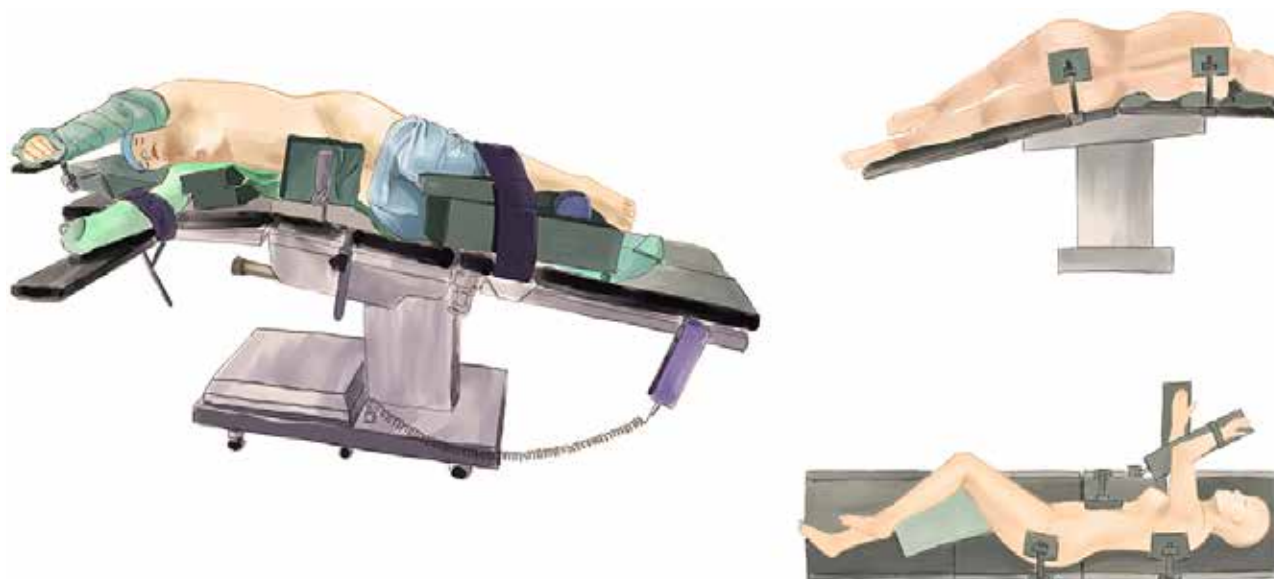


Figure 2 Jackknife position.

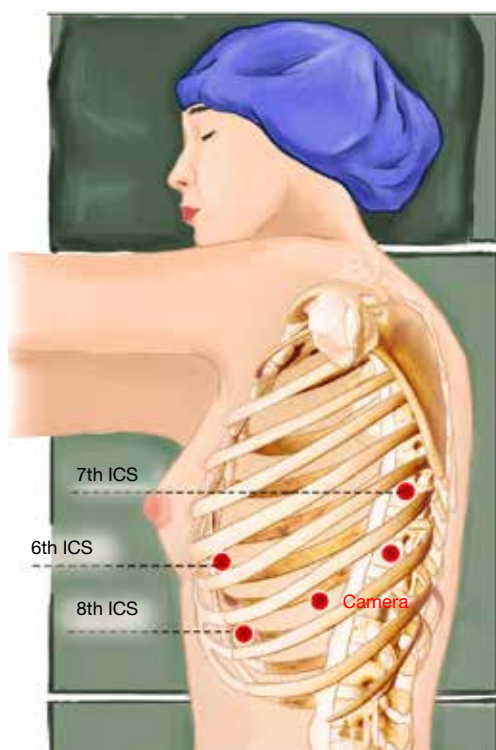


Figure 3 Ports in the 6th, 7th, and 8th ICS. ICS, intercostal space.

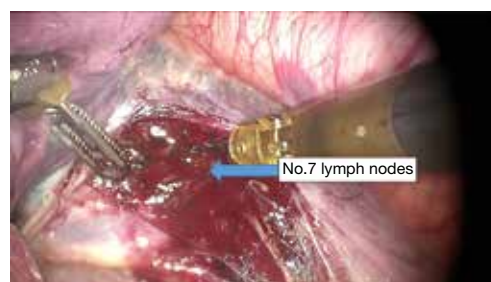


Figure 5 The left mediastinal pleural was opened, the subcarinal lymph node (No. 7) was resected.

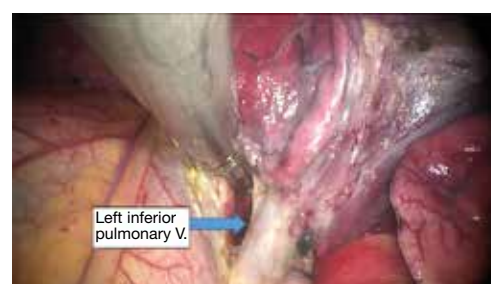


Figure 6 The left inferior pulmonary vein was dissected and skeletonized.

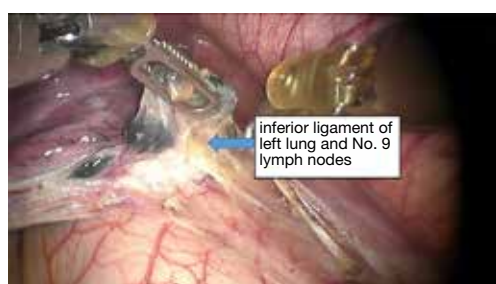

Figure 4 The inferior ligament of left lung was cut, and the No. 9 lymph nodes were resected.

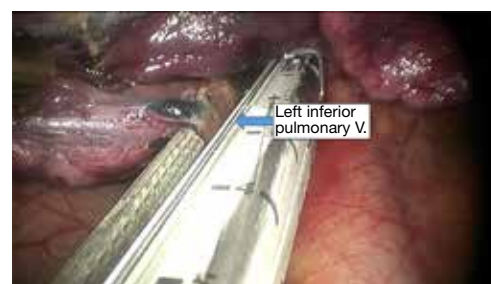


Figure 7 The left inferior pulmonary vein was cut with Endo GIA (60 mm-2.5).

Installation of the surgical arms (1,2)

The robot patient cart is positioned directly above the operating table and then connected. The #2 arm was connected to a bipolar cautery forceps, and the #1 arm was connected to a unipolar cautery hook.

Surgical procedure (1-5)

See Figures 4-17.

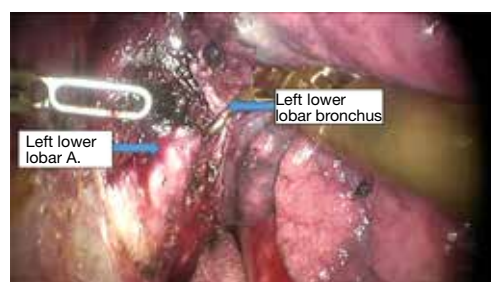


Figure 8 The left lower lobe bronchus and artery were dissected and separated.

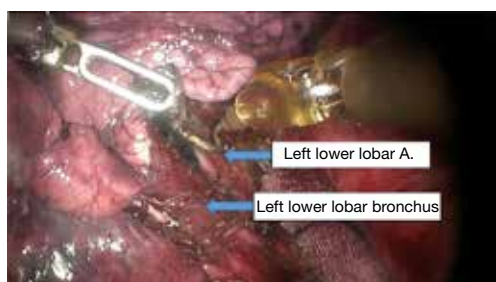


Figure 9 The lymph nodes around the left lower lobar bronchus (No. 11) were resected.

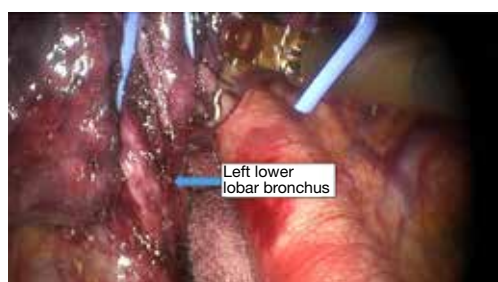


Figure 10 The left lower lobe bronchus was isolated and suspended with a rubber band.

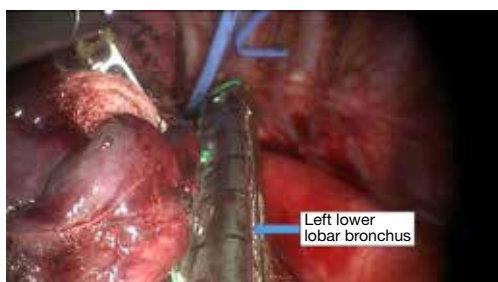


Figure 11 The left lower lobe bronchus was cut with Endo GIA (60 mm-4.8).

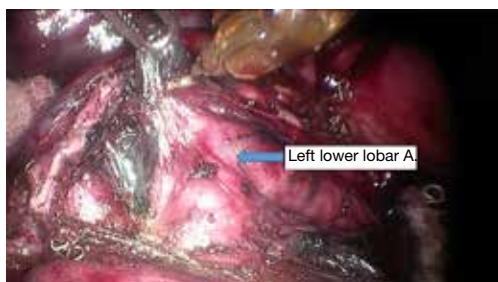

Figure 12 The left lower lobar artery and nearby lymph nodes around (No. 11) were resected.

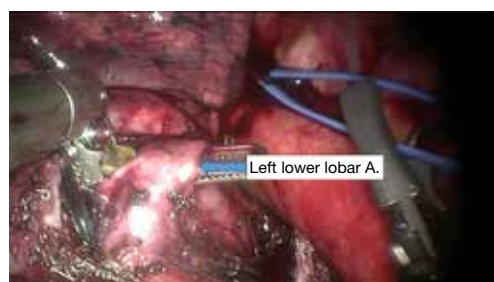

Figure 13 The left lower lobar artery was isolated.

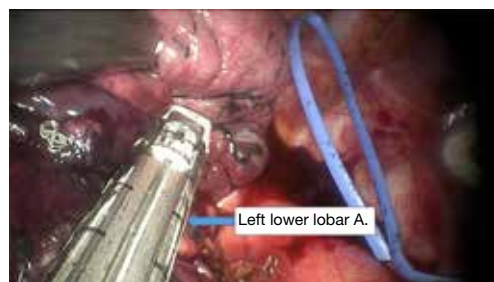


Figure 14 The left lower lobar artery was cut with Endo GIA (60 mm-2.5).

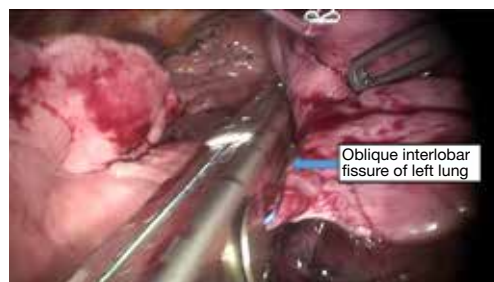


Figure 15 The interlobar fissure was separated with Endo GIA (60 mm-3.5×3, and 45 mm-3.5×1).

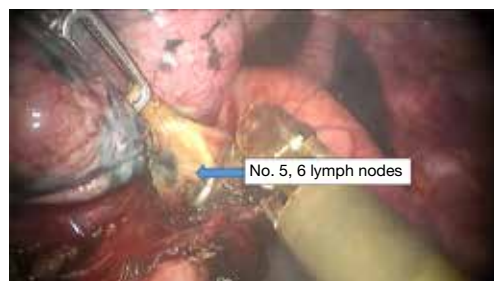


Figure 16 Lymph nodes No. 5 and 6 were resected.

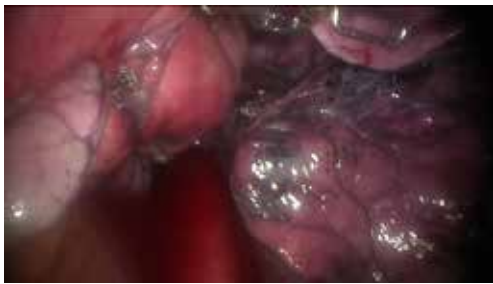

Figure 17 The lung was inflated under water to ensure that there was no air leak. The chest drainage tube was placed in the 8th ICS, and pigtail tube was placed in the 10th ICS. ICS, intercostal space.

Postoperative condition

Postoperative treatments included anti-inflammatory and phlegm-resolving treatment. The thoracic drainage tube was withdrawn 1 day after surgery, and the patient was discharged 3 days after surgery. No complications were observed during hospitalization.

Pathologic diagnosis was invasive adenocarcinoma of the left lower lobe. All lymph nodes were negative. Postoperative pathological stage was pT1N0M0 (stage IA adenocarcinoma).

Acknowledgements

None.

Footnote

Conflicts of Interest: The authors have no conflicts of interest to declare.

Informed Consent: Written informed consent was obtained from the patient for publication of this manuscript and any accompanying images.

References

1. Xu S, Meng H, Wang T, et al. Robotic-assisted left inferior lobectomy. *Ann Transl Med* 2015;3:169.
2. Zhao Y, Jiao W, Ren X, et al. Left lower lobe sleeve lobectomy for lung cancer using the Da Vinci surgical system. *J Cardiothorac Surg* 2016;11:59.
3. Augustin F, Bodner J, Wykypiel H, et al. Initial experience with robotic lung lobectomy: report of two different approaches. *Surg Endosc* 2011;25:108-113.
4. Dolezel J, Vlcek P. Robot-assisted pulmonary lobectomy. *Bratisl Lek Listy* 2008;109:251-253.
5. Gharagozloo F, Margolis M, Tempesta B. Robot-assisted thoracoscopic lobectomy for early-stage lung cancer. *Ann Thorac Surg* 2008;85:1880-1885; discussion 1885-1886.

doi: 10.21037/amj.2017.01.09

Cite this article as: Jin R, Yang S, Guo W, Zhang Y, Chen X, Wu H, Du H, Han D, Chen K, Xiang J, Li H. Robotic thoracic surgery: left lower lobectomy. *AME Med J* 2017;2:13.

Editorial for robotic left lower lobectomy

Michael D. Zervos

Department of Cardiothoracic Surgery, NYU Langone Medical Center, New York, NY, USA

Correspondence to: Michael D. Zervos. NYU Langone Medical Center, New York, NY, USA

Email: Michael.zervos@nyumc.org.

Provenance: This is an invited Editorial commissioned by Section Editor of JTD, Jianfei Shen, MD (Department of Cardiothoracic Surgery, Taizhou Hospital of Zhejiang Province, Wenzhou Medical University, Taizhou, China).

Comment on: Jin R, Yang S, Guo W, *et al.* Robotic thoracic surgery: left lower lobectomy. AME Med J 2017;2:13.

Submitted Jul 20, 2017. Accepted for publication Jul 24, 2017.

doi: 10.21037/jtd.2017.08.33

View this article at: <http://dx.doi.org/10.21037/jtd.2017.08.33>

Dr. Jin and colleagues from Ruijin Hospital have presented a nice review of their technique for left lower lobectomy (1). The authors are to be commended for their further advancement of minimally invasive surgery. We present a few comments. The authors describe using a 12-mm camera which is our preferred camera as well with the Si system. The authors should state early in the manuscript that their technique is on the Si and not the Xi or X system as the latter two upgraded systems afford several significant advantages, some of which include: an 8-m camera, camera hopping, the routine use of firefly and surgeon console independent stapling. When using an Si or Xi or X system the surgeon and team have the opportunity to staple through the most anterior port (which is our preference since it currently requires a 12-mm port and that is where the ribs are further apart. We also prefer using CO₂ insufflation the Conair system (previously called the SurgiQuest system). We prefer a thorough complete thoracic lymphadenectomy which was not fully described in this report. The diagrams and pictures of surgical steps are well done. We do not favor, in general the sequence the authors reported of: division of the inferior pulmonary vein

first followed by bronchus and artery last. Our preferred approach is division of pulmonary artery first followed by division of the inferior vein followed by bronchus last. We don't think that the order matters oncologically, however we have observed early congestion in the lung after division of the vein first. Also for clarity on nomenclature the operation is best labeled a left lower lobectomy and not an inferior lobectomy.

Acknowledgements

I would like to thank Dr. Robert Cerfolio for the support.

Footnote

Conflicts of Interest: The author has no conflicts of interest to declare.

References

1. Jin R, Yang S, Guo W, *et al.* Robotic thoracic surgery: left inferior lobectomy. AME Med J 2017;2:13.

Cite this article as: Zervos MD. Editorial for robotic left lower lobectomy. J Thorac Dis 2017;9(8):2319. doi: 10.21037/jtd.2017.08.33

Robotic left lower lobectomy: our experience

Runsen Jin, Hecheng Li

Department of Thoracic Surgery, Ruijin Hospital, Shanghai Jiao Tong University school of Medicine, Shanghai 200025, China

Correspondence to: Hecheng Li. Department of Thoracic Surgery, Ruijin Hospital, Shanghai Jiao Tong University School of Medicine, 197 Ruijin 2nd Road, Shanghai 200025, China. Email: lihecheng2000@hotmail.com.

Provenance: This is an invited article commissioned by Section Editor Jianfei Shen, MD (Department of Cardiothoracic Surgery, Taizhou Hospital of Zhejiang Province, Wenzhou Medical University, Taizhou, China).

Response to: Zervos MD. Editorial for robotic left lower lobectomy. J Thorac Dis 2017;9:2319.

Submitted Sep 25, 2017. Accepted for publication Oct 13, 2017.

doi: 10.21037/jtd.2017.10.55

View this article at: <http://dx.doi.org/10.21037/jtd.2017.10.55>

We very much appreciate the reviewer's positive comments and constructive critiques (1), which were valuable in guiding development of our minimally invasive surgical methods. We have addressed all of the comments and provided our point-by-point responses below:

The surgical steps that we presented were performed using the S system, and we only have the S and Si systems in our hospital. We agree that the Xi or X system affords several significant advantages, and we will try the Xi or X system as soon as we have the upgraded systems in our hospital. In addition, we used CO₂ insufflation in our surgeries with the Stryker Gas Insufflator.

We agree that a thorough complete thoracic lymphadenectomy should be performed. The International Association for the Study of Lung Cancer (IASLC) recommends that at least three mediastinal lymph node stations should be sampled and they include station 7 in all lung cancer patients, stations 5/6 in left upper lobe tumors, and station 9 in lower lobe tumors (2). We have described the steps of lymph node resection of stations 9, 7, 5/6, and 11, which are adequate for nodal staging.

We do prefer the sequence that we reported: division of the inferior pulmonary vein first followed by division of the bronchus and artery last. We believe that our sequence is easier, especially in patients with a fused fissure because it is difficult to divide the pulmonary artery first in these patients. In addition, the order of vein first followed by the artery conforms to oncologic principles (3). We agree that congestion is sometimes observed in the lung with this procedure. However, an experienced thoracic surgeon will be able to quickly divide the

pulmonary artery after dividing the vein. Thus, we do not think early congestion in the lung is a problem.

We agree that "a left lower lobectomy" is a more accurate and clear description of the operation, and we made this change in our manuscript.

Acknowledgements

We would like to acknowledge David Tian, Senior Editor of AME Publishing Company, for editing support.

Footnote

Conflicts of Interest: The authors have no conflicts of interest to declare.

References

1. Zervos MD. Editorial for robotic left lower lobectomy. J Thorac Dis 2017;9:2319.
2. Edwards T, Balata H, Elshafi M, et al. Adequacy of intra-operative nodal staging during surgical resection of NSCLC: influencing factors and its relationship to survival. J Thorac Oncol 2017. [Epub ahead of print].
3. Goldstraw P. Surgical oncologic principles. Chest Surg Clin N Am 2001;11:1-16. vii.

Cite this article as: Jin R, Li H. Robotic left lower lobectomy: our experience. J Thorac Dis 2017;9(10):E966. doi: 10.21037/jtd.2017.10.55

Different techniques in robotic lung resection

Pierluigi Novellis¹, Marco Alloisio^{1,2}, Umberto Cariboni¹, Giulia Veronesi¹

¹Division of Thoracic and General Surgery, Humanitas Clinical and Research Center, Rozzano (Milan), Italy; ²Biomedical Science Department, Humanitas University, Rozzano (Milan), Italy

Correspondence to: Pierluigi Novellis. Division of Thoracic and General Surgery, Humanitas Clinical and Research Center, Via Alessandro Manzoni 56, 20089 Rozzano, Milano, Italy. Email: pierluigi.novellis@cancercenter.humanitas.it.

Provenance: This is an invited Editorial commissioned by Section Editor of JTD, Jianfei Shen, MD (Department of Cardiothoracic Surgery, Taizhou Hospital of Zhejiang Province, Wenzhou Medical University, Taizhou, China).

Comment on: Jin R, Yang S, Wei G, *et al.* Robotic Thoracic surgery: left lower lobectomy. AME Med J 2017;2:13.

Submitted Sep 29, 2017. Accepted for publication Oct 10, 2017.

doi: 10.21037/jtd.2017.10.69

View this article at: <http://dx.doi.org/10.21037/jtd.2017.10.69>

Introduction

We read with great interest the article of Jin and co-authors describing a left lower lung lobectomy performed with robotic technique (1). The robotic approach for surgical treatment of lung cancer was first introduced in 2002 (2). The initial spread of this technique has been slow because many limitations were emphasized, such as the spatial footprint of the apparatus, the complexity in installing the robot's arms into the patient's chest and the increased duration of surgery; operating at a distance from the patient was also considered a source of anxiety by many surgeons. As a result, time was needed to gain confidence with the new apparatus and change the surgeons' mentality for accepting the new procedure.

In 2009 the database of the Agency for Healthcare Research and Quality (AHRQ, <http://hcupnet.ahrq.gov>) reported that 66% of lobectomies were performed via thoracotomy, 33% via video-assisted thoracoscopic surgery (VATS) and only 1% with a robotic system; nevertheless in 2013, the percentages changed the figures were 56%, 33% and 11%, respectively. A recent market analysis conducted in US in 2015 reported that lobectomies performed by robot reached the 15%.

Principal limitations to the wide adoption of robotic thoracic surgery consist in the high capital and running costs of the robot instruments (3). Furthermore it would seem that the use of robotic surgery in general has not improved patient outcomes (4,5), so it is important to provide a balanced assessment between advantages and disadvantages of robot-assisted surgery for lung resection. Another factor

affecting the diffusion of the robotic approach in thoracic surgery is the diffusion of uniportal thoracoscopy that has led to a critical review of the concept of mini-invasiveness, describing greater body preservation in patients undergoing lung surgery. Oncological results obtained with uniportal thoracoscopy also appear to be similar to those reported in open surgery (6). Despite these aspects, robotic supporters prefer it because of several advantages over VATS, including intuitive movements, tremor filtration, more degrees of manipulative freedom, motion scaling, and high definition stereoscopic vision. These advantages promise to make robotic surgery more accessible than VATS.

Different robotic approaches to the lung

The last generation robotic system was introduced in 2014. The advantages of this new system are a simpler docking, a more user-friendly design, a "port placement" menu and laser guidance. In addition, the thoracoscope has a digital end-mounted camera with autofocus for improved vision that does not require draping and can be placed onto any of the robotic arms. Lastly, the improved design of the arms allows placement of the ports relatively close together while still avoiding collision.

Different techniques of robotic approach to lung have been described in recent years. We here describe the different approaches used in robotic lung surgery: the two main approaches can be summarized in the anterior one with a utility incision (RAL) and in the complete port robotic lobectomy (CPRL) that does not include the use

of a utility incision but uses CO₂ during operation; other hybrid techniques have been described.

In 2005 Melfi and colleagues reported the first series of robotic lobectomy (7). In 2006 Park described a similar technique, where the port positions was similar to that used by the anterior VATS approach with a utility incision of 3–4 cm in the IV intercostal space on the mid axillary line, and used two more trocars for the camera port and for the second instrument (4). This approach was modified by Veronesi *et al.* and described in the paper comparing open, muscle-sparing thoracotomy and robotic lobectomy (four-arm technique with a 3 cm utility incision) (8).

In 2011, Cerfolio described a new “closed” technique (9). This was a four-arm technique in which the four arms were positioned along the same intercostal space (usually the 7th), between the mid-axillary and paravertebral lines, at the minimum distance of 9 cm, with no utility incision.

In the same year Dylewski *et al.* (10) reported on 200 robotic resections using a three-arm completely port approach with CO₂-induced pneumothorax (complete portal robotic lobectomy, CPRL).

Gharagozloo *et al.* (11) reported on another hybrid technique, composed by traditional thoracoscopy and robotics. Robotic arms were used for isolation of hilar elements and mediastinal lymph-node dissection, followed by stapling of the hilar structures using a manual VATS approach.

In the recent times the biggest innovation that has been made in the field of robotic surgery is represented by robotic endowrist staplers introduced in 2014. Stapler division of the hilar structures is considered one of the most important and potentially hazardous steps during a lobectomy. For some surgeons, the delegation of this task to the assistant is considered a risk. The use of the robotic stapler allows the surgeon to operate in absolute autonomy managing by himself the vascular section and seems to be safe and effective. The operating surgeon's ability to control the stapler from the console represents a critical technical advancement, as it can allow surgeons with limited assistance to explore robotic lung resection and perhaps transition from open or video-assisted lobectomy (12).

State of the art of robotic lung lobectomy techniques

Since the beginning we have adopted an anterior approach with utility incision. This approach mainly differs from the CPRL for the type of approach to the hylum (anterior or

posterior) and for the use of CO₂ during the procedure.

In our opinion the presence of a utility incision is related to some advantages as the possibility of palpating the lung and removing the specimen from the same incision; in case of vascular bleeding it allows a rapid conversion, with the possibility of enlarging the same incision; it also offers a comfortable access of a sponge in the case of small bleeding and avoids one trocar incision compared to the complete portal technique CO₂ is not routinely used in this techniques, but it is indicated in selected cases such as obesity, relaxation of the diaphragm, incomplete lung exclusion due to air trapping in COPD patients or problems with the tracheal tube (13).

The benefit of complete portal robotic procedures is the presence of CO₂. This can be related to the potential advantage to avoid the cold 22 °C ambient air of the operating room interfering with the 37 °C temperature within the chest, preventing potential tissue desiccation and further inflammation; it is also useful because it helps to detach the pulmonary parenchyma showing better the hilar structures and increase the working place in the chest cavity.

The use of robotics in thoracic surgery has increased considerably over the last few years. Although no new technical variations have been described, the presence of more recent articles has resulted in confusion in terms used to describe different techniques. To solve this problem the American Association of Thoracic Surgeons Guideline Committee appointed an expert consensus writing committee to construct definitions and nomenclature for robotic thoracic surgery to describe the current and possible subsequent types of robotic operations performed in general thoracic surgery (14).

The results of this consensus statement give some definitions that may help the future article to be better classified. One of the issues attempts to define the differences between a complete portal approach from the utility incision: the consensus define a robotic portal (RP) operation as any operation that use ports only (incisions that are only as large as the size of the trocars placed in them), the air in the pleural space or chest cavity does not directly communicate with the ambient air in the operating room. Robotic operations that include a utility incision have been defined as robotic-assisted (RA) procedures.

At this regard the author proposes the following nomenclature: the first letter “R” should be used to identify a robotic procedure, the second letter should describe a portal (P) or assisted (A) procedure. The third letter(s)—what operation is being performed: “L” for

lobectomy, “S” for segmentectomy, “W” for wedge, “P” for pneumonectomy and “SL” for sleeve lobectomy. The fourth letter should describe the number of robotic arms used. Thus, a completely portal lobectomy that uses 4 arms is a RPL-4; a robotic segmentectomy that is robot assisted and uses 4 arms would be RAS-4 and. A robotic sleeve lobectomy that uses 4 arms with a utility incision is abbreviated RASL-4.

Although this new classification system goes to the direction of harmonized the classifications of different robotic procedures, some criticisms have been moved in the editorial of Abbas E. Abbas. He asked to identify one system that can resume all the robotic procedures made on the lung, pleura, chest wall, mediastinum, esophagus, and stomach (15). He also added that surgeons must be persuaded to change what they call their own operations and other thoracic and minimally invasive societies will have to support this nomenclature.

Future direction for robotic thoracic surgery

Beside indisputable technical advantages of robotic approach, there are still some doubts today about the clinical benefits of robotic approach in lung surgery compared to manual video-assisted surgery considering that both are minimally invasive approach. In addition to assess oncological benefits we should wait for longer follow up data. Preliminary results based on retrospective studies or meta-analysis seems to give an advantage in terms of fewer conversions compared to VATS and a greater number of removed lymph nodes and upstage (16). A recent meta-analysis shows a small but significant benefit in terms of postoperative mortality (17). Despite these initial positive results, the high costs associated with the procedure deserve a higher level of evidence, hopefully based on randomized trials, to justify diffuse adoption.

In order to fill the gap, we started a multicentric randomized study to compare the results of robotic versus manual video-thoroscopic lung resection in patients with non-small cell lung cancer in stage I and II, in terms of perioperative outcome, oncological radicality and quality of life (Trial Gov NCT02804893).

Regarding the costs we recently analyzed retrospectively 103 consecutive patients who underwent a lobectomy or a segmentectomy for clinical stage I or II NSCLC with three different approaches: thoracotomy, robotic and VATS. We analyzed clinical, surgical data and costs. Our results showed that although the costs of robotic approach

was higher compared to other techniques, in one system of public health reimbursement, our hospital was able to make a profit (submitted data). Preliminary data on clinical outcome showed also that robotic surgery for early lung cancer was associated with shorter stay and more extensive lymph node dissection than VATS and open surgery. Duration of surgery was shorter for robotic than VATS.

Since its introduction into the market robotic system was produced by a single company that had maintained the costs high. The global crisis over the last decade associated with these high costs has not facilitated the spread of this highly demanding technology from an economic point of view by the organization of healthcare facilities. The high technology associated with the robot probably will never equal the cost to traditional thoracoscopy. However, in the coming years new producers will launch on the market new surgical robots (probably already in 2018). The improvement in the global economic situation associated with the entry of competitors that will certainly lead to lower costs can facilitate the diffusion of the technology (3).

The first desirable goals for robotic surgery are the entry of the “single site” technology in thoracic surgery. So far, the available technological platforms and the results of operations in urological and obstetrical pathology are not yet sufficient and exhaustive (18), but an imminent future is likely to occur in response to more and more frequent use of uniportal manual thoracoscopy.

The second goal could be the incorporation of a technology capable of receiving tactile feedback whose absence in robotic surgery has generated much skepticism.

The last important step in robotic surgery should be in our opinion the integration of the preoperative imaging information with intraoperative anatomical information obtained in real time by robotic visual system. The augmented reality (AR) can allow the surgeon to locate blood vessels or other structures that are not directly visible, and which previously could only be appreciated by palpation. It will also require a radical change in operating room practice and mindset.

Acknowledgements

The Umberto Veronesi Foundation is gratefully acknowledged for fellowship to Pierluigi Novellis.

Footnote

Conflicts of Interest: G Veronesi is a consultant for ABI

Medica SpA and Medtronic. The other authors have no conflicts of interest to declare.

References

1. Jin R, Yang S, Wei G, et al. Robotic Thoracic surgery: left lower lobectomy. *AME Med J* 2017;2:13.
2. Melfi FM, Menconi GF, Mariani AM, et al. Early experience with robotic technology for thoracoscopic surgery. *Eur J Cardiothorac Surg* 2002;21:864-868.
3. Novellis P, Alloisio M, Vanni E, et al. Robotic lung cancer surgery: review of experience and costs. *J Vis Surg* 2017;3:39.
4. Park BJ, Flores RM, Rusch VW. Robotic assistance for video-assisted thoracic surgical lobectomy: technique and initial results. *J Thorac Cardiovasc Surg* 2006;131:54-59.
5. Swanson SJ, Miller DL, McKenna RJ Jr, et al. Comparing robot-assisted thoracic surgical lobectomy with conventional video-assisted thoracic surgical lobectomy and wedge resection: results from a multihospital database (Premier). *J Thorac Cardiovasc Surg* 2014;147:929-937.
6. Ismail M, Swierzy M, Nachira D, et al. Uniportal video-assisted thoracic surgery for major lung resections: pitfalls, tips and tricks. *J Thorac Dis* 2017;9:885-897.
7. Melfi FM, Ambrogi MC, Lucchi M, Mussi A. Video robotic lobectomy. *Multimed Man Cardiothorac Surg* 2005;2005:mmcts.2004.000448.
8. Veronesi G, Galetta D, Maisonneuve P, et al. Four-arm robotic lobectomy for the treatment of early-stage lung cancer. *J Thorac Cardiovasc Surg* 2010;140:19-25.
9. Cerfolio RJ, Bryant AS, Minnich DJ. Starting a robotic program in general thoracic surgery: why, how, and lessons learned. *Ann Thorac Surg* 2011;91:1729-36; discussion 1736-1737.
10. Dylewski MR, Ohaeto AC, Pereira JF. Pulmonary resection using a total endoscopic robotic video-assisted approach. *Semin Thorac Cardiovasc Surg* 2011;23:36-42.
11. Gharagozloo F, Margolis M, Tempesta B, et al. Robot-assisted lobectomy for early-stage lung cancer: report of 100 consecutive cases. *Ann Thorac Surg* 2009;88:380-384.
12. Pearlstein DP. Robotic Lobectomy Utilizing the Robotic Stapler. *Ann Thorac Surg* 2016;102:e591-e593.
13. Veronesi G, Novellis P, Voulaz E, et al. Robot-assisted surgery for lung cancer: State of the art and perspectives. *Lung Cancer* 2016;101:28-34.
14. Cerfolio R, Louie BE, Farivar AS, et al. Consensus statement on definitions and nomenclature for robotic thoracic surgery. *J Thorac Cardiovasc Surg* 2017;154:1065-1069.
15. Abbas AE. New nomenclature for robotic-assisted thoracic surgery also gets rid of RATS. *J Thorac Cardiovasc Surg* 2017;154:1070-1071.
16. Mungo B, Hooker CM, Ho JS, et al. Robotic Versus Thoracoscopic Resection for Lung Cancer: Early Results of a New Robotic Program. *J Laparoendosc Adv Surg Tech A* 2016;26:243-248.
17. Emmert A, Straube C, Buentzel J, et al. Robotic versus thoracoscopic lung resection: A systematic review and meta-analysis. *Medicine (Baltimore)* 2017;96:e7633.
18. Nelson RJ, Chavali JSS, Yerram N, et al. Current status of robotic single-port surgery. *Urol Ann* 2017;9:217-222.

Cite this article as: Novellis P, Alloisio M, Cariboni U, Veronesi G. Different techniques in robotic lung resection. *J Thorac Dis* 2017;9(11):4315-4318. doi: 10.21037/jtd.2017.10.69

Robotic-assisted thoracoscopic surgery: left upper lobectomy

Jie Xiang, Su Yang, Wei Guo, Runsen Jin, Yajie Zhang, Xingshi Chen, Han Wu, Hailei Du, Dingpei Han, Kai Chen, Hecheng Li

Department of Thoracic Surgery, Ruijin Hospital, Shanghai Jiao Tong University, School of Medicine, Shanghai 200025, China

Correspondence to: Hecheng Li, MD, PhD. Department of Thoracic Surgery, Ruijin Hospital, Shanghai Jiao Tong University, School of Medicine, 197 Ruijin Er Road, Shanghai 200025, China. Email: lihecheng2000@hotmail.com.

Abstract: Robotic-assisted surgery is now widely used in the field of thoracic surgery. We are going to share the experience of robotic surgery for left upper lobectomy. A 63-year-old patient underwent robotic-assisted thoracic surgery for a primary non-small cell lung cancer. The patient was discharged on postoperative day 3 without any perioperative complications. The pathological stage was T1aN0M0 (stage IA).

Keywords: Robotic-assisted thoracoscopic surgery; left upper lobectomy

Received: 02 December 2016; Accepted: 27 December 2016; Published: 15 February 2017.

doi: 10.21037/amj.2017.01.10

View this article at: <http://dx.doi.org/10.21037/amj.2017.01.10>

Clinical data

The patient was a 63-year-old man admitted because of cough and pulmonary nodule detected by computed tomography (CT). Chest CT (*Figure 1*) showed a mass located in the posterior segment of the left upper lobe (2.5 cm × 2 cm) that was lobulated with burr-like edges. The mass did not change after anti-inflammation therapy. The positron emission tomography-CT SUV_{max} was 6.5 and malignancy was considered. The mediastinal lymph node was negative and there was no distant metastasis. The patient's complaints did not include chills, low fever, night sweats, hoarseness, or fatigue of upper limbs. The cardiopulmonary function, blood gas analysis, and laboratory tests were normal. There was no positive sign or supraclavicular lymph node enlargement on physical examination. He had no past medical history. Preoperative stage was cT1N0M0 (IA). Informed consent for robotic-assisted thoracic lobectomy was obtained from patient before operation.

Operation steps

Anesthesia and body position

After the induction of general anesthesia, the patient was placed in a right lateral decubitus position under double-lumen endotracheal intubation. With his hands placed in front of his head, the patient was fixed in a jackknife

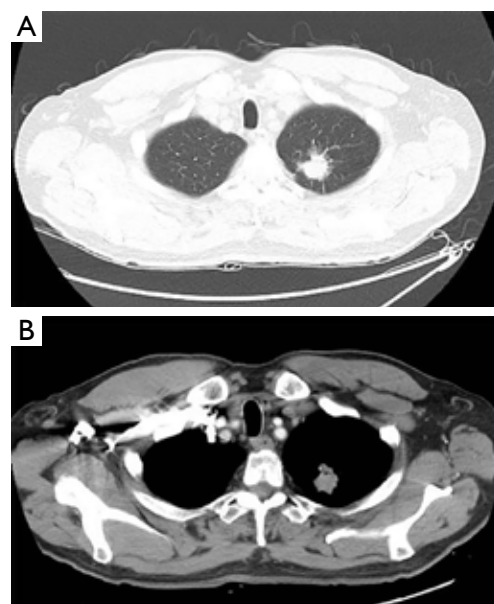


Figure 1 A mass located in the posterior segment of the left upper lobe (2.5 cm × 2 cm) that was lobulated with burr-like edges.

position with single-lung (right) ventilation (*Figure 2*).

Ports

A 1.5-cm camera port (for a 12-mm trocar) was created in the 8th intercostal space (ICS) at the left mid axillary line,

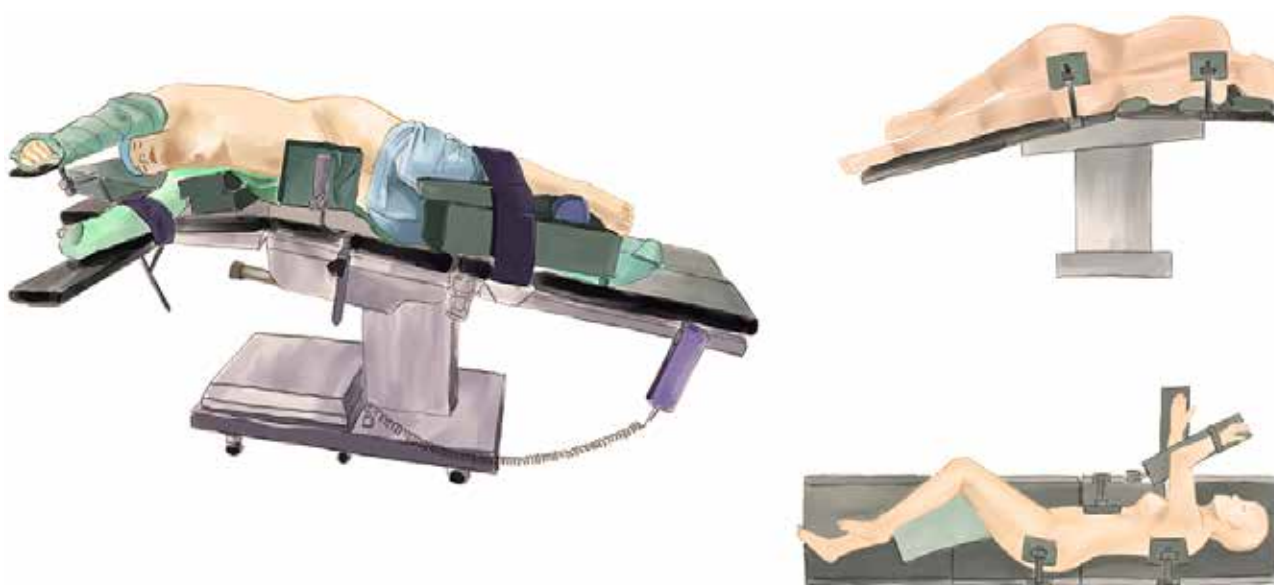


Figure 2 Jackknife position.

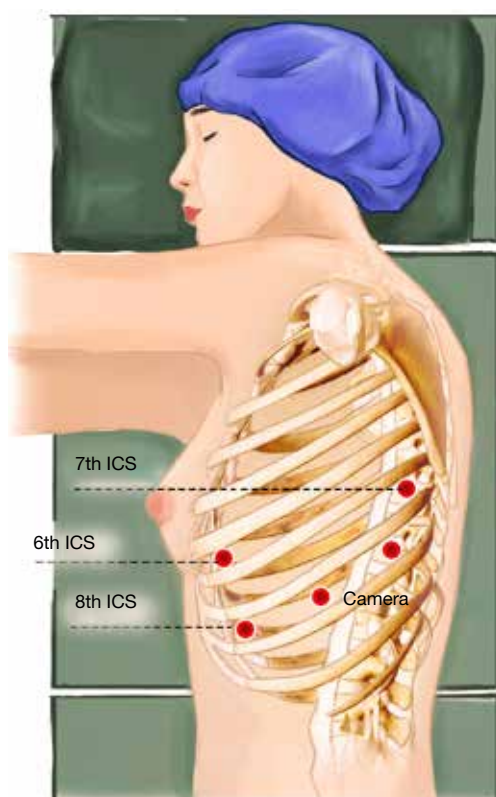


Figure 3 Ports in the 6th, 7th, and 8th ICS. ICS, intercostal space.

and three separate 1.0-cm working ports (for 8-mm trocars) were made in the 6th ICS (#1 arm) at the left anterior axillary line, the 8th ICS (#2 arm) at the left posterior axillary line, and the left 7th ICS (#3 arm), 2 cm from the spine. An auxiliary port (for a 12-mm trocar) was made in the 8th ICS near the costal arch (*Figure 3*).

Installation of the surgical arms

The robot patient cart was positioned directly above the operating table and then connected. The #2 arm was connected to a bipolar cautery forces, and the #1 arm was connected to a unipolar cautery hook.

Surgical procedure

See *Figures 4-18*.

Postoperative condition

Postoperative treatments included anti-inflammatory and phlegm-resolving treatments. The thoracic drainage tube was withdrawn 1 day after surgery, and the patient was discharged 3 days after surgery. No complications were

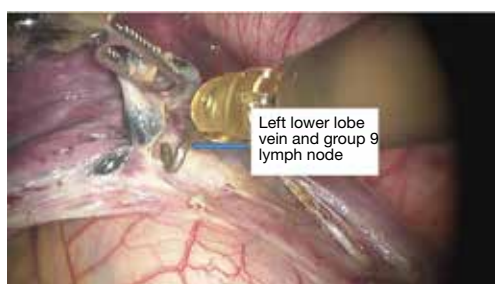


Figure 4 The inferior ligament of the left lung was cut, and group 9 lymph nodes were cleared.

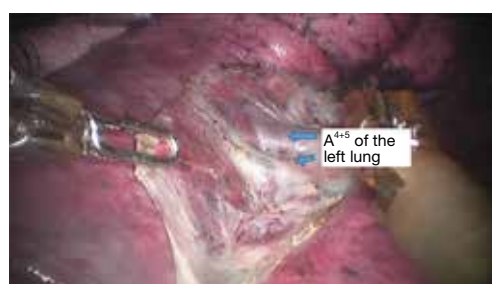


Figure 8 After dissecting from the interlobar fissure, and the branches of pulmonary artery were skeletonized.

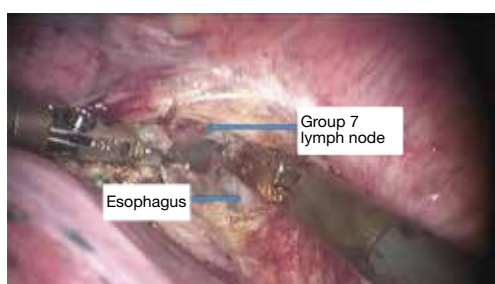


Figure 5 The posterior mediastinal pleura was opened, and the group 7 lymph nodes of the left carina of trachea were cleared.

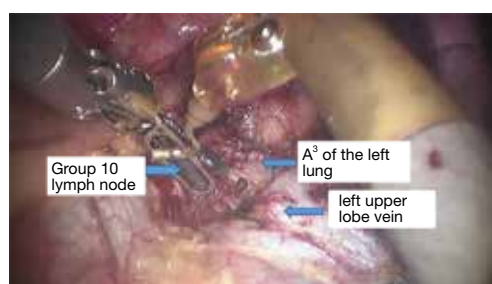


Figure 9 The anterior mediastinal pleura was opened, and the upper lobar veins were skeletonized to connect.

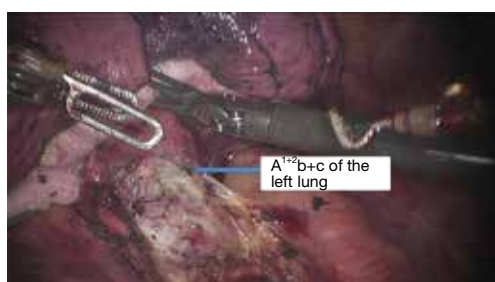


Figure 6 After dissecting from the posterior approach, the pulmonary artery and its branches were exposed.

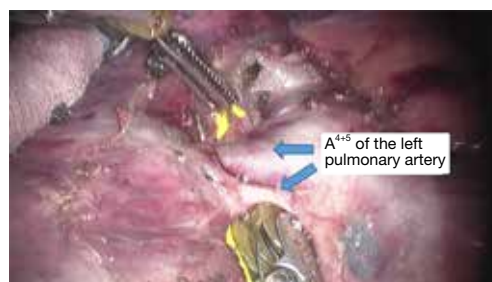


Figure 10 The lingular segmental artery was dissected and suspended with an elastic cuff.

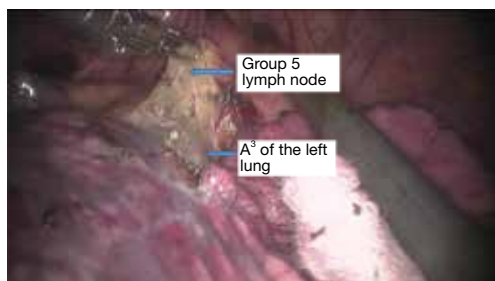


Figure 7 After dissecting along the arterial trunk, the superior mediastinal pleura was opened, and the group 5 and 6 lymph nodes were cleared.

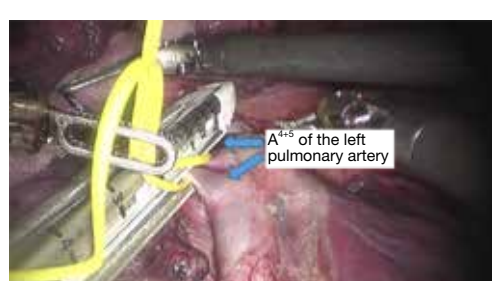


Figure 11 The lingular segmental artery was cut with Endo-GIA.

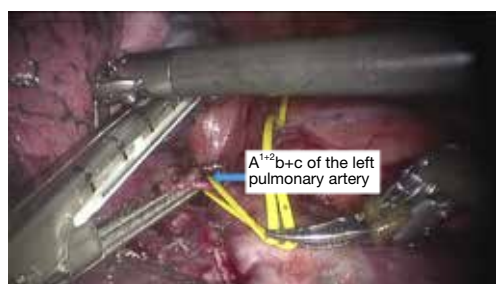


Figure 12 The apicoposterior segmental artery was cut with Endo-GIA.

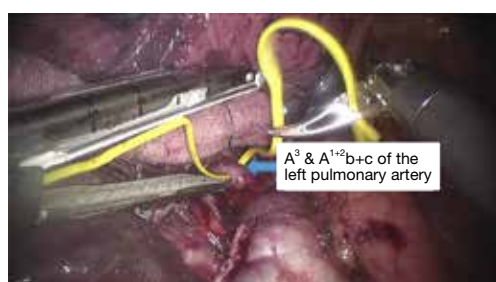


Figure 13 The left anterior segmental artery was cut with Endo-GIA.

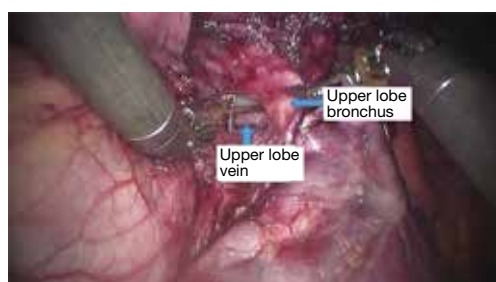


Figure 14 The fissure between the upper lobar veins and the bronchus was dissected.

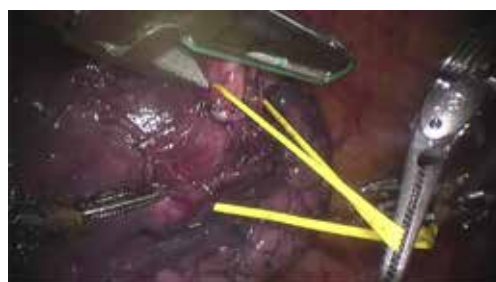

Figure 15 The upper lobar bronchus was cut with Endo-GIA.

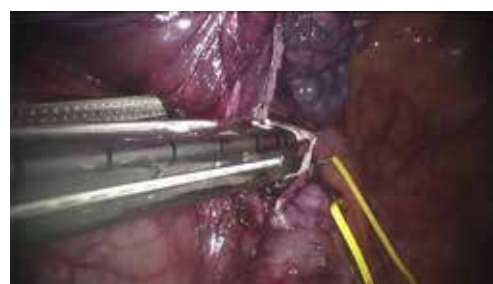

Figure 16 The upper lobar veins was cut with Endo-GIA.

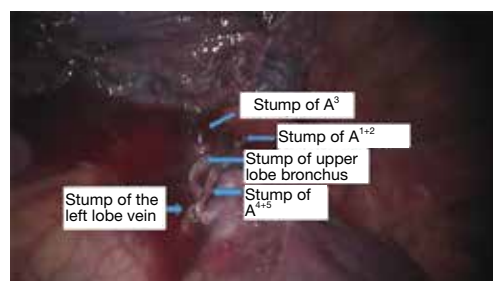


Figure 17 The lung was filled with water to check for air leaks.

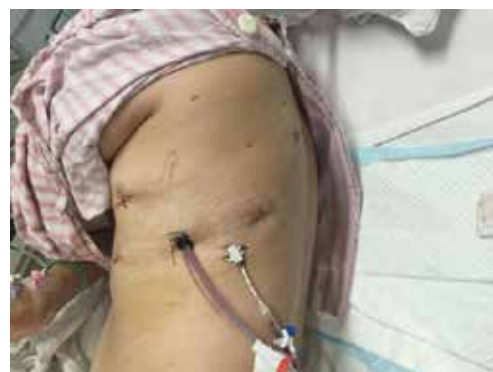

Figure 18 A chest cavity drainage tube was placed in the 8th ICS, and a pigtail tube was placed in the 10th ICS. ICS, intercostal space.

observed during hospitalization. Pathological diagnosis was left upper lobe invasive adenocarcinoma. All lymph nodes were negative. Postoperative pathological stage was pT1aN0M0 (IA adenocarcinoma).

Discussion

Originally, the robotic system was developed for cardiac surgery. The first internal mammary artery graft were performed in 1999 and 2000 (1,2). After these experiences,

robotic systems were used in other fields, such as thoracic surgery for a wide range of procedures, starting with simple ones such the resection of anterior or posterior mediastinal masses (3-5). Robotic technology has certain advantages, especially in minimally invasive anatomic lung resection. The advantages of the robot compared with video-assisted thoracoscopic surgery include improved visualization, improved instrumentation that provides the surgeon with more degrees of movement, better lymph node visualization and dissection, high magnification, the ability to teach using a dual console, and a simulator (6). The left upper lobectomy is the most challenging of all lobectomies because of the complex arterial branches in the left upper lobe. In particular, the short branch A³ hemorrhages easily when dissociating and pulling. The da Vinci Surgical System has four mechanical arms. The #3 arm can help the surgeon find the pulling location, which reduces the assistant's work. Hole of the #3 arm is relatively easy bleeding holes, beginners need to look at the punch. In all surgeries, we dissect the hilum using the posterior approach to expose the pulmonary artery which improves the safety. We inject CO₂ before withdrawing the specimen of lung lobe to form a closed space, which can keep the operation field clear. The assistant uses a forceps tong with a gauze roll to pull the lobe to provide room for the surgeon. Straight nails are used to cut the vessels to lower the cost for the patients.

Acknowledgements

None.

Footnote

Conflicts of Interest: The authors have no conflicts of interest

to declare.

Informed Consent: Written informed consent was obtained from the patient for publication of this manuscript and any accompanying images.

References

1. Carpentier A, Loulmet D, Aupecle B, et al. Computer-assisted cardiac surgery. *Lancet* 1999;353:379-380.
2. Kappert U, Cichon R, Guliernos V, et al. Robotic-enhanced Dresden technique for minimally invasive bilateral internal mammary artery grafting. *Heart Surg Forum* 2000;3:319-321.
3. Yoshino I, Hashizume M, Shimada M, et al. Thoracoscopic thymomectomy with the da Vinci computer-enhanced surgical system. *J Thorac Cardiovasc Surg* 2001;122:783-785.
4. Bodner J, Wykypiel H, Greiner A, et al. Early experience with robot-assisted surgery for mediastinal masses. *Ann Thorac Surg* 2004;78:259-265; discussion 265-266.
5. Rea F, Marulli G, Bortolotti L, et al. Experience with the "da Vinci" robotic system for thymectomy in patients with myasthenia gravis: report of 33 cases. *Ann Thorac Surg* 2006;81:455-459.
6. Cerfolio RJ, Bryant AS. Perspectives on robotic pulmonary resection: It's current and future status. *Ann Cardiothorac Surg* 2012;1:59-60.

doi: 10.21037/amj.2017.01.10

Cite this article as: Xiang J, Yang S, Guo W, Jin R, Zhang Y, Chen X, Wu H, Du H, Han D, Chen K, Li H. Robotic-assisted thoracoscopic surgery: left upper lobectomy. *AME Med J* 2017;2:22.

Robotic-assisted left upper lobectomy: facing the challenge head-on

Simon R. Turner¹, Daniela Molena²

¹Division of Thoracic Surgery, University of Alberta, Edmonton, Canada; ²Thoracic Surgery Service, Memorial Sloan Kettering Cancer Center, New York, NY, USA

Correspondence to: Daniela Molena. Thoracic Surgery Service, Memorial Sloan Kettering Cancer Center, 1275 York Ave, New York, NY 10065, USA. Email: molenad@mskcc.org.

Provenance: This is an invited Editorial commissioned by Section Editor of JTD, Jianfei Shen, MD (Department of Cardiothoracic Surgery, Taizhou Hospital of Zhejiang Province, Wenzhou Medical University, Taizhou, China).

Comment on: Xiang J, Yang S, Guo W, *et al.* Robotic-assisted thoracoscopic surgery: left upper lobectomy. AME Med J 2017;2:22.

Submitted Jul 24, 2017. Accepted for publication Jul 27, 2017.

doi: 10.21037/jtd.2017.08.34

View this article at: <http://dx.doi.org/10.21037/jtd.2017.08.34>

Left upper lobectomy is the most challenging pulmonary lobar resection for thoracic surgeons. The anatomy of the pulmonary artery and its relation to other hilar structures put it at risk of injury, more so than during any other lobectomy. It is, therefore, not surprising that multiple techniques for resection of the left upper lobe have been developed, via both open and minimally invasive approaches. Different techniques call for a specific order in which the hilar structures should be divided, all aiming to accomplish the same thing: a safe, efficient and oncologically optimal removal of the left upper lobe and its associated lymph nodes.

Xiang *et al.* (1) provide an excellent description of just such an approach to robotic left upper lobectomy. As the authors note, robotic surgery has gained significant penetrance in the field of thoracic surgery and is now a routinely applied technique for minimally invasive lobectomy. While the patient described in this case had a clinical stage I lung cancer, robotic technology can be applied to a wide range of clinical presentations. In fact, the enhanced dexterity and optics offered by the robotic platform make it especially useful in locally advanced disease, post-induction therapy cases and when sub-lobar resection is warranted (2). Robotic lobectomy may also offer decreased pain and shortened length of stay compared to other approaches, though evidence of superiority over non-robotic thoracoscopy is limited (3). From an educational standpoint, robotics offers the ability for robust simulation training and the availability of a second “teaching” console in the operating room allows

for easy integration of trainees into all steps of the procedure according to their skill level (4). Disadvantages of robotic lobectomy include cost and the lack of lung palpation (5).

The authors describe what many will recognize as a standard set up with regard to patient positioning and port placement. The use of an access incision, as described, allows easy access by the bedside assistant for suctioning and most importantly for the placement of a sponge-stick for compression of bleeding if a vascular injury occurs. The alternative to this approach is to use a closed system with CO₂ insufflation, which allows for more working room, better visualization and improved mediastinal stability. The hilar dissection described by the authors involves the division of the arterial branches of the left upper lobe first, followed by the left upper lobe bronchus and lastly the superior pulmonary vein. This technique has the advantage of dealing with the arterial branches early on in order to avoid injury to the artery while dissecting the other hilar structures. However, as described, this approach does mandate dissection within the fissure, which may predispose to air leaks. Our preferred approach is to divide the vein first, then the bronchus, saving the artery for last. This allows the artery to be fully visualized once the other hilar structures are divided, and can be done in a completely fissure-less manner. However, this approach does mandate blind dissection behind the bronchus, which can put arterial branches at risk of injury if not done with appropriate care. In our experience, performing first a meticulous intralobar nodal dissection allows complete

exposure of the bronchial and arterial branches and frees up the planes in between these structures, so that they can be encircled and divided with clear visualization. Regardless of the order in which structures are divided, the goal of any technique is a complete resection of all disease and proper staging. Xiang *et al.* provide an excellent description of a proper oncologic resection, with a thorough lymph node dissection, including mediastinal, hilar and intrapulmonary stations. This node dissection is one of the most important aspects of any lobectomy for lung cancer and should not be overlooked. The enhanced ability to dissect these nodes is one of the major advantages of the robotic platform.

Surgeons should be aware of multiple approaches to any operation, especially one as potentially challenging as left upper lobectomy. Thoracotomy, thoracoscopy and robotic approaches all have their place, as do a variety of sequences of controlling each of the hilar structures. Depending on the anatomy of the hilum, the fissure, the chest wall and the tumor, one's standard approach may not always be the best approach and knowledge and flexibility about other techniques might help get the job done in a safe manner. The advantages and disadvantages of each option must be weighed in each unique patient. In describing their preferred technique for robotic left upper lobectomy, Xiang *et al.* provide a useful contribution to the surgical literature.

Cite this article as: Turner SR, Molena D. Robotic-assisted left upper lobectomy: facing the challenge head-on. *J Thorac Dis* 2017;9(8):2323-2324. doi: 10.21037/jtd.2017.08.34

Acknowledgements

None.

Footnote

Conflicts of Interest: The authors have no conflicts of interest to declare.

References

1. Xiang J, Yang S, Guo W, et al. Robotic-assisted thoracoscopic surgery: left upper lobectomy. *AME Med J* 2017;2:22.
2. Turner SR, Latif MJ, Park BJ. Robotic assisted VATS lobectomy for loco-regionally advanced non-small cell lung cancer. *Video-assist Thorac Surg* 2017;2:10.
3. Rajaram R, Mohanty S, Bentrem DJ, et al. Nationwide Assessment of Robotic Lobectomy for Non-Small Cell Lung Cancer. *Ann Thorac Surg* 2017;103:1092-1100.
4. Cerfolio RJ, Cichos KH, Wei B, et al. Robotic lobectomy can be taught while maintaining quality patient outcomes. *J Thorac Cardiovasc Surg* 2016;152:991-997.
5. Nasir BS, Bryant AS, Minnich DJ, et al. Performing robotic lobectomy and segmentectomy: cost, profitability, and outcomes. *Ann Thorac Surg* 2014;98:203-208; discussion 208-209.

Robotic-assisted thoracoscopic surgery: cost and lymph node dissection

Jie Xiang, Hecheng Li

Department of Thoracic Surgery, Ruijin Hospital, Shanghai Jiao Tong University School of Medicine, Shanghai 200025, China

Correspondence to: Professor Hecheng Li. Department of Thoracic Surgery, Ruijin Hospital, Shanghai Jiao Tong University School of Medicine, 197 Ruijin 2nd Road, Shanghai 200025, China. Email: lihecheng2000@hotmail.com.

Provenance: This is an invited article commissioned by the Section Editor Jianfei Shen, MD (Department of Cardiothoracic Surgery, Taizhou Hospital of Zhejiang Province, Wenzhou Medical University, Taizhou, Zhejiang, China).

Response to: Turner SR, Molena D. Robotic-assisted left upper lobectomy: facing the challenge head-on. J Thorac Dis 2017;9:2323-4.

Submitted Sep 25, 2017. Accepted for publication Oct 13, 2017.

doi: 10.21037/jtd.2017.10.46

View this article at: <http://dx.doi.org/10.21037/jtd.2017.10.46>

We appreciate the thoughtful and constructive comments by Dr. Turner and Dr. Molena (1). All of your comments were valuable and helpful in improving our paper. We have studied your comments carefully and have made the suggested corrections, which we hope will meet with your approval. Our responses to your comments are below.

- (I) The use of carbon dioxide insufflation allows for more working room, better visualization, and improved mediastinal stability, and this technique is routinely performed in our center;
- (II) Currently in China, robotic-assisted thoracoscopic surgery (RATS) is significantly more costly than video-assisted thoracoscopic surgery (VATS), but as robot technology becomes more popular, the costs are likely to gradually decrease;
- (III) Louie *et al.* described the dissection of many N1-level lymph nodes (LNs) using RATS, and this report gave surgeons greater confidence to dissect N1-LNs adjacent to the pulmonary artery (2). Cerfolio *et al.* and Veronesi *et al.* showed that dissections of LNs using RATS were comparable to thoracotomies (3,4). We found that RATS has the advantage to perform the LN dissection at any angle of the visual field on account of the flexible arms of the robotic system;
- (IV) The approach described by Dr. Turner and Dr. Molena is also excellent and appropriate for most patients. Thank you for your suggestions.

Acknowledgements

We would like to acknowledge David Tian, Senior Editor

of AME Publishing Company, for editing support.

Footnote

Conflicts of Interest: The authors have no conflicts of interest to declare.

References

1. Turner SR, Molena D. Robotic-assisted left upper lobectomy: facing the challenge head-on. J Thorac Dis 2017;9:2323-2324.
2. Louie BE, Farivar AS, Aye RW, et al. Early experience with robotic lung resection results in similar operative outcomes and morbidity when compared with matched video-assisted thoracoscopic surgery cases. Ann Thorac Surg 2012;93:1598-1604; discussion 1604-1605.
3. Cerfolio RJ, Bryant AS, Skylizard L, et al. Initial consecutive experience of completely portal robotic pulmonary resection with 4 arms. J Thorac Cardiovasc Surg 2011;142:740-746.
4. Veronesi G, Galetta D, Maisonneuve P, et al. Four-arm robotic lobectomy for the treatment of early-stage lung cancer. J Thorac Cardiovasc Surg 2010;140:19-25.

Cite this article as: Xiang J, Li H. Robotic-assisted thoracoscopic surgery: cost and lymph node dissection. J Thorac Dis 2017;9(10):E967. doi: 10.21037/jtd.2017.10.46

Ruijin robotic thoracic surgery: right S⁶ segmentectomy

Chengqiang Li, Su Yang, Wei Guo, Runsen Jin, Yajie Zhang, Xingshi Chen, Han Wu, Hailei Du, Dingpei Han, Kai Chen, Jie Xiang, Hecheng Li

Department of Thoracic Surgery, Ruijin Hospital, Shanghai Jiao Tong University, School of Medicine, Shanghai 200025, China

Correspondence to: Hecheng Li, MD, PhD. Department of Thoracic Surgery, Ruijin Hospital, Shanghai Jiao Tong University, School of Medicine, 197 Ruijin Er Road, Shanghai 200025, China. Email: lihecheng2000@hotmail.com.

Abstract: We are going to share the experience of robotic-assisted thoracoscopic segmentectomy. A 55-year-old patient underwent robotic-assisted thoracic surgery for a nodule in the right segment 6. The patient was discharged on postoperative day 3 without any perioperative complications. This case showed the robotic-assisted technique is a safe approach for lung segmentectomy.

Keywords: Segmentectomy; robotic assisted thoracoscopic surgery

Received: 02 December 2016; Accepted: 27 December 2016; Published: 15 February 2017.

doi: 10.21037/amj.2017.01.11

View this article at: <http://dx.doi.org/10.21037/amj.2017.01.11>

Clinical data

The patient was a 55-year-old woman admitted because of pulmonary nodules for 7 months detected by computed tomography (CT). A CT scan revealed a nodule in the right segment 6 (S⁶), which had enlarged during 7-month follow up. The patient's syndrome did not include cough, shortness of breath, fever, or hoarseness. Her cardiopulmonary function, blood gas analysis, and laboratory tests were normal. There was no positive sign or supraclavicular lymph node enlargement on physical examination. She had no medical history. Survival of the patients who undergo segmentectomy is non-significantly worse (1,2) if the tumor size is smaller than 2.0 cm (3), but there is a functional advantage after radical segmentectomy compare with after a lobectomy (4). Therefore, we performed robotic-assisted right S⁶ segmentectomy for this patient with clinic stage IA lung cancer (*Figure 1*).

Operation steps

Anesthesia and body position

The patient received general anesthesia by double-lumen endotracheal intubation with single-lung (left) ventilation, and was placed in the lateral decubitus position and in a Jackknife position (*Figure 2*).

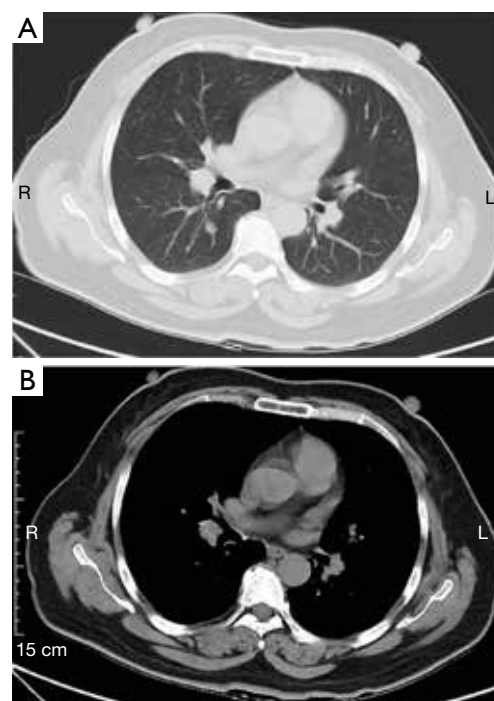


Figure 1 CT scan.

Ports

A 1.5-cm camera port (for a 12-mm trocar) was placed in the 8th intercostal space (ICS) at the right middle axillary

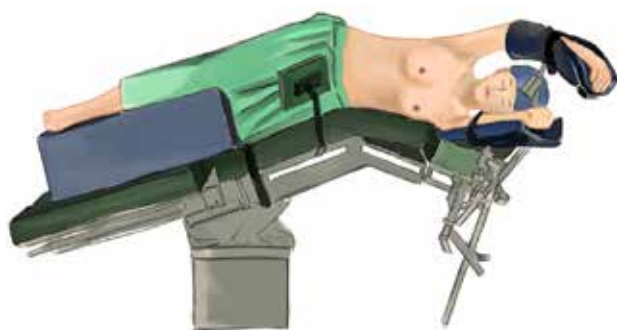


Figure 2 Jackknife position.

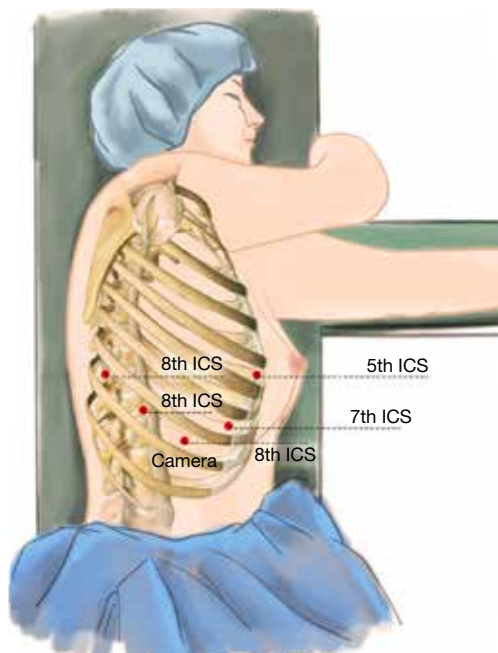


Figure 3 Ports in the 5th, 7th, and 8th ICS. ICS, intercostal space.

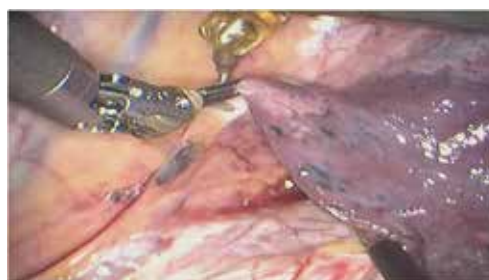

Figure 4 The right inferior pulmonary ligament was exposed.

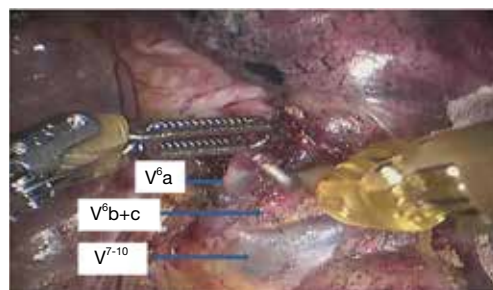


Figure 5 Pulmonary veins V⁶a and V⁶b+c were identified.

line, and three separate 1.0-cm working ports (for 8-mm trocars) were made in the 5th ICS (#1 arm) at the right anterior axillary line, the 8th ICS (#2 arm) at the right posterior axillary line, and the right 8th ICS (#3 arm), 2 cm from the spine. An auxiliary port (for a 12-mm trocar) was made in the 7th ICS near the costal arch (*Figure 3*).

Installation of the surgical arms

The robot patient cart is positioned directly above the operating table and then connected. The #2 arm is connected to the bipolar cautery grab, and the #1 arm is connected to a unipolar cautery hook.

Surgical procedure

See *Figures 4-11*.

Postoperative condition

The postoperative treatments include anti-inflammatory,

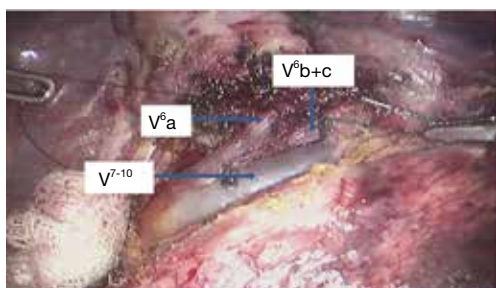


Figure 6 V^{6a} was cut and V^{6b+c} was preserved.

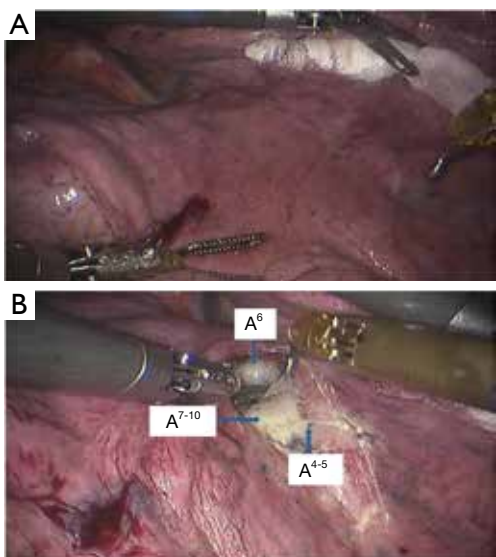


Figure 7 The interlobar fissure was exposed to facilitate a later pulmonary artery skeletonization.

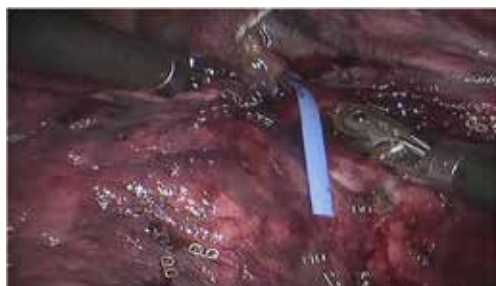


Figure 8 Artery A⁶ was cut.

and phlegm-resolving treatment. The drainage tube was withdrawn 2 days after surgery, and the patient was discharged 3 days after surgery. No complications were observed during hospitalization. Pathologic diagnosis was

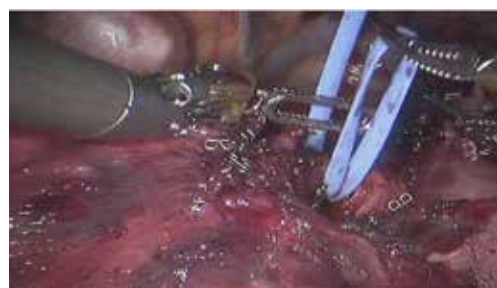

Figure 9 Bronchus B⁶ was cut.

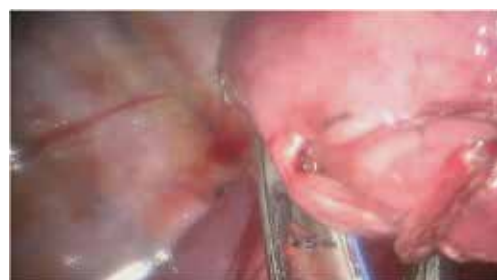

Figure 10 The right lung was inflated and then deflated to show the inflation-deflation line. The S⁶ segmentectomy was completed along the simple intersegmental plane.

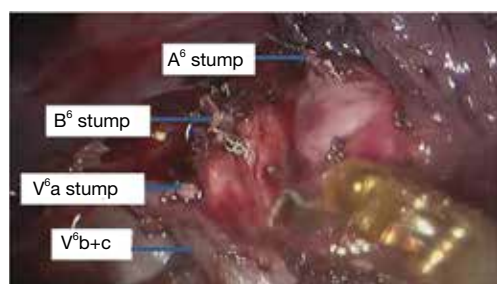


Figure 11 The stumps were exposed.

microinvasive carcinoma (pT1aN0M0), and all the lymph nodes were negative.

Acknowledgements

None.

Footnote

Conflicts of Interest: The authors have no conflicts of interest to declare.

Informed Consent: Written informed consent was obtained from the patient for publication of this manuscript and any accompanying images.

References

1. Keenan RJ, Landreneau RJ, Maley RH Jr, et al. Segmental resection spares pulmonary function in patients with stage I lung cancer. *Ann Thorac Surg* 2004;78:228-233; discussion 228-233.
2. Ginsberg RJ, Rubinstein LV. Randomized trial of lobectomy versus limited resection for T1 N0 non-small cell lung cancer. Lung Cancer Study Group. *Ann Thorac Surg* 1995;60:615-622; discussion 622-623.
3. Okada M, Nishio W, Sakamoto T, et al. Effect of tumor size on prognosis in patients with non-small cell lung cancer: the role of segmentectomy as a type of lesser resection. *J Thorac Cardiovasc Surg* 2005;129:87-93.
4. Harada H, Okada M, Sakamoto T, et al. Functional advantage after radical segmentectomy versus lobectomy for lung cancer. *Ann Thorac Surg* 2005;80:2041-2045.
5. Nomori H, Okada M. Illustrated textbook of anatomical pulmonary segmentectomy. New York: Springer-Verlag, 2012.

doi: 10.21037/amj.2017.01.11

Cite this article as: Li C, Yang S, Guo W, Jin R, Zhang Y, Chen X, Wu H, Du H, Han D, Chen K, Xiang J, Li H. Ruijin robotic thoracic surgery: right S⁶ segmentectomy. *AME Med J* 2017;2:23.

Technical aspects of video-assisted and robotic-assisted thoracoscopic segmentectomy

Jon A. Lutz, Gregor J. Kocher

Division of General Thoracic Surgery, Bern University Hospital, University of Bern, Bern, Switzerland

Correspondence to: Gregor J. Kocher, MD. Division of General Thoracic Surgery, University Hospital Bern, Bern CH-3010, Switzerland.

Email: gregor.kocher@insel.ch.

Provenance: This is an invited Editorial commissioned by Section Editor of *JTD*, Jianfei Shen, MD (Department of Cardiothoracic Surgery, Taizhou Hospital of Zhejiang Province, Wenzhou Medical University, Taizhou, China).

Comment on: Li C, Yang S, Guo W, *et al.* Ruijin robotic thoracic surgery: right S⁶ segmentectomy. *AME Med J* 2017;2:23.

Submitted Jul 21, 2017. Accepted for publication Jul 24, 2017.

doi: 10.21037/jtd.2017.08.36

View this article at: <http://dx.doi.org/10.21037/jtd.2017.08.36>

Introduction

Li and co-authors very nicely presented their technique of robot-assisted thoracic surgery (RATS) S⁶-segmentectomy illustrated by high quality figures (1). They presumably base their approach on the excellent book of Nomori and Okada (2), one of the most important references for open segmentectomy of the lung.

It is not the main goal of this editorial to simply expand on the advantages and drawbacks of the robotic approach, but rather to discuss the technical aspects of minimally invasive segmentectomy in general. In the presented case, the surgical procedure was performed with the assistance of the da Vinci Surgical System (Intuitive Surgical Inc., Sunnyvale, CA, USA). The integrated 3D vision, the ergonomics for the operating surgeon and the 7 degrees of freedom of the EndoWrist instrument (3) make the robotic approach a good tool to pass from an open to a minimally invasive technique. If safety concerns about bleedings have been reported for RATS anatomical resections compared to video-assisted thoracic surgery (VATS) with more need for conversion to thoracotomy (4), the use of appropriate measures can prevent such bleedings, or at least manage them once occurred (5). While superior costs of RATS compared to VATS are well established (6), this was not a disadvantage for gaining the most relative market share increase (+200%) for anatomical resections of lung cancer between 2010 and 2012 in the United States (7). Comparisons of the different approaches showed no perioperative or oncological benefit of RATS

compared to VATS (8). Finally, in recent years the uniportal approach has become increasingly popular and is without question challenging the multiportal VATS approach, and with that it could also become the new challenger of robotic surgery (9).

Background

While VATS lobectomy, including sublobar anatomical resections, have a history of 25 years of development, RATS lobectomy started more than 10 years later (10). Distinct VATS approaches have been used, leading to the apparitions of different surgical schools. Some advocate VATS lobectomy through a posterior approach (11) with the first step being the dissection of the artery in the fissure. Others recommend the anterior approach with a pragmatic sequence of section of hilar structures from anterior to posterior as they are encountered during the dissection (12). Most of these techniques use either four or three ports including a utility port, not last for security issues. This utility port has also been questioned with “closed chest” VATS anatomical resections (13) or, on the other hand, expanded at the costs of the standard ports resulting in the so called “uniportal approach” (14). Finally, the question of air leakage has been addressed specifically for the “fissureless” patient. The development of the “fissure last” technique (15), or the thoracoscopic tunnel technique allowing a “fissure first, hilum last” approach (16) are both strategies to overcome this frequent postoperative problem.

Technical considerations for robotic segmentectomy

What can we learn from the VATS experience and implement into RATS segmentectomy techniques?

In order to answer this question, we focused on three particular points, which are of crucial importance when defining a specific surgical technique.

Vein or artery first?

There are mainly three concerns about the sequence of vessel ligation during segmentectomy: the feasibility of the resection, bleeding and oncological considerations. Regarding the access to the segmental hilum, the primary dissection of the artery in the fissure can help identifying the basic anatomy (17). For VATS lobectomies, Li *et al.* showed that there was significantly less bleeding when the artery was ligated first (105 *vs.* 148 mL) (18). However, this difference did not have any clinical impact on short term patient outcomes. Somewhat more important seems to be the finding of Kurusu and colleagues, that more circulating tumor cells were seen in patients in whom the artery was ligated before the vein during lobectomy (19). So far, no clinical impact of the sequence of vessel ligation on tumor recurrence (20) or long-term survival was demonstrated (18). Since any additional manipulation of the lung during surgery could possibly result in an increase in tumor recurrence, a pragmatic sequence of vessel ligation should be chosen (20).

Sparing of the V⁶+c subsegmental veins and intersegmental plane issues

The classic open segmentectomy method illustrated by Nomori and Okada (2) uses the intersegmental veins as an orientation for the plane of dissection while tearing apart the parenchyma along this anatomical structure. This manoeuvre inevitably results in a wounded surface necessitating sealing of small bleeders and air leaks with sutures and/or biologic sealant products. Furthermore, this proceeding is difficult to apply in a minimally invasive setting and therefore most surgeons use stapling devices for this step. The volume loss in the remaining segments due to the shrinkage induced by the technique of stapling however does not result in a decreased postoperative pulmonary function (21) and has only minimal clinical and radiological consequences (22). One could hypothesize that preserving the intersegmental veins could improve the venous drainage of the adjacent lung segments, but this problem is probably more/only of clinical relevance when performing for example a lingula-sparing lobectomy rather

than a simple segmentectomy of the lower lobe. On the other hand, section of the intersegmental veins can give the surgeon a better access for the subsequent positioning of the stapling device near the segmental hilum. Since in RATS segmentectomies the section of the parenchyma is usually performed by the surgeon at the operating table with usual endoscopic staplers, one will be able to translate every evolution in the VATS technique for managing the intersegmental plane to robotic procedures as well.

Lymphatic drainage

The lymphatic drainage is well known to follow the bronchial tree (23). There is a suspected tendency to perform a less thorough lymphadenectomy during segmentectomy than during lobectomy. This could be one of the reasons for the currently observable trend towards a higher incidence of local recurrence after segmentectomy compared to lobectomy. Wolf *et al.* (24) for example showed that when more lymph nodes are sampled, the local recurrence rate seems to be similar to that encountered after lobectomy. For this reason, some groups even advocate a routine of frozen section of intersegmental lymph nodes during segmentectomy with the consequence of an extended resection, mainly lobectomy.

Closing remarks

As long as the costs won't stop the broadened use of robotics as an alternative to VATS sublobar resections (6), its usage will continue to develop. It will be interesting with the growing experience gained over the years, if the advantages of RATS will be as worthy for relatively trivial segmentectomies like S⁶, as for more complex partial basilar segmentectomies. The integrated features of the da Vinci surgical system already allows a better visualization of the intersegmental plane with the use of indocyanine green (25). We can imagine that augmented reality—when ripe for clinical usage—will be first implemented in RATS systems, opening new possibilities for complex segmentectomies.

Acknowledgements

None.

Footnote

Conflicts of Interest: The authors have no conflicts of interest to declare.

References

1. Li Ch, Yang S, Guo W, et al. Ruijin robotic thoracic surgery: right S⁶ segmentectomy. *AME Med J* 2017;2:23.
2. Nomori H, Okada M. *Illustrated Anatomical Segmentectomy for Lung Cancer*. Tokyo: Springer, 2011.
3. Park BJ, Flores RM, Rusch VW. Robotic assistance for video-assisted thoracic surgical lobectomy: technique and initial results. *J Thorac Cardiovasc Surg* 2006;131:54-59.
4. Augustin F, Bodner J, Maier H, et al. Robotic-assisted minimally invasive vs. thoracoscopic lung lobectomy: comparison of perioperative results in a Learning curve setting. *Langenbecks Arch Surg* 2013;398:895-901.
5. Kocher GJ, Schmid RA, Melfi FMA. Robotic lobectomy: tips, pitfalls and troubleshooting. *Eur J Cardiothorac Surg* 2014;46:e136-e138.
6. Bao F, Zhang Ch, Yang Y, et al. Comparison of robotic and video-assisted thoracic surgery for lung cancer: a propensity-matched analysis. *J Thorac Dis* 2016;8:1798-1803.
7. Rajaram R, Mohanty S, Bentrem DJ, et al. Nationwide Assessment of Robotic Lobectomy for Non-Small Cell Lung Cancer. *Ann Thorac Surg* 2017;103:1092-1100.
8. Cao C, Manganas C, Ang SC, et al. A systematic review and meta-analysis on pulmonary resections by robotic video-assisted thoracic surgery. *Ann Cardiothorac Surg* 2012;1:3-10.
9. Harris CG, James RS, Tian DH, et al. Systematic review and meta-analysis of uniportal versus multiportal video-assisted thoracoscopic lobectomy for lung cancer. *Ann Cardiothorac Surg* 2016;5:76-84.
10. Melfi FM, Fanucchi O, Davini F, et al. Robotic lobectomy for lung cancer: evolution in technique and technology. *Eur J Cardiothorac Surg* 2014;46:626-630; discussion 630-631.
11. Richards JM, Dunning J, Oparka J, et al. Video-assisted thoracoscopic lobectomy: the Edinburgh posterior approach. *Ann Cardiothorac Surg* 2012;1:61-69.
12. Hansen HJ, Petersen RH. Video-assisted thoracoscopic lobectomy using a standardized three-port anterior approach – The Copenhagen experience. *Ann Cardiothorac Surg* 2012;1:70-76.
13. Gossot D. Technical tricks to facilitate totally endoscopic major pulmonary resections. *Ann Thorac Surg* 2008;86:323-326.
14. Gonzalez-Rivas D. VATS Lobectomy: Surgical Evolution from Conventional VATS to Uniportal Approach. *ScientificWorldJournal* 2012;2012:780842.
15. Mitchell JD. Techniques of VATS lobectomy. *J Thorac Dis* 2013;5:S177-S181.
16. Decaluwe H, Sokolow Y, Deryck F, et al. Thoracoscopic tunnel technique for anatomical lung resections: a “fissure first, hilum last” approach with staplers in the fissureless patient. *Interact Cardiovasc Thorac Surg* 2015;21:2-7.
17. Yan TD. Surgical atlas of thoracoscopic lobectomy and segmentectomy. *Ann Cardiothorac Surg* 2014;3:183-191.
18. Li F, Jiang G, Chen Y, et al. Curative Effects of Different Sequences of Vessel Interruption During the Completely Thoracoscopic Lobectomy on Early Stage Non-Small Cell Lung Cancer. *Ann Thorac Cardiovasc Surg* 2015;21:536-543.
19. Kurusu Y, Yamashita J, Hasashi N, et al. The sequence of vessel ligation affects tumor release into the circulation. *J Thorac Cardiovasc Surg* 1998;116:107-113.
20. Refaely Y, Sadetzki S, Chetrit A, et al. The sequence of vessel interruption during lobectomy for non-small cell lung cancer: Is it indeed important? *J Thorac Cardiovasc Surg* 2003;125:1313-1320.
21. Tao H, Tanaka T, Hayashi T, et al. Influence of stapling the intersegmental planes on lung volume and function after segmentectomy. *Interact CardioVasc Thorac Surg* 2016;23:548-552.
22. Ojanguren A, Gossot D, Seguin-Givelet A. Division of the intersegmental plane during thoracoscopic segmentectomy: is stapling an issue? *J Thorac Dis* 2016;8:2158-2164.
23. Nohl-Oser HC. An investigation of the anatomy of the lymphatic drainage of the lungs. *Ann R Coll Surg Engl* 1972;51:157-176.
24. Wolf AS, Richards WG, Jaklitsch MT, et al. Lobectomy versus sublobar resection for small (2cm or less) non-small cell lung cancers. *Ann Thorac Surg* 2011;92:1819-1823.
25. Pardolesi A, Veronesi G, Solli P, et al. Use of indocyanine green to facilitate intersegmental plane identification during robotic anatomic segmentectomy. *J Thorac Cardiovasc Surg* 2014;148:737-738.

Cite this article as: Lutz JA, Kocher GJ. Technical aspects of video-assisted and robotic-assisted thoracoscopic segmentectomy. *J Thorac Dis* 2017;9(8):2320-2322. doi: 10.21037/jtd.2017.08.36

Robotic-assisted thoracoscopic segmentectomy: there is a long way to go

Chengqiang Li, Hecheng Li

Department of Thoracic Surgery, Ruijin Hospital Shanghai Jiao Tong University, School of Medicine, Shanghai 200025, China

Correspondence to: Hecheng Li, MD, PhD. Chair, Department of Thoracic Surgery, Ruijin Hospital Shanghai Jiao Tong University, School of Medicine, 197 Ruijin Er Road, Shanghai 200025, China. Email: lihecheng2000@hotmail.com.

Provenance: This is an invited article commissioned by the Section Editor Jianfei Shen, MD (Department of Cardiothoracic Surgery, Taizhou Hospital of Zhejiang Province, Wenzhou Medical University, Taizhou, China).

Response to: Lutz JA, Kocher GJ. Technical aspects of video-assisted and robotic-assisted thoracoscopic segmentectomy. J Thorac Dis 2017;9:2320-2.

Submitted Sep 25, 2017. Accepted for publication Oct 13, 2017.

doi: 10.21037/jtd.2017.10.81

View this article at: <http://dx.doi.org/10.21037/jtd.2017.10.81>

We appreciate the reviewer's excellent comments regarding robotic-assisted thoracoscopic S⁶ segmentectomy (1). We agree that there is no standardized technique for the video-assisted thoracic surgery (VATS) approach, but without a doubt, the future of surgery is going in the direction of single port access and robotics. The advantages of robotic VATS (R-VATS) over conventional VATS include an additional four degrees of freedom (internal pitch, internal yaw, rotation, and grip), elimination of the fulcrum effect, superior 3-D vision from the binocular camera, tremor filtration, and improved ergonomic positioning for the surgeon (2-4). The 5-year overall survival of stage I non-small cell lung cancer for the robotic, VATS, and open matched groups were 77.6%, 73.5%, and 77.9%, respectively, and there was no statistically significant difference between the groups (5). However, R-VATS has been associated with reductions in mortality, length of hospital stay, and overall complication rates when compared to both open and VAT surgeries (6).

In your comments, you referred to a study that suggested that R-VATS was associated with a higher rate of intraoperative conversion when compared with the VATS approach (7). However, in that study, the difference in the conversion rate was not statistically significant (19.2% *vs.* 8.4%, $P=0.4189$), and the reasons for conversion in the robotic-assisted lobectomy group were bleeding from a pulmonary artery with emergent conversion in one patient and four non-emergent conversions due to safety (two minor bleedings, one atypical anatomy, and one extended resection).

These conversions could be avoided with additional training. Other studies have shown no differences in the conversion rates from the R-VATS and VATS groups (5,8,9), albeit with higher conversion rates for the first 30 R-VATS.

Segmentectomy is widely accepted as an alternative procedure to treat stage IA non-small cell lung cancers that are 2 cm or less in low-risk and high-risk patients as this method preserves lung function with a similar prognosis (10-12). Management of the intersegmental plane, but not the intersegmental vein, remains controversial. The intersegmental vein should be preserved because it is a landmark for the intersegmental plane, which is in the central portion around the hilum, and because sacrificing the segmental vein could impair gas exchange leading to a reduction in pulmonary function. However, if the margin from the tumor is considered insufficient, the intersegmental vein should be removed without hesitation (13,14). Three techniques, stapling, electrocautery, or a combination of stapling and electrocautery, are used to cut the intersegmental plane. Stapling is easy and may reduce the rate of postoperative air leakage; however, it is expensive and may result in reduced postoperative pulmonary function as it may cause shrinkage of the preserved segment (15,16). If the intersegmental plane is closed with a linear staple line during a simple segmentectomy, such as an S⁶ segmentectomy, the reduction in lung volume or function can be minimized (17). Dissection of the segmental plane by electrocautery is strongly recommended because it offers some advantages, including full expansion of the residual

segments and easier assessment of surgical margins (13-16). Air leakage was found to be an issue after segmental resection in one study (13), but it can be easily remedied with a plane pleural closure or a mesh-cover for the intersegmental plane, which successfully blocks air leakage from an opened intersegmental plane up to 30 cm H₂O of airway pressure (16,18,19). The method of cutting the shallow lung tissue with electrocautery and cutting the deep lung tissue with a stapler is widely used because it effectively prevents air leakage and preserves pulmonary function (16,20). The robotic approach resulted in greater lymph node assessment (5) when compared to conventional VATS (6,9,10). The strategy for lymph node dissection and selection of lymph nodes for intraoperative frozen section is described in the “segmentectomy Bible” (21). Only one randomized controlled trial has shown that sublobar resection was inferior with regards to prognosis when compared with lobectomy (22), and in this trial, more than 30% of the sublobar resections were wedge resections for tumors up to 3 cm in diameter. In contrast, other studies have consistently shown that the prognoses of segmentectomy and lobectomy are similar (10,12,23). The Japanese Cancer Oncology Group (JCOG) 0802 will clarify this controversy in the future (24).

Acknowledgements

We would like to acknowledge David Tian, Senior Editor of AME Publishing Company, for editing support.

Footnote

Conflicts of Interest: The authors have no conflicts of interest to declare.

References

1. Lutz JA, Kocher GJ. Technical aspects of video-assisted and robotic-assisted thoracoscopic segmentectomy. *J Thorac Dis* 2017;9:2320-2322.
2. Park BJ, Flores RM, Rusch VW. Robotic assistance for video - assisted thoracic surgical lobectomy: technique and initial results. *J Thorac Cardiovasc Surg* 2006;131:54-59.
3. Melfi FM, Mussi A. Robotically assisted lobectomy: learning curve and complications. *Thorac Surg Clin* 2008;18:289-295. vi-vii..
4. LaPietra A, Grossi EA, Derivaux CC, et al. Robotic-assisted instruments enhance minimally invasive mitral valve surgery. *Ann Thorac Surg* 2000;70:835-838.
5. Yang HX, Woo KM, Sima CS, et al. Long-term Survival Based on the Surgical Approach to Lobectomy For Clinical Stage I Non-small Cell Lung Cancer. *Ann Surg* 2017;265:431-437.
6. Kent M, Wang T, Whyte R, et al. Open video-assisted thoracic surgery and robotic lobectomy: review of a national database. *Ann Thorac Surg* 2014;97:236-242.
7. Augustin F, Bodner J, Maier H, et al. Robotic-assisted minimally invasive vs thoracoscopic lung lobectomy: comparison of perioperative results in a Learning curve setting. *Langenbecks Arch Surg* 2013;398:895-901.
8. Zipu Y, Xie Q, Guo L, et al. Perioperative outcomes of robotic surgery for the treatment of lung cancer compared to a conventional video-assisted thoracoscopic surgery (VATS) technique. *Oncotarget* 2017. [Epub ahead of print].
9. Bao F, Zhang C, Yang Y, et al. Comparison of robotic and video-assisted thoracic surgery for lung cancer: a propensity-matched analysis. *J Thorac Dis* 2016;8:1798-1803.
10. Okada M, Koike T, Higashiyama M, et al. Radical sublobar resection for small-sized non-small cell lung cancer: a multicenter study. *J Thorac Cardiovasc Surg* 2006;132:769-775.
11. Keenan RJ, Landreneau RJ, Maley RH Jr, et al. Segmental Resection Spares Pulmonary Function in Patients With Stage I Lung Cancer. *Ann Thorac Surg* 2004;78:228-233; discussion 228-233.
12. Nomori H, Mori T, Ikeda K, Yoshimoto K, et al. Segmentectomy for selected cT1N0M0 non-small cell lung cancer: A prospective study at a single institute. *J Thorac Cardiovasc Surg* 2012;144:87-93.
13. Okada M, Mimura T, Ikegaki J, et al. A novel video-assisted anatomic segmentectomy technique: Selective segmental inflation via bronchofiberoptic jet followed by cautery cutting. *J Thorac Cardiovasc Surg* 2007;133:753-758.
14. Ohtsuka T, Goto T, Anraku M, Kohno M, et al. Dissection of lung parenchyma using electrocautery is a safe and acceptable method for anatomical sublobar resection. *J Cardiothorac Surg* 2012;7:42.
15. Yoshimoto K, Nomori H, Mori T, et al. Combined subsegmentectomy: postoperative pulmonary function compared to multiple segmental resection. *J Cardiothorac Surg* 2011;6:17.
16. Asakura K, Izumi Y, Kohno M, et al. Effect of cutting technique at the intersegmental plane during segmentectomy on expansion of the preserved segment: comparison between staplers and scissors in ex vivo pig

- lung. *Eur J Cardiothorac Surg* 2011;40:e34-e38.
17. Tao H, Tanaka T, Hayashi T, et al. Influence of stapling the intersegmental planes on lung volume and function after segmentectomy. *Interact Cardiovasc Thorac Surg* 2016;23:548-552.
18. Yoshimoto K, Nomori H, Mori T, et al. Comparison of postoperative pulmonary function and air leakage between pleural closure vs. mesh-cover for intersegmental plane in segmentectomy. *J Cardiothorac Surg* 2011;6:61.
19. Saito H, Konno H, Atari M, et al. Management of Intersegmental Plane on Pulmonary Segmentectomy Concerning Postoperative Complications. *Ann Thorac Surg* 2017;103:1773-1780.
20. Nomori H. Segmentectomy for c-T1N0M0 non-small cell lung cancer. *Surg Today* 2014;44:812-819.
21. Nomori H, Okada M. *Illustrated textbook of anatomical pulmonary segmentectomy*. New York: Springer, 2012.
22. Lung Cancer Study Group. Ginsberg RH, Rubinstein LV. Randomized trial of lobectomy versus limited resection for T1N0non-small cell lung cancer. *Ann Thorac Surg* 1995;60:615-622.
23. Sawabata N, Miyaoka E, Asamura H, et al. Japanese Lung Cancer Registry study of 11663 surgical cases in 2004: demographic and prognosis changes over decade. *J Thorac Oncol* 2011;6:1229-1235.
24. Nakamura K, Saji H, Nakajima R, et al. A phase III randomized trial of lobectomy versus limited resection for small-sized peripheral non-small cell lung cancer (JCOG0802/WJOG4607L). *Jpn J Clin Oncol* 2010;40:271-274.

Cite this article as: Li C, Li H. Robotic-assisted thoracoscopic segmentectomy: there is a long way to go. *J Thorac Dis* 2017;9(10):E968-E970. doi: 10.21037/jtd.2017.10.81

Ruijin robotic thoracic surgery: S¹⁺²⁺³ segmentectomy of the left upper lobe

Han Wu, Su Yang, Wei Guo, Runsen Jin, Yajie Zhang, Xingshi Chen, Hailei Du, Dingpei Han, Kai Chen, Jie Xiang, Hecheng Li

Department of Thoracic Surgery, Ruijin Hospital, Shanghai Jiao Tong University, School of Medicine, Shanghai 200025, China

Correspondence to: Hecheng Li, MD, PhD. Department of Thoracic Surgery, Ruijin Hospital, Shanghai Jiao Tong University, School of Medicine, 197 Ruijin Er Road, Shanghai 200025, China. Email: lihecheng2000@hotmail.com.

Abstract: Robotic-assisted thoracic segmentectomy is a minimally invasive option for the treatment of the resectable lung cancer. Its advantages over conventional video-assisted thoracic surgery include a clear and magnified three-dimensional operative field and the flexible multi-joint arms. This technical article presents a case from our center to share some surgical techniques for this procedure.

Keywords: Segmentectomy; robotic-assisted thoracic surgery

Received: 02 December 2016; Accepted: 27 December 2016; Published: 17 January 2017.

doi: 10.21037/amj.2017.01.12

View this article at: <http://dx.doi.org/10.21037/amj.2017.01.12>

Clinical data

A 65-year-old woman was admitted because of pulmonary nodules for 1 month detected by computed tomography (CT). Chest CT (*Figure 1*) showed ground glass opacity (GGO) in the S¹⁺²⁺³ segment of the left upper lobe. The patient's complaints did not include chest tightness, shortness of breath, cough, expectoration, low fever, chills, night sweats or hoarseness. Cardiopulmonary function, blood gas analysis and laboratory tests were normal. There was no positive sign or supraclavicular lymph node enlargement in physical examination. She had no past medical history.

Operation steps

Anesthesia and body position

The patient received general anesthesia by double-lumen endotracheal intubation and was placed in the lateral decubitus position and in a jackknife position with single-lung (right) ventilation (*Figure 2*).

Ports

A 1.5-cm camera port (for a 12-mm trocar) was created in

the 8th intercostal space (ICS) at the left mid axillary line, and three separate 1.0-cm working ports (for 8-mm trocars) were made in the 6th ICS (#1 arm) at the left anterior axillary line, the 8th ICS (#2 arm) at the left posterior axillary line, and the left 7th ICS (#3 arm), 2 cm from the spine. An auxiliary port (for a 12-mm trocar) was made in the 8th ICS near the costal arch (*Figure 3*).

Installation of the surgical arms

The robot patient cart was positioned above the operating table and then connected. The #1 arm was connected to a unipolar cautery hook and the #2 arm was connected with bipolar cautery forceps.

Surgical procedure

See *Figures 4-18*.

Postoperative condition

Postoperative treatments included anti-inflammatory and phlegm-resolving treatments. The thoracic drainage tube was withdrawn 2 days after surgery, and the patient was discharged 3 days after surgery. No complications

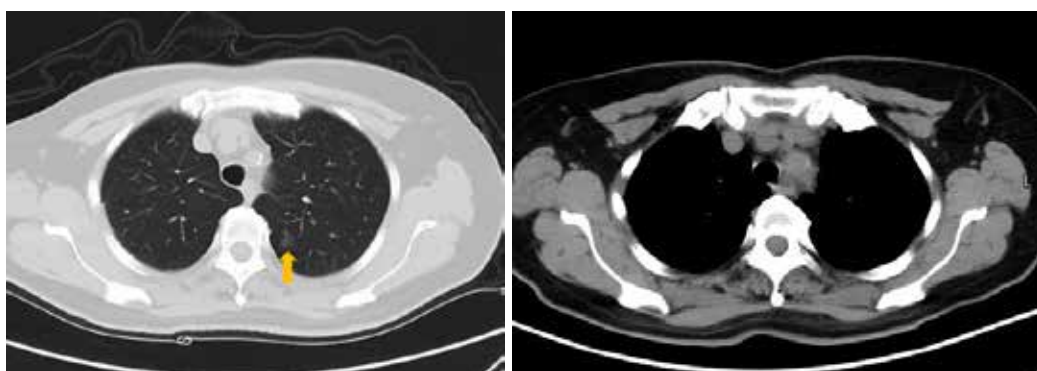


Figure 1 Preoperative CT showed GGO in the S¹⁺²⁺³ segment of the left upper lobe. GGO, ground glass opacity.

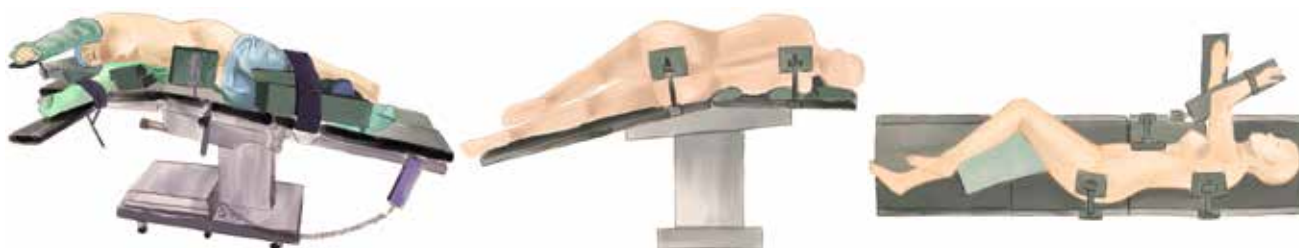

Figure 2 Jackknife position.

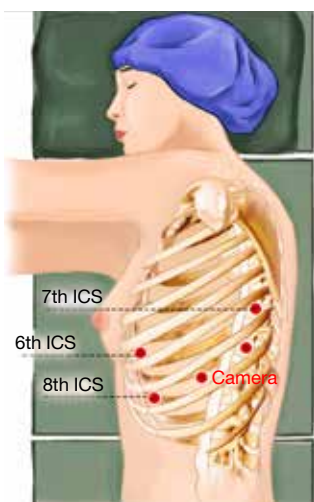


Figure 3 Ports in the 6th, 7th, and 8th ICS. ICS, intercostal space.

were observed during hospitalization. Pathological diagnosis was atypical adenomatous hyperplasia (AAH) at local alveolar epithelium of the S¹⁺²⁺³ segment of the left upper lobe.

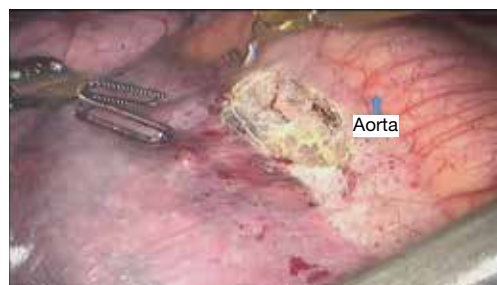

Figure 4 The mediastinal pleura was opened.

Discussion

The segmental dissection of the left upper lobe is a major challenge in robotic surgery because of the thin segmental vessels and bronchus. In addition, it is not easy to determine the segmental plane. The many arterial branches in the left upper lobe should be identified carefully when dissociating and pulling, especially the short branch A³. For that reason, the surgeon should be familiar with the fine anatomy of the vessels and bronchus. The robot has a clear and magnified field of view and flexible arms, which make dissection and use of Endo-GIA

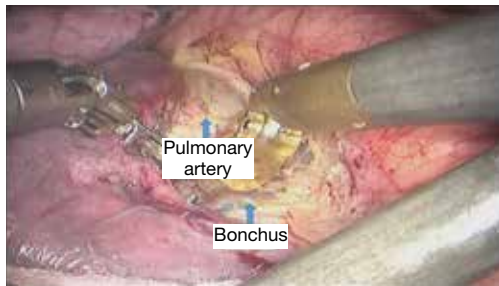


Figure 5 Lymph nodes of the bronchus and pulmonary artery were dissected, and the pulmonary artery was exposed.

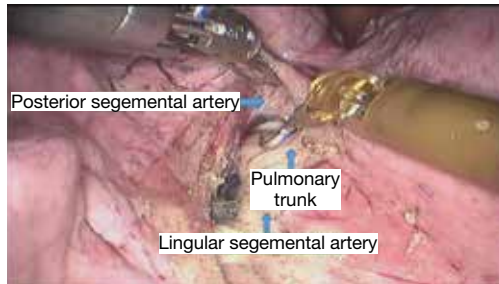


Figure 6 The pulmonary artery was dissected from the interlobar fissure, and a tunnel was formed to open the posterior interlobar fissure.

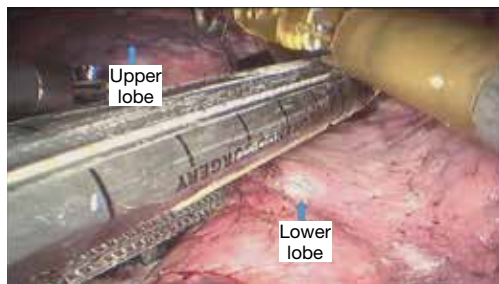


Figure 7 The posterior interlobar fissure was transected with the Echelon flex.

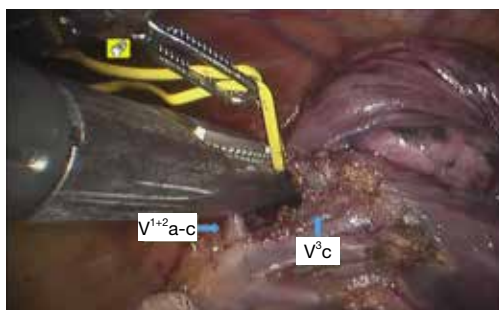


Figure 8 Pulmonary vein V¹⁺²a-c was skeletonized and cut with Echelon flex.

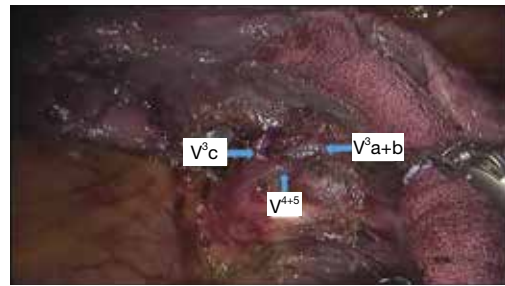


Figure 9 Vein V³c was skeletonized and ligated to cut.

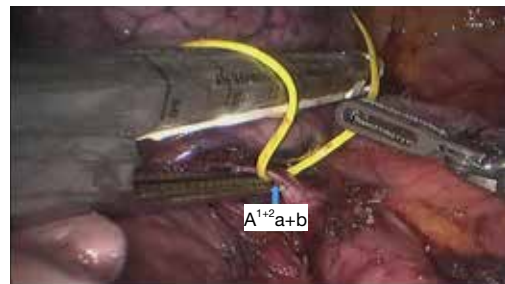


Figure 10 Pulmonary artery A¹⁺²a+b was skeletonized and cut with Echelon flex.

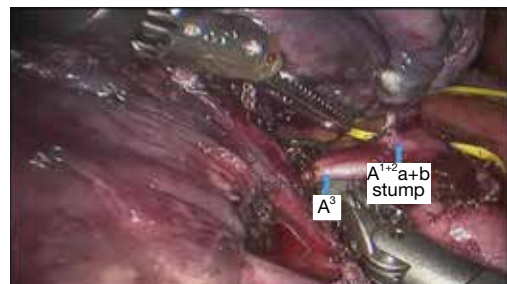


Figure 11 Artery A³ was skeletonized and dissociated.

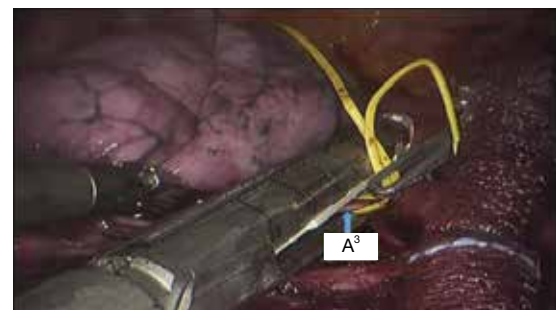


Figure 12 Artery A³ was cut with Echelon flex.

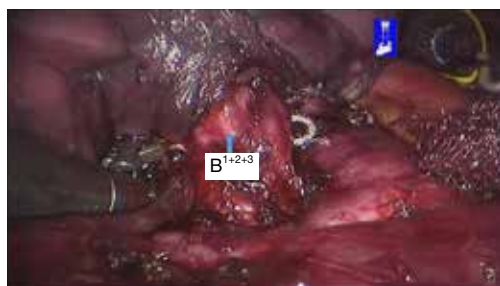


Figure 13 Bronchus B^{1+2+3} was dissected.

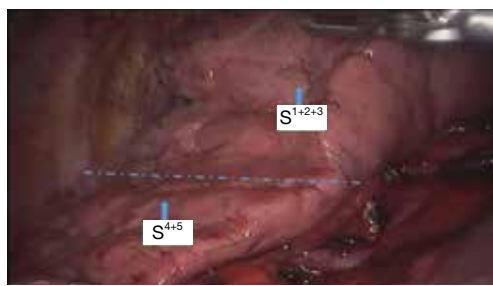


Figure 16 Ventilating the lung to expose intersegment plane.

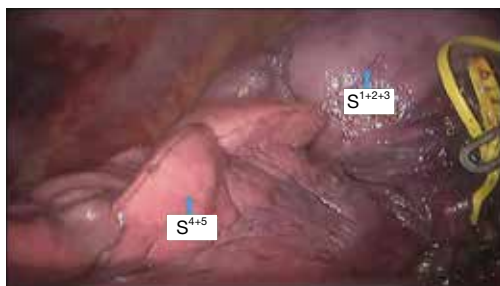

Figure 14 Bronchus B^{1+2+3} was clamped, and the lung was ventilated to expose the plane of the S^{1+2+3} segment.

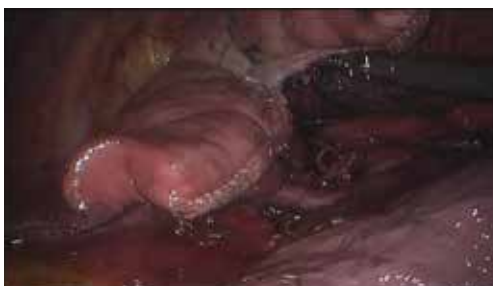

Figure 17 Segment S^{1+2+3} was cut along the intersegmental plane with the Echelon flex.

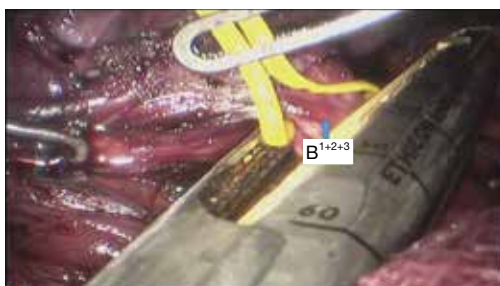


Figure 15 Bronchus B^{1+2+3} was cut with Echelon flex.

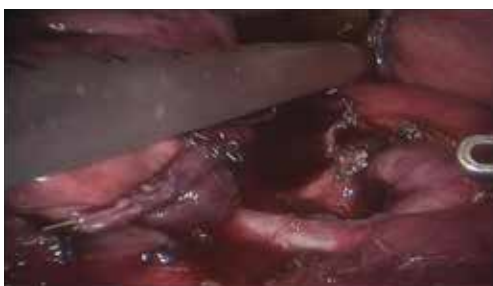

Figure 18 The lung was filled with water and checked for air leaks.

stapler easier compared with the thoracoscope. The #3 arm can help the surgeon to find the pulling location, which reduces the work of the assistant. In all surgeries, we dissect the hilum using a posterior approach and expose the pulmonary artery, which improves safety. We inject CO_2 before removing the specimen of lung lobe to form a closed space, which keeps the operation field clear (1-5).

Acknowledgements

None.

Footnote

Conflicts of Interest: The authors have no conflicts of interest to declare.

Informed Consent: Written informed consent was obtained from the patient for publication of this manuscript and any accompanying images.

References

1. Zhao X, Qian L, Lin H, et al. Robot-assisted lobectomy

- for non-small cell lung cancer in china: initial experience and techniques. *J Thorac Dis* 2010;2:26-28.
2. Augustin F, Bodner J, Wykypiel H, et al. Initial experience with robotic lung lobectomy: report of two different approaches. *Surg Endosc* 2011;25:108-113.
 3. Cao C, Manganas C, Ang SC, et al. A systematic review and meta-analysis on pulmonary resections by robotic video-assisted thoracic surgery. *Ann Cardiothorac Surg* 2012;1:3-10.
 4. Augustin F, Bodner J, Maier H, et al. Robotic-assisted minimally invasive vs. thoracoscopic lung lobectomy: comparison of perioperative results in a learning curve setting. *Langenbecks Arch Surg* 2013;398:895-901.
 5. Nakamura H.. Systematic review of published studies on safety and efficacy of thoracoscopic and robot-assisted lobectomy for lung cancer. *Ann Thorac Cardiovasc Surg* 2014;20:93-98.

doi: 10.21037/amj.2017.01.12

Cite this article as: Wu H, Yang S, Guo W, Jin R, Zhang Y, Chen X, Du H, Han D, Chen K, Xiang J, Li H. Ruijin robotic thoracic surgery: S¹⁺²⁺³ segmentectomy of the left upper lobe. *AME Med J* 2017;2:2.

Robotic-assisted thoracic surgery: a helpful tool or just another expensive gadget?

Florian Augustin¹, Johannes Bodner^{1,2}

¹Department of Visceral, Transplant and Thoracic Surgery, Center of Operative Medicine, Medical University of Innsbruck, Anichstrasse 35, 6020, Innsbruck, Austria; ²Department of Thoracic Surgery, Klinikum Bogenhausen, StKM, Munich, Germany

Correspondence to: Florian Augustin. Department of Visceral, Transplant and Thoracic Surgery, Center of Operative Medicine, Medical University of Innsbruck, Anichstrasse 35, 6020, Innsbruck, Austria. Email: florian.augustin@i-med.ac.at.

Provenance: This is an invited Editorial commissioned by Section Editor Jianfei Shen, MD (Department of Cardiothoracic Surgery, Taizhou Hospital of Zhejiang Province, Wenzhou Medical University, Taizhou, China).

Comment on: Wu H, Yang S, Guo W, *et al.* Ruijin robotic thoracic surgery: S¹⁺²⁺³ segmentectomy of the left upper lobe. *AME Med J* 2017;2:2.

Submitted Aug 05, 2017. Accepted for publication Aug 07, 2017.

doi: 10.21037/jtd.2017.08.85

View this article at: <http://dx.doi.org/10.21037/jtd.2017.08.85>

It is almost 20 years ago that the first useful surgical telemanipulator was introduced. Since that time, the surgical robot, as it was called ever since, has been applied to a large number of different procedures throughout surgical specialties ranging from thyroidectomy over mitral valve repair and colorectal resections to prostatectomy. A lot of case reports and case series on successful procedures have been published and yet, surgeons struggle to define robotic surgery's place in every day practice.

From a technical point of view, surgeons experience benefits due to high definition 3-dimensional vision, improved ergonomics and a tremor filter. But what was most striking in the beginning was the robot's improved maneuverability due to the EndoWrist[®] technology: an additional joint inside the patient's body allows for seven degrees of freedom and a hand-like mobility. This allows for perfect imitation of open surgery, even in small and confined space (1). Despite its advantages and even though technology has made constant progress over time, there is still no tactile feedback implemented in the currently available robotic systems, which has been criticized by many (mainly non-users, however).

Since its early days, we read publications reporting on the feasibility and safety of different thoracic procedures, including lobectomies and segmentectomies, thymectomies and resections of mediastinal tumors as well as esophageal resections and other complex thoracic procedures (1-4). In comparison to conventional open surgery, robotic-assisted

surgery achieves all advantages that we know and expect from every other minimally invasive approach, including less pain, shorter hospital stay and faster recovery (5).

But what about advantages compared to video-assisted thoracic surgery (VATS)? With respect to perioperative data, length of hospital stay is comparable (or maybe a little shorter for the robotic approach) (6,7) but operative time is longer in robotic-assisted cases (7,8). One reason for that may be the cumbersome and thus time-consuming set-up of the robotic system. Another reasonable explanation is the usually different levels of experience with many surgeons comparing their very first robotic cases with their advanced VATS results. Like in conventional VATS surgery the operative times decrease with increasing experience (2). Moreover, some reports even claim a faster learning curve for a robotic lobectomy (9). Also, the set-up time can be reduced with growing team-experience.

Postoperative morbidity and mortality are comparable between the two approaches with low mortality and acceptable morbidity (7). Reports exist on improved postoperative pain after robotic lobectomy (10).

In a recently published propensity matched analysis, there was no significant difference in 5-year overall survival between robotic and VATS lobectomy. However, 5-year disease free survival was superior in the robotic group; this was explained by an assumingly more accurate lymph node dissection with the robotic approach (11). Nodal upstaging, which was heavily discussed as a parameter for oncologic

accuracy in minimally invasive approaches during the last years, was found to be higher compared to conventional VATS in some institutional studies (12). A study analyzing a nationwide US-database, however, did not find any difference (7). So, conflicting data were on upstaging.

One might expect that the robotic system with its improved maneuverability might facilitate the—compared to a lobectomy—more delicate dissection of hilar structures in segmentectomies. As trends evolve towards parenchyma-sparing surgery, the robot seems to be an ideal tool to accomplish that goal. Robotic-assisted segmentectomy has been proven to be safe and feasible (13). However, so far no data have been shown proving any benefits over a conventional VATS approach.

Other ideal applications, where the robot's specific characteristics might be advantageous, are resections more complex than a simple lobectomy like bronchial or vascular sleeve resections. Again, the maneuverability of the EndoWrist® instruments might be helpful to accomplish anastomoses. There are some case reports and early series describing the technical details of such procedures (3,14). Again, profound data are missing however.

What is really consistent over all studies are the increased costs with a robotic approach (8,15). Higher acquisition costs, higher maintenance costs as well as higher costs for robotic instruments, draping and other disposable products account for an increase in costs of up to 50% compared to a VATS approach (depending on the method used to calculate expenditures). All authors analyzing costs for a robotic lobectomy raise concerns about the expenses that come with the technique and the possible impact on health care systems. As there is only limited proven benefit to date, the question remains whether these additional costs are justified. On the other hand, as more competition is anticipated in the market soon, everyone is expecting a decline in the costs.

So far, high-level evidence allowing for a profound appraisal of robotic-assisted surgery does still not exist. There is no single prospective randomized controlled trial showing any clear benefit of robotic over conventional minimally invasive thoracic surgery. Louie *et al.* suggested some reasons why surgeons would nevertheless feel motivated to initiate a robotic program (10): one is the urge to overcome the rather long learning curve in conventional VATS lobectomy; second, surgeons might expect to improve patients' operative outcome when applying the robot; and third, a robotic approach is often used as a marketing strategy to attract more patients. All of these reasons might

be true to a certain extent.

When the community of robotic surgeons thoroughly wants to define the current and increase the future role of the robot, it will be important to elaborate new and meaningful data. Just summarizing already existing data to so-called meta-analyses does not fulfill this requirement. What is of utmost importance is to increase and spread knowledge by educating fellow surgeons. One thing that was greatly achieved from the very beginning within the community of VATS surgeons was the willingness to share experience. As a consequence thousands of VATS thoracic surgeons today all follow one of only three to four major concepts on how to perform a VATS lobectomy (i.e., 3-port, 2-port, uniportal and totally endoscopic techniques); in contrast, the only few hundreds of robotic surgeons still are using myriad self-instructed techniques which vary considerably. This severely hinders multicentric studies and thus the elaboration of profound and reproducible data. The legitimate expectation and need of the community of dedicated minimally invasive thoracic surgeons is more technical standardization and tips and tricks for different anatomic resections. This will set the base for the clinical and consequently for the scientific future of robotic thoracic surgery and hopefully help to answer the question whether a robotic approach is worth the extra money that we are spending every time we switch it on.

May the articles summarizing the Ruijin experience contribute!

Acknowledgements

None.

Footnote

Conflicts of Interest: The authors have no conflicts of interest to declare.

References

1. Bodner J, Wykypiel H, Wetscher G, et al. First experiences with the da Vinci operating robot in thoracic surgery. *Eur J Cardiothorac Surg* 2004;25:844-851.
2. Augustin F, Bodner J, Wykypiel H, et al. Initial experience with robotic lung lobectomy: report of two different approaches. *Surg Endosc* 2011;25:108-113.
3. Schmid T, Augustin F, Kainz G, et al. Hybrid video-assisted thoracic surgery-robotic minimally invasive

- right upper lobe sleeve lobectomy. *Ann Thorac Surg* 2011;91:1961-1965.
4. Wu H, Yang S, Guo W, et al. Ruijin robotic thoracic surgery: S1+2+3 segmentectomy of the left upper lobe. *AME Med J* 2017;2:2.
 5. Dylewski MR, Ohaeto AC, Pereira JF. Pulmonary resection using a total endoscopic robotic video-assisted approach. *Semin Thorac Cardiovasc Surg* 2011;23:36-42.
 6. Yang CF, Sun Z, Speicher PJ, et al. Use and Outcomes of Minimally Invasive Lobectomy for Stage I Non-Small Cell Lung Cancer in the National Cancer Data Base. *Ann Thorac Surg* 2016;101:1037-1042.
 7. Louie BE, Wilson JL, Kim S, et al. Comparison of Video-Assisted Thoracoscopic Surgery and Robotic Approaches for Clinical Stage I and Stage II Non-Small Cell Lung Cancer Using The Society of Thoracic Surgeons Database. *Ann Thorac Surg* 2016;102:917-924.
 8. Augustin F, Bodner J, Maier H, et al. Robotic-assisted minimally invasive vs. thoracoscopic lung lobectomy: comparison of perioperative results in a learning curve setting. *Langenbecks Arch Surg* 2013;398:895-901.
 9. Veronesi G. Robotic surgery for the treatment of early-stage lung cancer. *Curr Opin Oncol* 2013;25:107-114.
 10. Louie BE, Farivar AS, Aye RW, et al. Early experience with robotic lung resection results in similar operative outcomes and morbidity when compared with matched video-assisted thoracoscopic surgery cases. *Ann Thorac Surg* 2012;93:1598-1604; discussion 1604-1605.
 11. Yang HX, Woo KM, Sima CS, et al. Long-term Survival Based on the Surgical Approach to Lobectomy For Clinical Stage I Nonsmall Cell Lung Cancer: Comparison of Robotic, Video-assisted Thoracic Surgery, and Thoracotomy Lobectomy. *Ann Surg* 2017;265:431-437.
 12. Wilson JL, Louie BE, Cerfolio RJ, et al. The prevalence of nodal upstaging during robotic lung resection in early stage non-small cell lung cancer. *Ann Thorac Surg* 2014;97:1901-6; discussion 1906-1907.
 13. Rinieri P, Peillon C, Salaün M, et al. Perioperative outcomes of video- and robot-assisted segmentectomies. *Asian Cardiovasc Thorac Ann* 2016;24:145-151.
 14. Lin MW, Kuo SW, Yang SM, et al. Robotic-assisted thoracoscopic sleeve lobectomy for locally advanced lung cancer. *J Thorac Dis* 2016;8:1747-1752.
 15. Deen SA, Wilson JL, Wilshire CL, et al. Defining the cost of care for lobectomy and segmentectomy: a comparison of open, video-assisted thoracoscopic, and robotic approaches. *Ann Thorac Surg* 2014;97:1000-1007.

Cite this article as: Augustin F, Bodner J. Robotic-assisted thoracic surgery: a helpful tool or just another expensive gadget? *J Thorac Dis* 2017;9(9):2881-2883. doi: 10.21037/jtd.2017.08.85

Robotic-assisted thoracic surgery: a promising tool should not be denied

Han Wu, Hecheng Li

Department of Thoracic Surgery, Ruijin Hospital, Shanghai Jiao Tong University School of Medicine, Shanghai 200025, China

Correspondence to: Hecheng Li. Department of Thoracic Surgery, Ruijin Hospital, Shanghai Jiao Tong University School of Medicine, 197 Ruijin 2nd Road, Shanghai 200025, China. Email: lihecheng2000@hotmail.com.

Provenance: This is an invited article commissioned by Section Editor Jianfei Shen, MD (Department of Cardiothoracic Surgery, Taizhou Hospital of Zhejiang Province, Wenzhou Medical University, Taizhou, China).

Response to: Augustin F, Bodner J. Robotic-assisted thoracic surgery: a helpful tool or just another expensive gadget? J Thorac Dis 2017;9:2881-3.

Submitted Sep 29, 2017. Accepted for publication Oct 10, 2017.

doi: 10.21037/jtd.2017.10.68

View this article at: <http://dx.doi.org/10.21037/jtd.2017.10.68>

We are grateful for the reviewers' comments on our manuscript (1). A robotic system has been used in thoracic surgery for more than 10 years, and the technique has matured and become common practice in many institutions.

Many studies have demonstrated the feasibility and safety of the robotic system and have shown that it can achieve equivalent short-term surgical efficacy when compared with traditional video-assisted thoracic surgery, but a higher cost is associated with robotic surgery (2-4). The high cost is due to the additional expenses of the disposable robotic instruments and the substantial overall cost to acquire and maintain the robotic system. Some studies have shown that robotic surgery decreases a portion of overall costs as hospital stay length and overall nursing care costs are reduced. Because the robotic technique continues to evolve and expand, manufacturers of robotic surgical systems will continue to develop new generations of robotic systems to reduce costs and remain competitive (4-8).

Currently, comprehensive evaluations of robotic techniques must be performed to achieve maximal benefits for potential patients. We should not abandon this promising technique due to the temporary costs associated with it. The future of robotic surgery is bright.

Acknowledgements

We would like to acknowledge David Tian, Senior Editor of AME Publishing Company, for editing support.

Footnote

Conflicts of Interest: The authors have no conflicts of interest to declare.

References

1. Augustin F, Bodner J. Robotic-assisted thoracic surgery: a helpful tool or just another expensive gadget? J Thorac Dis 2017;9:2881-2883.
2. Wei S, Chen M, Chen N, et al. Feasibility and safety of robot-assisted thoracic surgery for lung lobectomy in patients with non-small cell lung cancer: a systematic review and meta-analysis. World J Surg Oncol 2017;15:98.
3. Liang H, Liang W, Zhao L, et al. Robotic Versus Video-assisted Lobectomy/Segmentectomy for Lung Cancer: A Meta-analysis. Ann Surg 2017. [Epub ahead of print].
4. Park BJ, Flores RM. Cost comparison of robotic, video-assisted thoracic surgery and thoracotomy approaches to pulmonary lobectomy. Thorac Surg Clin 2008;18:297-300.
5. Augustin F, Bodner J, Maier H, et al. Robotic-assisted minimally invasive vs. thoracoscopic lung lobectomy: comparison of perioperative results in a learning curve setting. Langenbecks Arch Surg 2013;398:895-901.
6. Dylewski MR, Lazzaro RS. Robotics - The answer to the Achilles' heel of VATS pulmonary resection. Chin J Cancer Res 2012;24:259-260.
7. Deen SA, Wilson JL, Wilshire CL, et al. Defining the cost

of care for lobectomy and segmentectomy: a comparison of open, video-assisted thoracoscopic, and robotic approaches. *Ann Thorac Surg* 2014;97:1000-1007.

8. Wei B, D'Amico TA. Thoracoscopic versus robotic approaches: advantages and disadvantages. *Thorac Surg Clin* 2014;24:177-188.

Cite this article as: Wu H, Li H. Robotic-assisted thoracic surgery: a promising tool should not be denied. *J Thorac Dis* 2017;9(10):E971-E972. doi: 10.21037/jtd.2017.10.68

Robotic thoracic surgery: S¹⁺² segmentectomy of left upper lobe

Hailei Du, Su Yang, Wei Guo, Runsen Jin, Yajie Zhang, Xingshi Chen, Han Wu, Dingpei Han, Kai Chen, Jie Xiang, Hecheng Li

Department of Thoracic Surgery, Ruijin Hospital, Shanghai Jiao Tong University, School of Medicine, Shanghai 200025, China

Correspondence to: Hecheng Li, MD, PhD. Department of Thoracic Surgery, Ruijin Hospital, Shanghai Jiao Tong University, School of Medicine, 197 Ruijin Er Road, Shanghai 200025, China. Email: lihecheng2000@hotmail.com.

Abstract: We are going to share the experience of robotic surgery for lung segmentectomy. A 50-year-old patient underwent robotic-assisted thoracoscopic surgery for a ground glass opacity (GGO) in the S¹⁺² segment of left upper lobe. The patient was discharged on postoperative day 3 without any perioperative complications. The pathological stage was T1aN0M0 (stage IA). Our result showed the robotic approach was feasible and reliable for lung segmentectomy.

Keywords: Robotic-assisted thoracoscopic surgery; segmentectomy

Received: 02 December 2016; Accepted: 27 December 2016; Published: 21 January 2017.

doi: 10.21037/amj.2017.01.13

View this article at: <http://dx.doi.org/10.21037/amj.2017.01.13>

Clinical data

A 50-year-old woman was found to have a pulmonary nodule for 4 years detected by computed tomography (CT), Chest CT (*Figure 1*) showed ground glass opacity (GGO) in the S¹⁺² segment of left upper lobe. The lesion size increased from 5 to 8 mm during follow-up. The patient's did not have any clinical syndrome and her cardiopulmonary function, blood gas analysis and laboratory tests were normal. There was no positive sign or supraclavicular lymph node enlargement on physical examination. She has no medical history.

Operation steps

Anesthesia and body position

The patient received general anesthesia by double-lumen endotracheal intubation and was placed in the lateral decubitus position and in a jackknife position, with single-lung (right) ventilation (1) (*Figure 2*).

Ports

A 1.5-cm camera port (for a 12-mm trocar) was created in

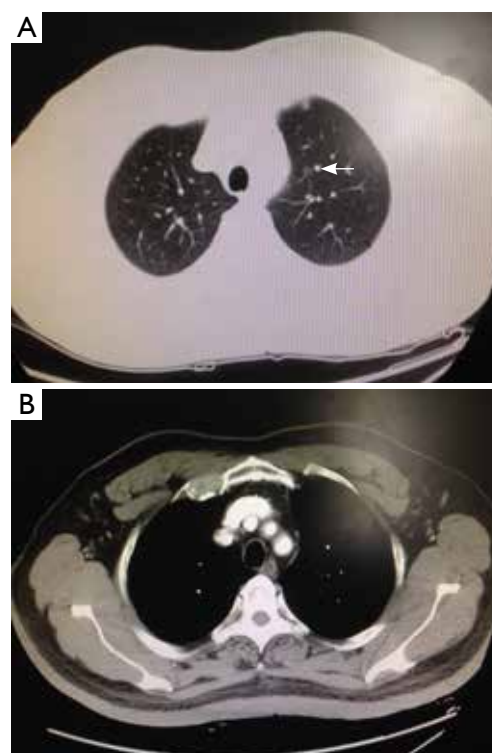


Figure 1 Preoperative CT showed GGO in the S¹⁺² segment of left upper lobe. GGO, ground glass opacity.

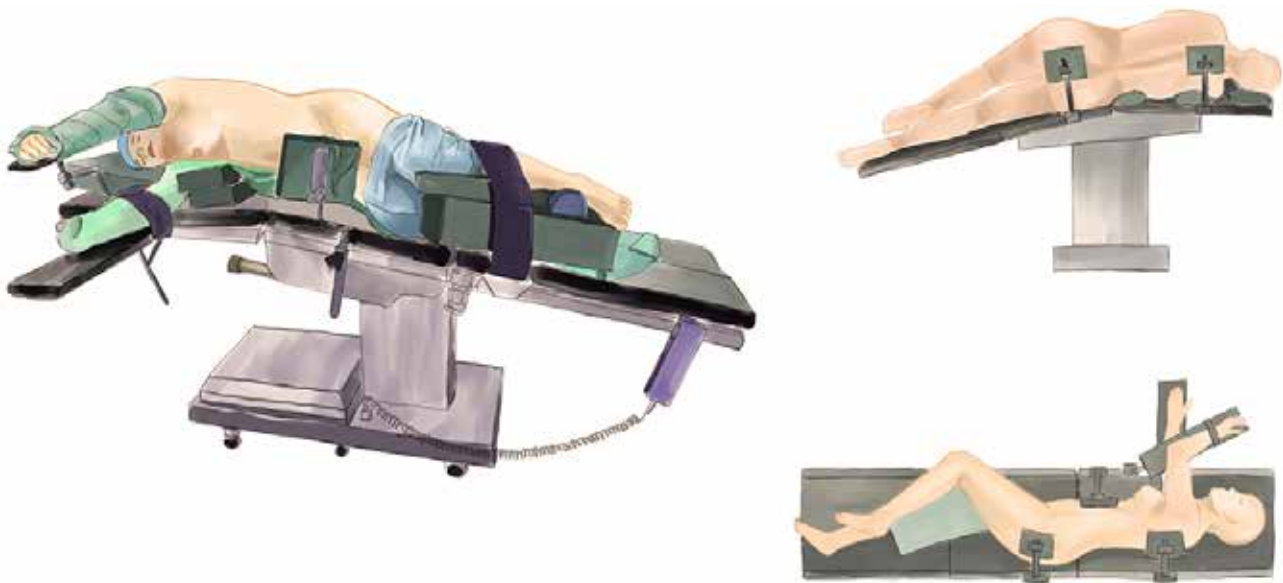


Figure 2 Jackknife position.

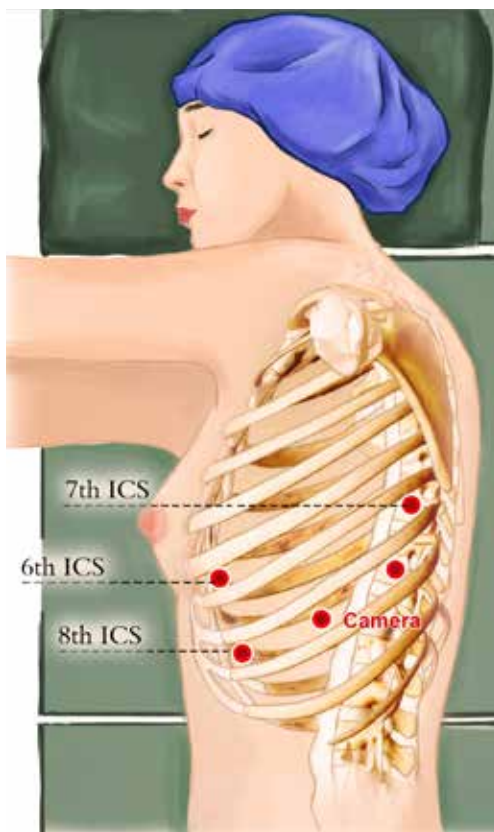


Figure 3 Ports in the 6th, 7th, and 8th ICS. ICS, intercostal space.

the 8th intercostal space (ICS) at the left mid axillary line, and three separate 1.0-cm working ports (for 8-mm trocars) were made in the 6th ICS (#1 arm) at the left anterior axillary line, the 7th ICS (#2 arm) at the left posterior axillary line, and the left 8th ICS (#3 arm), 2 cm from the spine. An auxiliary port (for a 12-mm trocar) was made in the 8th ICS near the costal arch (2) (*Figure 3*).

Installation of the operation arms

The robot Patient Cart is positioned directly above the operating table and then connected. The 2# arm was connected with bipolar cautery grab and the 1# arm was connected with a unipolar cautery hook (3).

Surgical procedure

See *Figures 4-18*.

Postoperative condition

Postoperative treatments included anti-inflammatory and phlegm-resolving treatment. The thoracic drainage tube was withdrawn 2 days after surgery, and the patient was discharged 3 days after surgery. No complications were

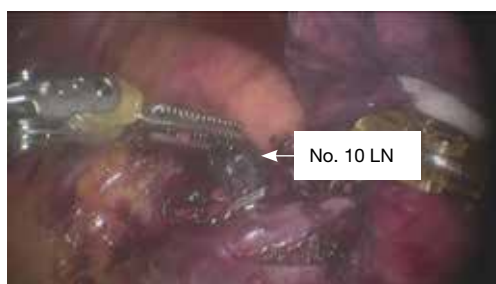

Figure 4 The pleura of hilum was opened, and the lymph nodes (No. 10) were removed.

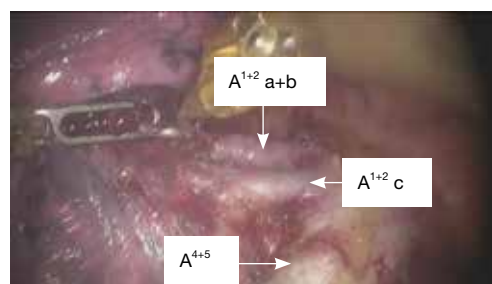


Figure 8 The branches of A¹⁺² and A⁴⁺⁵ were exposed.

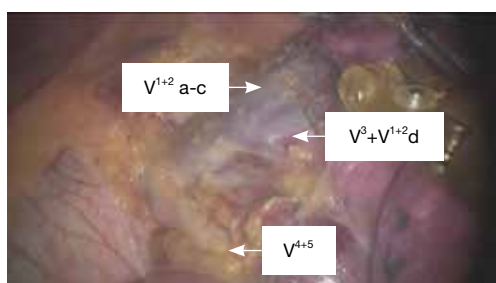


Figure 5 The branches of the left upper lobe pulmonary vein were exposed.




Figure 9 The A¹⁺² c were skeletonized, pulled using elastic cuffs, and cut by Endo GIA.

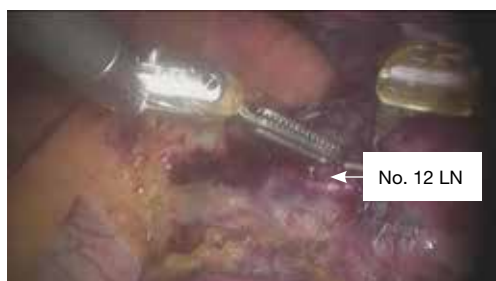

Figure 6 The lymph nodes (No. 12) were removed.

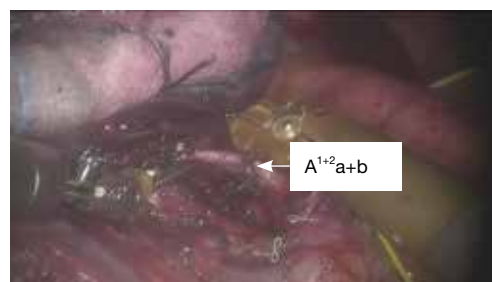


Figure 10 The A¹⁺² a+b were skeletonized and cut by Endo GIA.

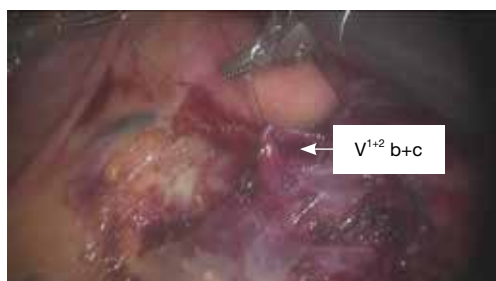

Figure 7 V¹⁺² b+c was skeletonized and cut off after ligation.

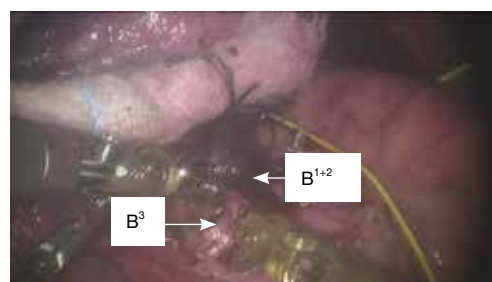


Figure 11 B¹⁺² and B³ were dissected.

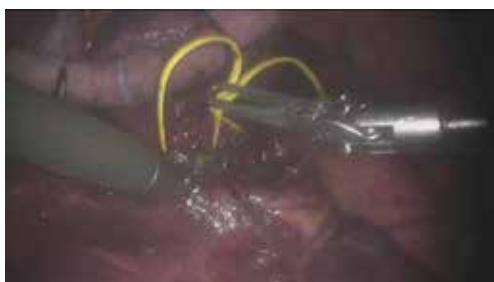

Figure 12 B¹⁺² were clamped, and the lung was ventilated to expose the plane of the proper segment.

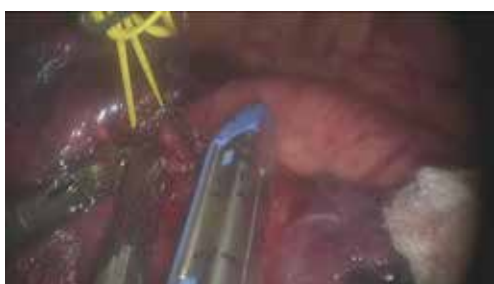


Figure 13 B¹⁺² was clamped and divided using Endo GIA.

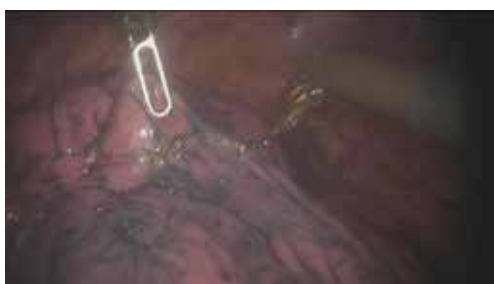

Figure 14 Ventilating the lung and expose intersegment plane, cut it using Endo GIA.

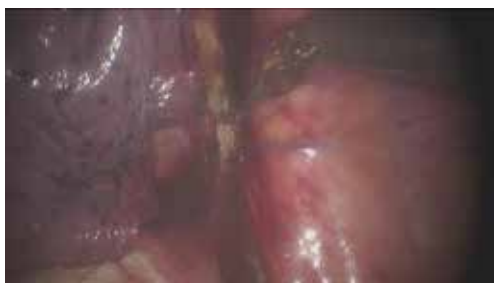

Figure 15 Lymph nodes (No. 9) in the inferior pulmonary ligament were removed.

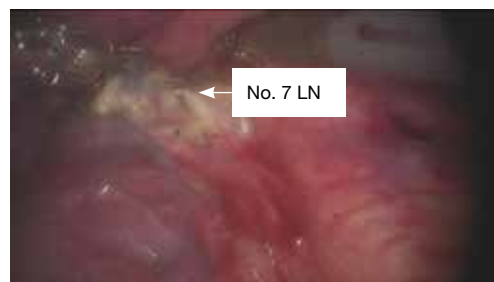

Figure 16 The subcarinal lymph node (No.7) was removed.

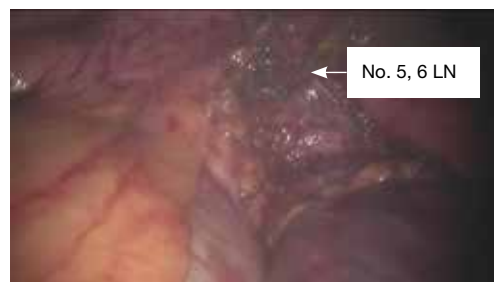


Figure 17 Lymph nodes (No. 5, No. 6) were removed.

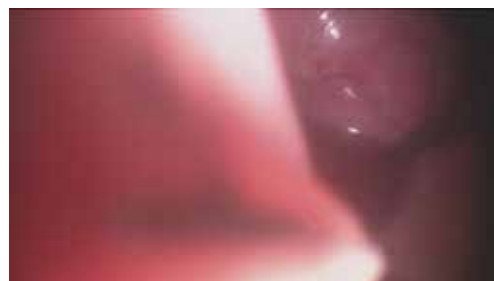

Figure 18 The lung was filled with water and checked for air leak. Then the chest was closed after a chest drainage tube was placed in the camera port.

observed during hospitalization. Pathologic diagnosis was microinvasive adenocarcinoma 0.8 cm in the apex posterior segment of the left upper pulmonary lobe. No metastasis was seen at the bronchial stump or in the sampled lymph nodes. The postoperational pathologic stage was pT1aN0M0 (IA stage).

Acknowledgements

None.

Footnote

Conflicts of Interest: The authors have no conflicts of interest to declare.

Informed Consent: Written informed consent was obtained from the patient for publication of this manuscript and any accompanying images.

doi: 10.21037/amj.2017.01.13

Cite this article as: Du H, Yang S, Guo W, Jin R, Zhang Y, Chen X, Wu H, Han D, Chen K, Xiang J, Li H. Robotic thoracic surgery: S¹⁺² segmentectomy of left upper lobe. AME Med J 2017;2:7.

References

1. Nomori H, Okada M. Illustrated Anatomical Segmentectomy for Lung Cancer. Tokyo: Springer, 2011.
2. Wang S. The Robotic Thoracic Surgery. China: AME Publishing Company, 2015.
3. Liu J, Lu W, Zhou X. Video-assisted thoracic surgery left S¹⁺²⁺³ segmentectomy for lung cancer. J Thorac Dis 2014;6:1837-1839.

Robotic-assisted thoracoscopic surgery: state of the art and future perspectives

Gregor J. Kocher

Division of General Thoracic Surgery, Bern University Hospital, University of Bern, Bern, Switzerland

Correspondence to: Gregor J. Kocher, MD. Division of General Thoracic Surgery, University Hospital Bern, CH – 3010 Bern, Switzerland.

Email: gregor.kocher@insel.ch.

Provenance: This is an invited Editorial commissioned by Section Editor, Jianfei Shen, MD (Taizhou Hospital of Zhejiang Province, Wenzhou Medical University, Wenzhou, China).

Comment on: Du H, Yang S, Guo W, *et al.* Robotic thoracic surgery: S¹⁺² segmentectomy of left upper lobe. AME Med J 2017;2:7.

Submitted Jun 14, 2017. Accepted for publication Jun 19, 2017.

doi: 10.21037/jtd.2017.06.139

View this article at: <http://dx.doi.org/10.21037/jtd.2017.06.139>

Background and state of the art

With interest I read the article of Du and co-authors (1), describing their meticulous technique for robotic lung segmentectomy. Robot-assisted thoracic surgery (RATS) has come a long way, with the first robotic lung resections being reported in 2002 by Melfi *et al.* (2). Since then, various different approaches for lung resection have been described using the da Vinci Surgical System (Intuitive Surgical Inc., Sunnyvale, CA, USA) by thoracic surgeons all over the world (3-7).

Despite the obvious advantages of robotics, such as 3D vision, increased dexterity and improved ergonomics for the operating surgeon, the robotic approach has not at all advanced to the gold standard for anatomic lung resection so far. An analysis of the U.S. National Cancer Data Base showed that the percentage of robotic lobectomies increased from 3% in 2010 up to 9% in 2012 (8). A more recent market analysis that has been conducted in the U.S. by the end of 2015, showed that already around 15% of lobectomies were performed by RATS. Although robotic lung resections are increasingly performed, one of the main factors still impeding a more wide-spread use of the robotic technique is without a doubt the increased overall costs, at least when compared to VATS approaches (9-12). Another concern which is an ongoing point of discussion among surgeons is the safety of the surgical procedure, since the main operating surgeon is not present at the operating table itself. While some authors observed an increased risk of bleeding during RATS (when compared to VATS)

with consecutive conversion (11,13), this was not observed neither by us, nor others, when appropriate measures were taken in order to prevent or properly manage intraoperative complications with the robot (14,15).

In summary it can be stated that to the present day, as demonstrated by the two largest available systematic literature analyses (16,17), RATS comes with an increased cost but does not seem to offer any advantages compared to VATS in terms of complications (intraoperative as well as postoperative), postoperative pain, hospital stay and oncological outcome for early-stage lung cancer.

More than that, the invasiveness of the surgical approach has been further challenged by the introduction of the single-incision VATS approach, reducing chest wall trauma to only one small single incision. This ‘uniportal’ approach is spreading rapidly all over the world and evidence is growing that this approach results in equivalent or even improved patient outcomes compared to multiport minimally invasive approaches (18). As a consequence, also Intuitive Surgical has made corresponding efforts and has developed software that allows Single-SiteTM Instrumentation (Introduction of the camera and two instruments in a crosswise manner through the same incision) compatible with the SiTM Surgical System in 2011. During the following years finally a ‘real’ single port platform has been developed and was approved by the FDA in 2014 in form of the da Vinci Sp Single Port Robotic Surgical System, compatible with the latest da Vinci XiTM robot. Nevertheless, technical limitations including suitable

instruments and the relatively large and rigid trocar with a diameter of 2.5 cm will most likely prevent the device from being used for thoracic surgical procedures.

A more important feature, which was introduced by Intuitive also in 2011, is an integrated near infrared fluorescence imaging system, which is capable of detecting infrared light reflected by indocyanine green (ICG). After intravenous injection, ICG distributes within seconds to minutes (maximum concentration in the lung after around 1 min) through the pulmonary arteries and can thus be helpful in the identification of the intersegmental plane during segmentectomy after ligation of the segments' arterial blood supply (19).

Future perspectives

More than 5 years ago, Intuitive in collaboration with Mimic®, released a dedicated Skills Simulator which allows surgeons to train their skills on the robotic console and get familiar with all the existing features the robotic platform has to offer. Furthermore recently Mimic released different Maestro AR™ (Augmented Reality) Modules, which even enable surgeons to train specific surgical procedures on the console and interact with anatomical regions within augmented 3D surgical video footage (available modules: Partial Nephrectomy, Hysterectomy, Inguinal Hernia Repair and Prostatectomy). In the near future hopefully also thoracic surgical procedure modules will be available in order to help improve the quality of the robotic surgical training for thoracic surgeons. But what we are really hoping and waiting for is the possibility to integrate patient data (i.e., preoperative CT-scan) into these simulations, in order to allow us to train a specific procedure on the console before even touching the patient. Furthermore, especially for more complex procedures such as anatomical segmentectomies, another future perspective is the creation of an augmented reality in which the anatomical structures (i.e., segmental artery, bronchus and vein) can be superimposed onto the real-time 3D image during the surgical procedure. Both aforementioned options would not only allow us to be perfectly prepared for any surgical procedure thanks to realistic training before surgery, but also would enable us to possibly anticipate and avoid intraoperative complications as the operating surgeon is fully aware of the given anatomy at any point of the surgical procedure.

All of the possible developments discussed above are mainly based on the already existing and/or possible

developments of Intuitive and collaborators, but one also has to consider other companies that are soon entering the market with their innovative robotic platforms (i.e., Senhance™ by TransEnterix, Inc.—with a similar Master and Slave design as the da Vinci platform). Furthermore Johnson & Johnson and Google announced in 2015 that they would be working on the development of a robotic platform which might be released in the near future. These new developments will hopefully not only reduce the cost of robotic surgery in general, in order to allow a more widespread use of this advanced technology, but also introduce new advanced features such as for example improved instruments, tactile feedback, “enhanced” reality and many more.

Bottom line

At the present time prospective multicenter randomized trials are needed in order to investigate for which kind of resections (segment and/or lobe) and for which tumor stages there are advantages of RATS over VATS, which could possibly justify the actual higher cost. Furthermore realistic simulations of thoracic surgical procedures are soon to become reality, which is an important step in the development of robotic thoracic surgical training programs. Further improvements in preoperative simulations with the integration of patient data combined with the availability of an augmented reality for specific ‘tailored’ operations could finally boost robotic surgery to the next level. However, one of the prerequisites for a more widespread use of this technology will be a markedly improved cost-effectiveness, which will hopefully evolve shortly not least because of a more vivid competition between the companies that manufacture robotic surgical platforms.

Acknowledgements

None.

Footnote

Conflicts of Interest: The author has no conflicts of interest to declare.

References

1. Du H, Yang S, Guo W, et al. Robotic thoracic surgery: S¹⁺² segmentectomy of left upper lobe. *AME Med J* 2017;2:7.

2. Melfi FM, Menconi GF, Mariani AM, et al. Early experience with robotic technology for thoracoscopic surgery. *Eur J Cardiothorac Surg* 2002;21:864-868.
3. Park BJ, Flores RM, Rusch VW. Robotic assistance for video-assisted thoracic surgical lobectomy: technique and initial results. *J Thorac Cardiovasc Surg* 2006;131:54-59.
4. Veronesi G, Galetta D, Maisonneuve P, et al. Four-arm robotic lobectomy for the treatment of early-stage lung cancer. *J Thorac Cardiovasc Surg* 2010;140:19-25.
5. Cerfolio RJ, Bryant AS, Skylizard L, et al. Initial consecutive experience of completely portal robotic pulmonary resection with 4 arms. *J Thorac Cardiovasc Surg* 2011;142:740-746.
6. Dylewski MR, Ohaeto AC, Pereira JF. Pulmonary resection using a total endoscopic robotic video-assisted approach. *Semin Thorac Cardiovasc Surg* 2011;23:36-42.
7. Gharagozloo F, Margolis M, Tempesta B, et al. Robot-assisted lobectomy for early-stage lung cancer: report of 100 consecutive cases. *Ann Thorac Surg* 2009;88:380-384.
8. Rajaram R, Mohanty S, Bentrem DJ, et al. Nationwide Assessment of Robotic Lobectomy for Non-Small Cell Lung Cancer. *Ann Thorac Surg* 2017;103:1092-1100.
9. Park BJ, Flores RM. Cost comparison of robotic, video-assisted thoracic surgery and thoracotomy approaches to pulmonary lobectomy. *Thorac Surg Clin* 2008;18:297-300. vii.
10. Swanson SJ, Miller DL, McKenna RJ Jr, et al. Comparing robot-assisted thoracic surgical lobectomy with conventional video-assisted thoracic surgical lobectomy and wedge resection: results from a multihospital database (Premier). *J Thorac Cardiovasc Surg* 2014;147:929-937.
11. Paul S, Jalbert J, Isaacs AJ, et al. Comparative effectiveness of robotic-assisted vs thoracoscopic lobectomy. *Chest* 2014;146:1505-1512.
12. Deen SA, Wilson JL, Wilshire CL, et al. Defining the cost of care for lobectomy and segmentectomy: a comparison of open, video-assisted thoracoscopic, and robotic approaches. *Ann Thorac Surg* 2014;97:1000-1007.
13. Augustin F, Bodner J, Maier H, et al. Robotic-assisted minimally invasive vs. thoracoscopic lung lobectomy: comparison of perioperative results in a learning curve setting. *Langenbecks Arch Surg* 2013;398:895-901.
14. Kocher GJ, Schmid RA, Melfi FM. Robotic lobectomy: tips, pitfalls and troubleshooting. *Eur J Cardiothorac Surg* 2014;46:e136-e138.
15. Cerfolio RJ, Bess KM, Wei B, et al. Incidence, Results, and Our Current Intraoperative Technique to Control Major Vascular Injuries During Minimally Invasive Robotic Thoracic Surgery. *Ann Thorac Surg* 2016;102:394-399.
16. Cao C, Manganas C, Ang SC, et al. A systematic review and meta-analysis on pulmonary resections by robotic video-assisted thoracic surgery. *Ann Cardiothorac Surg* 2012;1:3-10.
17. Agzarian J, Fahim C, Shargall Y, et al. The Use of Robotic-Assisted Thoracic Surgery for Lung Resection: A Comprehensive Systematic Review. *Semin Thorac Cardiovasc Surg* 2016;28:182-192.
18. Harris CG, James RS, Tian DH, et al. Systematic review and meta-analysis of uniportal versus multiportal video-assisted thoracoscopic lobectomy for lung cancer. *Ann Cardiothorac Surg* 2016;5:76-84.
19. Pardolesi A, Veronesi G, Solli P, et al. Use of indocyanine green to facilitate intersegmental plane identification during robotic anatomic segmentectomy. *J Thorac Cardiovasc Surg* 2014;148:737-738.

Cite this article as: Kocher GJ. Robotic-assisted thoracoscopic surgery: state of the art and future perspectives. *J Thorac Dis* 2017;9(7):1855-1857. doi: 10.21037/jtd.2017.06.139

Robotic thoracic surgery: S¹⁺² segmentectomy of the left upper lobe: advantages of robotic assisted thoracic surgery

Hailei Du, Hecheng Li

Department of Thoracic Surgery, Ruijin Hospital, Shanghai Jiao Tong University, School of Medicine, Shanghai 200025, China

Correspondence to: Professor Hecheng Li. Department of Thoracic Surgery, Ruijin Hospital, Shanghai Jiao Tong University, School of Medicine, 197 Ruijin 2nd Road, Shanghai 200025, China. Email: lihecheng2000@hotmail.com.

Provenance: This is an invited article commissioned by the Section Editor Jianfei Shen, MD (Department of Cardiothoracic Surgery, Taizhou Hospital of Zhejiang Province, Wenzhou Medical University, Taizhou, China).

Response to: Kocher GJ. Robotic-assisted thoracoscopic surgery: state of the art and future perspectives. J Thorac Dis 2017;9:1855-7.

Submitted Sep 25, 2017. Accepted for publication Oct 13, 2017.

doi: 10.21037/jtd.2017.10.80

View this article at: <http://dx.doi.org/10.21037/jtd.2017.10.80>

We are grateful for the reviewers' comments on our manuscript entitled "Robotic thoracic surgery: S¹⁺² segmentectomy of the left upper lobe" (1). An advantage of robotic assisted thoracic surgery (RATS) is that the robotic arms are flexible and allow the surgeon to move instruments freely inside the chest cavity as needed without geometric limitations. Compared with single-incision video-assisted thoracic surgery (VATS), the flexibility is one of the primary advantages of robotic surgery. Although the literature revealed that RATS does not seem to offer any advantages over VATS with regards to complications, postoperative pain, hospital stay, and oncological outcome for early-stage lung cancer (2,3), the benefit of RATS is that the surgeon feels more comfortable and confident when performing RATS.

Prospective multicenter randomized trials are needed to determine the most appropriate instances to utilize RATS. To improve the quality of the robotic surgical training for thoracic surgeons, more advanced thoracic surgical procedure modules must be available in the near future. As the cost goes down, RATS is expected to be used widely in the future.

Acknowledgements

We would like to acknowledge David Tian, Senior Editor of AME Publishing Company, for editing support.

Footnote

Conflicts of Interest: The authors have no conflicts of interest to declare.

References

1. Kocher GJ. Robotic-assisted thoracoscopic surgery: state of the art and future perspectives. J Thorac Dis 2017;9:1855-1857.
2. Cao C, Manganas C, Ang SC, et al. A systematic review and meta-analysis on pulmonary resections by robotic video-assisted thoracic surgery. Ann Cardiothorac Surg 2012;1:3-10.
3. Agzarian J, Fahim C, Shargall Y, et al. The Use of Robotic-Assisted Thoracic Surgery for Lung Resection: A Comprehensive Systematic Review. Semin Thorac Cardiovasc Surg 2016;28:182-192.

Cite this article as: Du H, Li H. Robotic thoracic surgery: S¹⁺² segmentectomy of the left upper lobe: advantage of robotic assisted thoracic surgery. J Thorac Dis 2017;9(10):E973. doi: 10.21037/jtd.2017.10.80

Robotic segmentectomy: far beyond choice

Suat Erus, Serhan Tanju

Department of Thoracic Surgery, Koç University School of Medicine, Istanbul, Turkey

Correspondence to: Suat Erus. Department of Thoracic Surgery, Koç University School of Medicine, Istanbul, Turkey. Email: suaterus@gmail.com.

Provenance: This is an invited Editorial commissioned by Section Editor of *JTD*, Jianfei Shen, MD (Department of Cardiothoracic Surgery, Taizhou Hospital of Zhejiang Province, Wenzhou Medical University, Taizhou, China).

Comment on: Du H, Yang S, Guo W, *et al.* Robotic thoracic surgery: S¹⁺² segmentectomy of left upper lobe. *AME Med J* 2017;2:7.

Submitted Jul 20, 2017. Accepted for publication Jul 27, 2017.

doi: 10.21037/jtd.2017.08.32

View this article at: <http://dx.doi.org/10.21037/jtd.2017.08.32>

With the progress of the technology, video-assisted surgeries have been developed in thoracic surgery as well as the other branches. With the widespread use in the 2000's, robotic surgical systems had also found a place within the field of thoracic surgery. First in benign diseases and then in parallel with the increasing experience, it started to be used in cancer surgery which requires more technical skill. It was shown in various articles that it can be used in a wide area from wedge resections to pneumonectomy.

Lung segmentectomies are used for long years in the treatment for benign lung lesion requiring surgery. Also, some authors prefer lung segmentectomies for tumors smaller than 2 cm and without lymph nodes involvement and for larger tumors in patients with limited pulmonary function. With the development of video-assisted thoracic surgery, VATS segmentectomy has been proved to be a safer procedure than open segmentectomy in terms of complications and hospital stay (1). Also, there is another study claims that the peri-operative outcome has been shown to be similar (2). This study also demonstrated that VATS segmentectomy is feasible in terms of oncological outcomes for stage IA non-small cell lung cancer (NSCLC), especially T1a and carefully selected T1b (2). Thoracoscopic segmentectomy has been compared to thoracoscopic lobectomy when analyzing oncologic results in small (≤ 2 cm) peripheral stage IA NSCLC (3). Local recurrence rates with thoracoscopic segmentectomy (5.1%) have been reported to be similar to the thoracoscopic lobectomy (4.9%). No significant difference has been observed in 5-year overall or disease free survival (3). Some studies also demonstrated that uniportal and total

thoracoscopic segmentectomies are safer alternatives for VATS segmentectomies (4,5). Minimally invasive methods will be even more needed as small nodules are more likely to be found. Certainly, robotic lung segmentectomies might be another safe and minimally invasive option for pulmonary segmentectomies. Growing knowledge of robotic anatomic lung resection for early stage lung cancer would provide additional experience for performing segmentectomy for lung cancer. The major difficulty in robotic operations is the resection without palpation. This could be overcome by palpating and marking the lesion prior to the docking of the robotic arms. Lung segmentectomies with robotic surgery requires an adequate knowledge of the pulmonary anatomy for each patient (6). It has been reported that preoperative planning based on patient's actual 3D pulmonary model was useful for patients with stage IA NSCLC ≤ 2 cm in diameter and for selecting an appropriate VATS lung resection for an individual (7). Apparently, this may be a required preoperative technique in robotic segmentectomy as well. Robotic segmentectomy may provide better dissection capabilities than conventional thoracoscopic surgery around smaller vessels and the lymph nodes around lobar and segmentary bronchi. However, developing these techniques may require preparation and patience to overcome the difficulties of a correct docking, developing dissection techniques. Yet, the provided data and results about performing robotic segmentectomies may not fully satisfy the thoracic surgical community. However, the robotic anatomic lung segmentectomy is a feasible and safe procedure with an acceptable operating time, adequate lymph node dissection, less pain and few complications.

Acknowledgements

None.

Footnote

Conflicts of Interest: The authors have no conflicts of interest to declare.

References

1. Leshnower BG, Miller DL, Fernandez FG, et al. Video-assisted thoracoscopic surgery segmentectomy: a safe and effective procedure. *Ann Thorac Surg* 2010;89:1571-1576.
2. Yamashita S, Tokuishi K, Anami K, et al. Thoracoscopic segmentectomy for T1 classification of non-small cell lung cancer: a single center experience. *Eur J Cardiothorac Surg* 2012;42:83-88.
3. Zhong C, Fang W, Mao T, et al. Comparison of thoracoscopic segmentectomy and thoracoscopic lobectomy for small-sized stage IA lung cancer. *Ann Thorac Surg* 2012;94:362-367.
4. Gonzalez-Rivas D, Fieira E, Mendez L, et al. Single-port video-assisted thoracoscopic anatomic segmentectomy and right upper lobectomy. *Eur J Cardiothorac Surg* 2012;42:e169-e171.
5. Ramos R, Girard P, Masuet C, et al. Mediastinal lymph node dissection in early-stage non-small cell lung cancer: totally thoracoscopic vs thoracotomy. *Eur J Cardiothorac Surg* 2012;41:1342-1348; discussion 1348.
6. Ikeda N, Yoshimura A, Hagiwara M, et al. Three dimensional computed tomography lung modeling is useful in simulation and navigation of lung cancer surgery. *Ann Thorac Cardiovasc Surg* 2013;19:1-5.
7. Kanzaki M, Kikkawa T, Shimizu T, et al. Presurgical planning using a three-dimensional pulmonary model of the actual anatomy of patient with primary lung cancer. *Thorac Cardiovasc Surg* 2013;61:144-150.

Cite this article as: Erus S, Tanju S. Robotic segmentectomy: far beyond choice. *J Thorac Dis* 2017;9(8):2317-2318. doi: 10.21037/jtd.2017.08.32

Ruijin robotic thoracic surgery: robot-assisted Ivor Lewis esophagectomy

Yajie Zhang, Su Yang, Wei Guo, Runsen Jin, Xingshi Chen, Han Wu, Hailei Du, Dingpei Han, Kai Chen, Jie Xiang, Hecheng Li

Department of Thoracic Surgery, Ruijin Hospital, Shanghai Jiao Tong University, School of Medicine, Shanghai 200025, China

Correspondence to: Hecheng Li, MD, PhD. Department of Thoracic Surgery, Ruijin Hospital, Shanghai Jiao Tong University, School of Medicine, 197 Ruijin Er Road, Shanghai 200025, China. Email: lihecheng2000@hotmail.com.

Abstract: We are going to share the experience of robotic surgery for esophageal carcinoma. A 51-year-old patient who has esophageal squamous cell carcinoma underwent robot-assisted Ivor-Lewis esophagectomy in our center. The patient was discharged on postoperative day 8 without any perioperative complications. The postoperative pathologic stage was pT1N0M0.

Keywords: Robotic-assisted thoracoscopic surgery; Ivor-Lewis; esophageal carcinoma

Received: 02 December 2016; Accepted: 27 December 2016; Published: 17 January 2017.

doi: 10.21037/amj.2017.01.14

View this article at: <http://dx.doi.org/10.21037/amj.2017.01.14>

Clinical data

A 51-year-old man was admitted to our hospital with a 1-week history of progressive dysphagia with solid food. He did not complain of retrosternal pain, gastroesophageal reflux or, weight loss. Esophagogastrosocopy identified a 3-cm mass in the esophageal lumen approximately 35 cm from the incisors, which was diagnosed as squamous cell carcinoma by endoscopic biopsy. Computed tomography (CT) of the chest and the abdomen revealed a thick wall around the distal thoracic esophagus with no metastases in the liver or lung, and the lymph nodes were negative (*Figure 1*). Barium swallow demonstrated a filling defect in the lumen of the distal third of the esophagus. Physical examination revealed no abnormalities. His cardiopulmonary function and laboratory tests were normal. He had no medical history.

Operation steps

Anesthesia and body position

Abdominal phase

After the general anesthesia and double-lumen endotracheal

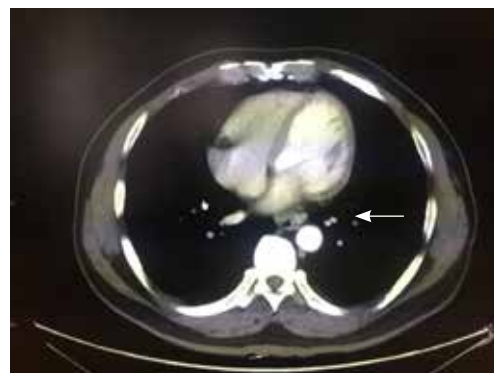

Figure 1 A mass located in the distal third of the esophagus and the mediastinal lymph nodes were negative.

intubation, the patient was placed in a supine position (*Figure 2*).

Thoracic phase

Once the abdominal phase was completed, the patient was positioned in the left lateral decubitus position, and tilted 45° towards the prone position under double-lumen endotracheal intubation (*Figure 3*).

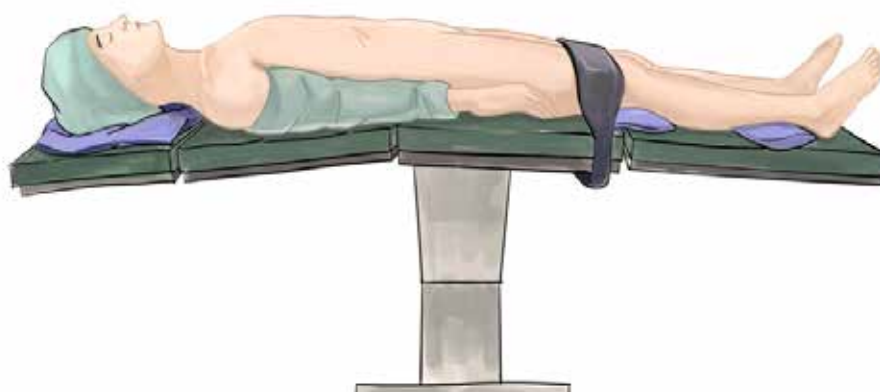


Figure 2 Supine position.

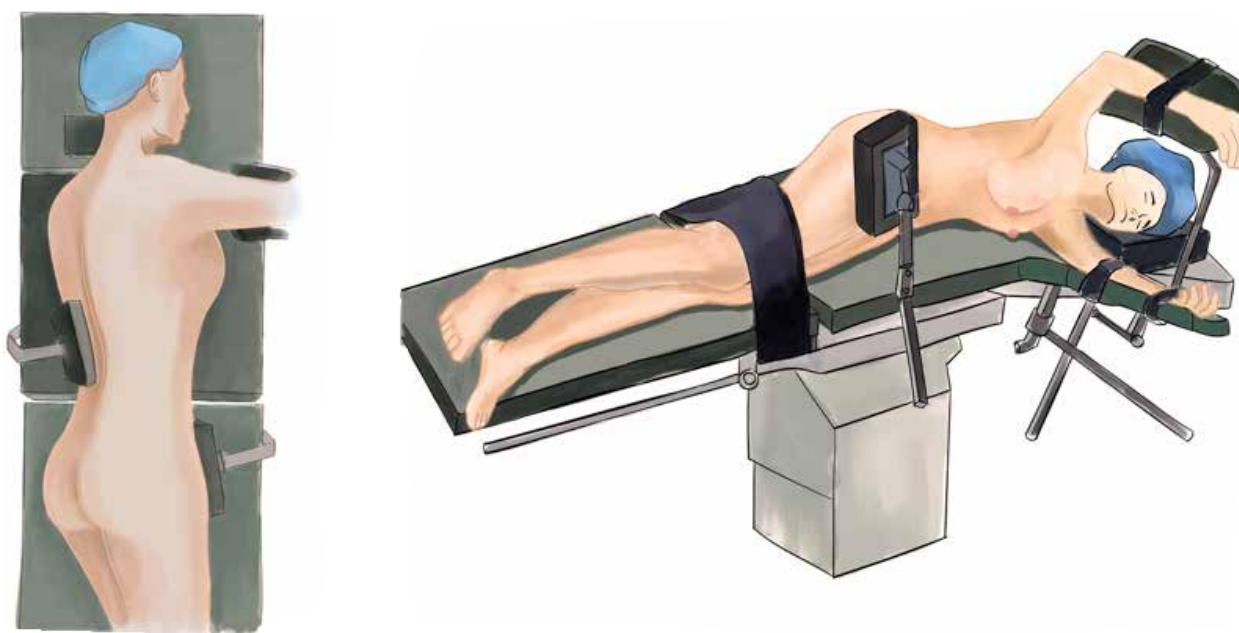


Figure 3 Left lateral decubitus and jackknife position.

Ports

Abdominal phase

Abdominal ports: the five-port method was used. The subumbilical port was used for observation (12-mm trocar), the #1 robotic arm was placed on the left anterior axillary line under the costal arch (8-mm trocar), the #2 robotic arm was placed on the right midclavicular line at 3 cm under the costal arch (8-mm trocar), and the #3 robotic arm was placed on the right anterior axillary line under the costal arch (8-mm trocar). An auxiliary port was placed on the left midclavicular line at 3 cm under the costal arch (12-mm

trocars) (*Figure 4*).

Thoracic phase

Thoracic ports: the five-port method was used. The observation port was placed on the right anterior axillary line at the 5th intercostal space (12-mm trocar), the #1 robotic arm was placed on right posterior axillary line at the 3th intercostal level (8-mm trocar), the #2 robotic arm was placed on the right posterior axillary line at 8th intercostal space (8-mm trocar), and the manual operative ports were placed on the right posterior axillary line at the 10th (8-mm trocar), and an auxiliary port was placed on the right

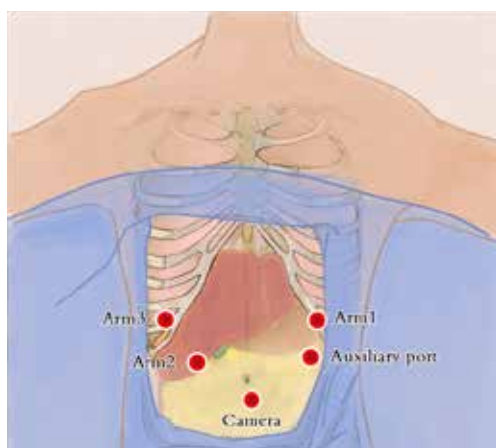


Figure 4 Ports for abdominal phase.

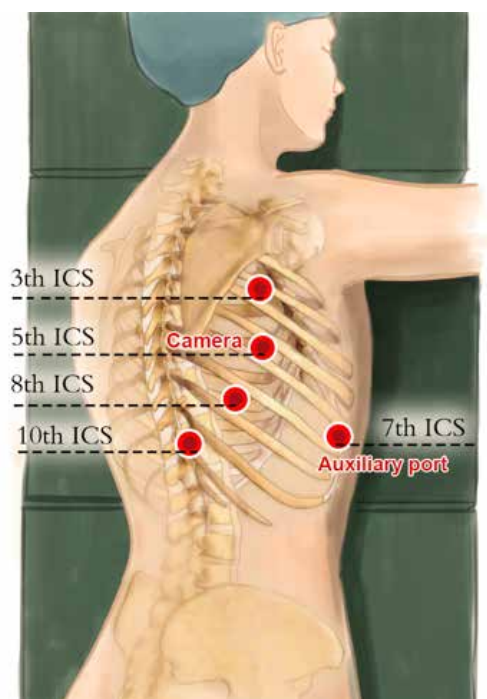

Figure 5 Ports for thoracic phase (3th, 5th, 7th, 8th, 10th ICS). ICS, ICS, intercostal space.

anterior axillary line at 7th intercostal spaces (12-mm trocar) (Figure 5).

Installation of the surgical arms

Abdominal phase

The #2 arm was connected to a bipolar cautery forceps, and

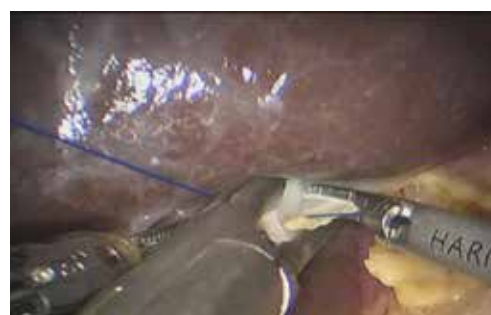

Figure 6 V-shaped liver suspension created by the purse string suture and clips

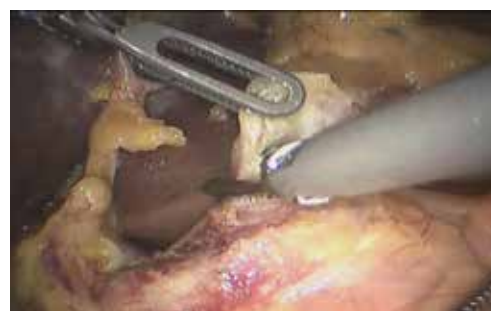

Figure 7 A radical en bloc lymphadenectomy was performed along the common hepatic artery, celiac trunk, and origin of the splenic artery.

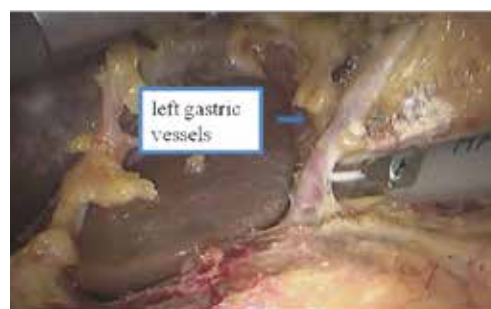


Figure 8 The left gastric vessels were dissected and interrupted, and the surrounding lymph nodes were removed.

the #1 arm was connected to an ultrasound knife.

Thoracic phase

The robot was positioned on the dorsal cranial side, with two assistants on the anterior side. The #2 arm was connected to a bipolar cautery forceps, and the #1 arm was

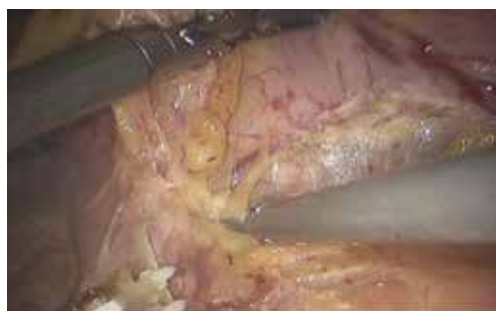

Figure 9 The adhesion between the stomach wall and pancreas was dissected.

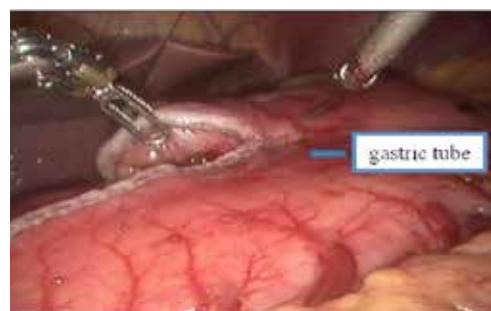


Figure 12 When the dissection was completed, a gastric tube was tailored using a stapling device. The transection started on the lesser curve and continued to the gastric fundus.

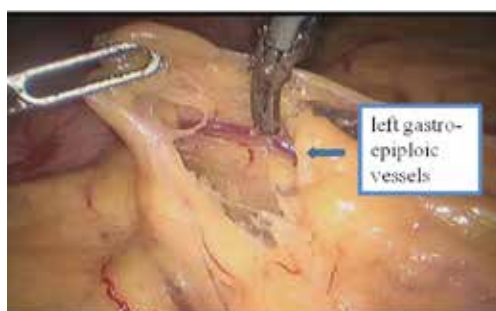

Figure 10 The greater curvature of the stomach was mobilized by dissecting the gastrocolic ligament and left gastroepiploic vessels.

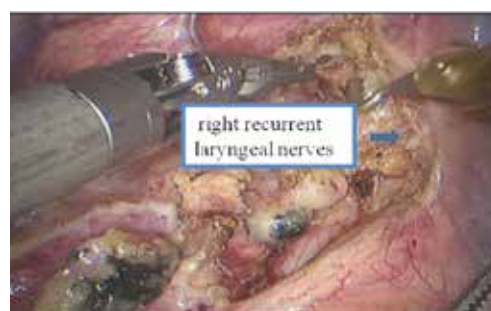


Figure 13 The lymph nodes with their associated fat pads around the right recurrent laryngeal nerves were dissected completely.

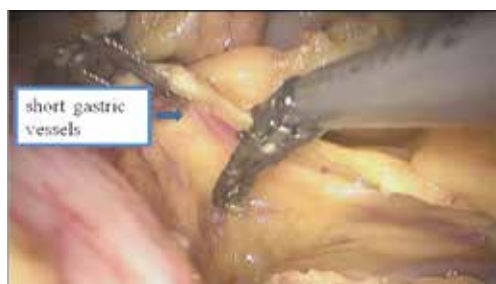

Figure 11 The short gastric vessels were cut.

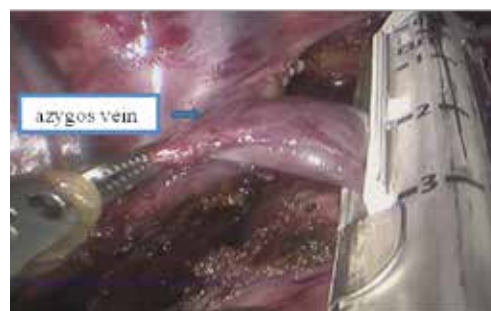


Figure 14 The azygos vein was dissected and divided using a stapling device.

connected to a unipolar cautery hook.

Surgical procedure

Abdominal phase

See Figures 6-12.

Thoracic phase

See Figures 13-22.

Postoperative condition

Postoperative treatments included anti-inflammatory

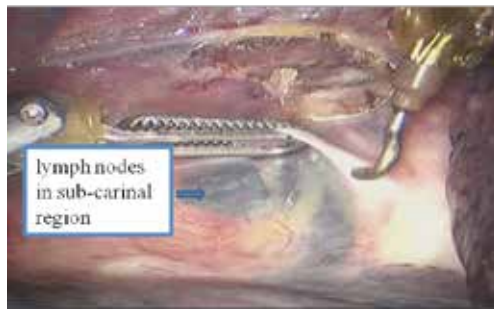

Figure 15 Complete lymph node dissection was performed in the sub-carinal region and right and left bronchus.

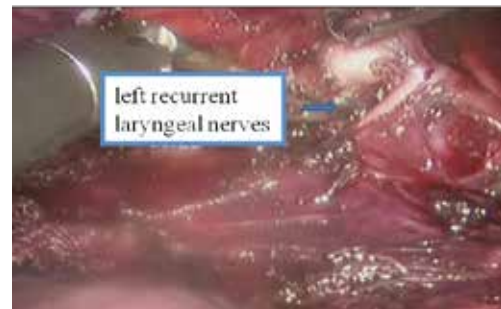

Figure 18 The lymph nodes around the left recurrent laryngeal nerves were dissected completely.

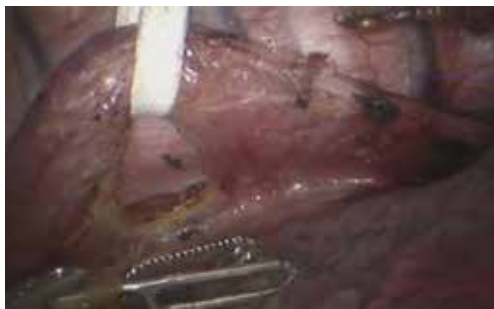

Figure 16 The esophagus was suspended with gauze.

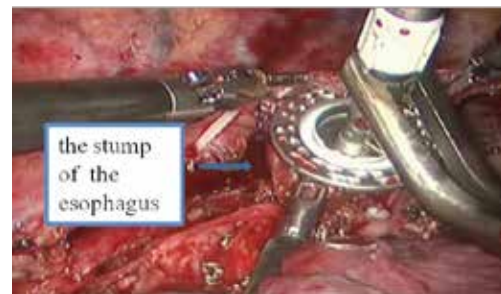

Figure 19 Anvil placement. Atraumatic robot graspers were used to pull the anvil into the cut end of the esophagus.

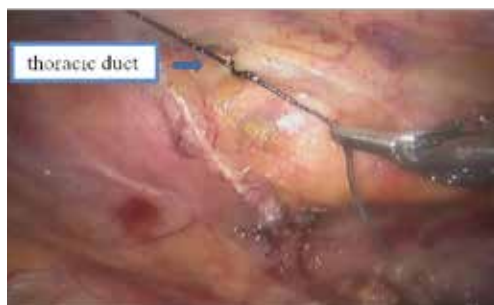

Figure 17 The thoracic duct was ligated.

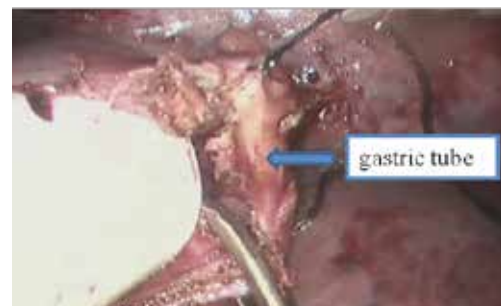


Figure 20 The end of the stapler was placed into the gastric tube.

medication, enteral nutrition and phlegm-resolving treatment. The chest cavity drainage tube was withdrawn after 2 days and the liquid diet was started on postoperative day 6. The patient was discharged on postoperative day 8 and tolerated a semi-liquid diet. No complications were observed during hospitalization. Pathologic diagnosis was squamous cell carcinoma infiltrating into the submucosa of the esophagus. All lymph nodes were negative. Postoperative pathologic stage was pT1N0M0 (IA squamous cell carcinoma).

Discussion

Surgery is currently the main treatment for esophageal cancer (1). Esophagectomy is technically challenging and is associated with high morbidity and mortality rates. Efforts to reduce these rates have spurred the adoption of minimally invasive techniques (2). But the conventional video-assisted surgery has some limitations such as the two-dimensional view or movement restrictions which could make a complex procedure such as esophagectomy difficult.

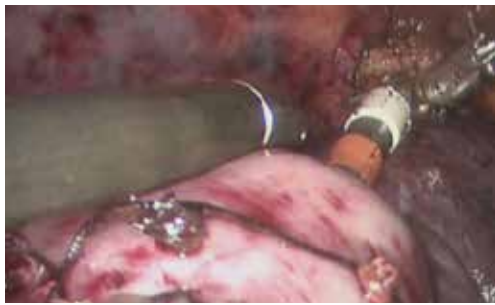

Figure 21 End-to-end anastomosis was created with circular stapler.

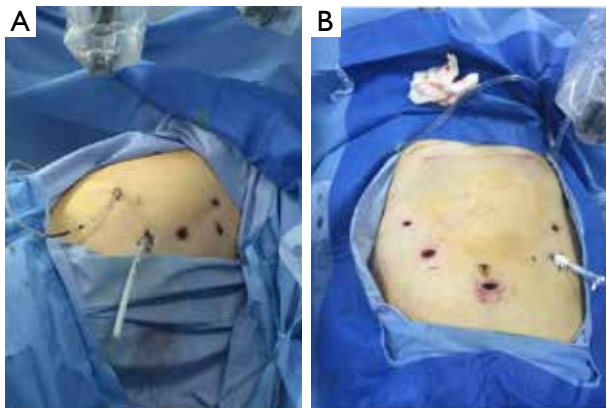


Figure 22 The placement of drainage. (A) Thoracic cavity; (B) abdominal cavity.

Robotic systems have been designed to overcome some of these disadvantages which could provide an amplified three-dimensional view and a greater freedom of movement (3). Most of the published reports on robotic esophagectomy describe two types of anastomosis including cervical or intrathoracic anastomosis that are created by using the suturing technique (4,5). Here we report the robot-assisted Ivor Lewis esophagectomy with intrathoracic stapled anastomosis. Our initial results suggest that the robotic-assisted surgical technique is safe and satisfies the

oncological principles. However, the potential of the da Vinci system remains to be proven in future clinical trials.

Acknowledgements

None.

Footnote

Conflicts of Interest: The authors have no conflicts of interest to declare.

Informed Consent: Written informed consent was obtained from the patient for publication of this manuscript and any accompanying images.

References

1. Dimick JB, Goodney PP, Orringer MB, et al. Specialty training and mortality after esophageal cancer resection. *Ann Thorac Surg* 2005;80:282-286.
2. Yerokun BA, Sun Z, Jeffrey Yang CF, et al. Minimally Invasive Versus Open Esophagectomy for Esophageal Cancer: A Population-Based Analysis. *Ann Thorac Surg* 2016;102:416-423.
3. Ruurda JP, van der Sluis PC, van der Horst S, et al. Robot-assisted minimally invasive esophagectomy for esophageal cancer: A systematic review. *J Surg Oncol* 2015;112:257-265.
4. Park SY, Kim DJ, Yu WS, et al. Robot-assisted thoracoscopic esophagectomy with extensive mediastinal lymphadenectomy: experience with 114 consecutive patients with intrathoracic esophageal cancer. *Dis Esophagus* 2016;29:326-332.
5. Hodari A, Park KU, Lace B, et al. Robot-Assisted Minimally Invasive Ivor Lewis Esophagectomy With Real-Time Perfusion Assessment. *Ann Thorac Surg* 2015;100:947-952.

doi: 10.21037/amj.2017.01.14

Cite this article as: Zhang Y, Yang S, Guo W, Jin R, Chen X, Wu H, Du H, Han D, Chen K, Xiang J, Li H. Ruijin robotic thoracic surgery: robot-assisted Ivor Lewis esophagectomy. *AME Med J* 2017;2:3.

Robotic assisted minimally invasive esophagectomy for esophageal cancer: a comment on the Ruijin hospital experience

David Pennywell, Inderpal S. Sarkaria

Department of Cardiothoracic Surgery, The University of Pittsburgh School of Medicine and the University of Pittsburgh Medical Center, Pittsburgh, PA, USA

Correspondence to: Dr. Inderpal S. Sarkaria. Department of Cardiothoracic Surgery, University of Pittsburgh Medical Center, UPMC Presbyterian-Shadyside, 5200 Centre Avenue, Suite 715.27, Pittsburgh, PA 15232, USA. Email: sarkariais@upmc.edu.

Provenance: This is an invited Editorial commissioned by Section Editor Jianfei Shen, MD (Department of Cardiothoracic Surgery, Taizhou Hospital of Zhejiang Province, Wenzhou Medical University, Taizhou, Zhejiang, China).

Comment on: Zhang Y, Yang S, Guo W, *et al.* Ruijin robotic thoracic surgery: robot-assisted Ivor Lewis esophagectomy. AME Med J 2017;2:3.

Submitted Aug 13, 2017. Accepted for publication Aug 22, 2017.

doi: 10.21037/jtd.2017.08.153

View this article at: <http://dx.doi.org/10.21037/jtd.2017.08.153>

Zhang *et al.* have described their technical approach to a total laparoscopic and thoracoscopic robotic assisted minimally invasive esophagectomy (RAMIE) via an Ivor Lewis approach for an early stage, distal, esophageal squamous cell carcinoma (1). The authors have offered a nicely detailed written, graphical, and pictorial description of port placement, positioning, and technical execution of the abdominal and thoracic portions of the operation using a three robotic-arm approach for both phases. The thoracic portion of the operation utilizes a semi-prone approach, and the intra-thoracic anastomosis is created using an end to end anastomotic (EEA) stapler. The authors depict several technical aspects including intra-corporeal creation of the gastric conduit, ligation of the thoracic duct, as well as dissection of lymph nodes along both recurrent laryngeal nerves. The patient did well with no immediate post-operative complications, and was discharged on post-operative day 8.

The current report is representative of a growing number of institutional series of Ivor Lewis RAMIE for esophageal cancer (2-4). Non-robotic minimally invasive esophagectomy (MIE) has largely been established as an approach with decreased pulmonary and wound complications, and equivalent oncologic outcomes compared to open operations (5,6).

While still limited in number, larger series of RAMIE are demonstrating feasibility, safety, and equivalence in early oncologic outcomes compared to other Ivor Lewis approaches (7,8). Putative advantages of the robotic approach include the advanced magnified stereo-optics, stable and central visualization of the operative field, articulated instrumentation,

and ability of the surgeon to self-assist. These advantages can be distilled into a single overarching principle: the surgeon simply gains far more control over the conduct of the operation. Intuitively, this suggests the ability to greatly increase operative efficiency with experienced users of current robotic platforms. These technologies may also potentially allow wider adoption of minimally invasive approaches by surgeons less experienced in standard minimally invasive techniques. However, this hypothesis, often assumed, is yet to be substantiated by evidence based studies.

Several cautions and potential pitfalls regarding the RAMIE approach should be considered, especially when instituting new programs. Esophagectomy remains a complex operation, with operative principles and surgeon expertise that remain paramount to gaining acceptable outcomes, regardless of the approach. It is imperative for new programs early in the learning curve for overall RAMIE and/or robotic skill sets to be aware of these challenges, and to avoid recapitulating known and avoidable complications of these operations.

First and foremost is the potential for airway injury and subsequent formation of enteric-airway fistula formation. This complication, far more common in minimally invasive operations (RAMIE or MIE), is almost always technical in nature. By and large, these devastating complications represent unintended or unrecognized direct or indirect thermal injury to the airway during thoracic esophageal mobilization and/or dissection of the subcarinal and paratracheal lymph nodes. Meticulous attention to clear identification of vital anatomy

and use of energy instrumentation with decreased thermal spread (such as bipolar instruments) during these portions of the operation can largely prevent these events (9).

Also, potential bleeding events during dissection of constricted gastro-splenic attachments, division of the short-gastric vessels, dissection of the left gastric pedicle/celiac axis, and posterior mediastinal/aortic dissection, far more common during open operations, can pose significant challenges during minimally invasive operations. Careful and meticulous dissection during these portions of the operation, potentially aided by uses of robotic platforms, will also serve to prevent many of these complications. When they do occur, surgeons must use quick and sound judgement in determining whether these events can be managed minimally invasively, or require urgent conversion to open operations (10). During attainment of the learning curve, estimated at 35–50 cases for experienced esophageal surgeons, strong consideration should be given to conversion for technically challenging portions of the case as experience is gained (7,8).

Growing evidence supports improved survival after esophagectomy with increased extent of lymphadenectomy (11). The robotic platform may allow for greater facility in lymphadenectomy to surgeons adopting minimally invasive approaches to esophagectomy, as nicely illustrated by the current cased study. As pictorially shown by Zhang *et al.*, extensive retrogastric/celiac, paraesophageal/mediastinal, and superior mediastinal/recurrent nerve lymph node dissection may be greatly facilitated by the sophisticated robotic instrumentation, stable control, and visualization.

As suggested by the authors, RAMIE represents a potentially safe and oncologically satisfactory operation for esophageal cancer. This commentary's senior author's (I.S.S.) own extensive experience with the RAMIE Ivor Lewis approach at both Memorial Sloan Kettering Cancer Center and the University of Pittsburgh Medical Center supports this hypothesis (8,12). In a collective experience of 125 cases, there was 1 operative mortality at 90 days, median lymph node counts were greater than 25, significant anastomotic leak occurred in 4%–6% of patients, and complete resection was achieved in over 90% of patients. While longer term data are needed to determine the oncologic equivalence of the operations, a growing number of similar series have supported RAMIE as a feasible and safe operation (13).

Our approach is similar, but differs in some technical details and preferences. We prefer a four arm robotic approach with an additional “self-assistant” arm, which may increase the surgeon's control of the operation and decrease reliance on the bedside assist. At the University of Pittsburgh, a pyloroplasty is

routinely performed in these patients and readily accomplished with the sophisticated robotic suturing abilities. Increasingly, robotic stapling technology is utilized to place additional control into the operator's hands during conduit creation and vessel ligation and division. We have also found some advantage to advance near infrared imaging technology, available on robotic platforms, to visualize critical vasculature, assess gastric conduit perfusion, and potentially aid in identification of involved lymph nodes in gastric carcinomas (14,15). The thoracic duct is not routinely ligated, unless injury is suspected. Given the significant predominance of gastroesophageal junction adenocarcinoma in our patient population, we do not find additional benefit in dissection of the recurrent laryngeal lymph node basins, with an associated rare incidence of recurrent laryngeal lymph node injury and vocal cord paresis. The thoracic portion of the operation is performed in the lateral decubitus position with no prone positioning. We believe this may allow for easier adoption of the technique, and more straightforward conversion, when needed. This position also allows for ready insertion of the fourth arm over approaches utilizing prone approaches. We utilize an additional port for a liver retractor, but highly appreciate the simple suture retraction method employed by Zhang *et al.*, which we may consider trialing in future operations, potentially allowing for streamlining of needed ports and equipment. We also perform a stapled EEA anastomosis, and find the suturing ability of the robotic platform allows for ease of placement of pursestring sutures to secure the anvil into the transected proximal esophagus.

Esophagectomy by any technique, whether open or laparoscopic/thoracoscopic, remains a complex and technically challenging operation. Regardless of the specific technical approach adopted by any given surgeon or practice, as Zhang *et al.* comment, minimally invasive approaches have arisen from a desire to improve the morbidity and mortality of open esophagectomy. MIE itself remains a technically challenging operation with a significant learning curve. Robotic approaches may allow surgeons to surmount some of these limitations. In their case report, Zhang *et al.* conclude that the robot-assisted technique which they have employed is both safe, and conducive to a satisfactory oncologic operation. While close attention must be paid to avoid known technical complications early in the learning curve, the authors of this commentary agree RAMIE is feasible and can be performed with a high degree of safety. RAMIE is likely to continue to be adopted by surgeons at esophageal centers of surgical excellence throughout the world, such as Dr. Zhang and colleagues at the Ruijin Hospital of the Shanghai Jiao Tong University School of

Medicine in Shanghai, China.

Acknowledgements

None.

Footnote

Conflicts of Interest: The authors have no conflicts of interest to declare.

References

1. Zhang Y, Yang S, Guo W, et al. Ruijin robotic thoracic surgery: robot-assisted Ivor Lewis esophagectomy. *AMA Med J* 2017;2:3.
2. Sarkaria IS, Rizk NP. Robotic-assisted minimally invasive esophagectomy: the Ivor Lewis approach. *Thorac Surg Clin* 2014;24:211-222. vii.
3. Cerfolio RJ, Bryant AS, Hawn MT. Technical aspects and early results of robotic esophagec-tomy with chest anastomosis. *J Thorac Cardiovasc Surg* 2013;145:90-96.
4. de la Fuente SG, Weber J, Hoffe SE, et al. Initial experience from a large referral center with robotic-assisted Ivor Lewis esophagogastrrectomy for oncologic purposes. *Surg Endosc* 2013;27:3339-3347.
5. Luketich JD, Pennathur A, Awais O, et al. Outcomes after minimally invasive esophagectomy: review of over 1000 patients. *Ann Surg* 2012;256:95-103.
6. Bieri SS, van Berge Henegouwen MI, Maas KW, et al. Minimally invasive versus open oe-sophagectomy for patients with oesophageal cancer: a multicentre, open-label, randomised controlled trial. *Lancet* 2012;379:1887-1892.
7. Hernandez JM, Dimou F, Weber J, et al. Defining the Learning Curve for Robotic-assisted Esophagogastrrectomy. *J Gastrointest Surg* 2013;17:1346-1351.
8. Sarkaria IS, Rizk NP, Grosser R, et al. Attaining Proficiency in Robotic-Assisted Minimally Invasive Esophagectomy While Maximizing Safety During Procedure Development. *Innova-tions (Phila)* 2016;11:268-273.
9. Sarkaria IS, Rizk NP, Finley DJ, et al. Combined thoracoscopic and laparoscopic robot-ic-assisted minimally invasive esophagectomy using a four-arm platform: experience, tech-nique and cautions during early procedure development. *Eur J Cardiothorac Surg* 2013;43:e107-e115.
10. Villa M, Sarkaria IS. Great Vessel Injury in Thoracic Surgery. *Thorac Surg Clin* 2015;25:261-278.
11. Rizk NP, Ishwaran H, Rice TW, et al. Optimum lymphadenectomy for esophageal cancer. *Ann Surg* 2010;251:46-50.
12. Okusanya OT, Sarkaria IS, Hess NR, et al. Robotic assisted minimally invasive esophagectomy (RAMIE): the University of Pittsburgh Medical Center initial experience. *Ann Cardiothorac Surg* 2017;6:179-185.
13. Ruurda JP, van der Sluis PC, van der Horst S, et al. Robot-assisted minimally invasive esophagectomy for esophageal cancer: A systematic review. *J Surg Oncol* 2015;112:257-265.
14. Herrera-Almario G, Patane M, Sarkaria I, et al. Initial report of near-infrared fluorescence imaging as an intraoperative adjunct for lymph node harvesting during robot-assisted lap-aoscopic gastrectomy. *J Surg Oncol* 2016;113:768-770.
15. Sarkaria IS, Bains MS, Finley DJ, et al. Intraoperative near-infrared fluorescence imaging as an adjunct to robotic-assisted minimally invasive esophagectomy. *Innovations (Phila)* 2014;9:391-393.

Cite this article as: Pennywell D, Sarkaria IS. Robotic assisted minimally invasive esophagectomy for esophageal cancer: a comment on the Ruijin hospital experience. *J Thorac Dis* 2017;9(9):2888-2890. doi: 10.21037/jtd.2017.08.153

Robotic-assisted McKeown esophagectomy

Dingpei Han, Su Yang, Wei Guo, Runsen Jin, Yajie Zhang, Xingshi Chen, Han Wu, Hailei Du, Kai Chen, Jie Xiang, Hecheng Li

Department of Thoracic Surgery, Ruijin Hospital, Shanghai Jiao Tong University, School of Medicine, Shanghai 200025, China

Correspondence to: Hecheng Li, MD, PhD. Department of Thoracic Surgery, Ruijin Hospital, Shanghai Jiao Tong University, School of Medicine, 197 Ruijin Er Road, Shanghai 200025, China. Email: lihecheng2000@hotmail.com.

Abstract: A patient with a history of dysphagia for 3 months was diagnosed as upper esophageal cancer by gastroscopy. After sufficient preoperative preparation, the patient underwent esophagectomy of McKeown procedure by Robotic-assisted approach. The five-port method was used in both thoracic and abdominal part. A jejunostomy tube was placed for enteral nutrition. At last, a cervical esophagogastric anastomosis was performed. No complications occurred during the 6-day postoperative hospitalization. The TNM stage was T3N0M0, stage IIA.

Keywords: Robotic-assisted surgery; esophageal cancer; esophagectomy

Received: 02 December 2016; Accepted: 27 December 2016; Published: 17 January 2017.

doi: 10.21037/amj.2017.01.18

View this article at: <http://dx.doi.org/10.21037/amj.2017.01.18>

Clinical data

The patient was a 53-year-old woman with a history of dysphagia for 3 months without nausea, vomiting, hematemesis, or stomachache. A protruding mass was detected 25–30 cm from the incisors by gastroscopy. The pathological biopsy result was esophageal squamous cancer. The patient lost 5 kg without anorexia. A physical examination showed no positive sign, and results of preoperative biochemical tests were all normal. Enhanced computed tomography (CT) scan revealed a thickened upper esophagus wall and enlarged lymph node in the superior mediastinum (*Figure 1*). Informed consent for robotic-assisted thoracic lobectomy was obtained from patient before operation.

Operating steps

Anesthesia and position

After general anesthesia, the patient was placed in a left lateral decubitus position with left one-lung ventilation in thoracic part (*Figure 2*). Supine position with two-lung ventilation in the abdominal part (*Figure 3*).

Ports

Abdominal ports (*Figure 4*): the five-port method was used. The subumbilical port was used for observation (12-mm trocar), #1 robotic arm was placed on the left anterior axillary line under the costal arch (8-mm trocar), the #2 robotic arm was placed on the right midclavicular line at 3 cm under the costal arch (8-mm trocar), and the #3 robotic arm was placed on the right anterior axillary line under the costal arch (8-mm trocar). An auxiliary port was placed on the left midclavicular line at 3 cm under the costal arch (12-mm trocar).

Thoracic ports (*Figure 5*): the five-port method was used. The observation port was placed on the right anterior axillary line at the 5th intercostal space (12-mm trocar), the #1 robotic arm was placed on right posterior axillary line at the 3th intercostal level (8-mm trocar), the #2 robotic arm was placed on the right posterior axillary line at 8th intercostal space (8-mm trocar), and the manual operative ports were placed on the right posterior axillary line at the 10th (8-mm trocar), and an axillary port were placed on the right anterior axillary line at 7th intercostal spaces (12-mm trocar).

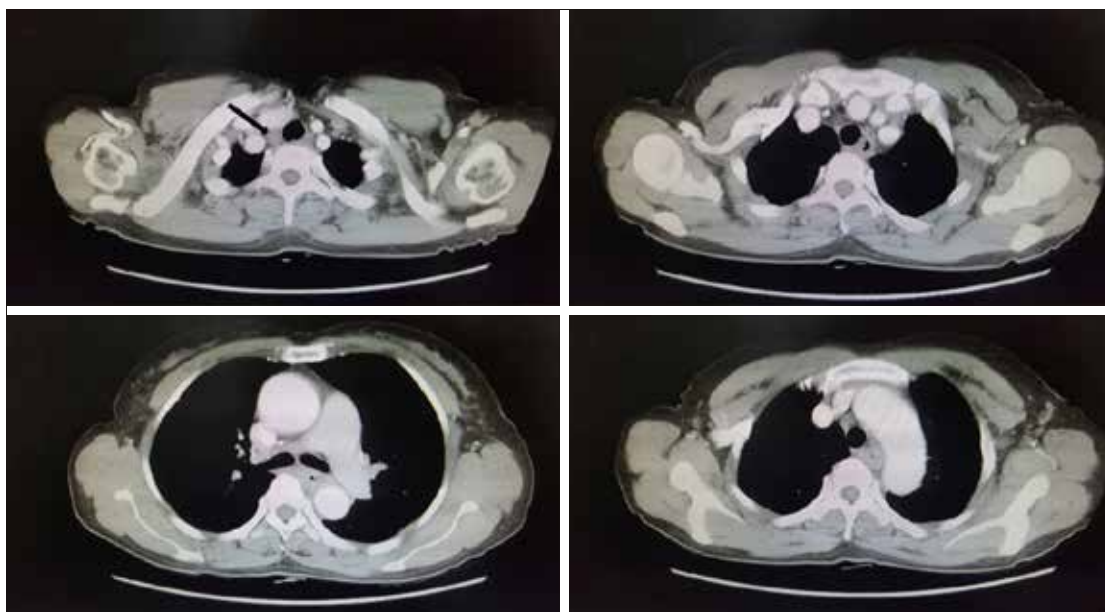


Figure 1 Enhanced CT scan. The black arrow indicates an enlarged lymph node beside the right recurrent laryngeal nerve.

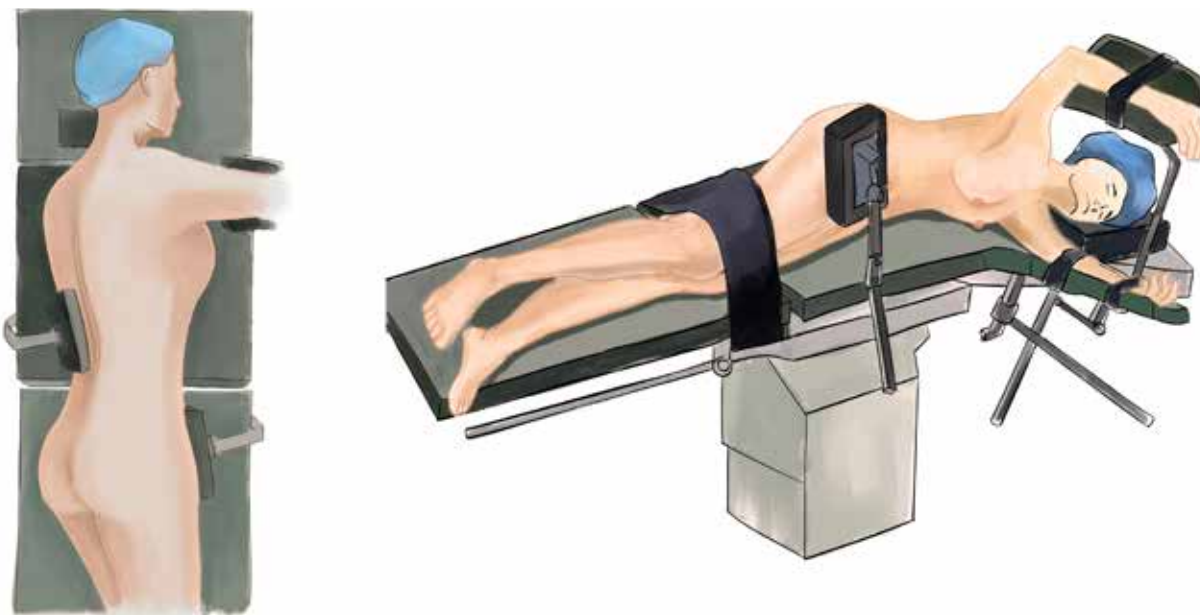


Figure 2 Left lateral decubitus and Jackknife position.

Docking the robotic arms

The robotic arms were docked through the operation table overhead, the #1 robotic arm was connected to a bipolar electric coagulation forceps, and the #2 robotic arm was connected to a hook electrode. A lap-protector was used to

avoid incision infection.

Surgical procedures

See *Figures 6-23*.

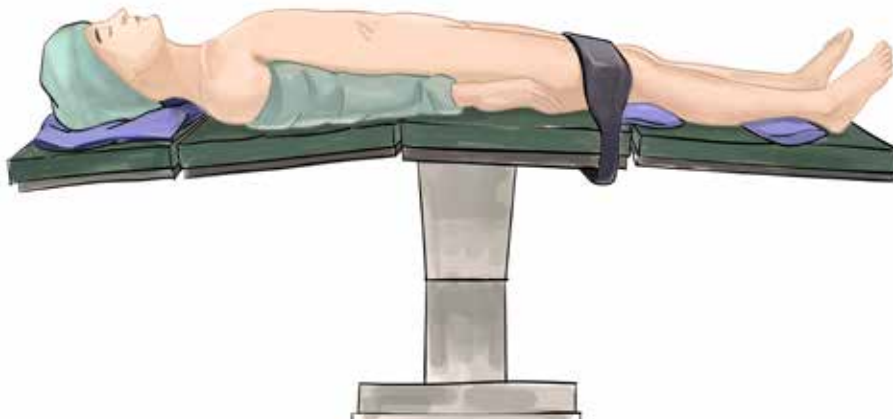

Figure 3 Supine position.

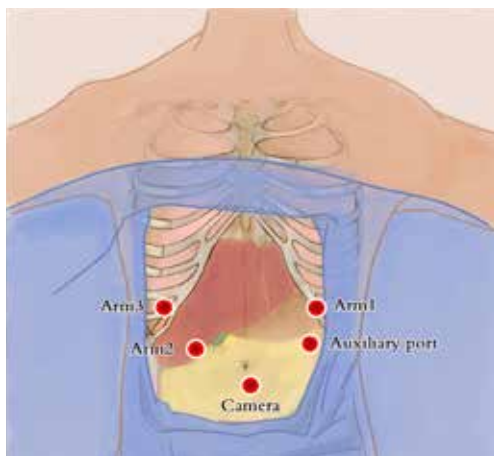


Figure 4 Ports for abdominal phase.

Postoperative results

The chest tube was removed on the second day postoperative day, and the patient was discharged on the sixth day postoperative day. No complications occurred during hospitalization. Pathologic diagnosis was esophageal squamous cancer (TNM stage was T3N0M0, stage IIA).

Comment

The first robotic-assisted minimally invasive esophagectomy (RAMIE) in the world was reported in 2003 by Dr.

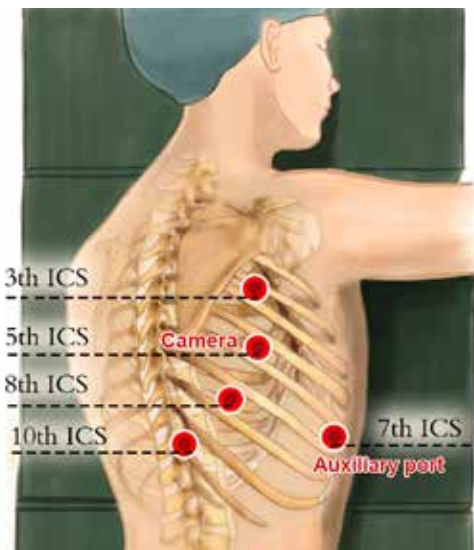


Figure 5 Ports for thoracic phase (3th, 5th, 7th, 8th, 10th ICS). ICS, intercostal space.

Horgan (1). Previously, research focused on RAMIE was limited because of the operative difficulties of minimally invasive esophagectomy, and the McKeown approach was the most widely adopted RAMIE approach. In 2010, Dr. Kim reported 21 cases of RAMIE to verify the feasibility and safety of the McKeown approach (2). In 2014, van der Sluis analyzed the clinical data of 108 patients who underwent RAMIE using the McKeown approach. The

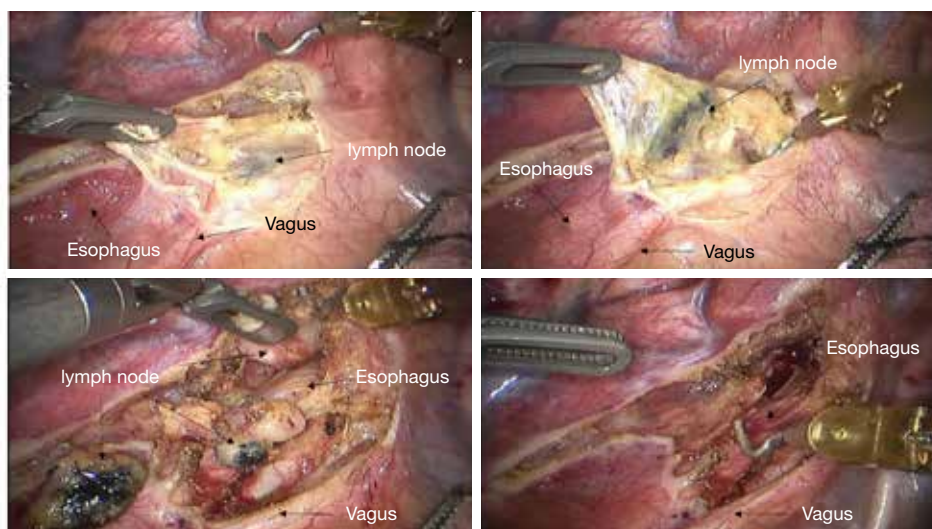


Figure 6 The lymph nodes around the right recurrent laryngeal nerve were dissected.

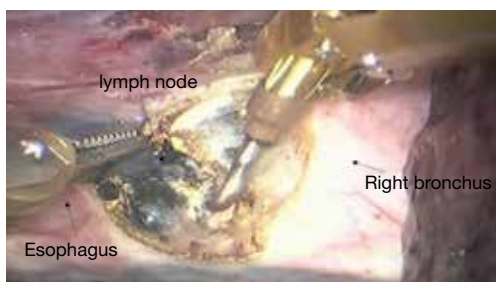


Figure 7 The subcarinal lymph nodes were dissected.

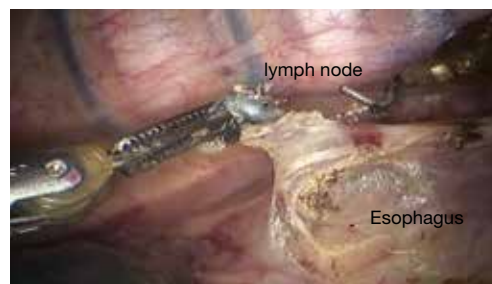


Figure 8 The lymph nodes around lower esophagus were dissected.

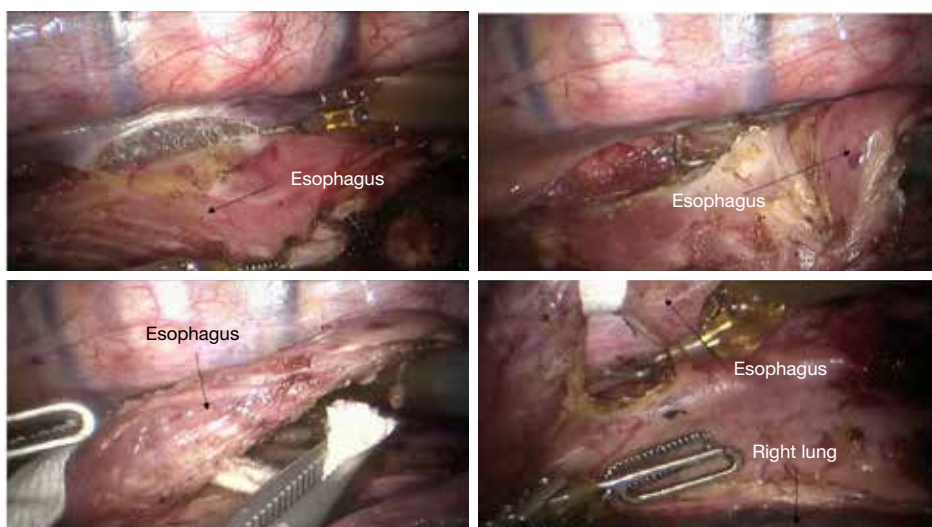


Figure 9 The middle esophagus was dissociated.

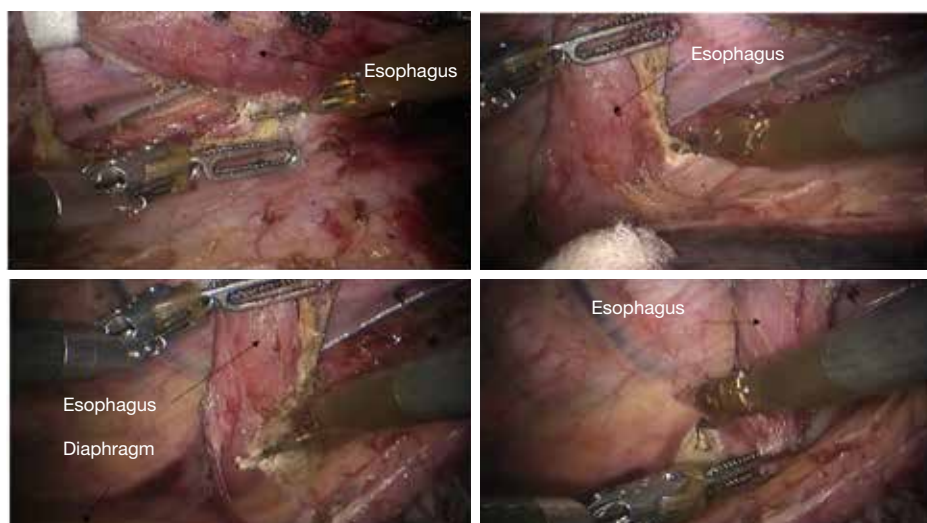


Figure 10 The lower esophagus was dissociated.

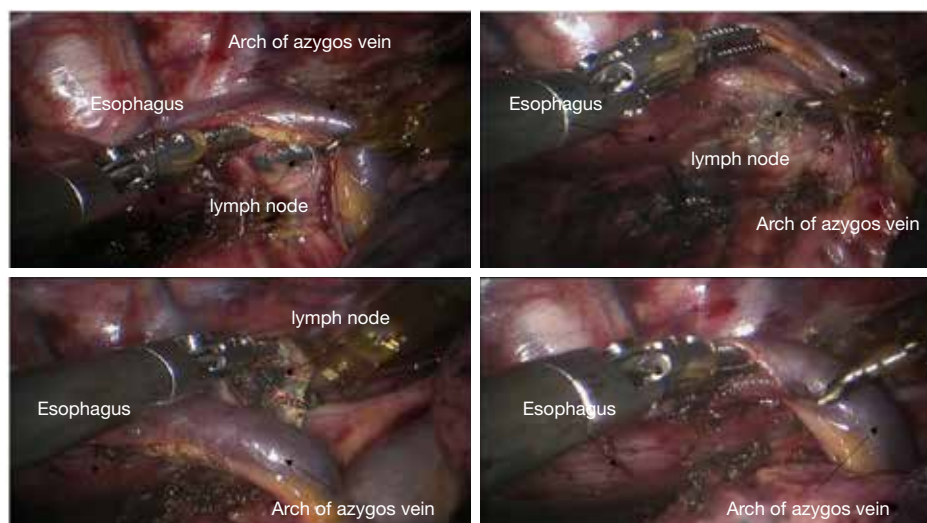


Figure 11 The lower esophagus was dissociated.

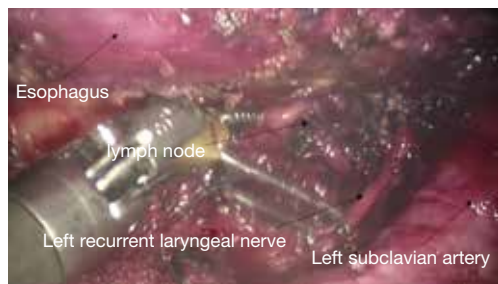


Figure 12 The lymph nodes around the left recurrent laryngeal nerve were dissected.

results showed that in-hospital mortality was 5%, 5-year-survival was 42%, and 47.2% cases had local or systemic recurrences. In this case, to avoid potential local recurrence, we removed the tumor during the thoracic part of the operation and connected the stumps of the upper and lower esophagus by using ribbon gauze. We found that the three-dimensional vision and robotic arm provided great accessibility for the subtle manipulations, especially while dissecting lymph nodes around the recurrent laryngeal nerves. It was reported that RAMIE could reduce the

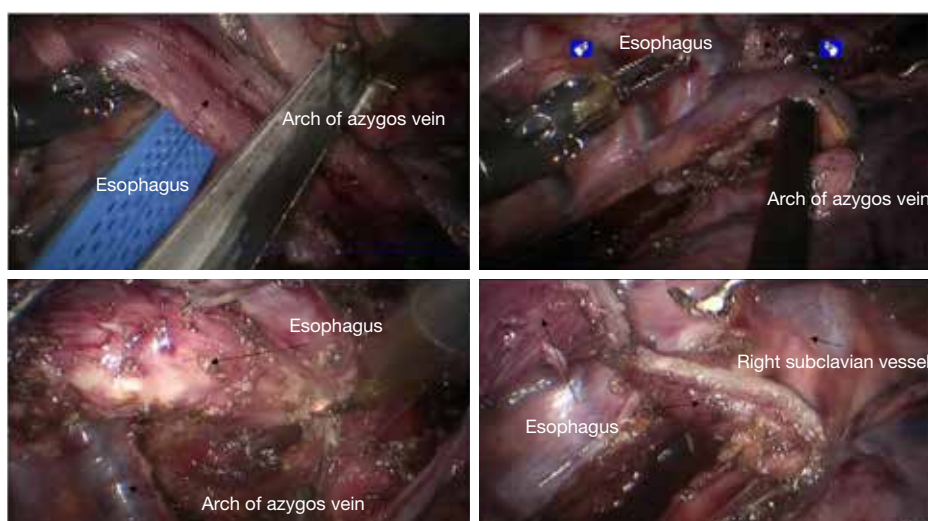


Figure 13 The upper esophagus was dissociated.

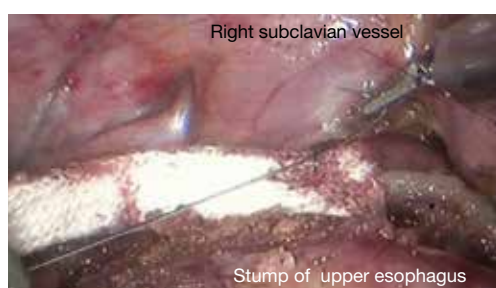


Figure 14 The stump of the upper esophagus was connected with ribbon gauze.

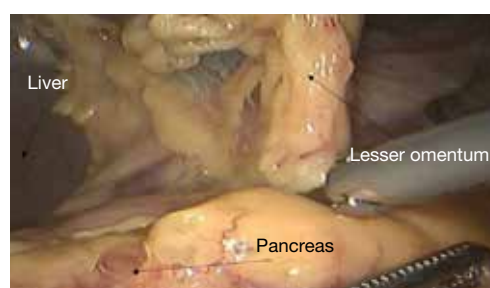

Figure 16 The lesser omentum was separated.

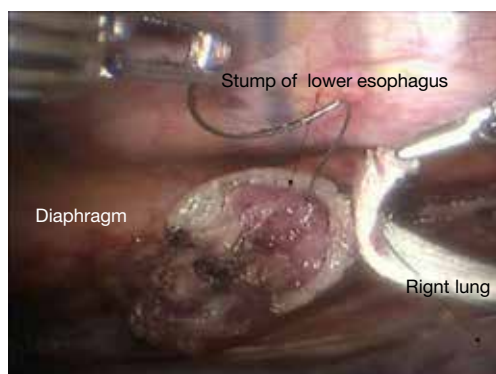


Figure 15 The stump of the lower esophagus was connected with ribbon gauze.

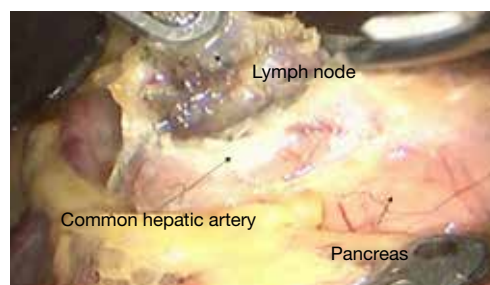


Figure 17 The lymph nodes around common hepatic artery were dissected.

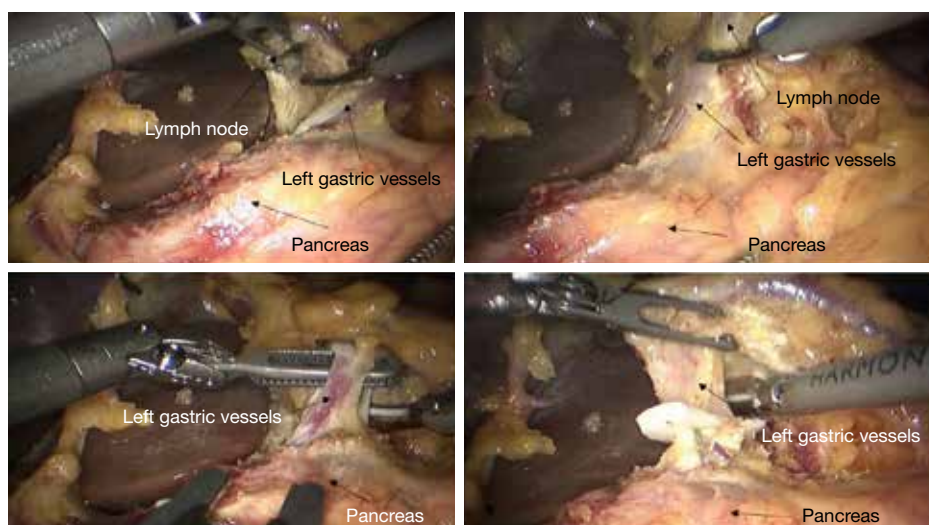


Figure 18 The lymph nodes around the left gastric vessels were dissected, and the left gastric vessels were cutting off.

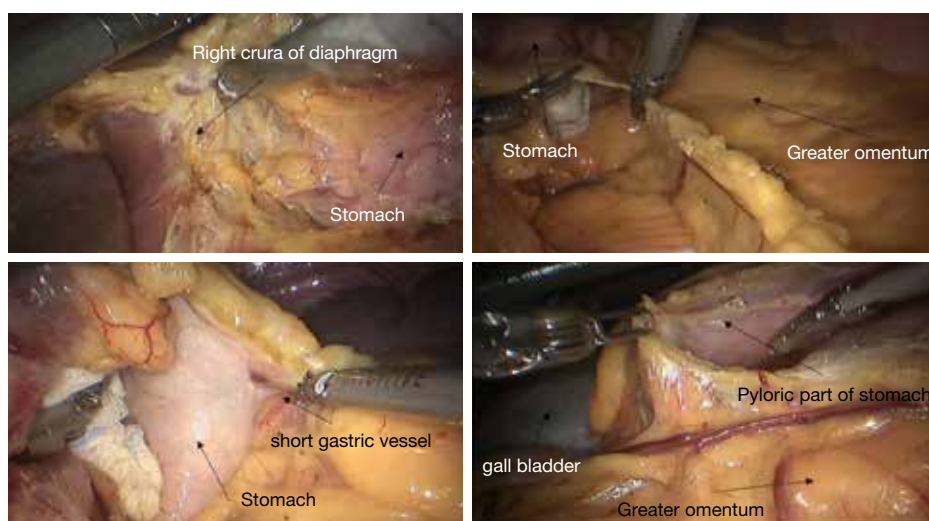


Figure 19 The stomach was mobilized after cutting off the short gastric vessels.

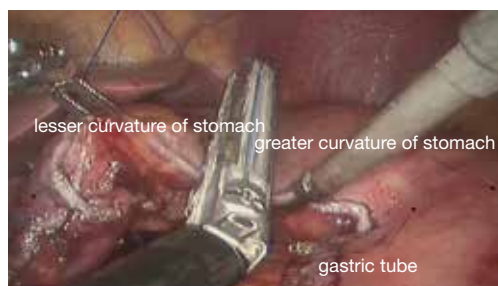


Figure 20 The gastric tube was created using staplers.

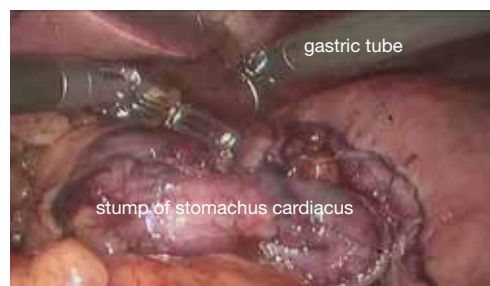


Figure 21 The gastric tube was connected to the stump of the cardia.

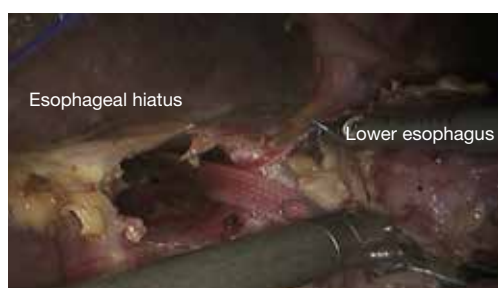


Figure 22 The cardia and abdominal esophagus were separated.

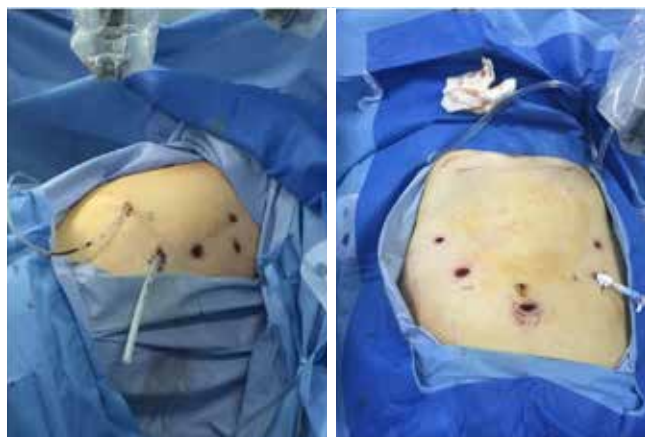


Figure 23 After the operation, a chest tube and a silicone tube were placed in the chest through the operative ports. A jejunostomy tube was placed during the abdominal operation. Subsequently, a cervical esophagogastric anastomosis was performed through the incision on the left side of the neck.

incidence of hoarseness (3) and provide satisfactory short-term outcomes (4). However, whether RAMIE can provide

long-term benefits to patients with esophageal cancer needs further study.

Acknowledgements

None.

Footnote

Conflicts of Interest: The authors have no conflicts of interest to declare.

Informed Consent: Written informed consent was obtained from the patient for publication of this manuscript and any accompanying images.

References

1. Horgan S, Berger RA, Elli EF, et al. Robotic-assisted minimally invasive transhiatal esoph-agectomy. *Am Surg* 2003;69:624-626.
2. Kim DJ, Hyung WJ, Lee CY, et al. Thoracoscopic esophagectomy for esophageal cancer: feasibility and safety of robotic assistance in the prone position. *J Thorac Cardiovasc Surg* 2010;139:53-59.e1.
3. Suda K, Ishida Y, Kawamura Y, et al. Robot-assisted thoracoscopic lymphadenectomy along the left recurrent laryngeal nerve for esophageal squamous cell carcinoma in the prone po-sition: technical report and short-term outcomes. *World J Surg* 2012;36:1608-1616.
4. Han D, Xiang J, Gao T, et al. Robotic-assisted Versus Open Ivor-Lewis Esophagectomy for Esophageal Cancer: a Comparative Study on Short-term Results. *Chin J Min Inv Surg* 2016;16:404-407.

doi: 10.21037/amj.2017.01.18

Cite this article as: Han D, Yang S, Guo W, Jin R, Zhang Y, Chen X, Wu H, Du H, Chen K, Xiang J, Li H. Robotic-assisted McKeown esophagectomy. *AME Med J* 2017;2:5.

Robotic esophagectomy: a better way or just another way?

Jacob A. Klapper, Matthew G. Hartwig

Division of Cardiothoracic Surgery, Duke University Medical Center, Durham, North Carolina, USA

Correspondence to: Dr. Jacob A. Klapper, MD. Division of Cardiothoracic Surgery, DUMC 3954, Durham 27710, North Carolina, USA.

Email: Jacob.klapper@duke.edu.

Provenance: This is an invited Editorial commissioned by Section Editor of JTD, Jianfei Shen, MD (Department of Cardiothoracic Surgery, Taizhou Hospital of Zhejiang Province, Wenzhou Medical University, Taizhou, China).

Comment on: Han D, Yang S, Guo W, *et al.* Robotic-assisted McKeown esophagectomy. *AME Med J* 2017;2:5.

Submitted Aug 03, 2017. Accepted for publication Aug 04, 2017.

doi: 10.21037/jtd.2017.08.57

View this article at: <http://dx.doi.org/10.21037/jtd.2017.08.57>

The authors present a concise case report of their experience performing a three-field esophagectomy robotically (1). They have clearly developed a methodology for performing this operation that works well and their report demonstrates the profound forethought that they have given towards safely performing this operation minimally-invasively. Reading this article, we are reminded of the long-standing question of what the superior approach is for esophagectomy. Multiple authors and centers have offered their opinions as to which approach is better over the years, often citing conflicting data (2,3). Now with the application of robotic technology we have yet another entrant into the discussion of what represents the best technique.

Over the years, numerous articles have been published promoting the advantages of one approach over another. No large randomized trial has ever been done comparing Ivor-Lewis esophagectomy to either transhiatal or three-field, and it is unlikely that one will ever be done, as some estimate that it would take nearly 3,200 patients to adequately address the question (4). In terms of postoperative morbidity, it would appear that with a three-field esophagectomy or transhiatal approach, leak rate is higher and thus, so is the subsequent risk of stricture. Conversely, the risk of leak is less with an Ivor Lewis esophagectomy, but the morbidity of a leak in the chest has, traditionally, been higher (5). While these facts are, for the most part, agreed upon, there has been some dispute regarding which operation is oncologically superior, and this too is an unanswered question (2,3). In the end,

robotic esophagectomy becomes part of a field that has no accepted standard of care and where institution and surgeon preferences predominate.

The morbidity associated with an esophagectomy, regardless of the approach, has been documented to be high, anywhere from 40%–50%. Aside from the complexity of this operation, the candidates for it are often debilitated by their disease and of advanced age; a combination of factors that contribute to the high rate of complications that arise. Ultimately, among the myriad of potential complications perhaps none are more feared than pneumonia, anastomotic leak, or gastric tip necrosis. In theory, part of the appeal of minimally-invasive techniques is that they might reduce the rate of post-operative complications. Prior to the introduction of the Da Vinci robot, laparoscopic and VATS approaches were promoted as a way to reduce morbidity. The data to support that these techniques have accomplished this goal are not robust. Certainly, at high volume centers with vast experience, the results have been encouraging. The University of Pittsburgh group reported a rate of major morbidities of 32% in 222 minimally-invasive esophagectomies (6). Alternatively, in a recent review of the National Cancer Database (NCDB) that evaluated outcomes following over 4,000 esophagectomies (1,300 of which were completed “minimally-invasively”), the authors reported comparable readmission and length of stay numbers for open versus minimally-invasive esophagectomy. Admittedly, this study, due to the nature of the database, was limited by a lack of information regarding specific morbidities or conduct of the operation, but the

surrogates they reported would suggest that minimally-invasive techniques produce only modest improvements. Interestingly, in a subgroup analysis, comparing robot-assisted esophagectomy to standard minimally-invasive strategies, there was no difference in outcomes; either cancer related or otherwise (7).

With incontrovertible evidence still lacking that traditional minimally-invasive techniques are superior to open approaches, the onus is on our field to continue working towards establishing a clear advantage to the application of the robotic and non-robotic minimally invasive techniques. As a frame of reference, robotic technology has been uniformly accepted as advantageous to traditional methods in other disciplines such as gynecology and urology, where the robot's fine movements have particular advantages in procedures like a prostatectomy. The benefits of the robot include a 3D camera with 10× magnification, the ability to drive one's own camera, and wristed instruments. Technical limitations include the lack of haptic feedback and the need for qualified bedside assistance. More specifically to esophagectomy, the robot allows for superior visualization of the right gastroepiploic artery, which aids in its preservation. Plus, all robots are equipped with Spyware technology, which can serve as a valuable adjunct when assessing conduit perfusion. Thoracoscopically, the wristed instruments greatly facilitate the creation of the anastomosis. For example, at our institution, we routinely perform a robot-assisted esophagectomy with a stapled side-to-side anastomosis followed by suture closure of the front wall; a process that is greatly simplified by the robot.

Despite some of its potential advantages, the application of the robot has been less uniformly widespread in thoracic surgery. This reality is, of course, multifaceted and is not simply limited to the much-heralded “learning-curve”, which cannot be diminished in its significance, and continues to limit the adoption of even VATS techniques for pulmonary disease. To begin with, simply consider the financial burden of the robot. At a cost, per machine of over \$1.5 million dollars (with a second console costing another half million) and maintenance costs of over \$100,000 dollars per year, it can be difficult for institutions to profit from procedures performed on the robot. For instance, in a single center retrospective cost analysis of VATS versus open versus robotic lobectomy, there was a significant difference in overall

cost of \$3,182 between robotic and VATS cases (8). Likewise, in another study based on the Nationwide Inpatient Sample, which is a large database maintained by the Agency for Healthcare Research Quality, total charges were again significantly higher in the cohort of patients undergoing a robotic lobectomy (9). However, it may be that systematic streamlining of operating room processes may lead to more cost-effective delivery of care in this area. For example, the group at the University of Alabama-Birmingham has published data demonstrating profitability from robotic techniques. While certainly impressive, this institution has achieved these margins by limiting expenditures on other routine elements of care. The early reports are very promising and hopefully longer-term studies will demonstrate cost savings without compromising quality of care (10).

Secondary to these challenges, robot-assisted thoracic procedures have been slow to attain widespread adoption. For example, a review of the NCDB for all lobectomies performed between the years of 2010 and 2012 demonstrated that only 20.9% of lobectomies are even being performed by VATS; with a paltry 5.9% being done robotically (11). However, the most recent report from 2016 indicated 40% of lobectomies in the U.S. were done using VATS techniques, and 20% were done robotically—a sharp increase in minimally invasive techniques. So what does this mean for robotic esophagectomy? Likely, the gradual acceptance of robotic lobectomy suggests a slow adoption for esophagectomy; again for a number of reasons. First, it is important to consider the disease itself. A still relatively rare disease in the U.S., with only 17,000 cases diagnosed per year (with the majority of those patients being non-operable), the number of esophagectomies being performed nationwide is relatively small in comparison to lobectomies (12). In addition, with the advances in endoscopic treatments (i.e., radiofrequency ablation, endoscopic mucosal resection and endoscopic submucosal resection) for Barrett's esophagus, high grade dysplasia (HGD) and T1a esophageal cancer, far fewer patients are being referred for esophagectomy. Thus, fewer esophagectomies are being done and far fewer surgeons nationwide have the level of surgical volume that enables them to develop the skill set required for robotic-assisted esophagectomy. In contrast, the disease is far more common in China and other countries in the Southeast Asia, where the number of esophagectomies that are performed at single hospitals

may eclipse the combined numbers across a geographic region in the U.S. Thus, when one takes all these variables into account, it seems likely that robot-assisted esophagectomy is going to remain, at least in the U.S., the domain of a very few centers.

The next question related to the robot is one of benefit. Any attempt to answer this question brings one back to the subject of superiority of approach. Clearly, there is no evidence yet that robotic-esophagectomy is better in terms of morbidity and mortality than traditional minimally-invasive techniques (7). In truth, the application of any new technology in medicine or surgery should at least meet, if not exceed, the traditional standard of care. No one would, for instance, dispute that a laparoscopic cholecystectomy was a vast improvement over the quite morbid way the operation was previously performed. More recently, transcatheter aortic valve replacement (TAVR) has repeatedly demonstrated outcomes that are either comparable or superior to surgical aortic valve repair while sparing these patients the morbidity associated with open heart surgery and cardiopulmonary bypass (13). But in reality and with these examples in mind, it is essential to remember that these transitions in surgical technique take time as the evidence mounts in one direction or another. The current manuscript provides support that the robotic approach can be systematically arranged and appears to be a safe and viable minimally invasive option. This importantly forms the basis to allow pioneers in this area to demonstrate superiority if and when it exists. We think few can deny that with continued engineering and technological advances, the future of robotic surgery will be intimately intertwined with the future of surgery in general.

In sum, robotic esophagectomy is yet another way of performing a difficult operation. In the future, it will undoubtedly become the preferred approach of certain surgeons and groups. Perhaps as the technology continue to improve, as it no doubt has across the various iterations of the Da Vinci system, more surgeons will begin to opt for its use. That has already been witnessed in the lung cancer arena. That said, we truly believe when it comes to esophagectomy, the best approach is the one that, for the individual surgeon, reliably produces consistently good outcomes for their patients in the least invasive manner possible. With that in mind, we commend the authors of this paper for achieving such an excellent outcome for their patient.

Acknowledgements

None.

Footnote

Conflicts of Interest: The authors have no conflicts of interest to declare.

References

1. Han D, Yang S, Guo W, et al. Robotic-assisted McKeown esophagectomy. *AME Med J* 2017;2:5.
2. Rentz J, Bull D, Harpole D, et al. Transthoracic versus transhiatal esophagectomy: a pro-spective study of 945 patients. *J Thorac Cardiovasc Surg* 2003;125:1114-1120.
3. Chang AC, Ji H, Birkmeyer NJ, et al. Outcomes after transhiatal and transthoracic esoph-agectomy for cancer. *Ann Thorac Surg* 2008;85:424-429.
4. Rindani R, Martin CJ, Cox MR. Transhiatal versus Ivor-Lewis oesophagectomy: is there a difference? *Aust N Z J Surg* 1999;69:187-194.
5. Gluch L, Smith RC, Bambach CP, et al. Comparison of outcomes following transhiatal or Ivor Lewis esophagectomy for esophageal carcinoma. *World J Surg* 1999;23:271-275.
6. Luketich JD, Alvelo-Rivera M, Buenaventura PO, et al. Minimally invasive esophagectomy: outcomes in 222 patients. *Ann Surg* 2003;238:486-494.
7. Yerokun BA, Sun Z, Yang CJ, et al. Minimally Invasive Versus Open Esophagectomy for Esophageal Cancer: A Population-Based Analysis. *Ann Thorac Surg* 2016;102:416-423.
8. Deen SA, Wilson JL, Wilshire CL, et al. Defining the cost of care for lobectomy and seg-mentectomy: a comparison of open, video-assisted thoracoscopic, and robotic approaches. *Ann Thorac Surg* 2014;97:1000-1007.
9. Paul S, Jalbert J, Isaacs AJ, et al. Comparative effectiveness of robotic-assisted vs thoraco-scopic lobectomy. *Chest* 2014;146:1505-1512.
10. Nasir BS, Bryant AS, Minnich DJ, et al. Performing robotic lobectomy and segmentectomy: cost, profitability, and outcomes. *Ann Thorac Surg* 2014;98:203-208.
11. Yang CF, Sun Z, Speicher PJ, et al. Use and Outcomes of Minimally Invasive Lobectomy for Stage I Non-Small Cell Lung Cancer in the National Cancer Data Base. *Ann Thorac Surg* 2016;101:1037-1042.

12. SEER database. Cancer Stat Facts: Esophageal Cancer. 2017. Available online: <https://seer.cancer.gov/statfacts/html/esoph.html>
13. Leon MB, Smith CR, Mack MJ, et al. Transcatheter or Surgical Aortic-Valve Replacement in Intermediate-Risk Patients. *N Engl J Med* 2016;374:1609-1620.

Cite this article as: Klapper JA, Hartwig MG. Robotic esophagectomy: a better way or just another way? *J Thorac Dis* 2017;9(8):2328-2331. doi: 10.21037/jtd.2017.08.57

Robotic-assisted McKeown esophagectomy: a safe and reliable method

Dingpei Han, Hecheng Li

Department of Thoracic Surgery, Ruijin Hospital, Shanghai Jiao Tong University, School of Medicine, Shanghai 200025, China

Correspondence to: Hecheng Li, PhD. Department of Thoracic Surgery, Ruijin Hospital, Shanghai Jiao Tong University, School of Medicine, 197 Ruijin Er Road, Shanghai 200025, China. Email: lihecheng2000@hotmail.com.

Provenance: This is an invited article commissioned by Section Editor Jianfei Shen, MD (Department of Cardiothoracic Surgery, Taizhou Hospital of Zhejiang Province, Wenzhou Medical University, Taizhou, China).

Response to: Klapper JA, Hartwig MG. Robotic esophagectomy: a better way or just another way? J Thorac Dis 2017;9:2328-31.

Submitted Sep 25, 2017. Accepted for publication Oct 13, 2017.

doi: 10.21037/jtd.2017.10.82

View this article at: <http://dx.doi.org/10.21037/jtd.2017.10.82>

Authors reply to “Robotic esophagectomy: a better way or just another way?”.

Thank you to the reviewer for the constructive comments on our manuscript of a case report of robotic-assisted three-field esophagectomy (1). The comments briefly reviewed the current state of minimal invasive esophagectomy (MIE) and asked the pragmatic question “Is robotic esophagectomy a better way or just another way?”.

Esophageal cancer ranks fifth in morbidity and fourth in mortality among all of the cancers in China. Patients often suffer great trauma and low quality of life after complex yet effective esophagectomies, and surgeons do their best to reduce the trauma of surgery, although early studies suggested that MIE did not provide advantages over open surgery with regards to postoperative recovery and complications (2), recent studies have demonstrated the benefits of MIE. In 2013, Dolan *et al.* (3) published a comparative study of 146 cases of open esophagectomy and MIE, and they showed that the MIE group had less blood loss, a higher amount of lymph node harvested, and shorter hospital stays than the open esophagectomy group, with no difference in the 5-year survival between the groups. In 2016, Guo *et al.* (4) performed a meta-analysis of 1,549 cases and found that MIE led to fewer postoperative complications and a similar survival rate when compared to open surgery. Furthermore, for patients with middle and lower esophageal cancers, a totally minimally invasive Ivor-Lewis esophagectomy can lead to less trauma, reduced postoperative pain, and fewer lung complications than open surgery (5). The benefits of MIE were also confirmed in a

randomized controlled trial, which found that the short-term oncologic results of MIE were comparable with standard open surgery (6). Although it has been clearly shown that MIE associates with faster recovery and less morbidity, the long-term outcomes and oncologic results remain in dispute.

In addition, the reviewer mentioned that fewer esophagectomies were performed in the U.S. because of the level of surgical volume. In China, because esophageal cancer is a common disease, Chinese surgeons will have the opportunities to develop the skills that are required to perform robotic-assisted esophagectomies. As in the U.S., there has been an increase in robotic thoracic surgeries in China. Since 2015, we have performed over 70 robotic-assisted esophagectomies, and preliminary results showed that the short-term outcomes, including 1-year overall survival and disease-free survival, were similar for robotic and open surgeries. In addition, our department performed a clinical trial entitled “Robot-assisted Ivor-Lewis esophagectomy: short-term outcomes of a single-arm phase II trial” to verify the outcomes of the robotic esophagectomies. Recently, we have attempted manual intrathoracic anastomosis for several cases, and flexible robot arms allowed for the most difficult step of MIE to be performed smoothly.

However, currently there is a lack of definitive evidence to support the superiority of robotic esophagectomy with regards to morbidity and mortality (7), and the cost associated with robotic esophagectomy is high. While it appears that robotic esophagectomy is a safe and reliable

method nowadays, we believe that with the development of instruments and the training programs of learning this technique, the advantages of robotic surgery will be amplified in the future, and the robotic esophagectomy will be a better option.

Acknowledgements

We would like to acknowledge David Tian, Senior Editor of AME Publishing Company, for editing support.

Funding: This study was supported by the grant from Science and Technology Commission of Shanghai Municipality Medical Guidance Science & Technology Support Project (16411966100), Shanghai Municipal Education Commission-Gaofeng Clinical Medicine Grant Support (20172005) and Shanghai Municipal Commission of Health and Family Planning Outstanding Academic Leaders Training Program (2017BR055).

Footnote

Conflicts of Interest: The authors have no conflicts of interest to declare.

References

1. Klapper JA, Hartwig MG. Robotic esophagectomy:

a better way or just another way? *J Thorac Dis* 2017;9:2328-2331.

2. Verhage RJ, Hazebroek EJ, Boone J, et al. Minimally invasive surgery compared to open procedures in esophagectomy for cancer: a systematic review of the literature. *Minerva Chir* 2009;64:135-146.
3. Dolan JP, Kaur T, Diggs BS, et al. Impact of comorbidity on outcomes and overall survival after open and minimally invasive esophagectomy for locally advanced esophageal cancer. *Surg Endosc* 2013;27:4094-4103.
4. Guo W, Ma X, Yang S, et al. Combined thoracoscopic-laparoscopic esophagectomy versus open esophagectomy: a meta-analysis of outcomes. *Surg Endosc* 2016;30:3873-3881.
5. Guo W, Ma L, Zhang Y, et al. Totally minimally invasive Ivor-Lewis esophagectomy with single-utility incision video-assisted thoracoscopic surgery for treatment of mid-lower esophageal cancer. *Dis Esophagus* 2016;29:139-145.
6. Bieri SS, van Berge Henegouwen MI, Maas KW, et al. Minimally invasive versus open oesophagectomy for patients with oesophageal cancer: a multicentre, open-label, randomised controlled trial. *Lancet* 2012;379:1887-1892.
7. Yerokun BA, Sun Z, Yang CJ, et al. Minimally Invasive Versus Open Esophagectomy for Esophageal Cancer: A Population-Based Analysis. *Ann Thorac Surg* 2016;102:416-423.

Cite this article as: Han D, Li H. Robotic-assisted McKeown esophagectomy: a safe and reliable method. *J Thorac Dis* 2017;9(10):E974-E975. doi: 10.21037/jtd.2017.10.82

Ruijin robotic thoracic surgery: robot-assisted enucleation of esophageal leiomyoma

Yajie Zhang, Su Yang, Wei Guo, Runsen Jin, Xingshi Chen, Han Wu, Hailei Du, Dingpei Han, Kai Chen, Jie Xiang, Hecheng Li

Department of Thoracic Surgery, Ruijin Hospital, Shanghai Jiao Tong University, School of Medicine, Shanghai 200025, China

Correspondence to: Hecheng Li, MD, PhD. Department of Thoracic Surgery, Ruijin Hospital, Shanghai Jiao Tong University, School of Medicine, 197 Ruijin Er Road, Shanghai 200025, China. Email: lihecheng2000@hotmail.com.

Abstract: We are going to share the experience of robotic surgery for esophageal leiomyoma. A 46-year-old patient underwent robotic-assisted enucleation of esophageal leiomyoma in our center. The patient was discharged on postoperative day 5 without any perioperative complications. Our result showed the robotic-assisted surgery has some advantages particularly in performing suture and knot tying.

Keywords: Robotic-assisted thoracoscopic surgery, esophageal leiomyoma

Received: 02 December 2016; Accepted: 27 December 2016; Published: 08 February 2017.

doi: 10.21037/amj.2017.01.15

View this article at: <http://dx.doi.org/10.21037/amj.2017.01.15>

Clinical data

A 46-year-old asymptomatic and healthy woman was found incidentally to have a lower mediastinal mass on a screening X-ray. A computed tomography scan revealed a 6.6 cm × 4.2 cm homogeneous mass in the distal esophagus (*Figure 1*). A barium study demonstrated a filling defect of 6.4 cm in the distal esophagus. Esophagogastroduodenoscopy/endoscopic ultrasound was performed, demonstrating a partially obstructing submucosal mass 34 cm from the incisors with a normal overlying mucosa. The EUS demonstrated a hypoechoic and homogeneous mass in the fourth layer (muscularis propria) of the distal esophageal wall with no lymph node enlargement. Results of preoperative cardiopulmonary function and laboratory tests were normal. There was no positive sign on physical examination. She had no medical history.

Operation steps

Anesthesia and body position

After the induction of general anesthesia, the patient was placed in a right lateral decubitus position under double-lumen endotracheal intubation. Her hands were placed in front of head, and she was placed in a Jackknife position

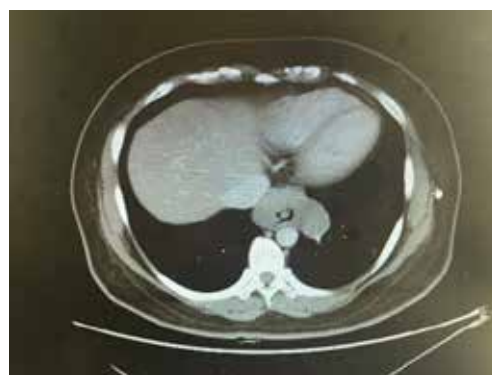

Figure 1 Computed tomography scan of the chest revealed a large homogeneous mass in the distal esophagus.

with single-lung (right) ventilation (*Figure 2*).

Ports

A 1.5-cm camera port (for a 12-mm trocar) was created in the 8th intercostal space (ICS) at left mid axillary line, and two 1.0-cm working ports (for 8-mm trocars) were made in the 10th ICS (#1 arm) at the left posterior axillary line and in the 9th ICS (#2 arm) at the left anterior axillary line. An auxiliary port (for a 12-mm trocar) was made in the 11th ICS

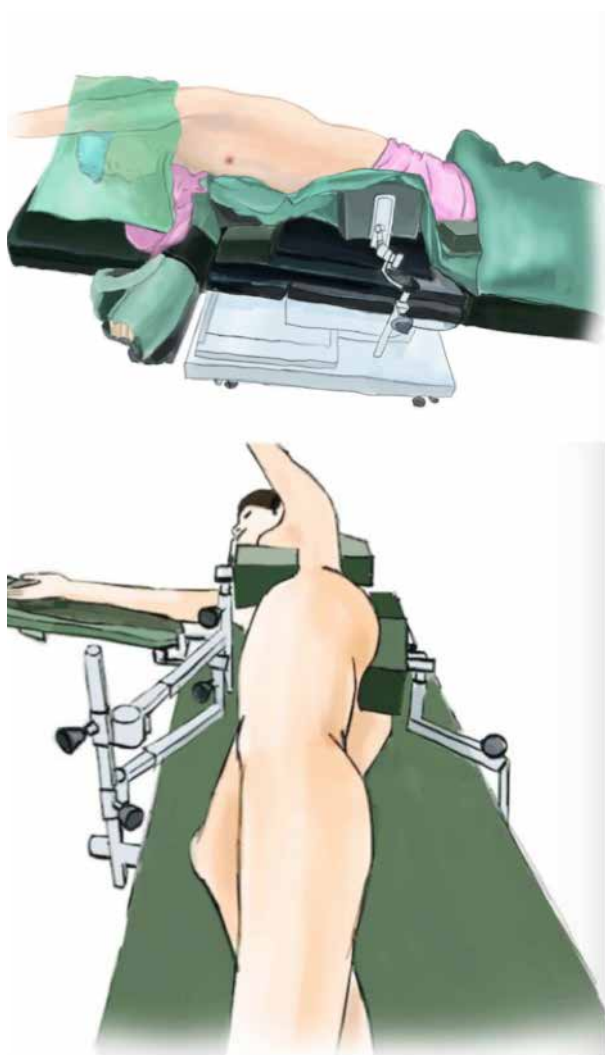


Figure 2 Right lateral decubitus and Jackknife position.

at the left posterior axillary line (*Figure 3*).

Installation of the surgical arms

After all the trocars were positioned, the robot was positioned directly above the operating table and then connected. The #2 arm was connected to a bipolar cautery forceps and the #1 arm was connected to a unipolar cautery hook.

Surgical procedure

See *Figures 4-11*.

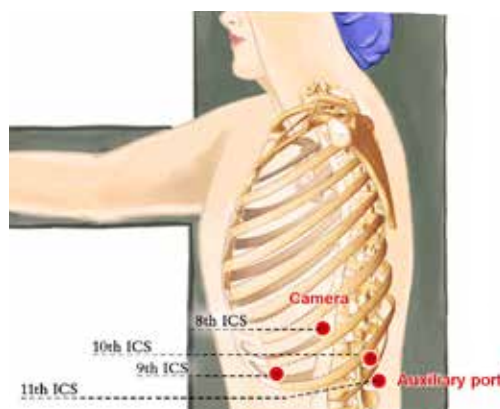


Figure 3 Ports in the 8th, 9th, 10th and 11th ICS. ICS, intercostal space.

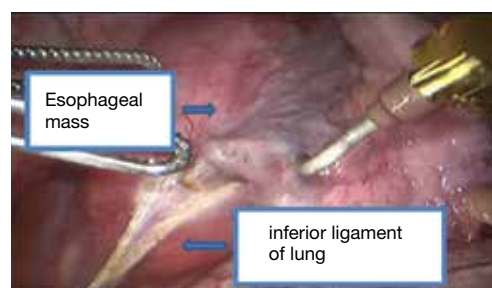


Figure 4 The large esophageal mass was clearly visualized on the border between the heart, diaphragm, and aorta.

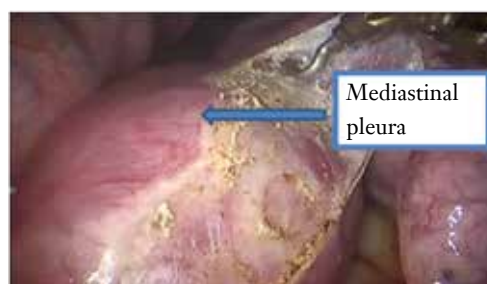

Figure 5 The mediastinal pleura overlying the esophagus was opened, and the tumor was freed from the mediastinal attachments.

Postoperative condition

Postoperative care included anti-inflammatory, and phlegm-resolving treatments. The chest cavity drainage tube was withdrawn after 2 days, and the patient started a liquid diet. The patient was discharged on postoperative

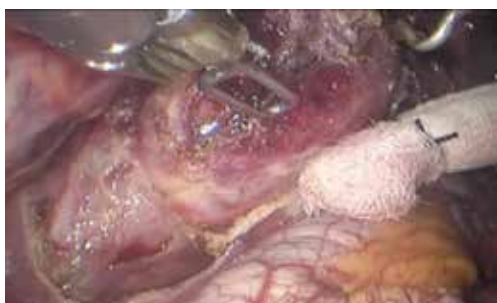

Figure 6 A longitudinal myotomy was performed, exposing a well-formed, smooth dumbbell-shaped lesion.

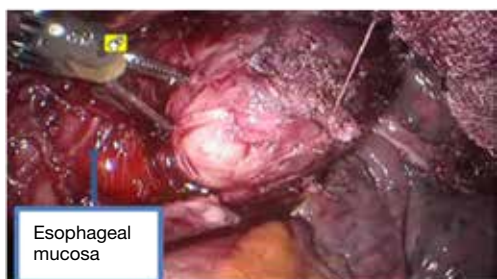

Figure 7 The lesion was separated from the surrounding muscle and then enucleated.

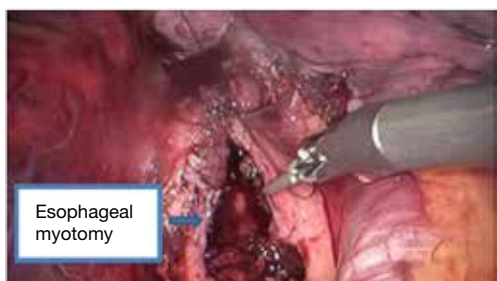

Figure 8 The esophageal myotomy was repaired with running sutures using PDS-II 3-0.

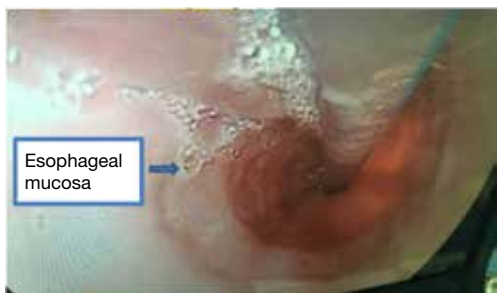

Figure 9 The integrity of the mucosa was confirmed by simultaneous intraoperative upper endoscopy.

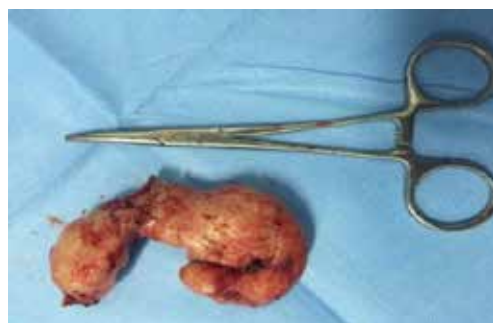

Figure 10 A 7 cm × 6 cm × 3 cm esophageal leiomyoma was confirmed on final pathology.

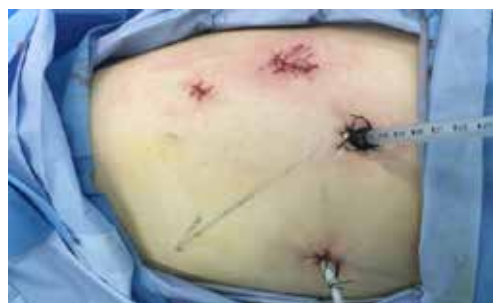

Figure 11 A chest cavity drainage tube was placed in the 11th ICS at the left mid axillary line, and a negative suction drainage was placed in the 9th ICS at the left anterior axillary line. ICS, intercostal space.

day 5 tolerating a semi-liquid diet. No complications were observed during hospitalization. Pathology confirmed an esophageal leiomyoma measuring 7 cm × 6 cm × 3 cm that was determined to be SMA, desmin and CD34-positive and CD117-, Ki67- and S-100-negative by immunohistochemistry.

Discussion

Leiomyoma, a rare esophageal neoplasm, is the most common benign esophageal neoplasm (1). Surgical resection is recommended in symptomatic case in which malignancy is suspected (2). The conventional treatment for esophageal leiomyoma is transthoracic enucleation by thoracotomy. However, open surgical approaches are associated with a high incidence of morbidities, significant postoperative pain, and long hospital stays. Over the years, minimally invasive surgery has more popular than conventional open thoracic surgery. However, these

techniques have potential limitations. The angles and narrow spaces between the ribs may restrict movement, suturing, and dissection with thoracoscopy (3). Recently, robot-assisted thoracoscopic surgery using the da Vinci robot system has provided improved visualization and dexterity in esophageal procedures. The first case of robot-assisted enucleation of two esophageal leiomyomas (4.5 cm × 2.0 cm and 3.2 cm × 2.6 cm) was reported in 2004 (4). The thoracic esophagus is located deep in the mediastinum and surrounded by major organs including the heart, lungs, airway, and aorta. The robotic approach has advantages over thoracoscopic enucleation, providing extra degrees of freedom in a confined space. A more precise dissection is allowed by the wrist-like movement of the robotic instruments, the three-dimensional view, and magnification of images. There were some important details in the surgical enucleation of esophageal leiomyomas. Simultaneous intraoperative endoscopy was the key to success for the operation. It allowed the exact localization of the tumor and evaluated the integrity of the mucosa once the tumor was enucleated. Another important detail was the repair of the myotomy after the enucleation. Repair of the myotomy prevented mucosal bulging and possible formation of a diverticulum. The wrist-like movement of the robotic instruments can easily perform the suturing and knot tying.

doi: 10.21037/amj.2017.01.15

Cite this article as: Zhang Y, Yang S, Guo W, Jin R, Chen X, Wu H, Du H, Han D, Chen K, Xiang J, Li H. Ruijin robotic thoracic surgery: robot-assisted enucleation of esophageal leiomyoma. AME Med J 2017;2:16.

Acknowledgements

None.

Footnote

Conflicts of Interest: The authors have no conflicts of interest to declare.

Informed Consent: Written informed consent was obtained from the patient for publication of this manuscript and any accompanying images.

References

1. Seremetis MG, Lyons WS, deGuzman VC, et al. Leiomyomata of the esophagus. An analysis of 838 cases. *Cancer* 1976;38:2166-2177.
2. Nemir P Jr, Wallace HW, Fallahnejad M. Diagnosis and surgical management of benign diseases of the esophagus. *Curr Probl Surg* 1976;13:1-74.
3. Kernstine KH, Andersen ES, Falabella A, et al. Robotic fourth-arm enucleation of an esoph-ageal leiomyoma and review of literature. *Innovations (Phila)* 2009;4:354-357.
4. Elli E, Espat NJ, Berger R, et al. Robotic-assisted thoracoscopic resection of esophageal leiomyoma. *Surg Endosc* 2004;18:713-716.

Robotic-assisted thoracoscopic thymectomy

Kai Chen, Su Yang, Wei Guo, Runsen Jin, Yajie Zhang, Xingshi Chen, Han Wu, Hailei Du, Dingpei Han, Jie Xiang, Hecheng Li

Department of Thoracic Surgery, Ruijin Hospital, Shanghai Jiao Tong University, School of Medicine, Shanghai 200025, China

Correspondence to: Hecheng Li, MD, PhD. Department of Thoracic Surgery, Ruijin Hospital, Shanghai Jiao Tong University, School of Medicine, 197 Ruijin Er Road, Shanghai 200025, China. Email: lihecheng2000@hotmail.com.

Abstract: We are going to share the experience of robotic-assisted thoracoscopic thymectomy. A 68-year-old patient underwent robotic-assisted thoracic surgery for a primary thymoma. The patient was discharged on postoperative day 3 without any perioperative complications. This case showed the robotic-assisted thoracoscopic thymectomy is a technically sound and safe approach for anterior mediastinal mass.

Keywords: Robotic-assisted thoracoscopic thymectomy

Received: 02 December 2016; Accepted: 27 December 2016; Published: 17 January 2017.

doi: 10.21037/amj.2017.01.16

View this article at: <http://dx.doi.org/10.21037/amj.2017.01.16>

Clinical data

A 68-year-old woman was referred to our hospital because of a chest computed tomography (CT) scan showing an abnormal shadow in the anterior mediastinum. She had no obvious symptoms except for a slight cough on exertion for a year. She had undergone an appendectomy and a fracture of the left tibia and fibula 16 years previously. Chest CT-scan showed a well-defined mass (18 mm × 12 mm) in the anterior mediastinum, in contact with left innominate vein (*Figure 1*). The homogenous contrast effect of the tumor had increased compared with itself half a year ago. The pulmonary function and other laboratory tests were normal. Differential diagnosis included thymoma, thymic carcinoma, and mediastinal cyst; therefore, surgical resection was recommended. Preoperative needle biopsy was not performed because of the deep location of the tumor. Informed consent for robotic-assisted thoracic lobectomy was obtained from patient before operation.

Procedure

We used two arms of the Da Vinci Robotic System and a 30° camera for thymectomies. The patient was anesthetized and intubated with a double-lumen endotracheal tube.

For the left Da Vinci surgical robotic approach, the patient was placed in a 45° right lateral decubitus position,

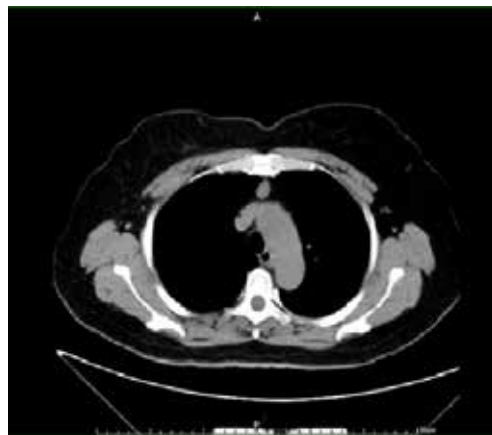


Figure 1 The mass located in the anterior mediastinum.

with sponge pads placed along the left scapula and behind the patient's hip. The arm of the patient was positioned parallel to the trunk, allowing for free access to the mid axillary line (*Figure 2*).

The camera port was made in the 6th intercostal space in the mid-axillary line. Then, the camera was inserted to explore the chest cavity and safely performed the other port incisions. The port for the left robotic arm was subsequently introduced under direct vision in the 8th intercostal space at the anterior axillary line, and the port of right arm was created in the 4th intercostal space at the mid axillary line

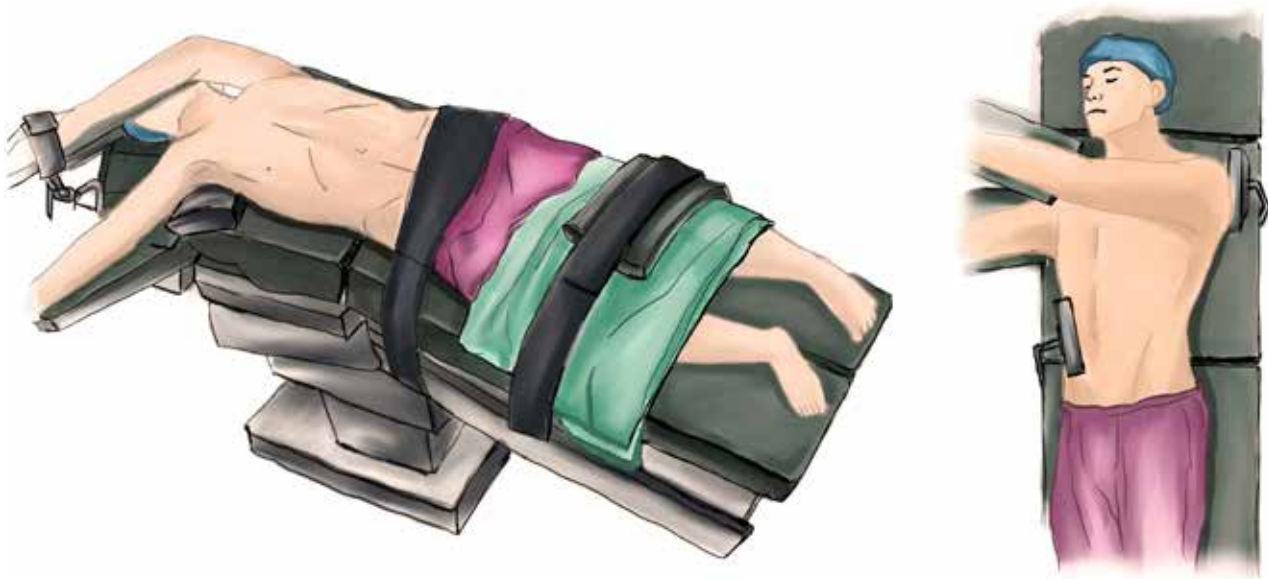


Figure 2 45° right lateral decubitus position.

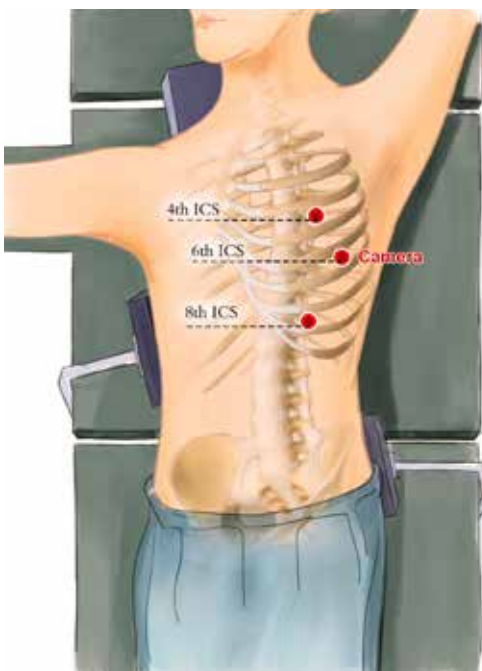


Figure 3 Ports in the 4th, 6th, and 8th ICS. ICS, intercostal space.

(Figure 3).

For the left arm, which was mainly used to grasp the adjacent tissue of the tumor, an Endo-Wrist instrument was used, and for the right arm, which was used to perform the dissection, an Endo-hook device with electric cautery

function was mainly used (Figures 4-11).

After irrigation with warm saline solution, a 32F drainage tube was placed through the incision of the 8th intercostal space. The other incisions were closed.

Postoperative outcome

The patient received phlegm-resolving treatments postoperatively, and the thoracic drainage tube was withdrawn on the second day after surgery. The patient was discharged from the hospital on the third day.

Comment

There have been numerous articles on the efficacy of robotic surgery for mediastinal diseases in recent years. The Da Vinci Surgical System offers a clear benefit compared with video-assisted thoracoscopic surgery and in small well-circumscribed tumours, even with an open approach. Because of the three-dimensional, high definition view and better maneuverability and dexterity of the robotic platform, the surgeon is able to perform surgery with high precision (1).

Thymoma patients may have symptoms of myasthenia gravis (MG) during the perioperative period. It is impossible to overstate the importance of a radical thymectomy for the MG patients. The robotic approach allows for a radical

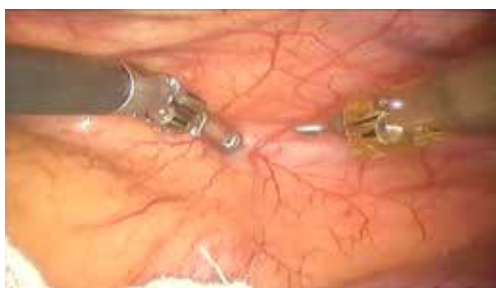

Figure 4 Once the camera and arms had been placed and the mediastinal structures identified, dissection began with the left thymic lobe. The mediastinal pleura was opened anterior to the phrenic nerve and posterior to the mammary vessels with a coagulation hook.

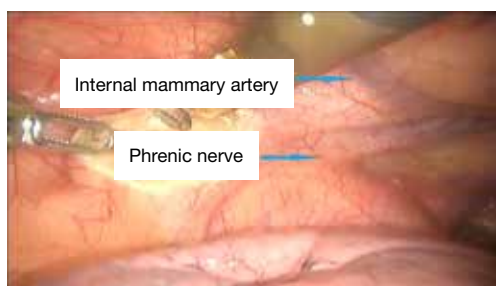


Figure 5 Sharp dissection was performed posterior and then anterior to the gland.

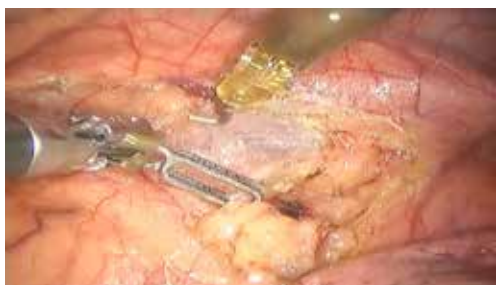

Figure 6 It was difficult to dissect the upper part of the gland until the left horn had been pulled down from the neck. The left cervical horn was displaced more posteriorly than the right horn because of the contour of the ascending aorta.

thymectomy which could improve the complete remission rate for MG when compared with the conventional thoracoscopic technique (2).

Because a radical thymectomy is achievable from one side only when using a robotic system, choice of the side is a

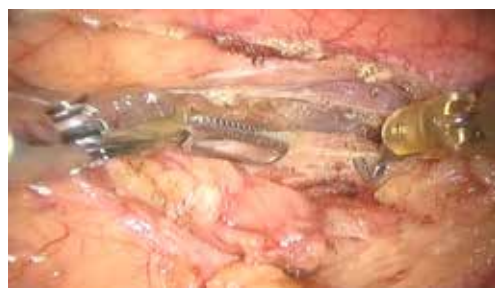

Figure 7 The lateral extent of the innominate vein was usually hidden by mediastinal fat on the left. After the left pole had been dissected, the left innominate vein and the thymic veins could be found.

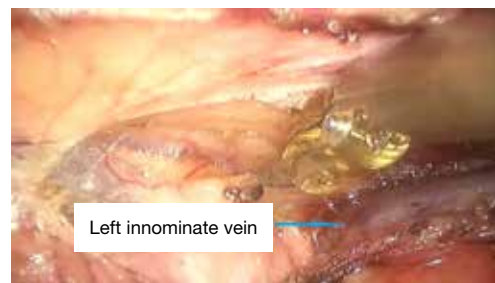

Figure 8 The right phrenic nerve could be found lateral or just anterior to the superior vena cava from the left approach. This nerve can be injured by blunt traction if the clamps extend beyond the right lateral margin of the gland. This injury can be avoided by pushing the right mediastinal pleura off the right lateral side of the horn and then off the lateral side of the right lobe. The most difficult part of thymectomy from the left-sided approach was dissection at the junction between the innominate vein and superior vena cava.

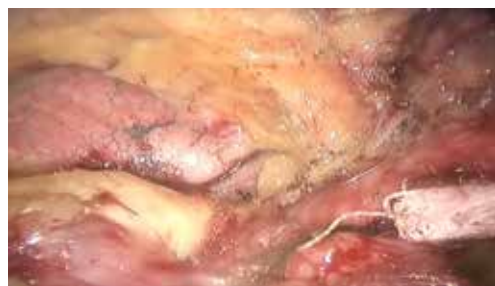

Figure 9 The left arm grasped the right lobe with gentle traction toward the left side, dissecting it sharply away from the right phrenic nerve.

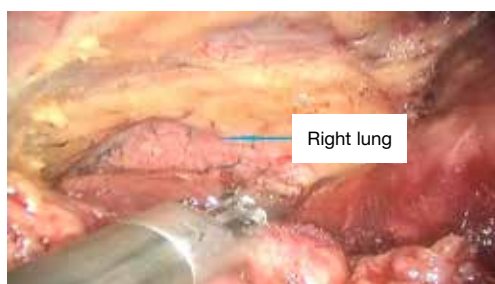


Figure 10 A small portion of the parathymic fat was removed along with the surgical specimen, taking care not to injure the phrenic nerve.

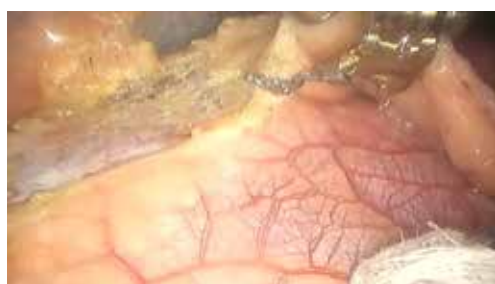

Figure 11 The gland was completely resected with the surrounding adipose tissues.

key issue. The anatomic considerations for the distribution of thymic tissue and the surgeon's preference are the major factors that guide the choice (3-5).

Factors supporting a left-sided approach include thymic tissue extending lateral to or under the left phrenic nerve (6), up to the cardiophrenic area which requires more dissection on the left side, and ectopic thymic tissue in the aortopulmonary window.

The advantage of a right-sided approach include better visualization of the junction between the innominate vein and superior vena cava, better visualization and dissection of the aortocaval groove, and better ergonomic position to accomplish dissection in the caudal-to-cephalad direction from the right side.

If the tumor is located in the middle or the left side of the body, we choose the left side for robotic-assisted thoracoscopic resection of the thymoma. If the tumor is located in the right side of the body, we choose the right side for robotic-assisted thoracoscopic resection of the thymoma. In patients without MG, in whom contralateral pericardial fat cannot be approached, we dissect the perithymic fat.

We have performed more than ten robotic thymectomies without any conversion to median sternotomy or thoracotomy. Unilateral left-sided 3-port approach was used in most patients.

In conclusion, complete resection of thymomas and adjacent tissues with the da Vinci Surgical System is feasible and safe, and the short-term outcomes such as hospital stay and complication rate were favorable.

Acknowledgements

None.

Footnote

Conflicts of Interest: The authors have no conflicts of interest to declare.

Informed Consent: Written informed consent was obtained from the patient for publication of this manuscript and any accompanying images.

References

1. Schneiter D, Tomaszek S, Kestenholz P, et al. Minimally invasive resection of thymomas with the da Vinci® Surgical System. *Eur J Cardiothorac Surg* 2013;43:288-292.
2. Rückert JC, Swierzy M, Ismail M. Comparison of robotic and nonrobotic thoracoscopic thy-mectomy: a cohort study. *J Thorac Cardiovasc Surg* 2011;141:673-677.
3. Ismail M, Swierzy M, Rückert JC. State of the art of robotic thymectomy. *World J Surg* 2013;37:2740-2746.
4. Cerfolio RJ, Bryant AS, Minnich DJ. Starting a robotic program in general thoracic surgery: why, how, and lessons learned. *Ann Thorac Surg* 2011;91:1729-1736; discussion 1736-1737.
5. Mack MJ. Video-assisted thoracoscopy thymectomy for myasthenia gravis. *Chest Surg Clin N Am* 2001;11:389-405. xi-xii.
6. Ismail M, Swierzy M, Rückert RI, et al. Robotic thymectomy for myasthenia gravis. *Thorac Surg Clin* 2014;24:189-195. vi-vii.

doi: 10.21037/amj.2017.01.16

Cite this article as: Chen K, Yang S, Guo W, Jin R, Zhang Y, Chen X, Wu H, Du H, Han D, Xiang J, Li H. Robotic-assisted thoracoscopic thymectomy. *AME Med J* 2017;2:4.

Robot-assisted surgery for posterior superior mediastinal mass

Wei Guo, Su Yang, Runsen Jin, Yajie Zhang, Xingshi Chen, Han Wu, Hailei Du, Dingpei Han, Kai Chen, Jie Xiang, Hecheng Li

Department of Thoracic Surgery, Ruijin Hospital, Shanghai Jiao Tong University, School of Medicine, Shanghai 200025, China

Correspondence to: Hecheng Li, MD, PhD. Department of Thoracic Surgery, Ruijin Hospital, Shanghai Jiao Tong University, School of Medicine, 197 Ruijin Er Road, Shanghai 200025, China. Email: lihecheng2000@hotmail.com.

Abstract: We are going to share the experience of robotic surgery for mediastinal mass. A 40-year-old patient underwent robotic-assisted thoracic surgery for a posterior superior mediastinal mass. The patient was discharged on postoperative day 2 without any perioperative complications. The pathological diagnosis was mediastinal neurofibroma. Our result showed the robotic thoracic surgery of the posterior superior mediastinal mass was efficient and reliable.

Keywords: Robot-assisted surgery; mediastinal mass; thoracic surgery

Received: 02 December 2016; Accepted: 27 December 2016; Published: 07 February 2017.

doi: 10.21037/amj.2017.01.17

View this article at: <http://dx.doi.org/10.21037/amj.2017.01.17>

Clinical data

Medical history

A 40-year-old woman was admitted to our hospital because of a posterior mediastinal mass. She had undergone a physical examination in a local hospital 1 month previously and received a diagnosis of a posterior mediastinal mass. One week previously she underwent a second contrast-enhanced computed tomography (CT) scan in our hospital, which showed a posterior mediastinal mass that measured 3.9 cm × 2.4 cm. She had no comorbidities such as diabetes, hypertension or heart disease.

Physical, laboratory and imaging examination

Physical examination

Body temperature was 36.8 °C. Heart rate was 92 beats per minutes. Respiratory rate was 20 breaths per minutes. Blood pressure was 130/78 mmHg. There was no positive sign detected during the physical examination.

Laboratory texts

Results of laboratory texts upon admission were negative.

Imaging examination

Chest contrast-enhanced CT (*Figure 1*): an oval soft-tissue

density mass was found in the right posterior superior mediastinum. It measured 3.9 cm × 2.4 cm and had homogeneous density and smooth margin. No contrast-enhanced signal was found in the opacity.

Preoperative preparation

Conventional skin preparation and preoperative education were performed.

Procedures

Anesthesia and body position

The operation was conducted using general anesthesia. The patient was placed slightly forward in the left lateral recumbent position with single-lung ventilation. Conventional disinfection and draping were performed.

Incision ports

A 1.2 cm camera port was placed at the 5th intercostal space at the right mid-axillary line. Another two 0.8 cm utility ports were created. One of them was between the right posterior axillary line and the subscapular line, in the 8th intercostal space. The other one was at the 3th intercostal space between the anterior axillary line and

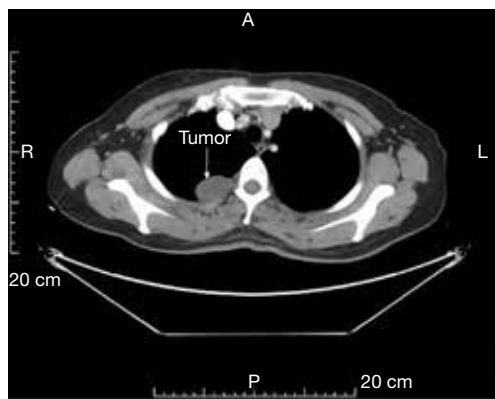


Figure 1 Posterior opacity was detected in the contrast enhanced CT.

midclavicular line.

Operation procedure

- (I) The thoracic cavity was inspected and checked for pleural adhesion. An 8-mm artificial pneumothorax was established. The 1st robotic arm was connected to a unipolar cautery hook, and the 2nd robotic arm was connected to a bipolar cautery forceps. The mass and its relation to adjoining tissues and organs were inspected.
- (II) The mediastinal pleura was opened and the tumor was dissociated along its edge.
- (III) The tumor was completely resected.
- (IV) Hemostasis of the tumor bed was achieved.
- (V) The dissected tumor was harvested.
- (VI) The thoracic cavity was lavaged and the emphysema was inspected.
- (VII) An indwelling drainage tube was placed in the camera port. The robot system was withdrawn. The chest was closed after sputum suction and lung recruitment. Total intraoperative blood loss was 5 mL.

Postoperative treatment

After the surgery, the patient received conventional adjuvant remedy. The drainage on postoperative day 1 was 20 mL. The patient was extubated on postoperative day 1. No postoperative morbidity was observed.

Pathologic diagnosis

Morphology: the mediastinal mass was 4 cm × 3 cm ×

1.5 cm. The mass substance was moderately hard and looked like tofu. The pathologic diagnosis was mediastinal neurofibroma.

Commentary

For this patient, robotic thoracic surgery was safe and efficient. Compared with traditional video-assisted thoracoscopic surgery (VATS), the robotic system provides a clearer and more intuitive enhanced three-dimensional vision and seven degrees of freedom of the robotic arms (1). These advantages improved the ability to dissociate the mediastinal tumor and perform subtle dissection in a confined space. Furthermore, although the incision length is the same as that required for VATS, the robotic surgery caused less friction and injury to the intercostal nerve. It has been 14 years since Ichiro Yoshino conducted the first robotic-assisted extirpation of a posterior mediastinal mass in 2002 (2). Since then, additional studies have confirmed the feasibility, reliability, and superiority of this method (3-5). Furthermore, the learning curve of robotic thoracic surgery for a posterior mediastinal mass is quite short (4). However, to confirm the advantage of robotic surgery regarding postoperative and long-term survival, high-volume design, pain score, and use of postoperative anesthetic and long-term follow up is still needed.

Acknowledgements

None.

Footnote

Conflicts of Interest: The authors have no conflicts of interest to declare.

Informed Consent: Written informed consent was obtained from the patient for publication of this manuscript and any accompanying images.

References

1. Schmid T. Robotic Surgery Eur Surg 2002;3:155-157.
2. Yoshino I, Hashizume M, Shimada M, et al. Video-assisted thoracoscopic extirpation of a posterior mediastinal mass using the da Vinci computer enhanced surgical system. Ann Thorac Surg 2002;74:1235-1237.

3. Bodner J, Wykypiel H, Greiner A, et al. Early experience with robot-assisted surgery for mediastinal masses. *Ann Thorac Surg* 2004;78:259-265; discussion 265-266.
4. Cerfolio RJ, Bryant AS, Minnich DJ. Operative techniques in robotic thoracic surgery for inferior or posterior mediastinal pathology. *J Thorac Cardiovasc Surg* 2012;143:1138-1143.
5. Al-Mufarrej F, Margolis M, Tempesta B, et al. Novel thoracoscopic approach to difficult posterior mediastinal tumors. *Gen Thorac Cardiovasc Surg* 2010;58:636-639.

doi: 10.21037/amj.2017.01.17

Cite this article as: Guo W, Yang S, Jin R, Zhang Y, Chen X, Wu H, Du H, Han D, Chen K, Xiang J, Li H. Robot-assisted surgery for posterior superior mediastinal mass. *AME Med J* 2017;2:10.

From manual to robotic video-assisted resection of posterior mediastinal masses

Giulia Veronesi, Michela Solinas

Division of Thoracic and General Surgery, Humanitas Clinical and Research Center, via Manzoni 56, 20089 Rozzano, MI, Italy

Correspondence to: Giulia Veronesi. Division of Thoracic and General Surgery, Humanitas Cancer Center, Via Manzoni 56, 20089, Rozzano, MI, Italy.

Email: giulia.veronesi@humanitas.it.

Provenance: This is an invited Editorial commissioned by Section Editor Jianfei Shen, MD (Department of Cardiothoracic Surgery, Taizhou Hospital of Zhejiang Province, Wenzhou Medical University, Taizhou, China).

Comment on: Guo W, Yang S, Jin R, *et al.* Robot-assisted surgery for posterior superior mediastinal mass. AME Med J 2017;2:10.

Submitted Aug 09, 2017. Accepted for publication Aug 14, 2017.

doi: 10.21037/jtd.2017.08.118

View this article at: <http://dx.doi.org/10.21037/jtd.2017.08.118>

Guo and colleagues described the technique of a robotic-assisted resection of a posterior mediastinal mass, using a three arms robotic approach with the aid of CO₂ insufflation, and concluded that this approach was efficient and reliable (1). During the last 10–15 years the robotic-assisted approach has become a consolidated alternative technique to traditional video-assisted surgery and open approach, for the treatment of many thoracic diseases (2).

Posterior mediastinal masses are in the majority of cases represented by intrathoracic neurogenic tumors (75% to 95%), that count for about 19%–39% of all mediastinal tumors (3,4). Malignancy rate is very low, reported in around 4% of the cases, and the lesions are often completely asymptomatic (3,5). In around 20% of cases excessive enlargement of the lesions can cause compression of neighbouring structures, bone erosion or spinal invasion, causing symptoms like chest pain, cough, dyspnoea, dysphagia, Horner's syndrome or neurological abnormalities (5,6). Generally neurogenic tumors are grouped in three categories, according to their site of origin. Those originating from peripheral nerves are neurofibroma, schwannoma or neurilemmoma, neurofibrosarcoma and neuroma (a post-traumatic lesion, appearing at the end of the severed nerve). The lesions that origin from sympathetic ganglia are neuroblastoma, ganglioneuroma and ganglioneuroblastoma. Finally, neurogenic tumors can rarely origin from parasympathetic ganglia like paraganglioma (3,7,8).

Once the traditional surgical treatment was a complete

resection with a wide posterolateral thoracotomy and division of latissimus dorsi muscle (3). This choice is still today considered by many surgeons in case the tumor is large, it invades intraspinal tissues (the so-called “dumb-bell tumor”), it is localized in narrow spaces of the mediastinum, the first or second rib cannot be visualized and in case of pleural adhesion or bleeding (9,10). In case of a dumb-bell tumor, because of the intraspinal invasiveness, the combination of neurosurgical and thoracic approach is sometimes necessary to minimize morbidity and mortality (3,6). A supraclavicular approach is recommended for the resection of tumors arising from the brachial plexus (11). One of the alternatives to the posterolateral thoracotomy was the less invasive transaxillary approach described by Becker and Munro (12) to treat 13 cases of mediastinal tumors, including neurogenic lesions. These were resected extrapleurally with reduction of postoperative pain, less morbidity and quicker return to normal activity compared to the traditional posterolateral thoracotomy (12).

Despite the many efforts to make the traditional surgical technique less traumatic, the need for innovative and increasingly minimally invasive techniques began to be felt. With the advent of video-assisted thoracoscopy (VATS) before and robotic-assisted thoracoscopy (RATS) after, the minimally invasive techniques started to be considered even for the excision of posterior mediastinal lesions (3).

After the publication of Landrenau's report in 1992 the VATS for the excision of mediastinal lesions has been

widely accepted (13,14). Conventional thoracoscopy allows visualization and removal of these lesions with small instruments and scope ports and less muscle injury. Large reviews on the video-assisted thoracoscopic resection of posterior mediastinal tumor showed that the VATS approach was feasible and safe with reduced duration of hospital stay and chest tube maintenance, with less morbidity and mortality for the patient (15).

A contraindications to VATS approach, as cited by Roviato *et al.* (16), should be considered the presence of malignant features for the risk of local recurrences and bad prognosis (5,16). Others considered that contraindications should not be related to the degree of malignancy, but rather to the dimension of the mass and to the presence of intraspinal growth (13).

According to the dimension, Li and Wang (17) reported their experience with 58 patients. They established a cut off of 6 cm for tumors of the apex to undergo easy and complete thoracoscopic resection, over which operative time, blood loss and the incidence of post-operative complications were increased, and concluded that tumor diameter is the principal determinant for surgical indication to VATS (17). Conversely, a recent experience by Ciriaco and co-workers (8) demonstrated the excision of 7–8 cm posterior mass via thoracoscopic surgery, simply enlarging one of the thoracoscopic access, and using an endo-bag to facilitate the passage through the incision and avoiding seeding.

About intraspinal invasiveness Vernissac and colleagues (13) have demonstrated that a combined video-thoracoscopic approach with neurosurgical laminectomy is feasible and safe. Their 10-year experience shows the radicality and safety of VATS procedure, even for the resection of apical lesions, close to Adamkiewicz artery (5,10,13). In fact, low mediastinal posterior tumors may take origin near this important artery. This vessel, also called arteria radicularis magna, origins from the posterior branches of the intercostal arteries at a level that varies mainly between T8 and L1 with major incidence on the left side (70%) (18). Loss of this artery could lead to spinal cord injuries or ischemia (10,17). A coordinated approach with neurosurgeons is important for a successful excision of these tumors and better outcome.

With the advancement of the sophisticated technology of computer mediated surgery and the ascending development of the robotic devices, the technical limitations of manual VATS became more and more evident. These limitations render the dissection not so intuitive and easy, in particular

because these tumors are characterized by strong adhesions and often narrow sites (9,19). Cerfolio *et al.* assert that posterior neurogenic tumors are difficult to remove both robotically and thoracoscopically and underline the additional difficulty in VATS to introduce the surgeons fingers or ports because ribs are closer together posteriorly (20). For these reasons robotic technique can extend the ability in the mediastinum, thanks to three-dimensional visualisation, dexterity and more accurate dissection, allowing resection of posterior mediastinal tumors, that, otherwise, would require an open resection (9).

In literature there are still limited experiences describing robotic-assisted excision of posterior mediastinal lesions (5,9,19,21). The first case of robotic resection of such a lesion was about a bronchogenic cyst, described by Yoshino and colleagues in 2002 (19). After this case other series or case reports have been described (20,22) showing that robotic was comparable, if not superior, to VATS in terms of morbidity, hospitalisation and conversion rate.

One aspect to consider with RATS is the need for the surgeon to adapt an advantageous technique to the anatomical features of the mediastinum. Cerfolio claims that the usual robotic pattern, used for lung resections, is not good for posterior mediastinal lesions. According to the site of the lesion, his proposal is to place the camera anteriorly and the robot posteriorly; in his opinion this easier scheme is not widespread used because many teams are unaware of it (20). Another workaround is the use of CO₂-insufflation, that is often recommended but not always necessary, like in the case reported by Nguyen and coworkers (23), who are used to insert robotic tools directly through the access without trocars. Moreover, according to the experience described by Al-Muffarej and colleagues (9), RATS approach is their main choice for excision of posterior mediastinal tumors, thanks to the numerous advantages of the same techniques (i.e., endowrist instruments) (9), with the only exception of extremely large tumors (>10 cm), in which an open approach is recommended. In case of robotic resection of an apical mass, at the level of the third rib or higher, they recommend to leave the apical portion as the last area mobilized. In this way, more traction can be applied on its apical portion, while dissecting it, avoiding potential damage to the stellate ganglion and subclavian vessels (9).

On the other hands, drawbacks of robotic technique has also been described; it is expensive, needs a specialized surgical team and it lacks tactile feedback (9).

Regarding the high costs to date, only one producer has marketed a robotic devices, Intuitive Surgical's da Vinci

system (Sunnyvale, CA, USA), but new robots are being developed by Medtronic and by Verbsurgical. The entry of these new systems, hopefully along with others, into the market is highly desirable and will determine the reduction of costs and, hence, permit this technology to become available for the wider community (22).

The robotic apparatus requires meticulous preparation in terms of set-up and placement at the operating table and the transition from traditional surgery to totally robot-assisted surgery is not immediate. Thus a precise organizational and didactic routes must be followed with dedicated courses that provide the surgeons and surgical teams with confidence when operating with the robotic system. After the initial theory course, the use of a simulator is an important step in learning robot-assisted procedures and training at the console becomes the surgeon's first real contact with robot-assisted surgery. The most frequent procedure used in the initial phase of the learning curve is just the treatment of mediastinum lesions, like neurinomas as Cerfolio *et al.* suggest (21). These procedures represent an ideal training model because they provide the means for learning basic procedures combined with a relatively simple technique.

The lack of tactile feed-back remains unsolved today, although technology is available, it seems not to be affordable on large-scale, due to cost issues and to the fragility of the sophisticated sensors that must be applied at the tip of each instruments. We must note that the other technical advantages of the robotic system like the high degrees of movement freedom, dexterity, and improved visualisation, largely compensate the lack of tactile feedback.

The case report described by Guo *et al.* at the Ruijin Hospital of Shanghai is another example of the effectiveness of the excision of a neurogenic tumor, a neurofibroma, by robotic-assisted technique, without postoperative complications and morbidity for the patient. They describe the surgical approach and the trocar ports positioning and underline the very low blood loss both intraoperatively and postoperatively. We agree with the authors that RATS facilitate neurogenic tumors resection, particularly those in extreme site of the mediastinum as underlined by other investigators (24). The possibility to have interchangeable and precise instruments permits to resect lesion also in small spaces and close to important structures. Finally, the operation timing and learning curve applied to posterior mediastinal tumors are reasonable (25).

Even if the thoracoscopic accesses appear to be the same, when using the robot, there is less fractioning with intercostal nerve, less pain for the patient and consequent

lower utilisation of analgesics compared to VATS.

All these aspects can potentially translate into a favourable cost-effectiveness ratio in a near future, when the number of robotic procedures will be substantially increased in thoracic surgery and the new robotic systems will be available on the market with the promise of reducing the costs. To increase the evidence of the benefits of robotic versus manual VATS and open procedures, further experience is required, and prospective comparative studies with assessment of pain, quality of life and costs are needed.

Acknowledgements

The authors thanks Elisa Dieci for her help in the editing of the paper.

Footnote

Conflicts of Interest: G Veronesi has financial relationship with Abi Medica, Medtronic and Verb Surgical; M Solinas has no conflicts of interest to declare.

References

1. Guo W, Yang S, Jin R, et al. Robot-assisted surgery for posterior superior mediastinal mass. *AME Med J* 2017;2:10.
2. Cerfolio R, Louie BE, Farivar AS, et al. Consensus statement on definitions and nomenclature for robotic thoracic surgery. *J Thorac Cardiovasc Surg* 2017;154:1065-1069.
3. Strollo DC, Rosado-de-Christenson ML, Jett JR. Primary Mediastinal Tumors. Part II. Tumors of the Middle and Posterior Mediastinum. *Chest* 1997;112:1344-1357.
4. Yamaguchi M, Yoshino I, Fukuyama S, et al. Surgical treatment of neurogenic tumors of the chest. *Ann Thorac Cardiovasc Surg* 2004;10:148-151.
5. Ng CS, Wong RH, Hsin MK, et al. Recent advances in video-assisted thoracoscopic approach to posterior mediastinal tumours. *Surgeon* 2010;8:280-286.
6. Abdel Rahman AR, Sedera MA, Mourad IA, et al. Posterior Mediastinal Tumors: Outcome of Surgery. *J Egypt Natl Canc Inst* 2005;17:1-8.
7. Kuhlman JE, Bouchardy L, Fishman EK, et al. CT and MR Imaging Evaluation of Chest Wall Disorders. *Radiographics* 1994;14:571-595.
8. Pavlus JD, Carter BW, Tolley MD, et al. Imaging of Thoracic Neurogenic Tumors. *AJR Am J Roentgenol*

- 2016;207:552-561.
9. Al-Mufarrej F, Margolis M, Tempesta B, et al. Novel thoracoscopic approach to difficult posterior mediastinal tumors. *Gen Thorac Cardiovasc Surg* 2010;58:636-639.
 10. Ciriaco P, Negri G, Bandiera A, et al. Videothoracoscopic Resection of Benign Neurogenic Tumors of the Posterior Mediastinum. *Innovations (Phila)* 2006;1:332-334.
 11. Liu Y, Lu T, Fan H, et al. Surgical approaches to non-thyrogenic and non-thymic mediastinal tumors of the thoracic Inlet. *Thorac Cardiovasc Surg* 2016. [Epub ahead of print].
 12. Becker RM, Munro DD. Transaxillary minithoracotomy: the optimal approach for certain pulmonary and mediastinal Lesions. *Ann Thorac Surg* 1976;22:254-259.
 13. Venissac N, Leo F, Hofman P, et al. Mediastinal neurogenic tumors and video-assisted tho-racoscopy: always the right choice? *Surg Laparosc Endosc Percutan Tech* 2004;14:20-22.
 14. Bousamra M 2nd, Haasler GB, Patterson GA, et al. A comparative study of thoracoscopic vs open removal of benign neurogenic mediastinal tumors. *Chest* 1996;109:1461-1465.
 15. Hazelrigg SR, Nunchuck SK, LoCicero J 3rd. Video-assisted thoracic surgery study group data. *Ann Thorac Surg* 1993;56:1039-1043; discussion 1043-1044.
 16. Roviario G, Rebuffat C, Varoli F, et al. Videothoracoscopic excision of mediastinal masses: indications and technique. *Ann Thorac Surg* 1994;58:1679-1683; discussion 1683-1684.
 17. Li Y, Wang J. Experience of video-assisted thoracoscopic resection for posterior mediastinal neurogenic tumours: a retrospective analysis of 58 patients. *ANZ J Surg* 2013;83:664-668.
 18. Shadmehr MB, Gaissert AH, Wain JC, et al. The surgical approach to "Dumbbell Tumors" of the mediastinum. *Ann Thorac Surg* 2003;76:1650-1654.
 19. Yoshino I, Hashizume M, Shimada M, et al. Video-assisted thoracoscopic extirpation of a posterior mediastinal mass using the da Vinci computer enhanced surgical system. *Ann Thorac Surg* 2002;74:1235-1237.
 20. Cerfolio RJ, Bryant AS, Minnich DJ. Operative techniques in robotic thoracic surgery for in-ferior or posterior mediastinal pathology. *J Thorac Cardiovasc Surg* 2012;143:1138-1143.
 21. Cerfolio RJ, Bryant AS. How to teach robotic pulmonary resection. *Semin Thorac Cardiovasc Surg* 2013;25:76-82.
 22. Veronesi G, Novellis P, Voulaz E, et al. Robot-assisted surgery for lung cancer: State of the art and perspectives. *Lung Cancer* 2016;101:28-34.
 23. Nguyen DC, Garagozlo C, Moslemi M, et al. Robotic resection of a superior sulcus neurogenic tumor. *Innovations (Phila)* 2015;10:142-145.
 24. Pacchiarotti G, Wang MY, Kolcun JP, et al. Robotic paravertebral schwannoma resection at extreme locations of the thoracic cavity. *Neurosurg Focus* 2017;42:E17.
 25. Ruurda JP, Hanlo PW, Hennipman A, et al. Robot-assisted thoracoscopic resection of a be-nign mediastinal neurogenic tumor: technical note. *Neurosurgery* 2003;52:462-464; discus-sion 464.

Cite this article as: Veronesi G, Solinas M. From manual to robotic video-assisted resection of posterior mediastinal masses. *J Thorac Dis* 2017;9(9):2884-2887. doi: 10.21037/jtd.2017.08.118

Robot-assisted surgery for posterior mediastinal mass

Carmelina Cristina Zirafa, Franca Melfi

Department of Surgical, Medical, Molecular Pathology and of Critical Area, University of Pisa, Pisa, Italy

Correspondence to: Carmelina Cristina Zirafa; Franca Melfi. Department of Surgical, Medical, Molecular Pathology and of Critical Area, University of Pisa, Pisa, Italy. Email: c.zirafa@gmail.com; franca.mamelfi@gmail.com.

Provenance: This is an invited Editorial commissioned by Section Editor, Jianfei Shen, MD (Department of Cardiothoracic Surgery, Taizhou Hospital of Zhejiang Province, Wenzhou Medical University, Taizhou, China).

Comment on: Guo W, Yang S, Jin R, *et al.* Robot-assisted surgery for posterior superior mediastinal mass. AME Med J 2017;2:10.

Submitted Oct 04, 2017. Accepted for publication Oct 23, 2017.

doi: 10.21037/jtd.2017.10.160

View this article at: <http://dx.doi.org/10.21037/jtd.2017.10.160>

In the last decade, robotic surgery is increasingly becoming an essential instrument in the hands of thoracic surgeons. Indeed, the Robotic Surgical Systems (da Vinci, Intuitive Surgical, Inc., Sunnyvale, CA, USA), particularly the latest models, the SI system and the latest XI system, are used to perform lung resection and exeresis of mediastinal lesions (1-3). Thanks to their features it is possible to work in a comfortable and secure manner in narrow spaces, such as the anterior mediastinum, or in remote areas, such as the posterior mediastinum or the costal-phrenic areas. Robotic surgery allows a mini-invasive approach overcoming the limits that characterize video-assisted thoracic surgery (e.g., complex maneuverability of the instruments in close or deep spaces, 2-dimensional and limited vision). As a matter of fact, surgical procedures are easier thanks to the 3D magnified vision, the surgeon's direct control of the camera, the possibility to have instruments with a large range of articulation and movements, the filtration of the physiological tremor of the hands (4,5).

Currently, the use of robotic surgery to remove mediastinal lesions has become a routine choice, guaranteeing excellent results. Several Authors have described the robotic surgical technique and its results for the treatment of anterior mediastinal lesions, in particular of the thymic gland disease (6-8). However, only few authors have reported their experience on the application of robotic system for posterior mediastinal tumors (9,10).

Neurogenic tumors are the most common type of posterior mediastinal lesions. In most cases, the patients are asymptomatic and the diagnosis is accidental. Usually the neoplasm is benign, well defined, localized in a paravertebral

area, arising from peripheral nerves, as intercostal nerve, or sympathetic nerves (*Figure 1*). Other lesions located in the posterior mediastinum can be cysts, esophageal tumors, lymphadenopathy, infectious or inflammatory lesions (11).

Despite the uncomfortable site, the removal of the masses localized in the posterior mediastinum using robotic technique is usually described as a simple and safe procedure. For these characteristics this kind of procedure could therefore represent the first step of the learning curve for the surgeon starting a thoracic robotic program (12).

The authors described different port mapping (9,12-15).

The exeresis of posterior mediastinal lesions consists of three or four centimetric surgical ports. Guo *et al.* illustrated an approach with three surgical accesses: camera port at 5th intercostal space at mid-axillary line, the posterior port in 8th intercostal space, at the midpoint between posterior axillary line and subscapular line, and the anterior port at 3th intercostal space between anterior axillary line and midclavicular line (16).

To obtain a standardization of technique, a useful port mapping could be the port mapping used also for lung resection. After the intubation, the patient must be positioned in lateral decubitus, with operating table flexed at the level of the inferior border of the scapula. The positioning is mandatory in order to obtain the alignment of the scapula and the hip, preventing potential injuries to the hip and the camera port.

The camera port is positioned in the 7th or 8th intercostal space on the posterior axillary line using a 30° camera. When possible, given the variability the chest wall, the posterior ports are positioned in the same intercostal space,

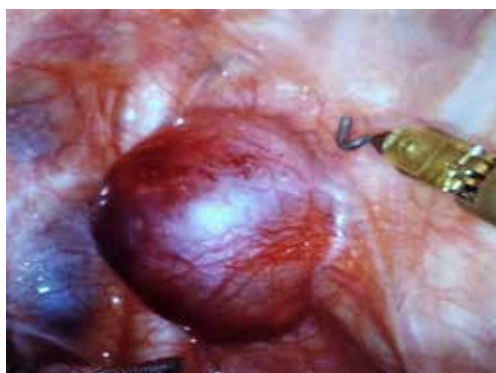

Figure 1 Posterior mediastinal mass (schwannoma).

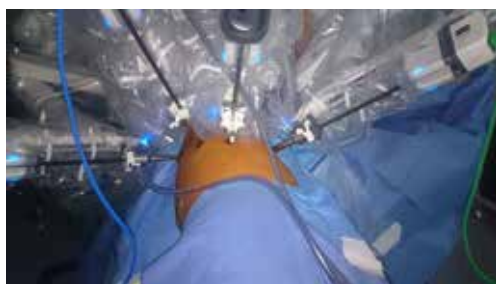

Figure 2 Standardized port mapping.

each of them 6 cm from the camera port with a second optional port positioned in the auscultatory triangle. The anterior port is positioned over the diaphragm, in the 5th–6th intercostal space on the anterior axillary line (*Figure 2*). It is always highly recommended to verify the internal position of each surgical port with the camera, in order to ensure an adequate distance between the arms. The CO₂ insufflation (5–8 mmHg), can be useful to increase the space available for maneuverability thanks to the collapsing of the lung and the flexion diaphragm (17).

The fourth arms already reported, is not strictly indispensable, although it can be applied to use a grasper to retract the lung achieving a better vision. From a technical point of view, the use of all four arms of the robotic system is recommended as it represent a good exercise for the surgeon at the beginning of the robotic experience.

The used instruments can be the monopolar (e.g., Hook or Spatula, Intuitive Surgical) or the bipolar instruments (e.g., Maryland or Fenestrated Bipolar, Intuitive Surgical), as reported by Guo *et al.*, and if used in the fourth arm a grasper (e.g., Cadiere, Prograsp, Intuitive Surgical) (16).

Few authors reported their experience, usually concerning a small series about the removal of masses located in posterior mediastinum using robotic surgical system.

The robotic system allows the execution of the surgical procedure with exceptional precision and safety, guaranteeing minimization of surgical trauma and surgical manipulation of the mass. Therefore, robotic surgery, is characterized by less pain, less hospital-stay, fewer complications, good cosmetic results and quick return to daily activities (18).

The use of robotic surgical system for surgery of posterior mediastinal masses to be a safe and comfortable mini-invasive technique, representing a useful instrument for the treatment of lesions located in narrow spaces, generally barely reachable.

Acknowledgements

The Authors thank Teresa Hung Key for assistance with this article.

Footnote

Conflicts of Interest: The authors have no conflicts of interest to declare.

References

1. Wei B, Cerfolio RJ. Robotic Lobectomy and Segmentectomy: Technical Details and Results. *Surg Clin North Am* 2017;97:771-782.
2. Yamashita S, Yoshida Y, Iwasaki A. Robotic Surgery for Thoracic Disease. *Ann Thorac Cardiovasc Surg* 2016;22:1-5.
3. Melfi FM, Fanucchi O, Mussi A. Minimally invasive mediastinal surgery. *Ann Cardiothorac Surg* 2016;5:10-7.
4. Liang H, Liang W, Zhao L, et al. Robotic Versus Video-assisted Lobectomy/Segmentectomy for Lung Cancer: A Meta-analysis. *Ann Surg* 2017. [Epub ahead of print].
5. Fok M, Bashir M, Harky A, et al. Video-Assisted Thoracoscopic Versus Robotic-Assisted Thoracoscopic Thymectomy: Systematic Review and Meta-analysis. *Innovations (Phila)* 2017;12:259-264.
6. Gkouma A. Robotically assisted thymectomy: a review of the literature. *J Robot Surg* 2017. [Epub ahead of print].
7. Rueckert J, Swierzy M, Badakhshi H, et al. Robotic-assisted thymectomy: surgical procedure and results.

- Thorac Cardiovasc Surg 2015;63:194-200.
8. Karagkounis G, Uzun DD, Mason DP, et al. Robotic surgery for primary hyperparathyroidism. Surg Endosc 2014;28:2702-2707.
9. Xu S, Liu B, Wang X, et al. Robotic thoracic surgery of the posterior superior mediastinal mass. Ann Transl Med 2015;3:127.
10. Cerfolio RJ, Bryant AS, Minnich DJ. Operative techniques in robotic thoracic surgery for inferior or posterior mediastinal pathology. J Thorac Cardiovasc Surg 2012;143:1138-1143.
11. Duwe BV, Sterman DH, Musani AI. Tumors of the mediastinum. Chest 2005;128:2893-2909.
12. Balduyck B, Hendriks JM, Lauwers P, et al. Quality of life after anterior mediastinal mass resection: a prospective study comparing open with robotic-assisted thoracoscopic resection. Eur J Cardiothorac Surg 2011;39:543-548.
13. Perez-Cruet MJ, Welsh RJ, Hussain NS, et al. Use of the da Vinci minimally invasive robotic system for resection of a complicated paraspinal schwannoma with thoracic extension: case report. Neurosurgery 2012;71:209-214.
14. Pacchiarotti G, Wang MY, Kolcun JP, et al. Robotic paravertebral schwannoma resection at extreme locations of the thoracic cavity. Neurosurg Focus 2017;42:E17.
15. Ruurda JP, Hanlo PW, Hennipman A, et al. Robot-assisted thoracoscopic resection of a benign mediastinal neurogenic tumor: technical note. Neurosurgery 2003;52:462-464; discussion 464.
16. Guo W, Yang S, Jin R, et al. Robot-assisted surgery for posterior superior mediastinal mass. AME Med J 2017;2:10.
17. Kocher GJ, Schmid RA, Melfi FM. Robotic lobectomy: tips, pitfalls and troubleshooting. Eur J Cardiothorac Surg 2014;46:e136-138.
18. Kamel MK, Rahouma M, Stiles BM, et al. Robotic Thymectomy: Learning Curve and Associated Perioperative Outcomes. J Laparoendosc Adv Surg Tech A 2017;27:685-690.

Cite this article as: Zirafa CC, Melfi F. Robot-assisted surgery for posterior mediastinal mass. J Thorac Dis 2017;9(12):4929-4931. doi: 10.21037/jtd.2017.10.160

Pre-operative preparation for Da Vinci robotic surgery

Xueyu Chen, Su Yang, Wei Guo, Runsen Jin, Yajie Zhang, Xingshi Chen, Han Wu, Hailei Du, Dingpei Han, Kai Chen, Jie Xiang, Hecheng Li

Department of Thoracic Surgery, Ruijin Hospital, Shanghai Jiao Tong University, School of Medicine, Shanghai 200025, China

Correspondence to: Hecheng Li, MD, PhD. Department of Thoracic Surgery, Ruijin Hospital, Shanghai Jiao Tong University, School of Medicine, 197 Ruijin Er Road, Shanghai 200025, China. Email: lihecheng2000@hotmail.com.

Received: 02 December 2016; Accepted: 27 December 2016; Published: 08 February 2017.

doi: 10.21037/amj.2017.01.04

View this article at: <http://dx.doi.org/10.21037/amj.2017.01.04>

Psychological preparation

When patients are hospitalized, they are usually unhappy. Furthermore, patients in the thoracic surgery ward usually have malignant tumors. Therefore, in addition to dealing with a monotonous and unfamiliar environment, patients often feel depressed. Before the operation, most patients have some degree of anxiety, because they lack comprehensive knowledge about the operation, such as tissue trauma and postoperative conditions. If patients have any questions or worries, they can ask the physician or nurses. The doctors should answer these questions patiently and help patients feel positive about the operation.

Respiratory tract preparation

- (I) For patients with a history of smoking, bronchial secretions will increase after the operation, which will exacerbate respiratory symptoms and related postoperative complications. These patients should quit smoking at least 2 weeks before the operation.
- (II) Patients should take a deep breath and cough training consciously to inflate the lung after the surgery. Patients should practice abdominal deep breathing and effective expectoration drainage.
 - ❖ Deep breathing training
 - ♦ Abdominal breathing: the patient should relax and stand upright (semi-reclining position or sitting position for sick patients) and put the left and right hand separately on the abdomen and chest. Relax the muscles and slow the breathing. Inhale deeply through the nose and try to expand the belly without moving the chest. Exhale

though the mouth, compress the abdomen at the same time, and keep the thorax as still as possible, taking a slow and deep breath and increasing alveolar ventilation. Take 7–8 breaths per minute, for 10 to 20 minutes each training session, 2 times a day. After becoming skilled, gradually increase the frequency and duration to develop an unconscious breathing habit.

- ♦ Pursed lip breathing: inhale through the nose and exhale through the mouth. While exhaling, purse the lips like as when whistling, exhale slowly and continuously, and compress the abdomen at the same time. The ratio between inhale and exhale time should be 1:2 or 1:3. The lip girdle degree and exhale flow should be selected such that a candle flame would flicker at a distance of 15–20 cm.
- ♦ Yawn: Yawn once every 5–10 min by inhaling continuously for 5 s and then exhaling slowly.
- ♦ Bilateral lower thoracic expansion and lateral lower thoracic expansion exercises.
- ❖ Coughing training: instruct the patient in the correct position and method for coughing.
 - ♦ When coughing in the sitting position, the body should be bend forward slightly with legs crossed.
 - ♦ When coughing in the side-lying position, bend the knees.
 - ♦ When coughing in the sitting position, sit on the chair or bed, bring the shoulders forward with the head downward, and hold a small pillow against the abdomen with two hands. Press against the abdomen with the hands when coughing.

- ♦ Using the abdominal or chest breathing method, relax the throat, open the mouth, and extend the tongue slightly to cough 2 or 3 times.
 - ❖ Using the incentive spirometer
 - ♦ The Incentive Spirometer is an instrument that is used to encourage sustained maximal inspiration and to judge the patient's inspiratory capacity by observing the position of the rising ball. Methods: After one normal deep breath, put the mouthpiece into the mouth, inhale, and then take out the mouthpiece, and exhale slowly with pursed lips, 5 times.
- (III) Atomization inhalation: atomization inhalation begins 3 days before the operation and is performed two or three times each day, for 15 to 20 minutes for each time.

Diet

To enhance physical fitness, increase the tissue repair, and prevent infection, patients should eat digestible food high in heat, protein, fiber, vitamin, and rich fruit acid (except for patients who suffer from esophageal obstruction), such as lean meat and fish, eggs, fresh vegetables and fruits, and bean products, etc. For patients who have difficulty in eating and those who are not able to eat food because of digestive tract obstruction, intravenous nutrition can be provided. For patients with malignant anemia and hypoproteinemia, these conditions should be corrected before the operation.

Pre-operative examination

Examinations

General laboratory texts

Before the operation, patients should undergo blood, biochemical, and urine, and receive proper treatment. For example, low hemoglobin indicates anemia and poor nutrition, so small amounts of blood can be transfused frequently to bring the hemoglobin level back to normal in a short time. Patients who suffer from esophagus cancer often have difficulty eating, so most of them have hypoproteinemia. They should be given infusions of human albumin to correct this condition and in this way improve the safety of the operation. Coagulation function of patients should also be checked before the operation. If the patient

has had a coronary heart event just before the operation, serum myocardial enzyme level should also be checked. With routine blood glucose examination, asymptomatic type II diabetes can be detected.

Serum tumor markers detection

The commonly used domestic and foreign primary pulmonary and esophageal malignancy tumor markers include carcinoembryonic antigen (CEA), neuron-specific enolase (NSE), cytokeratin fragment 19 (CYFRA21-I), pro-gastrin-releasing peptide (ProGRP), and squamous cell carcinoma (SCC) antigen. Using a combination of these tumor markers can improve their sensitivity and specificity in clinical applications.

Imaging examination

Commonly used imaging methods in thoracic surgery include: chest X-ray, computed tomography (CT), magnetic resonance imaging (MRI), ultrasound, radionuclide imaging, and positron emission-CT scan. These tests are mainly used in the diagnosis, classification, post-treatment monitoring of lung and esophageal malignant tumors, and determining prognosis. In the clinical diagnosis and treatment process, one or more appropriate imaging methods should be selected.

Chest X-ray

Chest radiograph is a basic imaging examination method used before and after treatment for lung cancer and esophageal cancer. It generally includes chest posteroanterior and lateral images. If the physician detects a suspicious area on the chest radiograph, or wants additional information that may help the diagnosis, additional imaging examination methods should be selected.

Chest CT examination

Chest CT can provide information that is difficult to discover by X-ray chest. This method can effectively detect early peripheral lung cancer, verify lesion sites and range of involvement, and identify benign or malignant lesions. Therefore, it is the most important and most commonly used imaging method for diagnosis, staging, evaluating outcome, and follow up. For chest lesions that are difficult to diagnose, CT-guided percutaneous lung puncture biopsy can be used to obtain a cytological and histological diagnosis. For patients with esophagus cancer, the neck,

chest, and epigastrium should be imaged to check the metastatic condition of the esophagus cancer and lymph nodes and to know the involved layer and degree of invasion of esophageal lesion and surrounding tissue.

MRI examination

MRI examinations can be selectively used before the thoracic surgery to determine whether the chest wall or mediastinum is invaded; show the relationship between a pulmonary sulcus tumor and brachial plexus and blood vessels; differentiate between pulmonary hilar mass and pulmonary atelectasis, obstructive pneumonia. For patients for whom iodine contrast agent is contraindicated, MRI is the first choice to observe the mediastinum, pulmonary hilum great vessels invasion, and lymph node enlargement. It is also useful for identifying post-radiotherapy fibrosis and tumor recurrence. MRI is also suitable for judging the brain and bone marrow metastasis, contrast-enhanced MRI of the brain should be routine for pre-operative classification of lung cancer.

Ultrasound

Ultrasound is mainly used to determine whether there is metastasis in the solid organs of the abdomen, abdominal cavity, retroperitoneal lymph nodes, and neck and supraclavicular lymph nodes. For pulmonary lesions close to the chest wall or chest wall lesions, it can identify its cystic or solid nature and is useful for ultrasound-guided biopsy; ultrasound is also used to position drainage tubes for pleural effusion and pericardial effusion.

Bone scanning examination

This routine examination is used to evaluate bone metastasis of patients suffering from malignant pulmonary tumors. When the bone scanning examination indicates suspected bone metastasis, MRI, CT or PET-CT can be conducted to verify the suspect lesions.

PET-CT examination

For some patients with a pulmonary lesion in a deeper location that is close to the central region, it is hard to obtain a biopsy by bronchoscopy, PET-CT examination can be used to check the standardized uptake value of fluorodeoxyglucose to determine the benign or malignant nature of the lesion, and whether there is metastasis in the mediastinum and hilar lymph nodes. It is the best method for the diagnosis of lung and esophagus malignant tumor, and evaluation of outcomes and prognosis (1).

Splanchnoscopy

Bronchoscopy

Bronchoscopy is a popular method to diagnose pulmonary malignant tumors by means of brush biopsy, or needle aspiration using a bronchoscope and bronchial lavage to obtain a cytology and histology diagnosis. The detection rate can be improved if several of the above methods are combined.

Transbronchial needle aspiration (TBNA) and endobronchial ultrasound-guided transbronchial needle aspiration (EBUS-TBNA)

Tracheal puncture and paracentesis of lymphaden and lump beside parabronchial masses are helpful for lung cancer diagnosis and lymphaden staging. Traditional TBNA is defined as a blind procedure based on the chest CT, but is generally not recommended because it is highly dependent on operator skill. Hospitals with sufficient trained operator should try the traditional TBNA method. EBUS-TBNA, with its high safety and reliability, is used for needle aspiration to obtain an accurate pathologic and cytologic diagnosis for focal and lymph node metastasis.

Transbronchial lung biopsy (TBLB)

TBLB is generally performed under the guidance of X-ray, CT, endobronchial ultrasound probe, virtual bronchoscope, or electromagnetic navigation bronchoscopy, and it is suitable for peripheral pulmonary lesions and at the same time examine the condition of the lumina, it is an important nonsurgical method for diagnosing means of bellow nodes.

Gastroscopy

For patients with esophageal focal lesions, a gastroscopic examination before surgery can help to determine the position of the lesion and judge whether the focal lesion is benign or malignant based on its appearance. For an esophageal focal lesion suspected to be malignant, a biopsy can be conducted to determine the pathologic diagnosis. The biopsy can be combined with a photoacoustic endoscopic probe to determine the depth of infiltrating of the tumor.

Endoscopic mucosal resection & endoscopic submucosal dissection

Endoscopic methods have become important for curing

early-stage esophageal cancer since the development of endoscope. Currently, widely used endoscopic treatment methods for early-stage esophageal cancer includes endoscopic mucosal resection and endoscopic submucosal dissection (2,3).

Pulmonary function test

Routine pulmonary function test

For the test of lung capacity and voluntary ventilation function, the most important indices are vital capacity (VC), forced vital capacity (FVC), the volume exhaled in the first second of maximal expiration (FEV₁), the percentage of VC exhaled in the first second of maximal expiration (FEV₁%), and maximal voluntary ventilation (MVV).

Routine pulmonary function tests are necessary prior to open chest surgery. The preliminary screening will determine whether complications such as respiratory failure will occur after the surgery. Generally, open chest surgery is regarded as high risk if VC <50%, MVV <50%, FEV₁ <1.0 L, or FEV₁% <50%. Some experts consider MVV as the index that best represents respiratory dysfunction to judge the risk of surgery, thinking that the patient can tolerate surgery if MVV >70%, the risk of surgery should be given careful consideration if MVV is 69%–50%, conservative treatment should be given and surgery avoided if MVV is 49%–30%, and surgery should not be performed if MVV is below 30% (4,5).

Unconventional pulmonary function test

Side pulmonary function test

This includes lateral position testing and side double-lumen endotracheal intubation measurement testing. The former is simple but has large errors, and the latter will give accurate results but is more invasive and needs special instruments. The side pulmonary function test is performed to determine the contribution of each lung to total lung function, especially for patients considering pneumonectomy. This test can evaluate whether the residual lung can bear the trauma of surgery and function well enough such that the patient can maintain regular daily activities after surgery.

Bronchial relaxation test

At present, the testing method and evaluation standard are not unified. Generally, the ventilation improvement rate is obtained by measuring FVC, FEV₁, or MVV before or

after breathing 0.5% atomized Isuprel or subcutaneous injection of adrenaline in (1:1,000). It is significance if improvement is >15%. If there is a suspicion of reversible airway obstruction after the conventional bronchial relaxation test, this testing can be carried out. If lung function is improved after giving the medication, the patient likely has reversible airway obstruction, which commonly occurs with chronic obstructive pulmonary disease or bronchial asthma. The treatment targets the cause of airway disease to relieve the obstruction, which not only increases the surgery indication but can also help the patient survive the surgery.

Echocardiography

Doppler echocardiography is the only procedure that can dynamically display the cardiac intracavitary structure, heartbeat and hemokinesis without trauma to the body. Thoracic surgical procedures will bring considerable trauma and affect the circulation of patients after the surgery, especially as most patients are at middle-aged or elderly. Echocardiography before surgery can help doctors to get a preliminary indication of the cardiac reserve and patient tolerance for surgery so as to fully estimate the surgery risk. In addition, echocardiography before surgery is also used to determine cardiac structural abnormality or hemodynamic changes.

Acknowledgements

None.

Footnote

Conflicts of Interest: The authors have no conflicts of interest to declare.

References

1. Zhi X, Shi Y, Yu J. Edition). Chinese Journal of Oncology 2015;2015:37.
2. Hamanaka H, Gotoda T. Endoscopic resection for early gastric cancer and future expectations. Digestive Endoscopy 2005;17:275-285.
3. Makuuchi H, Yoshida T, Ell C. Four-Step endoscopic esophageal mucosal resection (EEMR) tube method of resection for early esophageal cancer. Endoscopy

- 2004;36:1013-1018.
4. Nakamura M, Iwahashi M, Nakamori M, et al. An analysis of the factors contributing to a reduction in the incidence of pulmonary complications following an esophagectomy for esophageal cancer. *Langenbecks Arch Surg* 2008;393:127-133.
 5. Reid WD, Samrai B. Respiratory muscle training for patients with chronic obstructive pulmonary disease. *Phys Ther* 1995;75:996-1005.

doi: 10.21037/amj.2017.01.04

Cite this article as: Chen X, Yang S, Guo W, Jin R, Zhang Y, Chen X, Wu H, Du H, Han D, Chen K, Xiang J, Li H. Pre-operative preparation for Da Vinci robotic surgery. *AME Med J* 2017;2:15.

Collaboration between the surgeon, assistants and nurses in robotic-assisted thoracic surgery

Jie Li, Wei Wang, Qianjian Qian, Xingshi Chen, Hecheng Li

Department of Operation Theatre, Ruijin Hospital, Shanghai Jiao Tong University, School of Medicine, Shanghai 200025, China

Correspondence to: Hecheng Li, MD, PhD. Department of Thoracic Surgery, Ruijin Hospital, Shanghai Jiao Tong University, School of Medicine, 197 Ruijin Er Road, Shanghai 200025, China. Email: lihecheng2000@hotmail.com.

Received: 02 December 2016; Accepted: 27 December 2016; Published: 15 February 2017.

doi: 10.21037/amj.2017.01.03

View this article at: <http://dx.doi.org/10.21037/amj.2017.01.03>

Section 1: surgical instruments and preparation

Conventional surgical instruments

Routine surgical instruments: #7 knife handles, surgical scissors, forceps, needle holders, clamps (Snap, Kelly, Allis), Langenbeck, retractors, sponge-holding forceps, disinfection plates, and medicine bowls.

- (I) Routine instruments for pulmonary surgeries (see *Table 1*).
- (II) Routine instruments for esophageal surgeries (see *Table 2*).

Other instruments needed for neck lymph nodes dissection: gauze, thyroid retractor, clamps (Mosquito, Snap), forceps, surgical scissors, 200-mL negative pressure drainage bottle, 3-0 sutures, and 6×14 round needles.

- (III) Routine instruments for mediastinum and thymus surgeries (see *Table 3*).

Instruments of the da Vinci surgical system

- (I) Accessories: 8-mm trocar ×3, seal for trocar ×3, puncture device, collators for camera, adapters for camera and camera arm, light-transmitting instrument, sterile drapes for robotic arms and camera, and 30° lens (0° lens for mediastinal surgeries).
- (II) Instruments: permanent cautery hook, fenestrated bipolar forceps, Cadiere forceps, Maryland bipolar forceps, large needle, monopolar curved scissors, and harmonic curved shears.

Other instruments

The operation table should be equipped with a nonadjustable

hand shelf, a hand shelf with adjustable height and angle, two pelvic supports, foot supporter, fan-shaped instruments table, square-shaped instrument table, height-adjustable chair, surgical basin stand, cushions, elastic bandages, marker pens, and image recording apparatus.

Section 2: the layout of the operating rooms

The da Vinci Surgical System consists of several key components, including the follow: surgeon console, the patient-side cart, and the vision cart. Using the da Vinci Surgical System, the surgeon operates while seating at an ergonomically designed console a few feet from the patient, away from the aseptic area. The console is connected to the patient-side cart and the vision cart. The patient-side cart is the main instrument. The vision cart provides the surgical assistant with a broad perspective and visualization of the procedure. The vision cart should be placed near the operating table beyond the patient at an appropriate height and angle facing the surgical assistant. It is equipped with a lens, light source, and energy platforms and connected to the robotic arms through a monopolar or bipolar energy instrument cord. Placement of the patient-side cart should align the camera position, target area, and the central column of the patient-side cart. Place the patient-side cart in front of the patient's head with arms 1 and 2 on the left side, and arm 3 at the back.

Place the anesthesia machine at the front left of the operating table to shorten the distance between the respiratory interface of the anesthesia machine and the tracheal intubation interface of the patient. Adjust the positions of the cords and fluid infusion pathway according to the position of the patient (left lateral or right-lateral).

Table 1 Routine instruments for pulmonary surgeries

Endoscopic instruments: 12-mm trocars, suction apparatus, pneumoperitoneum tubes, endoscopic forceps, scissors, 10mm titanium clips, Hem-o-lock clips, monopolar and bipolar energy instrument cord

Disposable instruments: #22 blades, #11 blades, 9×24 needles, ruler, urethral catheterization bags, drainage pack, suction connecting tubes, electric scalpels, paraffin oil tampons, 6×7 and 10×10 wound dressings, imaging gauzes, imported rubber strips, Endo GIA autosuture single-use stapler and reloads, specimen fetcher, 32 Fr thoracic drainage tube, 8 Fr drainage tube, #0 5/8 VICRYL arc absorbable sutures, 3-0 fast absorbing skin sutures

Table 2 Routine instruments for esophageal surgeries

Endoscopic instruments: 12-mm trocars, suction apparatus, pneumoperitoneum tubes, ultrasonic knife line, endoscopic forceps, scissors, 10-mm titanium clips, Hem-o-lok clips, monopolar and bipolar lines, endoscopic fan retractors, endoscopic double joint forceps, and endoscopic anvil- holding forceps

Disposable instruments: #22 blades, #11 blades, 9×24 needles, ruler, urethral catheterization bags, drainage pack, suction connecting tubes, electric scalpels, protective sleeves, paraffin oil tampons, 6×7 and 10×10 wound dressings, imaging gauze 20 mL syringes, Endo GIA™ autosuture single-use stapler and reloads, specimen fetcher, 32Fr thoracic drainage tube, 8Fr drainage tube, 200-mL negative pressure drainage bottle, jejunal fistula, 2-0 double-headed straight needles, 3-0 Prolene sutures, 3-0 MAXON sutures, 3-0 VICRYL absorbable sutures, #0 5/8 VICRYL arc absorbable sutures, 3-0 fast absorbing skin sutures

Table 3 Routine instruments for mediastinum and thymus surgeries

Endoscopic instruments: 12-mm trocars, suction apparatus, pneumoperitoneum tubes, endoscopic forceps, scissors, 10-mm titanium clips, Hem-o-lok clips, monopolar and bipolar energy instrument cord

Disposable instruments: #22 blades, #11 blades, 9×24 needles, ruler, urethral catheterization bags, drainage pack, suction connecting tubes, electric scalpel, paraffin oil tampons, 6×7 and 10×10 wound dressings, imaging gauze, specimen fetching device, 32 Fr thoracic drainage tube, #0 5/8 VICRYL arc absorbable sutures, 3-0 fast absorbing skin sutures

The anesthetist should be able to see both the monitor screen of the anesthesia machine and the vision system of the da Vinci system.

Section 3: the position of the patient

Patient position plays a key role in the success of the operation because of the difficulty in moving the patient-side cart during the operation. Unlike traditional open surgery, da Vinci surgery requires clear exposure of the incision and viscera and unlimited robotic arm movement in horizontal and vertical space. The optimal patient position varies according to the body type. Ensure normal physiological curvature without excessive traction of muscles and nerves. Protect the limbs of the patient to avoid postoperative complications due to compression.

90° lateral position for pulmonary surgeries

Position the nonadjustable hand shelf at the level of the patient's contralateral shoulder and then position the hand shelf with adjustable height and angle, which can maintain an unlimited operating field for the robotic arms and prevent the thorax from oppressing the upper limbs and brachial plexus (1). Move the patient to a 90° lateral position after giving anesthesia. A padded wedge or pillow is placed under the thorax at the level of the fourth and the fifth rib to bow the chest and open the rib spaces on the upper side to facilitate the exposure. Place the patient's waist facing the back plate of the operation table to avoid disturbance of the pelvis by the robotic arms during surgery (*Figure 1*). Place the ipsilateral upper limb on the adjustable hand shelf angled outwards to 15°-20°, and the contralateral upper limb on the unadjustable hand shelf. Use elastic bandages and restraint straps to fix the upper limbs from the distal side to proximal side with appropriate pressure and expose the fingers to observe the peripheral circulation. The lateral position is maintained by pelvic and buttock supports which prevent rolling or slipping. The upper leg is placed in a flexed position, and the lower leg in an extended position. Cushions are placed not only between the legs, but also under the knees and ankles. Use restraint straps to fix the lower limbs.

90° lateral position and supine position for esophageal surgeries

The 90° lateral position used for esophageal surgeries is almost the same as the 90° lateral position used for pulmonary surgeries. Place the patient slightly forward and maintain the 15° reverse Trendelenburg position to provide excellent exposure for the surgeon (*Figure 2*).

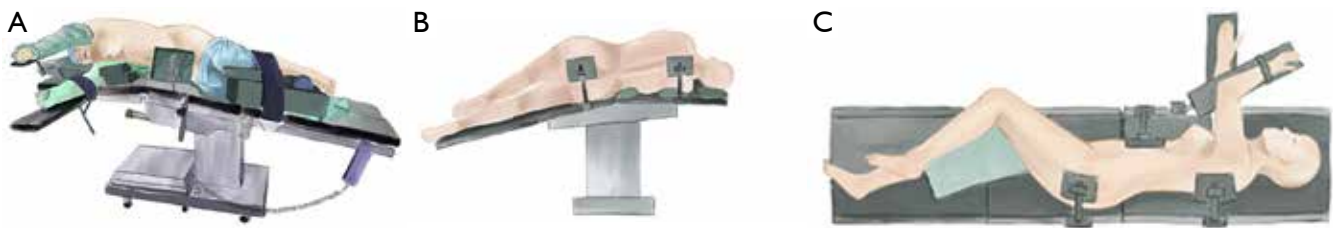

Figure 1 Jackknife position for lung surgery.

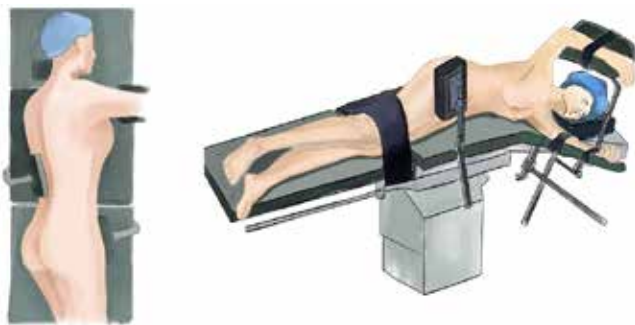


Figure 2 Left lateral decubitus and Jackknife position.

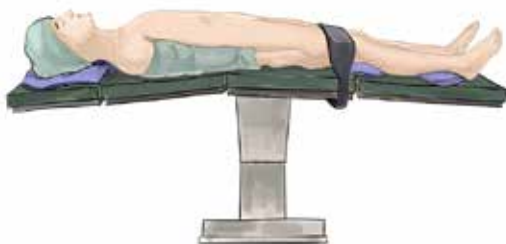

Figure 3 Supine Trendelenburg position.

The supine position for esophageal surgeries

With the patient in a supine position, add a bedside board for neck lymph node dissection. Place a cushion under the thorax and the waist to prevent post-operative discomfort. Place a cushion under the knee joint to ensure normal physiological curvature. Place a cushion under the heel to prevent compression. Fix restraint straps above the knee joint with appropriate tightness. Place the patient's left arm (used for intravenous injection) on the hand shelf angled outwards less than 90° and fix with a restraint strap. Fix the other arm using the same approach with good protection. Use a foot supporter to prevent slipping. Maintain a 10° - 15° reverse Trendelenburg position and tilt the operation table 10° - 15° to the right to better expose the stomach

(Figure 2).

Place the patient in the supine Trendelenburg position for neck lymph nodes dissection. Place occiput supports under the cervical vertebrae to avoid excessive neck traction (Figure 3).

Position for mediastinal surgeries

Mediastinal surgeries can be divided into anterior mediastinal surgeries and posterior mediastinal surgeries. Anterior mediastinal surgeries require the patient to be in a 45° semi-lateral position with the patient-side cart at the contralateral side. Posterior mediastinal surgeries require the patient to be in a 90° lateral position with the patient-side cart at the ipsilateral side.

For the 45° semi-lateral position, place the contralateral arm on the hand shelf angled outwards to less than 90° . Place pelvic supports at the axilla and iliac crest to prevent movement when the table is rolled. Place slope-shaped cushions under the ipsilateral shoulder and hip, and place a cushion under the waist. The patient's upper body should be in a 45° semi-lateral position. Use a cotton pad to protect the ipsilateral wrist and fix it to the operation table with an elastic bandage to avoid excessive traction and compression. Place a cushion under the knee joint and use a foot supporter. Fix the lower limbs (Figure 2).

The 90° lateral position for posterior mediastinal surgeries is nearly the same as the 90° lateral position for pulmonary surgeries. Tilt the operation table 10° to the ipsilateral side for better exposure.

Section 4: intraoperative collaboration

Patient protection and the use of protective equipment

The patient is often placed in the lateral position after receiving anesthesia in thoracic surgeries. The anesthetists

and nurses should cooperate to avoid tracheal intubation or infusion tube slipping because of the traction due to inappropriate posture. Muscle relaxation caused by anesthesia makes the limbs vulnerable to hyperextension or compression, especially in certain position that allow exposure of the surgical field. Protective equipment for patient position include a silicone bed sore pad, heel pad, cushions, cotton pad, foot supporter, elastic bandages, elastic restraint straps, hand shelf with adjustable height and angle, and iliac supporter.

Preparation for special surgical dressings and sutures

Because of the magnified view of the operative field in da Vinci robotic surgeries, it is suitable to use compact gauze (length 5 cm, diameter 7–8 mm) made by nurses, which have a smooth surface without protruding threads to facilitate the absorption of exudates and blood in the surgical field.

The sutures used in robotic surgeries should be 8 cm for interrupted sutures, 18–20 cm for continuous sutures, and original length for purse-string sutures and with strict sterilization.

Choice of single-use staplers and reloads

Use Endo GIA™ 60-3.5 reloads to cut the pulmonary lobe, 60-4.8 reloads to cut the bronchus and 60-2.5/45-2.5/30-2.5 reloads to cut the pulmonary blood vessels in pulmonary surgeries.

Use Endo GIA™ 60-3.5 reloads and 60-3.5 rotatable reload to make the gastric tube in esophageal surgeries. Use 60-2.5 reloads for the arch of azygos vein.

Section 5: cooperation between surgical team members and problem solving in robotic thoracic surgeries

Teamwork

The surgical team members in robotic thoracic surgeries include the surgeon, surgical assistant, anesthetist, instrument nurses, and circulating nurses. The surgical team should have clearly defined roles and cooperate well. Double-lumen endotracheal intubation, stable ventilation, and hemodynamics are important prerequisites to ensure a smooth operation. Instrument nurses should be familiar with the use of robotic arms and sterile drapes

for robotic arms, lens settings, loading and firing of the special instruments in the da Vinci system, and the surgical procedure. Circulating nurses should make the preparations for da Vinci robotic surgery including setting up the system, self-checking, robotic arms, and lens loading. They should move the patient-side cart to the appropriate position beside the operation table to facilitate the connections between robotic arms and the trocars. Circulating nurses also need to help position the patient and observe and protect the patient during surgery.

Problem solving

Clear endoscopic operative view

The lens of the da Vinci system provides the surgeon with two visual fields, whereas the vision cart only shows only one visual field. If the visual field is obscured due to exudation or fog generated by electric scalpels, the surgical assistant should take out the lens and use wet gauze to scrub the lens and trocar to prevent the lens from being contaminated by blood again. Readjust the focus.

Instrument changing and error solving

The surgeon should instruct the surgical team to change the robotic arms and straighten the wrist of the robotic arm when it is open slightly. The instrument nurse should confirm this with the surgeon before removing the robotic arms. It is important to use the instruments appropriately. Effective communication is the key to avoiding unnecessary injury to the patient, maintaining normal operation of the da Vinci system, and shortening the surgery time.

The circulating nurse should be able to deal with system alarms and errors. Common problems such as power connection issues or crash of the robotic arms could be handled with the clutch. Reinsert or change the robotic arm and use the recovery button in the event of a system alarm. Record the fault code and inform the engineer in the event of an unrecoverable fault.

The surgical assistant and nurses should ask the surgeon to pause the surgery and change the position of the robotic arms if there is robotic arms crash. Be sure to protect the incisions.

Emergency coordination for conversion to open surgery

Promptly prepare the instruments for open surgery (e.g., headlamp, electric scalpels, and ultrasonic knives, if needed)

Table 4 Routine thoracic instruments for open pulmonary surgeries

Routine instruments: routine thoracic instruments for open pulmonary surgeries, retractors (auto-retractors for small incisions or crossed retractors), handles for shadowless lamp, measuring cylinder and special instruments for esophageal surgery

Disposable instruments: Yankauer suction tip, extension for electric scalpels, trocars, 2-0 sutures, 0 sutures, 3-0 Prolene sutures, 4-0 Prolene sutures, 5-0 Prolene sutures, ultrasonic knives, gauze, 20 or 25 cm wound dressings, and spherical irrigator

under the instruction of the surgeon and remove the da Vinci surgical instruments to provide enough space for open surgery (*Table 4*). Adjust the operation table to the appropriate height and angle for open surgery and protect and restrict the patient's limbs. Avoid unnecessary exposure

doi: 10.21037/amj.2017.01.03

Cite this article as: Li J, Wang W, Qian Q, Chen X, Li H. Collaboration between the surgeon, assistants and nurses in robotic-assisted thoracic surgery. AME Med J 2017;2:21.

of the limbs and use an electric blanket to maintain the patient's body temperature.

Acknowledgements

None.

Footnote

Conflicts of Interest: The authors have no conflicts of interest to declare.

References

1. Wang S. The Robotic Thoracic Surgery. China: AME Publishing Company, 2015.

Postoperative management of robotic-assisted thoracic surgery

Yanxia Hu, Jiajie Pu, Beiwen Wu, Xingshi Chen, Hecheng Li

Department of Thoracic Surgery, Ruijin Hospital, Shanghai Jiao Tong University, School of Medicine, Shanghai 200025, China

Contributions: (I) Conception and design: Y Hu, H Li; (II) Administrative support: H Li; (III) Provision of study materials or patients: Y Hu, H Li; (IV) Collection and assembly of data: Y Hu, J Pu; (V) Data analysis and interpretation: Y Hu, B Wu; (VI) Manuscript writing: All authors; (VII) Final approval of manuscript: All authors.

Correspondence to: Hecheng Li, MD, PhD. Department of Thoracic Surgery, Ruijin Hospital, Shanghai Jiao Tong University, School of Medicine, 197 Ruijin Er Road, Shanghai 200025, China. Email: lihecheng2000@hotmail.com.

Abstract: With the widely application of da Vinci Surgical System in thoracic surgery, which has advantages such as less trauma, less bleeding, and quick recovery, the delivery of specialized nursing care has come to the forefront. However, there were few studies about the postoperative nursing for robot surgery. Therefore, we summarized our experience on enhanced recovery after robotic-assisted thoracic surgery.

Keywords: Robot-assisted surgery; nursing; ERAS; postoperative exercise

Received: 02 December 2016; Accepted: 27 December 2016; Published: 07 February 2017.

doi: 10.21037/amj.2017.01.06

View this article at: <http://dx.doi.org/10.21037/amj.2017.01.06>

Introduction

With the widely application of robot-assisted thoracic surgery using the da Vinci Surgical System, the delivery of specialized nursing care has come to the forefront. Robot-assisted thoracic surgery with less trauma, less bleeding, and quick recovery has reduced the difficulty of clinical nursing care and increase the expectation of an enhanced recovery after surgery.

Mental care

Patient unfamiliar with the da Vinci Surgical System may have unreasonable expectations or a skeptical attitude. Short-term discomfort after surgery may prevent patients from seeing the advantages of da Vinci surgery. In addition, patients and their families may be disappointed in the seemingly minor benefits over conventional surgery, particularly as this procedure is more expensive. In addition to preoperative health education, nurses should offer professional postoperative health education, emphasizing the features and benefit of da Vinci surgery versus conventional surgery, to boost patient confidence. Nurses also set up a group for patients undergoing da Vinci surgery to share their feelings, which will ultimately improve patient

outcomes.

Diet is mainly divided into two categories according to type of disease and surgery

- (I) For non-gastrointestinal surgeries (e.g., pulmonary disease, mediastinal disease), the diet should be bland and consist of easily digested semi-liquids (e.g., porridge, noodles, ravioli), gradually increasing the intake of protein, calories, and vitamins. Provide a high-roughage diet for regular defecation.
- (II) For gastrointestinal surgeries (e.g., esophageal disease), patients should receive enteral nutrition the first day after surgery. The nutrient solutions should be given at the appropriate temperature (37–42 °C) in the appropriate amount (gradually increasing from 500 to 1,500–2,000 mL/d), and at an appropriate rate (gradually increasing from 50 to 120 mL/h). Adjust fluid speed and amount of nutrient solution according to the chief complaints of the patients. Typically, the postoperative diet starts 24 hours after stopping gastrointestinal decompression in the absence of dyspnea, chest pain, ipsilateral diminished breath sounds, fever, or other symptoms

of anastomotic fistula. Patients usually start with a little water before advancing to a liquid diet and then a semiliquid diet. About 1 month after the surgery, patients are able to advance to a soft diet. Patients should eat smaller more frequent meals, chew foods thoroughly, eat and drink slowly, and avoid raw or cold foods to prevent anastomotic fistula. Sitting in a reclining position for 2 hours after meals and using high pillows while sleeping can prevent reflux.

Position

After surgery the patient should take a semi-reclining position (the head of the bed should be elevated 30°) to ease breathing and drainage and minimize coughing, sputum, and pain. After 6 hours, patients can move into other positions with the assistance of nurses after eating or fluid infusion.

Pain care

- (I) Keep the ward quiet. Ensure the patients get sufficient rest. Help the patient find a comfortable position.
- (II) Teach the patients how to move in bed. Fix the thoracic drainage tube while the patient is changing position or coughing to avoid irritating the pleura and consequent chest pain.
- (III) Instruct patients to relax by using abdominal deep breaths or soothing music.
- (IV) Give analgesics according to the doctors' instruction and watch for signs of respiratory depression.
- (V) Encourage early removal of the thoracic drainage tube to avoid the pain caused by factors such as the traction of the duct due to the lower amount of effusion of da Vinci surgery.

Airway management

- (I) Closely observe respiratory patterns (frequency and rhythm) and perform pulmonary auscultation to see if the breath sounds are normal and whether there are signs of hypoxia.
- (II) Encourage the patients to take deep breaths or use a respiration training device to promote lung expansion. Help the patients expectorate. Pat them on the back (on both sides of the spinal column, from basis pulmonis to apex pulmonis, from bottom to top, from

outside to inside, about 2–3 times per second) or use auxiliary instruments. Compress the trachea or take thyrocricocentesis to inject saline, if needed, to induce cough.

- (III) Use a nebulizer to dilute the sputum and make it easier to cough.
- (IV) Use a fiberoptic bronchoscope to suction sputum for patients who are too weak to cough.

Tubes care

- (I) Thoracic drainage tube (1)
 - (i) To ensure effective drainage, observe whether the pipe column fluctuates with respiration. Squeeze the tube to prevent obstruction of the drainage tube if there are blood clots or floccules in it.
 - (ii) Place the drainage bottle lower than the incision.
 - (iii) Properly place and fix the drainage bottle to prevent tilting and determine the appropriate length of the drainage tube to facilitate the patients' activities and prevent distortion.
 - (iv) Observe and record the color, quality, and quantity of the fluids and gas discharge in the drainage tube. Note that bleeding >200 mL/h for 3 hours indicates active hemorrhage.
 - (v) Use strict aseptic technique.
 - (vi) Maintain the tightness of the drainage tube. Use two clamps to seal the duct while moving the patients or changing the drainage bottle to prevent air from entering. Avoid pneumothorax or atelectasis caused by clamping the duct when there is air leakage. Ask the patients to exhale and use Vaseline, gauze, and tape to protect the wound and inform the doctor if the thoracic drainage tube slips.
 - (vii) Indications of extubation include 24–72 hours' drainage without gas discharge or with dwindling clear fluids, drainage fluids <100 mL/d, pus <10 mL/d, chest X-ray with good lung expansion, and no signs of dyspnea.
- (II) Jejunal fistula and nasogastric feeding tube
 - (i) The tube must be tied or taped securely, and the patients should take a semi-reclining position to prevent reflux and aspiration. Extra caution is required when the patients has a choking cough because of the possibility of reflux or aspiration.

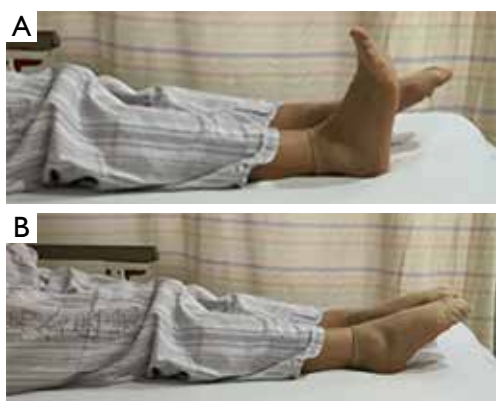

Figure 1 Ankle pump exercises.

Patients should be encouraged to cough to discharge inhaled fluid. Use a fiberoptic if needed.

- (ii) The skin around and under the ties or tube should be frequently assessed for ulcerations. Lubricate the nasal mucosa with paraffin oil daily.
- (iii) The tube needs periodical flushing to remain unobstructed.
- (iv) Pause injection of the jejunal nutrient solution and inform the doctor if there is exudation or slipping.
- (III) Gastric tube
 - (i) The tube must be tied properly to prevent slipping.
 - (ii) Monitor the quality and quantity of drainage fluids. A small amount of bloody or coffee-like fluid can be aspirated from the gastric tube 6–12 hours after the surgery, and then the drainage fluids should become clearer. A large amount of bloody fluid, irritability, decreased blood pressure, increased pulse rate, and decreased urine volume may suggest anastomotic bleeding that needs emergency treatment.
 - (iii) Squeeze the tube to keep it unobstructed and use saline if needed.
 - (iv) If slipping occurred, do not reinsert the gastric tube to prevent piercing the anastomosis and cause anastomotic leakage.

Complications

The da Vinci surgical system has been proven to be an

effective procedure with enhanced visualization, better dexterity, and fewer complications. In addition to common thoracic surgery complications, the following complications may occur due to the characteristics of da Vinci robotic system.

- (I) Postoperative hemorrhage (2-5): the da Vinci robotic system lacks tactile feedback, which may cause undetectable intraoperative hemorrhage due to excessive traction of tissues and blood vessels. Members of the healthcare team must pay attention to the patients' vital signs, chief complaints, and drainage fluids.
- (II) Hypercapnia: CO₂ pneumoperitoneum during surgery may cause acidosis, subcutaneous emphysema, and other complications. Nurses should carefully observe the patients' state of consciousness and respiratory rate and enhance airway management to promote CO₂ removal.

Exercise and rehabilitation

Injuries to blood vessels, muscles, and nerves adjacent to the surgical field are inevitable. Patients may experience shoulder stiffness, muscle atrophy, and upper extremity dysfunction due to postoperative pain. Early ambulation can prevent complications such as shoulder joint ankylosis, disuse atrophy, atelectasis, pressure ulcers, constipation, and deep venous thrombosis (6).

- (I) Early in-bed mobilization: patients can start to clench their fists or do ankle pump exercises (*Figure 1*) (holding for 5–10 seconds and then relaxing 3 times a day) once they awake from anesthesia. These exercises may promote blood circulation to improve limb numbness and stimulate lower extremity venous reflux to prevent deep venous thrombosis.
- (II) Shoulder exercises (*Figure 2*):
 - (i) Patients can start finger flexion and extension or ankle pump exercises (3–5 minutes, 3 times a day) once they awaken from anesthesia.
 - (ii) Patients can start elbow flexion and extension movement the first day after surgery. They may use their ipsilateral hand to brush teeth, wash face, and eat. To comb the hair, patients should maintain the neck in a neutral position and raise the elbow. Raise the hand above the head and use the contralateral hand to drag the ipsilateral elbow. Put the

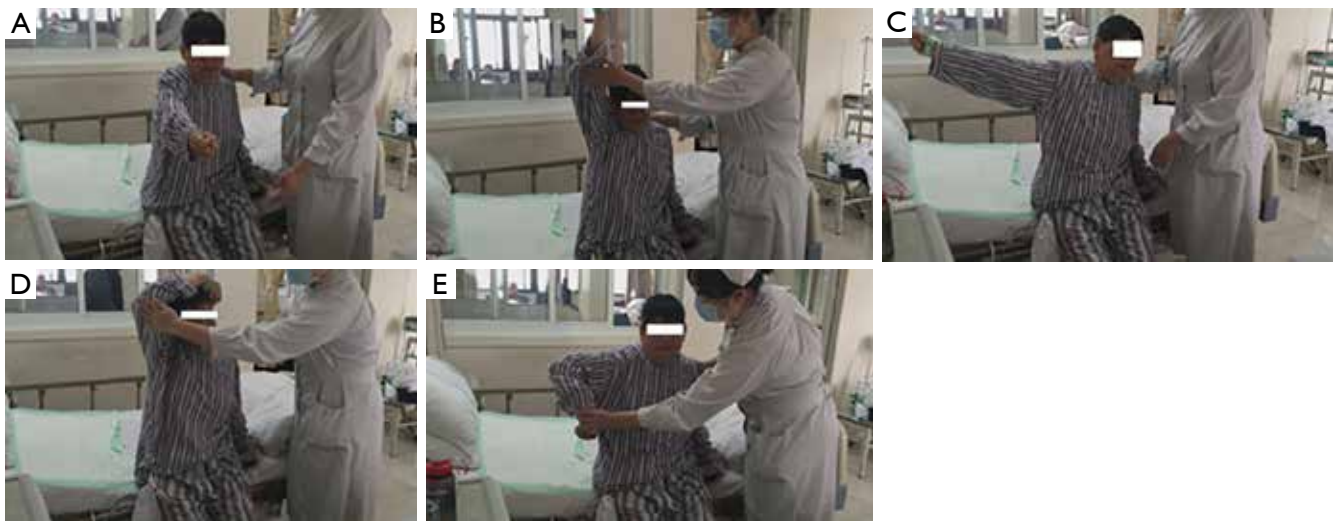


Figure 2 Shoulder exercises.

ipsilateral hand on the shoulder, try to touch the contralateral ear, and gradually put the ipsilateral hand over the head. Do each exercise described above for 3–5 minutes, 3 times a day.

- (iii) Patients can start comprehensive exercise including arm movement the second day after surgery. The ipsilateral and contralateral sides should work together. Lift arms together. Lift arms alternately. Flap arms. Cross fingers behind the head. Open and close elbows in front of the chest at the same height and then open backwards. Do each exercise described above for 3–5 minutes, 3 times a day.

(III) Out-of-bed activities: nurses should assist the patients with steady vital signs in out-of-bed activities the first day after surgery.

- (i) Preparation: fix the drainage tubes and take the drainage bottle. Keep drainage tubes lower than the incision to prevent reflux.
- (ii) For the patients who are in a supine or Fowler's position: support the body with the upper limbs against the bed to move to the side of the bed. For patients with good pain tolerance, lie on the side with help, and sit up at the bedside with the support of a single arm. For patients with poor pain tolerance, sit up with the help of an assistant lifting the neck. Ask the patients

if there is dizziness or discomfort. Sit up 30 seconds after waking up, stand up 30 seconds after sitting up, and start walking 30 seconds after standing up. Patients may have cough because of the position change. Pause walking until they expel the sputum with the help of healthcare providers.

Acknowledgements

None.

Footnote

Conflicts of Interest: The authors have no conflicts of interest to declare.

Informed Consent: Written informed consent was obtained from the patient for publication of this manuscript and any accompanying images.

References

1. Luo Y, Han T. Postoperative nursing of mediastinal tumors resection patients assisted by Da Vinci-S surgery. *Journal of Clinical Medicine in Practice* 2015;19:47-49.
2. Kong P, Xu P, et al. Postoperative nursing of robot-assisted thymectomy in 36 patients. *Journal of Nursing (China)*

- 2013;20:29-31.
3. Jing R, Zhang H, Zhao Y, et al. 161 cases nursing experience of preoperative period about robotic assisted radical hysterectomy. *Practical Journal of Clinical Medicine* 2015;12:12930.
 4. Tong X, Xu S, Wang S, et al. Clinical experience of the treatment of solitary pulmonary nodules with Da Vinci surgical system. *Zhongguo Fei Ai Za Zhi* 2014;17:541-544.
 5. Herron DM, Marohn M. SAGES-MIRA Robotic Surgery Consensus Group. A consensus document on robotic surgery. *Surg Endosc* 2008;22:313-325; discussion 311-312.
 6. Wilmore DW, Kehlet H. Management of patients in fast track surgery. *BMJ* 2001;322:473-476.

doi: 10.21037/amj.2017.01.06

Cite this article as: Hu Y, Pu J, Wu B, Chen X, Li H. Postoperative management of robotic-assisted thoracic surgery. *AME Med J* 2017;2:11.



AME 外科系列图书001

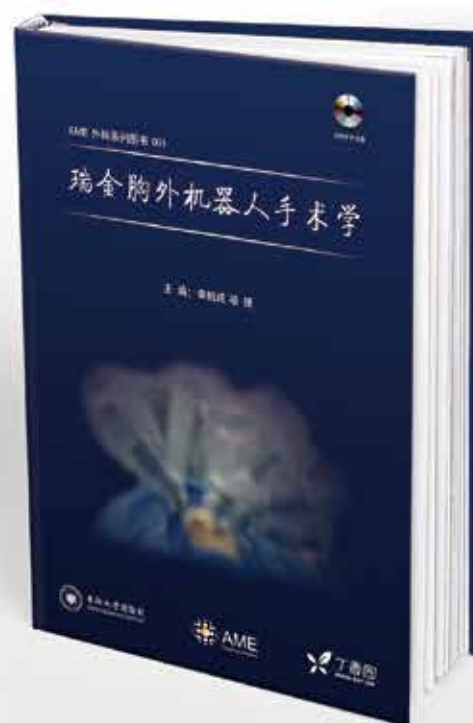瑞金胸外机器人手术学

主 编：李鹤成 项 捷

上海交大医学院附属瑞金医院



AME 科研时间微店预售



本书分享了上海交大医学院附属瑞金医院胸外科机器人手术录像，结合了肺、食管及纵隔解剖的基础知识，重点讲述了应用达芬奇机器人进行普胸外科常见手术的要点和技巧，分别从肺叶，肺段，食管癌，食管良性肿瘤和纵膈肿瘤等几方面进行阐述，具有很强的实用性和指导性。图文并茂，全书用大量的图片介绍和展示解剖要点，详述各个手术的步骤及难点，描述简洁明了，通俗易懂，极其便于读者了解和学习。

Vol 9, No 6 June 2017

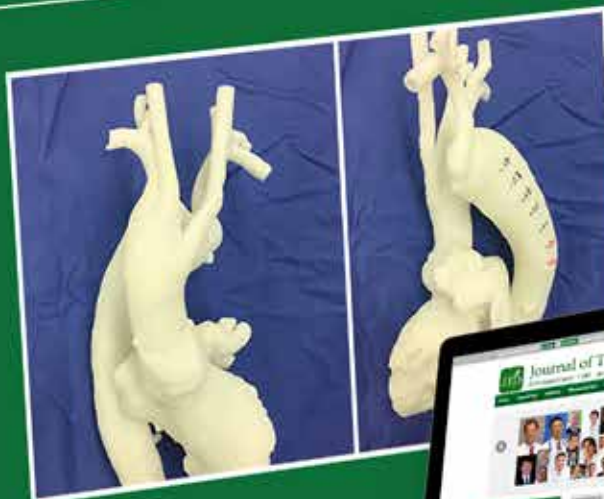ISSN 2072-1439

JOURNAL of THORACIC DISEASE

2016
IMPACT FACTOR
2.365



jtd.amegroups.com



The Official Publication of





JOVS

JOURNAL OF VISUALIZED SURGERY

EDITORS-IN-CHIEF:

ALAN DART LOON SIHOE (THORACIC SURGERY)

YUPEI ZHAO (GENERAL SURGERY)

Features of JOVS

- Highlights the roles of each member of the multi-disciplinary surgical team
- Represents a source of the latest developments in video-enabled operations
- Serves as an archive of video instructions from the masters of such surgery from around the globe

